



HAL
open science

Long-term radiological changes and functional outcomes after proximal row carpectomy: Retrospective study with 3 years' minimum follow-up

Charles Bijon, Marc Saab, Thomas Amouyel, Nadine Sturbois-Nachef, Elvire Guerre, Christophe Chantelot

► To cite this version:

Charles Bijon, Marc Saab, Thomas Amouyel, Nadine Sturbois-Nachef, Elvire Guerre, et al.. Long-term radiological changes and functional outcomes after proximal row carpectomy: Retrospective study with 3 years' minimum follow-up. *Orthopaedics & Traumatology: Surgery & Research*, 2020, 106, pp.1589 - 1595. 10.1016/j.otsr.2020.03.038 . hal-03493701

HAL Id: hal-03493701

<https://hal.science/hal-03493701v1>

Submitted on 15 Dec 2022

HAL is a multi-disciplinary open access archive for the deposit and dissemination of scientific research documents, whether they are published or not. The documents may come from teaching and research institutions in France or abroad, or from public or private research centers.

L'archive ouverte pluridisciplinaire **HAL**, est destinée au dépôt et à la diffusion de documents scientifiques de niveau recherche, publiés ou non, émanant des établissements d'enseignement et de recherche français ou étrangers, des laboratoires publics ou privés.



Distributed under a Creative Commons Attribution - NonCommercial 4.0 International License

Original article

Long-term radiological changes and functional outcomes after proximal row carpectomy: Retrospective study with 3 years' minimum follow-up

Charles **Bijon**^{a*}, Marc **Saab**^a, Thomas **Amouyel**^a, Nadine **Sturbois-Nachef**^a, Elvire **Guerre**^a, Christophe **Chantelot**^a

a CHU Lille, Service d'Orthopédie – Traumatologie, F-59000 Lille, France

Mail = Charles Bijon,

cbijon@gmail.com

Abstract

Introduction: The aim of this study was to analyze the radiological changes and determine the clinical and functional outcomes of proximal row carpectomy (PRC) over the long term.

Hypothesis: Radiological changes after PRC occur in every patient while the clinical and functional outcomes remain stable over time.

Methods This was a retrospective single-center study of patients who underwent PRC between January 2004 and December 2014. A clinical assessment (range of motion, grip strength), functional assessment (Mayo Wrist score and QuickDASH) and radiographic assessment (radiocapitate osteoarthritis, radiocapitate congruency) was done in every patient at the longest follow-up.

Results: Thirty-one patients were reviewed with a mean follow-up of 97.9 months. The indications for PRC were SLAC (n=10), SNAC (n=5), Kienböck disease (n=9) and other conditions (n=7). The radiocapitate index, which is the radius of curvature of the tip of the capitate divided by the mean radius of curvature of the lunate fossa, went from 0.68 immediately postoperative to 0.74 at the final assessment ($p = 0.035$). The mean flexion/extension arc was 93°. The mean grip strength was 25 kg. The mean QuickDASH was 29 and the mean Mayo Wrist score was 69. Fifteen patients had radiocapitate osteoarthritis. Seven patients (22%) required revision surgery for wrist fusion after a mean of 18.6 months.

Conclusion: Radiological adaptation in the radiocapitate joint after PRC was found in this study. PRC is a reliable solution and yields stable outcomes over time for treating radiocarpal osteoarthritis, except in young adults and manual laborers who had a notable early revision rate.

Level of evidence: IV - retrospective study

Keywords: proximal row carpectomy; SLAC; SNAC; Kienböck; osteoarthritis

1. Introduction

Degenerative conditions of the carpus are not very common [1]. The main cause is carpal collapse due to scapholunate ligament lesion and scaphoid nonunion, along with Kienböck's disease, Preiser disease or sequelae of complex wrist injuries. Pain is the main reason that patients consult a surgeon. Several surgical techniques, often palliative, may be offered to patients to eliminate wrist pain and provide sufficient function for day-to-day activities. The technique is selected based on the patient's age, hand dominance, occupation, functional complaint, osteoarthritis stage and the surgeon's preferences. When no degeneration is present in the midcarpal joints, some surgeons prefer doing proximal row carpectomy (PRC), first described by Stamm in 1944 [2]. Others prefer scaphoid excision combined with partial intracarpal fusion as described by Watson [3]. Several studies confirm the good outcomes of PRC in degenerative wrists in the context of SLAC, SNAC, Kienböck's disease and Preiser's disease [4–6]; some also describe its use as emergency management of perilunate carpus dislocation [7]. More recent techniques such as partial wrist fusion, arthroplasty or pyrocarbon implant interposition have started to compete with the more established techniques, with no evidence that one is better than the others [4,8–13].

In PRC, the lunate fossa of the radius articulates with the proximal pole of the capitate forming a neo-radiocapitate joint. However, the articulating surfaces at the lunate fossa of the radius and the proximal pole of the capitate must be completely intact (no chondral lesions) [14]. A comprehensive clinical and radiological preoperative assessment is done to look at the radiocarpal and midcarpal articular surfaces and to propose the most suitable surgical technique [15,16]. In some cases, the decision may hinge on meticulous intraoperative examination of these surfaces

[17]. Some authors always perform arthroscopy and choose the procedure based on the arthroscopic findings [18,19]. In fact, substantial loads will be applied to the future radiocapitate joint; Hogan et al. reported a 57% increase in pressure on the lunate surfaced of the radius after PRC [20]. Progression to radiocapitate osteoarthritis after PRC is a well-known complication, although the clinical and functional outcomes do not appear to be correlated to these radiographic changes [21–23]. The aim of this study was to evaluate the functional, clinical, and radiological outcomes of proximal row carpectomy (PRC) over the long term. The primary hypothesis was that radiological changes after PRC occur in every patient while the clinical and functional outcomes remain stable over time.

2. Method

2.1. Type of study

This was a retrospective single-center study of all patients who underwent PRC between January 2004 and December 2014. Inclusion criteria were adult patients with symptomatic wrist osteoarthritis without involvement of the midcarpal joint or the lunate fossa of the radius who had undergone primary or secondary PRC and had a minimum of 3 years' follow-up. Exclusion criteria were patients with rheumatoid arthritis, neuromuscular disease, or cognitive disorders. All the patients who were reviewed provided written consent to participate in this study.

2.2. Study population

We identified 59 eligible patients between 2004 and 2014; 13 declined to participate in the study, 10 were lost to follow-up and 5 had died, leaving 31 patients for analysis at a mean follow-up of 97.9 months (\pm 42.7). The patients were a mean

of 40.5 (\pm 13.6) years old at the time of the primary intervention; there were 18 men and 13 women. Eighteen patients were manual workers and 17 underwent the procedure on their dominant side. The main reason for consultation was pain and functional disability. The causes of osteoarthritis were SLAC in 10 patients, SNAC in 5 patients, Kienböck's disease in 9 patients, complex wrist trauma in 5 patients, carpal collapse in 1, lunate and triquetrum necrosis in 1 patient (Table 1, Figure 1).

2.3 Surgical technique

The patients were operated under general or regional anesthesia through a dorsal longitudinal or oblique surgical approach. The extensor retinaculum was incised longitudinally between the 3rd and 4th extensor compartment. The posterior interosseous nerve was resected to reduce pain. An H-shaped arthrotomy was done. After evaluating the surfaces of the lunate fossa of the radius and proximal pole of the capitate, PRC was done starting at the lunate, taking all the bones at once when possible. The pisiform was left in place. Joint mobility was then checked to ensure there was no radiocarpal impingement. The arthrotomy was closed with tensionless interrupted sutures—this is a determining factor for the stability of the future radiocarpitate joint. Lastly, the extensor retinaculum was closed, and the skin closed over a suction drain. Postoperative immobilization consisted of a removable short-arm splint for an average of 3 weeks.

2.4. Clinical evaluation

All patients were reviewed by a surgeon who was not involved in the initial surgical procedure. The clinical assessment was done bilaterally to compare the healthy and operated sides. It consisted of joint range of motion measured in degrees using a goniometer with grip and pinch strength measured using a Jamar® dynamometer.

Pain was determined on a visual analog scale (VAS) at rest and during activity, along with the need to take analgesics. The functional outcomes were evaluated using the QuickDASH [24], Mayo Wrist Score [25], and overall satisfaction (very satisfied, satisfied, somewhat satisfied, not satisfied). Some patients underwent wrist fusion secondarily; only the postoperative radiographs and the one made at the last visit before the fusion procedure were analyzed. The clinical outcomes were evaluated only in patients who did not undergo wrist fusion after the PRC.

2.5. Radiographic evaluation

2.5.1. Preoperative

All patients had a preoperative imaging assessment consisting of standard AP and lateral views of the wrist. The stages of SLAC and SNAC were determined using Watson's classification [1,26]. Patients also underwent a CT arthrogram to assess the ligaments and cartilage. Lichtman's classification [27] was used to classify the cases of Kienböck's disease, while the lunate's vascularity was evaluated using MRI.

2.5.2. Postoperative

The radiographic evaluation consisted of standard AP and lateral views of the wrist made immediately after surgery and at the final visit. Measurements were done using iSight PACS software (Philips, Eindhoven, Netherlands) or on standard radiographic films (patients operated before 2010) [28].

The radiographs were used to look for degenerative lesions in the neo-radiocarpitate joint based on the Culp and Jebson classification [29,30] (Figure 2), the Youm index (normal value between 0.51 and 0.57 [31]), ulnar or radial translation of the carpus in the frontal plane as described by Chamay (normal value between 0.25 and 0.31 [32]), and radiocarpitate congruency in the sagittal plane captured by the

radiocapitate index: radius of curvature of the capitate tip divided by the radius of curvature of the lunate fossa. In a perfectly congruent joint, the radiocapitate index will be near 1. An index near 0 corresponds to poor articular congruency between the capitate and lunate fossa of the radius [21,33] (Figure 3).

2.5.3. Statistical analysis

The qualitative data were summarized by their counts and percentages. The quantitative data were summarized by the mean and standard deviation. The normality of the numerical variables was verified graphically and using the Shapiro-Wilk test. A survival analysis with “revision” as the endpoint was done, with the Kaplan-Meier curve shown in Figure 4. Since a few patients underwent revision, the following analyses were done only with the patients who did not require revision: the change in clinical and radiographic measures between the immediate postoperative time point and the final assessment was evaluated using a paired Student’s *t* test or a paired Wilcoxon test. The significance threshold was set at 5%. The statistical analysis was performed using SAS software (version 9.4, SAS Institute, Cary, NC, USA).

3. Results

3.1. Clinical outcomes (Patients who did not undergo secondary fusion)

In the 24 patients who did not undergo secondary fusion, the mean pain level was 1.4 (± 2) at rest and 3.6 (± 2.5) during activity. Five patients took analgesics daily or occasionally. All the joint motions were reduced relative to the healthy contralateral side, with the flexion-extension and radioulnar deviation arcs being significantly less. The pinch and grip strength were less on the operated side, but not significantly (Table 2).

3.2. Functional outcomes

Twenty patients said they were satisfied or very satisfied with the procedure, while one was somewhat satisfied and three were not satisfied. The mean QuickDASH was 29 (\pm 25) and the mean Mayo Wrist Score was 69 (\pm 23), corresponding to a satisfactory result (Table 2).

3.3. Radiographic outcomes

In these 24 patients, 15 patients (62.5%) had radiocapitate osteoarthritis graded as stage 1 in 5 patients, stage 2 in 5 patients and stage 3 in 5 patients. The carpal height, Youm index and Chamay index were not statistically different at the final assessment relative to the immediate postoperative values. The radius of curvature of the lunate fossa of the radius did not change statistically since it averaged at 10.27 mm (\pm 1.83) immediately postoperative and was 10.47 mm (\pm 1.65) at the final assessment ($p = 0.655$). There was a statistically significant difference in the radius of curvature of the capitate head which averaged 6.94 mm (\pm 1.08) immediately postoperative and was 7.75 mm (\pm 1.95) at the final assessment ($p = 0.028$). The radiocapitate index was 0.68 (\pm 0.1) immediately postoperative and 0.74 (\pm 0.1) at the final assessment, which was a significant change ($p = 0.035$) (Table 3).

3.4. Complications

Of the 31 patients who underwent PRC, 7 subsequently underwent total wrist fusion. The mean time to revision was 18.6 months (\pm 6.8) and the mean age of these patients was 34.2 years (\pm 7.5). Five of these seven patients did manual labor. The reason for revision was disabling pain. The initial indication for PRC was SLAC in 2

patients, SNAC in 2 patients and Kienböck's disease in 3 patients, with one of these patients having received a Swanson-like implant before the PRC and two patients having Lichtman stage IV disease. Of the 24 patients who did not undergo secondary fusion, two had complex regional pain syndrome: one resolved spontaneously, and one had continuing neuropathic pain at 50 months' follow-up, with no signs of radiocapitate osteoarthritis at the final assessment. One patient underwent wrist extensor tenolysis because of scar adhesions and one patient underwent secondary radial styloidectomy due to radiotrapezial impingement, with a satisfactory outcome.

Discussion

In this study of patients with post-traumatic wrist osteoarthritis (SNAC or SLAC) or advanced Kienböck's disease, PRC results in wrists that were only mildly painful, graded less than 4 on VAS during activity. The range of motion was significantly lower than the healthy side for flexion-extension and radioulnar deviation. Pinch and grip strength were not significantly less than the healthy contralateral side at the final assessment. The functional outcome scores were satisfactory at a minimum 4 years' follow-up. And based on the radiographs, 15 patients had radiocapitate osteoarthritis at the final assessment, the radius of curvature of the capitulum had significantly increased and the radiocapitate index had also increased. Most studies report a slight decrease in postoperative joint motion, which our findings are consistent with, even when the PRC is followed by an early postoperative mobilization protocol [34,35]. In a study of 18 patients with Kienböck's disease, Croog et al. found the flexion-extension range of motion was 12° better than in our study, with 105° at more than 10 years' follow-up [36]. Our pinch and grip strength findings are like other published studies. Ali et al. were the only team to report a large decrease in

postoperative grip strength (48%) in the operated wrist relative to the healthy contralateral side. This difference relative to the other studies can be explained by the fact that it included patients who had rheumatoid arthritis and neuromuscular diseases. As for the functional outcomes, the QuickDASH corresponded to very low functional disability while the Mayo Wrist score corresponded to satisfactory results. Most authors concur that the functional scores stabilize in the long term, which is what we found [22,23,30,36–41].

Radiologically, we found long-term progression towards osteoarthritis of the new radiocapitate joint, like several other authors. However, the clinical and functional outcomes did not appear to deteriorate, even with more than 20 years of follow-up [22]. The joint congruency between the capitate head and the lunate fossa of the radius has not been studied extensively. According to Imbriglia et al., the radius of curvature of the capitate head corresponds to between 60% and 64% of that of the lunate fossa of the radius. This difference tends to improve over time, reaching 67% to 72% [21]. Like Chedal-Bornu et al., we observed that the ratio between these two radiuses of curvature (radiocapitate index) tends to get closer to 1, and had changed significantly by the final assessment [23]. On radiographs, the lunate fossa of the radius tends to become deeper and the capitate tends to flatten and become wider. This contributes to the morphological adaptation of this new joint over time and may explain the good long-term clinical and functional outcomes. The architectural changes in the new radiocapitate joint seen on radiographs could be an osteoarthritis progression or simply remodeling in the joint space. It would be interesting to do an MRI or bone scan in patients who have higher Culp scores or a radiocapitate index near 1, to further evaluate the joint space.

In our study, the PRC failure rate was 22% (7/31 patients); these patients were revised by total wrist fusion. This percentage is similar to that reported in other studies [22,23,37,38]. According to Wagner et al, the revision rate is higher in patients less than 40 years of age, those who do manual labor and those whose osteoarthritis is secondary to Kienböck's disease. These factors were found in our study. The revisions most often occur within 3 years of the PRC since the condition stabilizes itself afterwards [39].

Our study has several limitations. The nature of this retrospective study led to a loss of patients and thus statistical power and may have contributed to certain findings not being statistically significant. We did not have any preoperative clinical and functional scores. Because of this, the findings at the final assessment were compared to the healthy contralateral side, limiting the scope of the conclusions about improving functional scores.

Conclusion

PRC is a reliable option that produces a minimally painful wrist with satisfactory motion in patients who have wrist osteoarthritis that does not affect the capitate head or lunate fossa of the radius. While radiographic changes over time were found in all patients, the clinical outcomes were stable, and the number of complications was low.

Conflict of interest: The authors have no conflict of interest to declare relative to this work.

Funding: No funding was received for this study

Author contributions:

CB: wrote and revised manuscript, analyzed data

MS: wrote and revised manuscript

TA: critical review of manuscript; support

NSN: critical review of manuscript

EG: critical review of manuscript, supervision

CC: critical review of manuscript, supervision

References

1. Watson HK, Ballet FL. The SLAC wrist: scapholunate advanced collapse pattern of degenerative arthritis. *J Hand Surg.* 1984;9:358–65.
2. Stamm TT. Excision of the Proximal Row of the Carpus. *Proc R Soc Med.* 1944 Dec;38(2):74–5.
3. Watson HK, Weinzweig J, Guidera PM, Zeppieri J, Ashmead D. One thousand intercarpal arthrodeses. *J Hand Surg Edinb Scotl.* 1999;24:307–15.
4. Le Nen D, Richou J, Simon E, Le Bourg M, Nabil N, de Bodman C, Bacle G, Saint-Cast Y, Obert L, Saraux A, Bellemère P, Dréano T, Laulan J. The arthritic wrist. I - The degenerative wrist: Surgical treatment approaches. *Orthop Traumatol Surg Res.* 2011;97:S31–6.
5. Laulan J, Marteau E, Bacle G. Wrist osteoarthritis. *Orthop Traumatol Surg Res OTSR.* 2015;101:S1-9.
6. Lenoir H, Coulet B, Lazerges C, Mares O, Croutzet P, Chammas M. Idiopathic avascular necrosis of the scaphoid: 10 new cases and a review of the literature. Indications for Preiser's disease. *Orthop Traumatol Surg Res OTSR.* 2012 ;98:390–7.
7. Muller T, Hidalgo Diaz JJ, Pire E, Prunières G, Facca S, Liverneaux P. Treatment of acute perilunate dislocations: ORIF versus proximal row carpectomy. *Orthop Traumatol Surg Res OTSR.* 2017;103:95–9.
8. Aita MA, Nakano EK, Schaffhausser H de L, Fukushima WY, Fujiki EN. Randomized clinical trial between proximal row carpectomy and the four-corner fusion for patients with stage II SNAC. *Rev Bras Ortop Engl Ed.* 2016 ;51:574–82.
9. Berkhout MJL, Bachour Y, Zheng KH, Mullender MG, Strackee SD, Ritt MJPF. Four-Corner Arthrodesis Versus Proximal Row Carpectomy: A Retrospective Study With a Mean Follow-Up of 17 Years. *J Hand Surg.* 2015;40:1349–54.
10. Cohen MS, Kozin SH. Degenerative arthritis of the wrist: Proximal row carpectomy versus scaphoid excision and four-corner arthrodesis. *J Hand Surg.* 2001 ;26:94–104.
11. Mulford JS, Ceulemans LJ, Nam D, Axelrod TS. Proximal Row Carpectomy vs Four Corner Fusion for Scapholunate (Slac) or Scaphoid Nonunion Advanced Collapse (Snac) Wrists: A Systematic Review of Outcomes. *J Hand Surg Eur Vol.* 2009;34:256–63.
12. Saltzman BM, Frank JM, Slikker W, Fernandez JJ, Cohen MS, Wysocki RW. Clinical outcomes of proximal row carpectomy versus four-corner arthrodesis for post-traumatic wrist arthropathy: a systematic review. *J Hand Surg Eur Vol.* 2015 ;40:450–7.

13. Tomaino MM, Miller RJ, Cole I, Burton RI. Scapholunate advanced collapse wrist: Proximal row carpectomy or limited wrist arthrodesis with scaphoid excision? *J Hand Surg.* 1994;19:134–42.
14. Green DP, Perreira AC, Longhofer LK. Proximal Row Carpectomy. *J Hand Surg.* 2015;40:1672–6.
15. Vishwanathan K, Hearnden A, Talwalkar S, Hayton M, Murali SR, Trail IA. Reproducibility of radiographic classification of scapholunate advanced collapse (SLAC) and scaphoid nonunion advanced collapse (SNAC) wrist. *J Hand Surg Eur Vol.* 2013;38:780–7.
16. Belhaouane R, Lebeau N, Maes-Clavier C, Hustin C, Krief E, Bonnaire B, Warin M, Rotari V, David E. Reproducibility of X-rays and CT arthrography in SLAC, SNAC, SCAC wrists. *Hand Surg Rehabil.* 2016;35:393–400.
17. Zinberg EM, Chi Y. Proximal Row Carpectomy Versus Scaphoid Excision and Intercarpal Arthrodesis: Intraoperative Assessment and Procedure Selection. *J Hand Surg.* 2014;39:1055–62.
18. C. Mathoulin, Messina J. Traitement arthroscopique des lésions cartilagineuses au poignet. *Chir Main.* 2006;25:S231–43.
19. Luchetti R. Proximal row carpectomy, scaphoidectomy with midcarpal arthrodesis or midcarpal tenodesis: when and how to use. *J Hand Surg Eur Vol.* 2018 ;43:579–88.
20. Hogan CJ, McKay PL, Degnan GG. Changes in radiocarpal loading characteristics after proximal row carpectomy. *J Hand Surg.* 2004 ;29:1109–13.
21. Imbriglia JE, Broudy AS, Hagberg WC, McKernan D. Proximal row carpectomy: clinical evaluation. *J Hand Surg.* 1990;15:426–30.
22. Wall LB, DiDonna ML, Kiefhaber TR, Stern PJ. Proximal Row Carpectomy: Minimum 20-Year Follow-Up. *J Hand Surg.* 2013;38:1498–504.
23. Chedal-Bornu B, Corcella D, Forli A, Moutet F, Bouyer M. Long-term outcomes of proximal row carpectomy: A series of 62 cases. *Hand Surg Rehabil.* 2017 ;36:355–62.
24. Hudak PL, Amadio PC, Bombardier C. Development of an upper extremity outcome measure: the DASH (disabilities of the arm, shoulder and hand) [corrected]. The Upper Extremity Collaborative Group (UECG). *Am J Ind Med.* 1996 ;29:602–8.
25. Cooney WP, Bussey R, Dobyns JH, Linscheid RL. Difficult wrist fractures. Perilunate fracture-dislocations of the wrist. *Clin Orthop.* 1987;:136–47.
26. Vender MI, Watson HK, Wiener BD, Black DM. Degenerative change in symptomatic scaphoid nonunion. *J Hand Surg.* 1987;12:514–9.

27. Goldfarb CA, Hsu J, Gelberman RH, Boyer MI. The Lichtman classification for Kienböck's disease: An assessment of reliability. *J Hand Surg.* 2003 ;28:74–80.
28. Sorin G, Pasquier G, Drumez E, Arnould A, Migaud H, Putman S. Reproducibility of digital measurements of lower-limb deformity on plain radiographs and agreement with CT measurements. *Orthop Traumatol Surg Res.* 2016 ;102:423–8.
29. Culp RW, McGuigan FX, Turner MA, Lichtman DM, Osterman AL, McCarroll HR. Proximal row carpectomy: a multicenter study. *J Hand Surg.* 1993;18:19–25.
30. Jebson P, Hayes EP, Engber WD. Proximal row carpectomy: a minimum 10-year follow-up study. *J Hand Surg.* 2003;28:561–9.
31. McMurtry RY, Youm Y, Flatt AE, Gillespie TE. Kinematics of the wrist. II. Clinical applications. *J Bone Joint Surg Am.* 1978;60:955–61.
32. Chamay A, Della Santa D, Vilaseca A. Radiolunate arthrodesis. Factor of stability for the rheumatoid wrist. *Ann Chir Main Organe Off Soc Chir Main.* 1983;2:5–17.
33. Hawkins-Rivers S, Budoff JE, Ismaily SK, Noble PC, Haddad J. MRI Study of the Capitate, Lunate, and Lunate Fossa With Relevance to Proximal Row Carpectomy. *J Hand Surg.* 2008 ;33:841–9.
34. Jacobs R, Degreef I, De Smet L. Proximal row carpectomy with or without postoperative immobilisation. *J Hand Surg Eur Vol.* 2008;33:768–70.
35. Edouard P, Vernay D, Martin S, Hirsch P, Bardoux S, Grange C, Claus D, Claise J-M. Proximal row carpectomy: Is early postoperative mobilisation the right rehabilitation protocol? *Orthop Traumatol Surg Res OTSR.* 2010;96:513–20.
36. Croog AS, Stern PJ. Proximal Row Carpectomy for Advanced Kienböck's Disease: Average 10-Year Follow-Up. *J Hand Surg.* 2008;33:1122–30.
37. DiDonna ML, Kiefhaber TR, Stern PJ. Proximal row carpectomy: study with a minimum of ten years of follow-up. *J Bone Joint Surg Am.* 2004;86-A:2359–65.
38. Ali MH, Rizzo M, Shin AY, Moran SL. Long-Term Outcomes of Proximal Row Carpectomy: A Minimum of 15-Year Follow-up. *HAND.* 2012;7:72–8.
39. Wagner ER, Bravo D, Elhassan B, Moran SL. Factors associated with improved outcomes following proximal row carpectomy: a long-term outcome study of 144 patients. *J Hand Surg Eur Vol.* 2016;41:484–91.
40. Richou J, Chuinard C, Moineau G, Hanouz N, Hu W, Le Nen D. Proximal row carpectomy: Long-term results. *Chir Main.* 2010;29:10–5.
41. Lumsden BC, Stone A, Engber WD. Treatment of advanced-stage Kienböck's disease with proximal row carpectomy: an average 15-year follow-up. *J Hand Surg.* 2008;33:493–502.

42. Wyrick JD. Proximal row carpectomy and intercarpal arthrodesis for the management of wrist arthritis. *J Am Acad Orthop Surg.* 2003;11:277–81.

Figure legends

Figure 1: Study flow chart

Figure 2: Culp-Jebson classification

- Stage 0: no osteoarthritis
- Stage I: joint space narrowing < 50%
- Stage II: joint space narrowing >50% + subchondral bone condensation
- Stage III: complete loss of joint space, erosions, subchondral cysts, osteophytes

Figure 3: Measurement of the radius of curvature on radiographs (according to

Imbriglia et al.) and example of how ratio is calculated.

Red circle and line: capitata radius of curvature; Green circle and line: radius of curvature of lunate fossa of radius

Figure 4: Survival curve for PRC with “revision” as the endpoint

Tables

Table 1 - Study population

Patients	31
<hr/>	
Age (years)	40.5 (\pm 13.6)
<hr/>	
Sex	
Male	18
Female	13
<hr/>	
Dominant side	
Right	24
Left	4
Ambidextrous	3
<hr/>	
Manual worker	18
<hr/>	
Procedure on dominant side	17
<hr/>	
Diagnosis	
SLAC	10
SNAC	5
Kienböck	9
Trauma	5
Other	2

Table 2 - Clinical and functional outcomes of patients who did not undergo secondary fusion

Patients		24	
Pain on VAS at rest		1.4 (\pm 2)	
Pain on VAS during activity		3.6 (\pm 2.5)	
ROM Flexion/Extension ($^{\circ}$)			
	Operated	93 (\pm 37)	p = 0.0001
	Healthy	139 (\pm 36)	
ROM Radial/Ulnar deviation ($^{\circ}$)			
	Operated	28 (\pm 9)	p = 0.0007
	Healthy	39 (\pm 9)	
ROM Pronation/Supination ($^{\circ}$)			
	Operated	165 (\pm 43)	p = 0.415
	Healthy	171 (\pm 37)	
Grip strength (kg)			
	Operated	25 (\pm 13)	p = 0.096
	Healthy	32 (\pm 16)	
Pinch strength (kg)			
	Operated	9 (\pm 5)	p = 0.903
	Healthy	10 (\pm 7)	
QuickDASH		29 (\pm 25)	
MWS		69 (\pm 23)	
Overall satisfaction			
	Very satisfied	12	
	Satisfied	8	
	Somewhat satisfied	1	
	Not satisfied	3	

Table 3 - Radiographic outcomes of patients who did not undergo secondary fusion

Patients	24	
Carpal height (mm)		
Immediately postoperative	24.8 (± 2.3)	p = 0.066
Last follow-up	24.1 (± 1.9)	
Youm index (mm)		
Immediately postoperative	0.38 (± 0.04)	p = 0.332
Last follow-up	0.38 (± 0.03)	
Chamay index (mm)		
Immediately postoperative	0.36 (± 0.02)	p = 0.3398
Last follow-up	0.36 (± 0.03)	
Radius of curvature lunate fossa of the radius (mm)		
Immediately postoperative	10.27 (± 1.83)	p = 0.655
Last follow-up	10.47 (± 1.65)	
Radius of curvature capitate (mm)		
Immediately postoperative	6.94 (± 1.08)	p = 0.028
Last follow-up	7.75 (± 1.95)	
Curvature ratio (congruency index)		
Immediately postoperative	0.68 (± 0.1)	p = 0.035
Last follow-up	0.74 (± 0.1)	

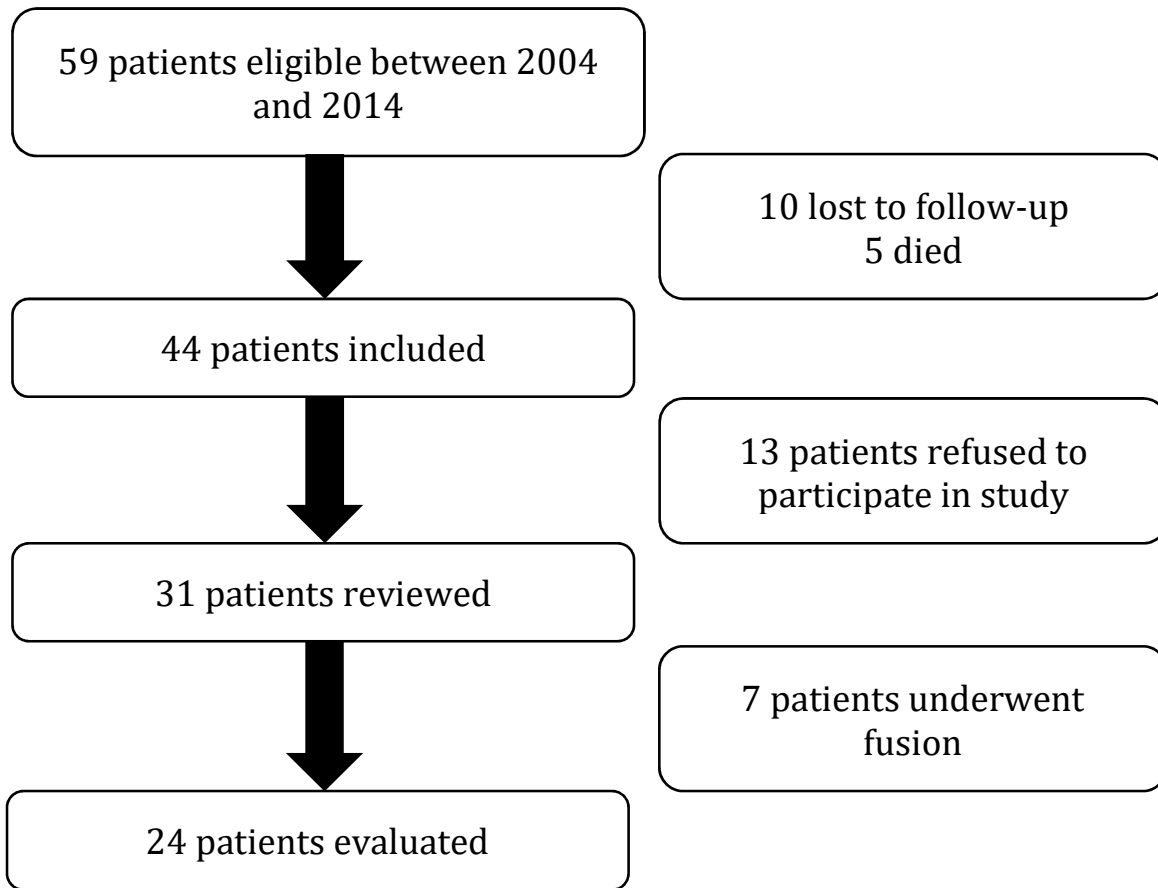
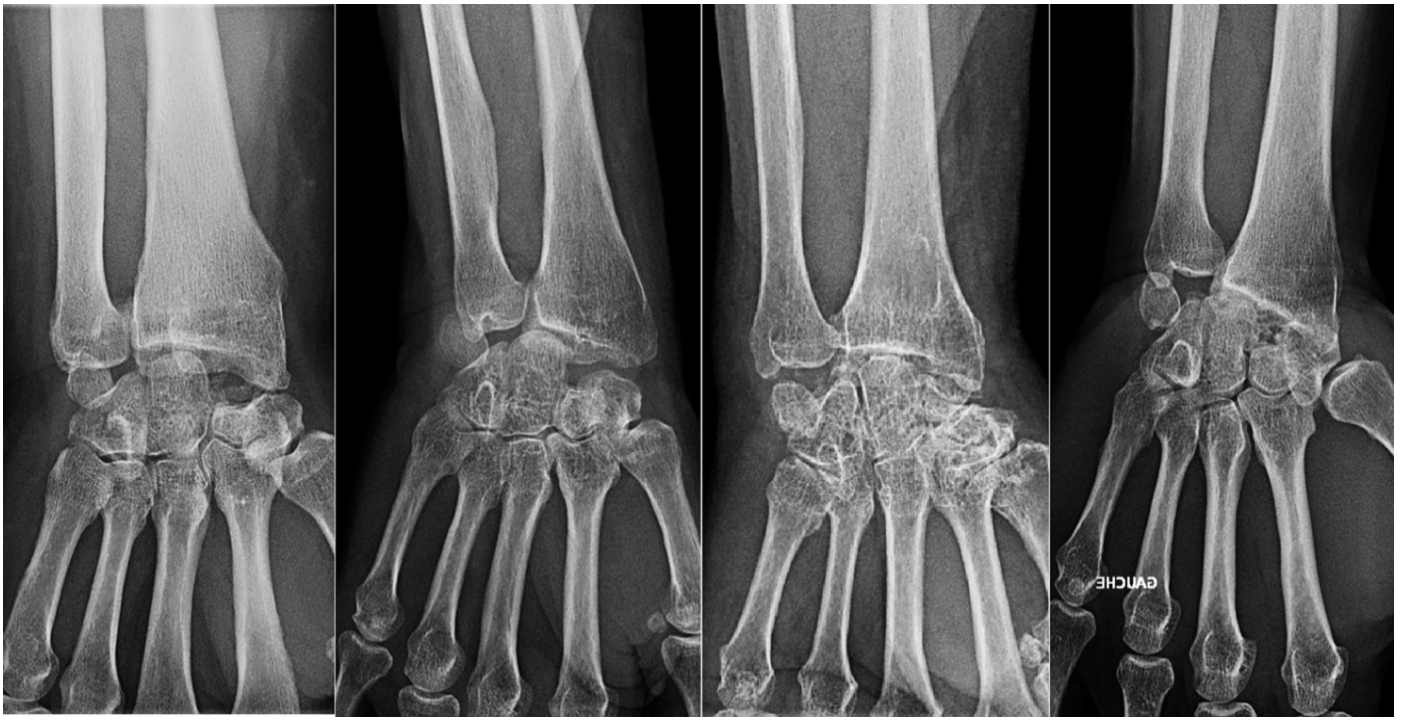

Figure 1 :



Stage 0

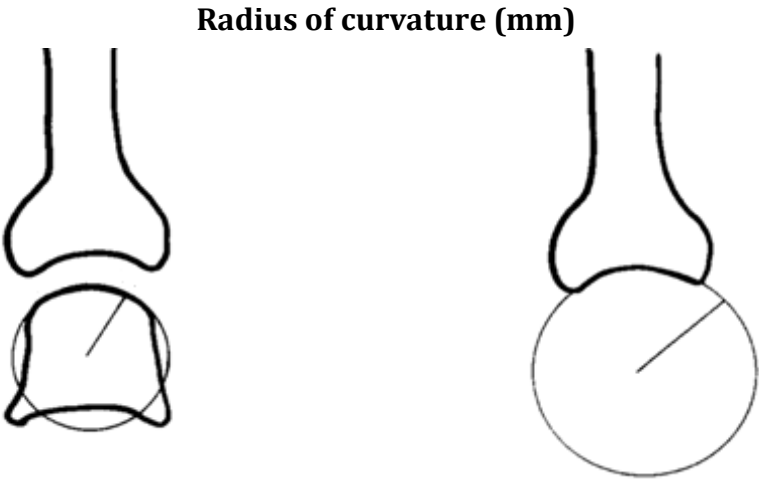
Stage I

Stage II

Stage III

Figure 2 :

Figure 3:



Capitate

Lunate fossa

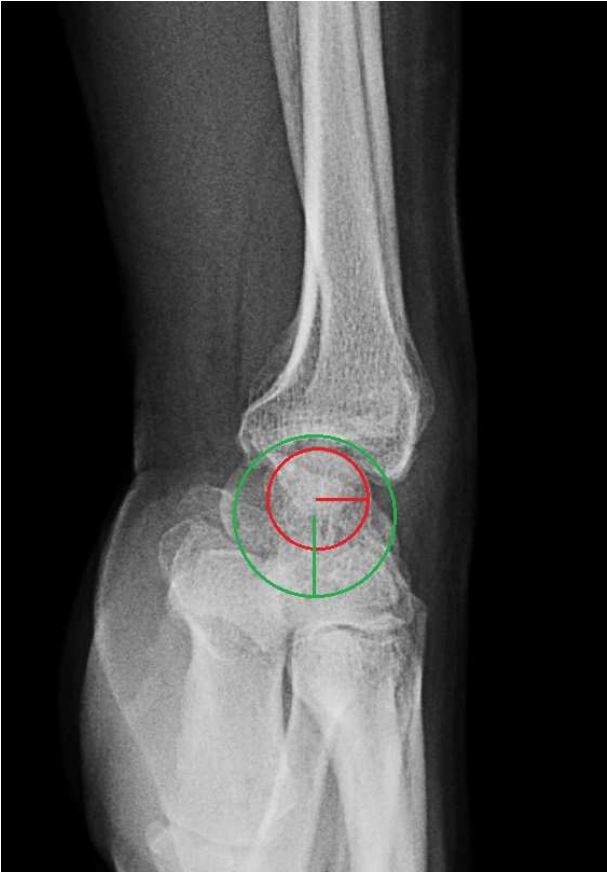

Figure 4:

