



HAL
open science

Specificities of small cell neuroendocrine prostate cancer: Adverse prognostic value of TTF1 expression

Mathilde Cancel, Claire Castellier, Celine Debiais-Delpech, Thomas Charles, François Rozet, Nathalie Rioux-Leclercq, Romain Mathieu, Françoise Beltjens, Luc Cormier, Franck Bruyère, et al.

► To cite this version:

Mathilde Cancel, Claire Castellier, Celine Debiais-Delpech, Thomas Charles, François Rozet, et al.. Specificities of small cell neuroendocrine prostate cancer: Adverse prognostic value of TTF1 expression. *Urologic Oncology: Seminars and Original Investigations*, 2021, 39, pp.74.e17 - 74.e23. 10.1016/j.urolonc.2020.07.007 . hal-03493690

HAL Id: hal-03493690

<https://hal.science/hal-03493690>

Submitted on 15 Dec 2022

HAL is a multi-disciplinary open access archive for the deposit and dissemination of scientific research documents, whether they are published or not. The documents may come from teaching and research institutions in France or abroad, or from public or private research centers.

L'archive ouverte pluridisciplinaire **HAL**, est destinée au dépôt et à la diffusion de documents scientifiques de niveau recherche, publiés ou non, émanant des établissements d'enseignement et de recherche français ou étrangers, des laboratoires publics ou privés.



Distributed under a Creative Commons Attribution - NonCommercial 4.0 International License

SPECIFICITIES OF SMALL CELL NEUROENDOCRINE PROSTATE CANCER:
ADVERSE PROGNOSTIC VALUE OF TTF1 EXPRESSION

Mathilde Cancel^{1,2}, Claire Castellier³, Celine Debiais-Delpech⁴, Thomas Charles⁵,
François Rozet⁶, Nathalie Rioux-Leclercq⁷, Romain Mathieu⁸, Françoise Beltjens⁹, Luc
Cormier¹⁰, Franck Bruyère¹¹, Gaëlle Fromont^{1,3}

¹*Inserm UMR1069 “Nutrition, Croissance et Cancer” Université de Tours,
CHRU Bretonneau, Departments of ²Oncology, ³Pathology and ¹¹Urology, 37000 Tours,
France*

CHU Poitiers, Departments of ⁴Pathology and ⁵Urology, 86000 Poitiers, France

⁶*Institut Mutualiste Montsouris, Department of Urology, 75014 Paris, France*

CHU Rennes, Departments of ⁷Pathology and ⁸Urology, 35000 Rennes, France

*Centre Georges Francois Leclerc, Department of ⁹Pathology, and CHU Dijon, Department
of ¹⁰Urology, 21000 Dijon, France*

Address for correspondence:

Gaëlle Fromont, MD, PhD

Service d'Anatomie Pathologique

Hopital Bretonneau, CHRU Tours

Bld Tonnelle

37000 Tours

France

Tel : +33 (0)2-47-47-82-72

Fax : +33 (0)2-47-47-82-74

Email: gaille.fromont-hankard@univ-tours.fr

Declarations of interest: none

ABSTRACT

OBJECTIVES: To determine whether small cell neuroendocrine prostate cancers (NEPCa) emerging after anti-androgen treatments are different from the rarest cases diagnosed *de novo*, and to identify effective predictive markers.

MATERIAL AND METHODS: The expression of neuroendocrine markers, androgen receptor (AR) and androgen-regulated genes, as well as markers of aggressiveness, were analyzed by immunohistochemistry on a tissue microarray containing samples of 30 sNEPCa, either pure or admixed with conventional PCa, and including 14 cases diagnosed *de novo* and 16 cases subsequent to prior androgen deprivation.

RESULTS: Chromogranin A is a better marker of NE differentiation than synaptophysin in post-treatment NEPCa, with 94% and 44% of positive tumors, respectively, while both markers are equally expressed in *de novo* cases. Despite the acquisition of a NE phenotype, more than half of NEPCa expressed AR and the androgen-regulated gene NKX3.1, more frequently in cases admixed with conventional PCa. TTF1 staining, present in half of NEPCa, was associated with loss of androgen-regulated genes and with markers of aggressiveness, including increased proliferation, Zeb1 expression and PTEN loss. In multivariate analysis, only TTF1 expression was significantly associated with shorter overall survival.

CONCLUSION: These results suggest the persistence of androgen signaling in a number of NEPCa cases, and the interest of TTF1 staining as a predictive biomarker.

Keywords: prostate cancer; neuroendocrine carcinoma; prognosis

INTRODUCTION

Small cell neuroendocrine prostate cancer (NEPCa) is a rare and highly aggressive disease, that can present *de novo*, but more commonly arises after androgen deprivation or androgen receptor (AR) targeted therapy for conventional prostate adenocarcinoma (PCa) [1, 2]. Although some NEPCa are composed only by NE cells, characterized by the presence of secretory granules, others are admixed with an adenocarcinoma component [1, 2].

NE phenotype in PCa cells includes low or absent expression of the androgen receptor (AR) and androgen-regulated markers, together with the acquisition of NE markers like synaptophysin and chromogranin A [3, 4]. In addition, more than half of NEPCa cases have been shown to express the thyroid transcription factor-1 (TTF1), that cannot therefore be used as a marker to distinguish between lung and prostatic origin of NE carcinoma [3, 4].

Rearrangements involving *ERG* and the androgen regulated gene *TMPRSS2*, that are present in around 50% of conventional acinar PCa, have also been demonstrated in NEPCa [5, 6]. Since *ERG* rearrangements are prostate specific [7], this finding could help to distinguish NEPCa from NE carcinomas of other primary sites, and suggests that NEPCa is derived from acinar PCa cells. In addition, the presence of NEPCa cases mixed with conventional acinar PCa, coupled with evidence of cells that may co-express in one side NE markers and on the other side AR and its target genes, also strengthen the hypothesis that NEPCa could arise from non NE prostatic tumor cells through a phenomenon termed transdifferentiation [2, 8].

Although the molecular characterization of NEPCa has been improved in recent years, focused on the genetic aspects of the disease, it remains unclear whether there is a different immunophenotype in *de novo* and post-treatment NEPCa, and whether NE cancer cells are different in pure compared to mixed tumors. **In addition, even if NEPCa is an aggressive disease, there is a need to identify markers that could distinguish patients with a better prognostic.**

In the present study, we characterized the immunophenotypic profile of 30 NEPCa, **in order to evaluate the differences between *de novo* and post-treatment tumors, as well as between pure and mixed cases, and to identify prognostic markers related to survival.**

MATERIALS AND METHODS

Samples

Samples from 50 patients diagnosed with neuroendocrine prostate cancer (NEPCa) were retrieved from the files of 5 institutions, and subsequently selected according to the following criteria: pure NEPCa or admixed with minor conventional adenocarcinoma component, with small cell morphology, formalin fixed tissues, sufficient amount of cancer tissue available, at least 6 months follow-up after tissue collection.

At the end, with these criteria, samples from 30 patients were retained (see flowchart, supplementary Fig1), and included transurethral resections (n=19), radical prostatectomy specimens (n=2), prostate biopsies (n=5), or biopsies from a metastatic site (n=4). The diagnosis of NEPCa was suspected on morphologic criteria, with small cell carcinoma features (Fig 1A), and confirmed after immunostaining with either chromogranin A or synaptophysin. Fourteen cases were diagnosed *de novo*, in the absence of any prior treatment, and 16 cases were subsequent to previous hormone deprivation. For the 16 later patients, the initial pathology on prostate biopsies was devoid of NE component; androgen deprivation therapy was initially effective, but all patients subsequently relapsed with a NE phenotype. Ten cases were pure NEPCa, and for 20 patients NEPCa was admixed with conventional adenocarcinoma, most often with an abrupt transition between the two components.

Immunohistochemistry on Tissue Micro-Array

TMA Construction: TMAs were constructed using formalin-fixed paraffin-embedded tissue samples. For each case, a minimum of 3 cores (0.6 diameter) were transferred from the selected areas to the recipient block, using a TMA workstation (Manual Tissue Arrayer MTA Booster, Alphelys, France). Serial 3 μ m sections of the TMA blocks were used for immunohistochemistry. One section on ten was stained with hematoxylin-eosin to check that the cores adequately represented diagnostic areas.

Immunohistochemistry: Slides were deparaffinized, rehydrated, and heated in citrate buffer pH 6 for antigenic retrieval. After blocking for endogenous peroxidase with 3% hydrogen peroxide, the primary antibodies were incubated. The panel of primary antibodies included chromogranin A (Zytomed, MSG 062, dilution 1/1, 30 min), synaptophysin

(DakoCytomation, clone DAK-SYNAP, 1/200, 30 min), TTF1 (Roche, SP141, 1/1, 30 min), androgen receptor (AR) (Roche, clone SP107), NKX3.1 (Roche, EP356, 1/1, 30 min), PTEN (Cell Signaling, 138G6, 1/200), ERG (Roche, EPR 3864, 1/1, 30 min), Zeb1 (Abnova, clone 4C4, 1/500, 1 hour), and the proliferation marker Ki67 (DakoCytomation, clone 39-9, 1/50, 30 min). Immunohistochemistry was performed with either the automated BenchMark XT slide stainer (Ventana Medical Systems Inc) using OptiView Detection Kit (Ventana Medical Systems Inc) or manually (for PTEN and Zeb1) using the streptavidin-biotin-peroxydase method with diaminobenzidine as the chromogen (Kit LSAB, Dakocytomation, Glostrup, Denmark). Slides were finally counterstained with haematoxylin. Negative controls were obtained after omission of the primary antibody or incubation with an irrelevant antibody.

Scoring of antibody staining: The slides were analyzed by 2 observers in a blinded fashion. AR, Zeb1 and Ki67 were expressed as a percentage of cancer cells. Staining for PTEN was scored as - : no stained cells, +: low intensity, ++: high intensity. Chromogranin A, synaptophysin, TTF1, NKX3.1 and ERG were expressed as positive or negative. In case of inter-observer variability (different categories in the case of categorical data or variability more than 10% in the case of continuous data), which occurred in <5% of cases, slides were rescored until a consensus was reached.

Statistical analysis

Statistical analyses were carried out with StatView, version 5.0, software (Abacus Concepts, Berkeley, CA). Comparison between groups was performed using the χ^2 test for categorical data and nonparametric Mann-Whitney *U* test or Kruskal Wallis test for continuous data. The relationship between 2 continuous variables was evaluated using the nonparametric Spearman rank correlation test. **Overall survival** was analyzed by Kaplan-Meier method, and the curves were compared using the log-rank test. Multivariate survival analysis was performed using Cox's regression model. P-values <0.05 were considered significant.

RESULTS

Patients characteristics

Median age at diagnosis was 72 years (range 52-86), and median serum PSA was 6 ng/ml (range 0.03-1288, 0.03-3.60 for pure cases, and 4.7-1288 for mixed cases). Twenty three patients had metastasis at diagnosis, including 9 with visceral metastasis (liver or lung). Among the 16 cases secondary to previous hormone deprivation, 9 patients initially underwent local treatment, including prostatectomy (n=1), radiation therapy (n=7), or both (n=1). NEPCa subsequent to prior hormone deprivation were treated with either second generation hormonotherapy or taxanes (n=5), or platinum chemotherapy (alone or associated with etoposide) (n=6). Among the 14 *de novo* cases, 6 patients underwent local treatment after NEPCa diagnosis, including prostatectomy (n=2), radiation therapy (n=4). These *de novo* cases were subsequently treated by either primary hormone deprivation (cases admixed with adenocarcinoma) (n=10) then second generation hormonotherapy (n=1), or platinum chemotherapy (alone or associated with etoposide) (n=8, 4 with associated hormone deprivation therapy). The sequence of treatments according to tissue sampling is provided in supplementary Figure 2. Twenty-four patients on 30 died, and the median follow-up from tissue collection to last news or death was 13 months (0.3 – 68 months). Written informed consents were obtained from patients in accordance with the requirements of the medical ethic committee of our institutes.

Immunoprofile

The expression profile of all markers is summarized Table 1. Briefly, chromogranin A is expressed in 10 on 14 *de novo* cases, and in 15 on 16 post-treatment cases (Fig 1B). The 5 chromogranin negative cases were diffusely positive for synaptophysin (Fig 1C). Staining for synaptophysin was found in 9 *de novo* and 7 post-treatment cases. No significant differences for chromogranin and synaptophysin expression were found between NEPCa subgroups, either pure versus mixed (p=0.15 and 0.29, respectively) or *de novo* versus post-treatment (p=0.64 and 0.70, respectively). TTF1 was expressed in half cases (Fig 1D), in 8 on 10 pure NEPCa and in 7 on 20 admixed cases (near significance, p=0.05). No significant difference in TTF1 staining was found in *de novo* versus post-treatment NEPCa (p=0.51).

Thirteen cases on 30 co-expressed chromogranin A (Fig 1E) and AR (Fig 1F). AR, NKX3.1 (Fig 1G), and ERG (Fig 1H) were expressed in respectively 53%, 43%, and 13% of tumors (Fig 1 D, E, F). All ERG positive cases also stained NKX3.1, and all NKX3.1 positive cases also expressed AR. NKX3.1 staining was more frequent in the NE component of tumors admixed with conventional adenocarcinoma (12 positive cases on 20) compared to pure NEPCa (1 positive case on 10) ($p=0.01$). No differences for AR and NKX3.1 expression were observed between *de novo* and post-treatment cases ($p=0.53$ and $.064$, respectively).

Among markers of aggressiveness, the expression profile of Ki67 and Zeb1 was very heterogeneous, and PTEN expression was totally or partially lost in half of NEPCa cases.

No significant differences were found for Ki67, Zeb1 and PTEN expression between NEPCa subgroups, either pure versus mixed ($p=0.07$, 0.88 , and 0.21 , respectively) or *de novo* versus post-treatment ($p=0.06$, 0.55 , and 0.91 , respectively).

Correlation between markers

No significant association was found between both chromogranin A and synaptophysin staining and androgen-regulated markers. In contrast, TTF1 expression was closely associated with loss of both AR ($p=0.0004$) and NKX3.1 ($p=0.0001$). Only 3 cases on 30 were negative for TTF1 and NKX3.1, and 1 other case was positive for both markers.

AR and NKX3.1 expression were associated with decreased proliferation ($p=0.0006$ and 0.0004 , respectively), and absence of PTEN loss ($p=0.04$ and 0.02 , respectively).

Although we found no significant association between both chromogranin A and synaptophysin staining and markers of aggressiveness, TTF1 expression (Fig 2A) was associated with increased proliferation (Fig 2B) ($p=0.001$), Zeb1 staining (Fig 2C) ($p=0.04$), and PTEN loss (Fig 2D) (0.02).

Prognostic value

The expressions of NKX3.1, TTF1, Ki67 and Zeb1 were significantly associated with shorter overall survival (log rank, $p=0.007$, 0.0003 , 0.006 and 0.008 , respectively) (Fig 3), while chromogranin A and synaptophysin staining were not (log rank, $p=0.8$ and 0.7 , respectively). Patients with visceral metastases at diagnosis did not have a significant shorter overall

survival compared to other patients ($p=0.07$). Patients treated with platinum chemotherapy did not have a significant longer overall survival ($p=0.12$).

In addition, cases with an admixed component of conventional adenocarcinoma showed a longer overall survival compared to pure NEPCa cases ($p=0.003$). No significant difference was observed in term of survival between *de novo* and post-treatment NEPCa ($p=0.9$).

In multivariate analysis, including parameters significant in univariate analysis, only TTF1 staining remained significant (Table 2).

DISCUSSION

NE cells are rare components of normal prostatic glands, scattered within the epithelium, and are defined in current practice by immunohistochemical positivity for either chromogranin A, synaptophysin, or CD56 (1). Foci of NE cells, indistinguishable from other cancer cells by routine HES staining, can also be found using immunohistochemistry in typical prostate adenocarcinoma. The presence of such a focal neuroendocrine differentiation (NED) in hormone naive PCa has not been shown to worsen disease prognosis [1]. In contrast, small cell neuroendocrine prostate cancer (NEPCa) is a highly aggressive disease, that rarely arises *de novo*, and most often emerges from prostate adenocarcinoma after androgen deprivation or androgen receptor (AR) targeted therapy [2]. The diagnosis of NEPCa, either in its pure form or admixed with an adenocarcinoma component, must be suspected on morphological criteria (small cell morphology) and only then confirmed by immunohistochemistry using NE markers, mainly chromogranin A and synaptophysin. In the present study, we selected cases with drastic NEPCa criteria, either pure or with a majority NE component. Furthermore, since our objective was to identify both immunoprofile and prognostic markers, we selected NEPCa cases with sufficient amount of cancer tissue available, and extensive clinical data including at least 6 months follow-up after tissue collection.

Considering the markers of NE differentiation, we observed that 94% of post-treatment cases expressed chromogranin A and only 44% synaptophysin, suggesting that chromogranin is a better marker of NED in treatment induced NEPCa. In contrast, both markers were found to be equally expressed in *de novo* cases. Other studies, composed mainly of *de novo* NEPCa cases, have reported a more frequent positivity for synaptophysin than for chromogranin A [3, 4, 9]. Taken together, these findings suggest that the NE profile is different when NEPCa is treatment related. As previously described [4], we observed that half of NEPCa cases express TTF1. TTF1 staining has been shown to be positive in 7 to 80% of extra-pulmonary NE carcinomas, demonstrating that this marker cannot be used to determine the origin of NE cancer [10]. Alterations of tumor suppressors, including PTEN, have been shown to be key genetic events underlying NEPCa, with frequent combined loss of PTEN, TP53, and RB1 [11, 12]. Similarly, we found that half of our NEPCa cases displayed a partial or total loss of PTEN expression.

Despite the acquisition of a NE phenotype, we observed that more than half of cases still expressed AR (53%) and most of them the androgen regulated transcription factor NKX3.1 (43%). Previous studies have reported either a similar high expression of AR [13], or lower levels for both AR and NKX3.1 [3, 5]. We also observed that the expression of AR and NKX3.1 is more frequent in the NE component of cases admixed with conventional adenocarcinoma when compared to pure NEPCa. As previously reported [5], we found that a minority of NEPC cases were stained for ERG, which is an androgen regulated factor in the presence of the fusion gene *TMPRSS2-ERG* [7]. The persistence of androgen regulated markers in a number of NEPCa cases strongly suggest the interest in these patients to maintain androgen targeted therapy, despite the acquisition of a NE phenotype.

After analysis of the correlations between markers, we found a strong inverse association between TTF1 expression and loss of androgen regulated markers. In fact, all TTF1 positive NEPC, except 1 case, showed a complete loss of NKX3.1 expression. TTF1 could then be considered as a marker of complete NE transdifferentiation in PCa. Moreover, we observed that complete transdifferentiation, ie loss of AR/NKX3.1, is associated with markers of aggressiveness such as increased proliferation and loss of PTEN expression. Similarly, TTF1 staining is associated with increased proliferation, loss of PTEN, and also with increased expression of the EMT transcription factor Zeb1. The inverse association between androgen regulated markers and TTF1 expression could be explained by the implication of the POU-domain transcription factor BRN2, a master regulator of neuronal differentiation [14]. In PCa, BRN2 is induced by AR suppression, and is a driver of NE differentiation [14]. In addition, BRN2 has been directly involved in TTF1 expression in NE lung cancer [15].

Although it is now well established that NED in PCa induces poor outcome, few studies have evaluated the prognostic factors among NEPCa. Recent retrospective studies without pathological review reported decreased survival in patients with pure NEPCa compared to patients with mixed cancer [16, 17]. Moreover, in these patients, low serum PSA level, that reflects low expression of androgen regulated markers, has been show to predict poorer outcome [16]. Accordingly, we observed that pure NEPCa and loss of NKX3.1 were significantly associated with decreased survival. However, unlike others [17], we do not find any survival advantage for patients previously treated by hormonal therapies. In univariate analysis, we also identified other prognostic factors, such as high proliferation, zeb1 expression, and TTF1 staining. However, in multivariate analysis, only TTF1 expression

remained significantly associated with shorter survival. Therefore TTF1, whose mRNA could be measured in serum samples [18], could be used as a predictive biomarker, particularly in patients under androgen deprivation or androgen receptor (AR) targeted therapy.

In conclusion, the persistence of AR expression in half of NEPCa cases strongly suggest the interest of AR targeted therapy in these patients. Compared to cases admixed with adenocarcinoma, pure NEPCa showed decreased AR signalling and increased TTF1 staining, whose expression is a marker of poor prognosis.

REFERENCES

- [1] Epstein JI, Amin MB, Beltran H, Lotan TL, Mosquera JM, Reuter VE, et al. Proposed morphologic classification of prostate cancer with neuroendocrine differentiation. *Am J Surg Pathol*. 2014;38(6):756-767.
- [2] Priemer DS, Montironi R, Wang L, Williamson SR, Lopez-Beltran A, Cheng L. Neuroendocrine Tumors of the Prostate: Emerging Insights from Molecular Data and Updates to the 2016 World Health Organization Classification. *Endocr Pathol*. 2016;27(2):123-135.
- [3] Yao JL, Madeb R, Bourne P, Lei J, Yang X, Tickoo S, et al. Small cell carcinoma of the prostate: an immunohistochemical study. *Am J Surg Pathol* 2006; 30: 705-712.
- [4] Wang W, Epstein JI. Small cell carcinoma of the prostate. *Am J Surg Pathol* 2008; 32: 65-71.
- [5] Lotan TL, Gupta NS, Wang W, Toubaji A, Haffner MC, Chaux A, et al. ERG rearrangements are common in prostatic small cell carcinomas. *Modern Pathology* 2011; 24: 820-828.
- [6] Beltran H, Rickman DS, Park K, Chae SS, Sboner A, MacDonald T, et al. Molecular characterization of neuroendocrine prostate cancer and identification of new drug targets. *Cancer Discovery* 2011; 487-494.
- [7] Tomlins SA, Rhodes DR, Perner S, Dhanasekaran SM, Mehra R, Sun XW, et al. Recurrent fusion of TMPRSS2 and ETS transcription factor genes in prostate cancer. *Science* 2005; 310: 644-648.
- [8] Terry S, Beltran H. The many faces of neuroendocrine differentiation in prostate cancer. *Frontiers in oncology* 2014; 4; 1-9.
- [9] Chedgy ECP, Vandekerkhove G, Herberts C, Annala M, Donoghue AJ, Sirougos M, et al. Biallelic tumour suppressor loss and DNA repair defects in *de novo* small cell prostate carcinoma. *J Pathol* 2018; 246: 244-253.

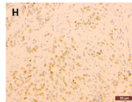
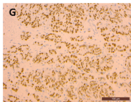
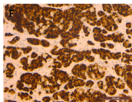
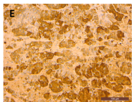
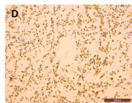
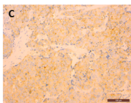
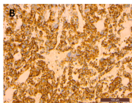
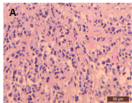
- [10] Quinn AM, Blackhall F, Wilson G, Danson S, Clamp A, Ashcroft L, et al. Extrapulmonary small cell carcinoma: a clinicopathological study with identification of potential diagnostic mimics. *Histopathology* 2012; 61: 454-464.
- [11] Aparicio AM, Shen L, Tapia ELN, Lu JF, Chen HC, Zhang J, et al. Combined tumor suppressor defects characterized clinically defined aggressive variant prostate cancers. *Clin Cancer Res* 2016; 22: 1520-1530.
- [12] Tan HL, Sood A, Rahimi AA, Wang W, Gupta N, Hisks J, et al. Rb loss is characteristic of prostatic small cell neuroendocrine carcinoma. *Clin Cancer Res* 2014; 20: 890-903.
- [13] Arggawal R, Huang J, Alumkal JJ, Zhang L, Feng FY, Thomas GV, et al. Clinical and genomic characterization of treatment emergent small cell neuroendocrine prostate cancer: a multi-institutional prospective study. *JCO* 2018; 36: 2492-25.3.
- [14] Bishop JL, Thaper D, Vahid S, Davies A, Ketola K, Kuruma H, et al. The master neural transcription factor BRN2 is an androgen receptor-suppressed driver of neuroendocrine differentiation in prostate cancer. *Cancer Discovery* 2017; 7: 54-71.
- [15] Sakaeda M, Sato H, Ishii J, Miyata C, Kamma H, Shishido-Hara Y, et al. Neural lineage-specific homeoprotein BRN2 is directly involved in TTF1 expression in small lung cancer. *Lab Invest* 2013; 93: 408-421.
- [16] Wang J, Xu W, Mierxiati A, Huang Y, Wei Y, Lin G, et al. low serum PSA level predicts poor outcome in patients with primary neuroendocrine prostate cancer. *The Prostate* 2019; 1-9.
- [17] Conteduta V, Oromendia C, Eng KW, Bareja R, Sigouros M, Molina A, et al. Clinical features of neuroendocrine prostate cancer. *Eur J Cancer* 2019; 121: 7-18.
- [18] Liu Y, Zhang G, Li H, Han L, Fu L, Zhang N, et al. Serum microRNA 365 in combinaison with its target gene TTF1 as non invasive prognostic marker for non-small cell lung cancer. *Biomedecine and Pharmacotherapy* 2015; 75: 185-190.

6. FIGURE LEGENDS

Figure 1: HES staining of NEPCa with small cell morphology (A). Twenty five cases on 30 NEPCa were positive for chromogranin A (B), 16 cases for synaptophysin (C), and TTF1 expression was found in 15 tumors (D). The majority of NEPCa cases co-expressed chromogranin A (E) and AR (F), whereas 13 tumors on 30 were positive for NKX3.1 (G), and only 4 cases were positive for ERG (H).

Figure 2: TTF1 expression in NEPCa (A) was associated with high proliferation (B), positive Zeb1 staining (C), and loss of PTEN expression in cancer cells (D).

Figure 3: Kaplan-Meier overall survival in NEPCa patients, according to NKX3.1 (A, $p=0.007$), TTF1 (B, $p=0.0003$), Ki67 (C, $p=0.006$), and Zeb1 (D, $p=0.008$) staining.



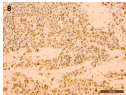




TABLE 1: Expression of markers of NE differentiation, androgen signalling, and aggressiveness

Chromogranin A	- (n)	5
	+ (n)	25
Synaptophysin	- (n)	14
	+ (n)	16
TTF1	- (n)	15
	+ (n)	15
AR	- (n)	14
	+ (n) <i>% (median, range)</i>	16 95 (20-100)
NKX3.1	- (n)	17
	+ (n)	13
ERG	- (n)	26
	+ (n)	4
Ki67	<i>% (median, range)</i>	50 (10-100)
Zeb1	<i>% (median, range)</i>	50 (0-100)
PTEN <i>(24 cases available)</i>	- (n)	7
	+/- (n)	5
	+ (n)	12

TABLE 2 : Markers predictive of overall survival in NEPCa in multivariate analysis (Cox)

	HR	95% CI	p
mixed NEPCa vs pure	0.325	0.076-1.401	0.13
NKX3.1 negative	0.088	0.006-1.362	0.08
TTF1 negative	0.013	0.001-0.613	0.01
Ki67	1.014	0.988-1.042	0.29
Zeb1	0.999	0.975-1.023	0.92