



**HAL**  
open science

## European Association of Urology Guidelines on Upper Urinary Tract Urothelial Carcinoma: 2020 Update

Morgan Rouprêt, Marko Babjuk, Maximilian Burger, Otakar Capoun, Daniel Cohen, Eva M. Compérat, Nigel C. Cowan, Jose L. Dominguez-Escrig, Paolo Gontero, A. Hugh Mostafid, et al.

► **To cite this version:**

Morgan Rouprêt, Marko Babjuk, Maximilian Burger, Otakar Capoun, Daniel Cohen, et al.. European Association of Urology Guidelines on Upper Urinary Tract Urothelial Carcinoma: 2020 Update. European Urology, 2021, 79, pp.62 - 79. 10.1016/j.eururo.2020.05.042 . hal-03493512

**HAL Id: hal-03493512**

**<https://hal.science/hal-03493512v1>**

Submitted on 16 Dec 2022

**HAL** is a multi-disciplinary open access archive for the deposit and dissemination of scientific research documents, whether they are published or not. The documents may come from teaching and research institutions in France or abroad, or from public or private research centers.

L'archive ouverte pluridisciplinaire **HAL**, est destinée au dépôt et à la diffusion de documents scientifiques de niveau recherche, publiés ou non, émanant des établissements d'enseignement et de recherche français ou étrangers, des laboratoires publics ou privés.



Distributed under a Creative Commons Attribution - NonCommercial 4.0 International License

## European Association of Urology Guidelines on Upper Urinary Tract Urothelial Carcinoma: 2020 Update

Morgan Rouprêt <sup>a,\*</sup>, Marko Babjuk <sup>b,c</sup>, Maximilian Burger <sup>d</sup>, Otakar Capoun <sup>e</sup>, Daniel Cohen <sup>f</sup>, Eva M. Compérat <sup>g</sup>, Nigel C. Cowan <sup>h</sup>, Jose L. Dominguez-Escrig <sup>i</sup>, Paolo Gontero <sup>j</sup>, A. Hugh Mostafid <sup>k</sup>, Joan Palou <sup>l</sup>, Benoit Peyronnet <sup>m</sup>, Thomas Seisen <sup>a</sup>, Viktor Soukup <sup>e</sup>, Richard J. Sylvester <sup>n</sup>, Bas W.G. van Rhijn <sup>d,o</sup>, Richard Zigeuner <sup>p</sup>, Shahrokh F. Shariat <sup>b,q,r,s</sup>

<sup>a</sup> Urology, GRC n°5, Predictive ONCO-URO, Pitié-Salpêtrière Hospital, AP-HP, Sorbonne University, Paris, France

<sup>b</sup> Department of Urology, Hospital Motol, Second Faculty of Medicine, Charles University, Prague, Czech Republic

<sup>c</sup> Department of Urology, Medical University of Vienna, Vienna, Austria

<sup>d</sup> Department of Urology, Caritas-St. Josef Medical Center, University of Regensburg, Regensburg, Germany

<sup>e</sup> Urology, General Teaching Hospital and 1st Faculty of Medicine, Charles University Praha, Prague, Czech Republic

<sup>f</sup> Urology, Royal Free London-NHS Foundation Trust, Royal Free Hospital, London, UK

<sup>g</sup> Department of Pathology, Sorbonne University, Assistance Publique-Hôpitaux de Paris, Hopital Tenon, Paris, France

<sup>h</sup> Department of Radiology, The Queen Alexandra Hospital, Portsmouth, UK

<sup>i</sup> Urology, Fundació Instituto Valenciano de Oncología (I.V.O.), Valencia, Spain

<sup>j</sup> Division of Urology, Molinette Hospital, University of Torino School of Medicine, Torino, Italy

<sup>k</sup> Royal Surrey Hospital, Guildford, UK

<sup>l</sup> Department of Urology, Fundacio Puigvert, Universidad Autonoma de Barcelona, Barcelona, Spain

<sup>m</sup> Department of urology, university of Rennes, Rennes, France

<sup>n</sup> EAU Guidelines Office, Arnhem, The Netherlands

<sup>o</sup> Department of Surgical Oncology (Urology), Netherlands Cancer Institute, Antoni van Leeuwenhoek Hospital, Amsterdam, The Netherlands

<sup>p</sup> Department of Urology, Medical University of Graz, Graz, Austria

<sup>q</sup> Department of Urology Comprehensive Cancer Centre, Medical University of Vienna, Vienna, Austria

<sup>r</sup> Department of Urology, Weill Cornell Medical College, New York, NY, USA

<sup>s</sup> Department of Urology, University of Texas Southwestern, Dallas, TX, USA

<sup>t</sup> Institute for Urology and Reproductive Health, I.M. Sechenov First Moscow State Medical University, Moscow, Russia

\* Corresponding author. Urology, GRC n°5, Predictive ONCO-URO, Pitié-Salpêtrière Hospital, AP-HP, Sorbonne University, Paris F-75013, France. Tel. +33 144 495 336; Fax: +33 142 177 354.

E-mail address: [morgan.roupret@aphp.fr](mailto:morgan.roupret@aphp.fr) (M. Rouprêt).

**Keywords:** Urothelial carcinoma; Upper tract; Neoplasm; Risk factors; Ureter; Renal pelvis; Diagnosis; Cytology; Ureteroscopy; Management; Nephroureterectomy; Chemotherapy; Systemic treatment; Follow-up; Survival; Guidelines

## **Abstract**

**Context:** The European Association of Urology (EAU) Guidelines Panel on Upper Urinary Tract Urothelial Carcinoma (UTUC) has prepared updated guidelines to aid clinicians in the current evidence-based management of UTUC and to incorporate recommendations into clinical practice.

**Objective:** To provide an overview of the EAU guidelines on UTUC as an aid to clinicians.

**Evidence acquisition:** The recommendations provided in the current guidelines are based on a thorough review of available UTUC guidelines and articles identified following a systematic search of Medline. Data on urothelial malignancies and UTUC were searched using the following keywords: urinary tract cancer, urothelial carcinomas, upper urinary tract carcinoma, renal pelvis, ureter, bladder cancer, chemotherapy, ureteroscopy, nephroureterectomy, neoplasm, adjuvant treatment, instillation, recurrence, risk factors, and survival. References were weighted by a panel of experts.

**Evidence synthesis:** Owing to the rarity of UTUC, there are insufficient data to provide strong recommendations. The 2017 tumour, node, metastasis (TNM) classification is recommended. Recommendations are given for diagnosis and risk stratification as well as for radical and conservative treatment, and prognostic factors are discussed. A single postoperative dose of intravesical mitomycin after nephroureterectomy reduces the risk of bladder tumour recurrence. Kidney-sparing management should be offered as a primary treatment option to patients with low-risk tumour and two functional kidneys. After radical nephroureterectomy, cisplatin-based chemotherapy is indicated in locally advanced UTUC.

**Conclusions:** These guidelines contain information on the management of individual patients according to a current standardised approach. Urologists should take into account the specific clinical characteristics of each patient when determining the optimal treatment regimen, based on the proposed risk stratification of these tumours.

**Patient summary:** Urothelial carcinoma of the upper urinary tract is rare, but because 60% of these tumours are invasive at diagnosis, an appropriate diagnosis is most important. A number of known risk factors exist.

## **1. Introduction**

The previous European Association of Urology (EAU) Guidelines on Upper Urinary Tract Urothelial Carcinoma (UTUC) were published in 2017 [1]. The EAU Guidelines Panel has prepared updated guidelines to provide evidence-based information on the management of these tumours in clinical practice.

## **2. Methodology**

### ***2.1. Data identification***

Databases searched included PubMed, Ovid, EMBASE, and both the Cochrane Central Register of Controlled Trials and the Cochrane Database of Systematic Reviews. A detailed search history is available in the Supplementary material. The publications identified were mainly retrospective, including some large multicentre studies. Owing to the scarcity of randomised data, articles were selected based on the following criteria: evolution of concepts, intermediate- and long-term clinical outcomes, study quality, and relevance. Older studies were included only if they were historically relevant. To facilitate evaluation of the quality of information provided, levels of evidence (LEs) and grades of recommendation were included according to the general principles of evidence-based medicine [2].

## **3. Epidemiology, aetiology, and pathology**

### ***3.1. Epidemiology***

Urothelial carcinomas (UCs) are the fourth most common tumours [3]. They can be located in the lower (bladder and urethra) or the upper (pyelocaliceal cavities and ureter) urinary tract. Bladder tumours account for 90–95% of UCs and are the most common urinary tract malignancy [4]. However, UTUCs are uncommon and account for only 5–10% of UCs [3], with an estimated annual incidence in Western countries of almost two cases per 100 000 inhabitants. Pyelocaliceal tumours are approximately twice as common as ureteral tumours. In 17% of cases, concurrent bladder cancer is present [5]. Recurrence in the bladder occurs in 22–47% of UTUC patients [6], compared with 2–6% in the contralateral upper tract [7].

Overall, two-thirds of UTUCs are invasive at diagnosis compared with 15–25% of bladder tumours [8]. UTUCs have a peak incidence in individuals aged 70–90 yr and are three times more common in men [9]. Following radical cystectomy for muscle-invasive bladder cancer, 3–5% of patients develop a metachronous UTUC.

Familial/hereditary UTUCs are linked to hereditary nonpolyposis colorectal carcinoma [10], and these patients can be screened during an interview (Fig. 1) [11]. The Amsterdam criteria are a set of diagnostic criteria used by doctors to help identify families that are likely to have Lynch syndrome [12]. In Lynch-related UTUC, immunohistochemistry analysis showed loss of protein expression corresponding to the disease-predisposing mismatch repair (*MMR*) gene mutation in 98% of the samples (46% were microsatellite instable and 54% microsatellite stable) [11]. The majority of tumours develop in *MSH2* mutation carriers [11]. Patients identified to be at high risk for Lynch syndrome should undergo DNA sequencing for patient and family counselling [11].

### **3.2. Risk factors**

A number of environmental factors have been implicated in the development of UTUC [13,14]. Published evidence in support of a causative role for these factors is not strong, with the exception of smoking and aristolochic acid. Tobacco exposure increases the relative risk from 2.5 to 7 [14]. Historically, UTUC “amino tumours” were related to occupational exposure to carcinogenic aromatic amines including benzidine and  $\beta$ -naphthalene, both of which have been banned since the 1960s in most industrialised countries.

The average duration of exposure needed to develop UTUC is  $\sim 7$  yr, with a latency period of  $\sim 20$  yr following termination of exposure. In Taiwan, the presence of arsenic in drinking water has been tentatively linked to UTUC, which represents 20–25% of UCs in the region [15].

Aristolochic acid, a nitrophenanthrene carboxylic acid produced by *Aristolochia* plants, exerts multiple effects on the urinary system. Several studies have demonstrated the carcinogenic potential of aristolochic acid contained in *Aristolochia fangchi* and *Aristolochia clematis*. The aristolochic acid derivative d-aristolactam causes a specific mutation in the *p53* gene at codon 139 that occurs mainly in patients with nephropathy due to Chinese herbs or Balkan endemic nephropathy who present with UTUC [16]. Although the incidence of Balkan endemic nephropathy is also on the decline, roles have been proposed for aristolochic acid and the consumption of Chinese herbs in the pathophysiology and induction of this nephropathy, respectively.

Differences in the ability to counteract carcinogens may contribute to host susceptibility to UTUC. Some genetic polymorphisms are associated with an increased risk of cancer or faster disease progression that introduces variability in the interindividual susceptibility to the risk factors mentioned previously. UTUC

may share some risk factors or molecular disruption pathways with bladder UC. So far, two UTUC-specific polymorphisms have been reported [17].

### **3.3. Histology and classification**

#### **3.3.1. Histological types**

Upper urinary tract UC with pure nonurothelial histology is rare [18,19], but variants are present in approximately 25% of cases [20,21]. Pure squamous cell carcinoma of the urinary tract is often assumed to be associated with chronic inflammatory diseases and infections arising from urolithiasis [22–25]. UC with divergent squamous differentiation is present in approximately 15% of cases [23]. Upper urinary tract UCs with variant histology are often high grade and have a worse prognosis compared with pure UC [21,26,27]. Collecting duct carcinoma can have similar characteristics to UTUC due to its common embryological origin [28]. Recommendations are listed in Table 1.

## **4. Staging and classification systems**

### **4.1. Classification**

The classification and morphology of UTUC and bladder carcinoma are similar [29]. It is possible to distinguish between noninvasive papillary tumours (papillary urothelial tumours of low malignant potential and low- and high-grade papillary UC) [30], flat lesions (carcinoma in situ [CIS]), and invasive carcinoma.

### **4.2. Tumour, node, metastasis staging**

The tumour, node, metastasis (TNM) classification is shown in Table 2 [31]. The regional lymph nodes (LNs) are the hilar and retroperitoneal nodes, and for the mid and distal ureter, the pelvic nodes.

### **4.3. Tumour grade**

In 2004, the World Health Organization (WHO) published a new histological classification of UCs, which provides a different patient stratification between individual categories compared with the older 1973 WHO classification [32]. In 2016, an update of the 2004 WHO grading classification was published without major changes [33]. These guidelines are still based on both the 1973 and the 2004/2016 WHO classifications since most published data use the 1973 classification [30].

## **5. Diagnosis**

### **5.1. Symptoms**

The diagnosis of UTUC may be incidental or symptom related. The most common symptom is visible or nonvisible haematuria (70–80%) [34,35]. Flank pain occurs in approximately 20% of cases [36,37]. Systemic symptoms (including anorexia, weight loss, malaise, fatigue, fever, night sweats, or cough) associated with UTUC should prompt evaluation for metastases associated with a worse prognosis [36,37].

### **5.2. Diagnosis**

#### **5.2.1. Imaging**

##### **5.2.1.1. Computed tomography urography**

Computed tomography (CT) urography has the highest diagnostic accuracy of the available imaging techniques [38]. A meta-analysis of 13 studies comprising 1233 patients revealed a pooled sensitivity of CT urography for UTUC of 92% (confidence interval [CI]: 88–98) and a pooled specificity of 95% [39]. Rapid acquisition of thin sections allows high-resolution isotropic images that can be viewed in multiple planes to assist with diagnosis without loss of resolution. Epithelial “flat lesions” without mass effect or urothelial thickening are generally not visible with CT. The presence of enlarged LNs is highly predictive of metastases in UTUC [40].

##### **5.2.1.2. Computed tomography**

Prior to any treatment with curative intent, it is essential to rule out distant metastases. CT of the chest, abdomen, and pelvis is the diagnostic technique of choice for staging [39].

##### **5.2.1.3. Magnetic resonance urography**

Magnetic resonance (MR) urography is indicated in patients who cannot undergo CT urography, usually when radiation or iodinated contrast media are contraindicated [41]. The sensitivity of MR urography is 75% after contrast injection for tumours <2 cm [41]. MR urography with gadolinium-based contrast media should be used with caution in patients with severe renal impairment (<30 ml/min creatinine clearance), due to the risk of nephrogenic systemic fibrosis. CT urography is generally preferred to MR urography for the diagnosis and staging of UTUC.

### *5.2.2. Cystoscopy and urinary cytology*

Urethroscopy is an integral part of UTUC diagnosis to rule out concomitant bladder cancer [5,42]. Abnormal cytology may indicate high-grade UTUC when bladder cystoscopy is normal, and in the absence of CIS in the bladder and prostatic urethra [29,43,44]. Cytology is less sensitive for UTUC than for bladder tumours and should be performed selectively for the affected upper tract [45]. Retrograde ureteropyelography remains an option to detect UTUCs [38,46,47]. Urinary cytology of the renal cavities and ureteral lumina is preferred before the application of a contrast agent for retrograde ureteropyelography because it may cause deterioration of cytological specimens [47,48]. In a recent study, barbotage cytology detected up to 91% of cancers, being as effective as biopsy histology [49]. The sensitivity of fluorescence in situ hybridisation for molecular abnormalities characteristic of UTUCs is approximately 50%, and therefore its use in clinical practice remains unproven [50–52].

### *5.2.3. Diagnostic ureteroscopy*

Flexible ureteroscopy (URS) is used to visualise the ureter, renal pelvis, and collecting system, and for biopsy of suspicious lesions. Presence, appearance, and size of tumour can be determined using URS. In addition, ureteroscopic biopsies can determine tumour grade in 90% of cases with a low false-negative rate, regardless of sample size [53]. Undergrading may occur following diagnostic biopsy, making intensive follow-up necessary if kidney-sparing treatment is chosen [54]. URS also facilitates selective ureteral sampling for cytology in situ [47,55,56]. Stage assessment using ureteroscopic biopsy is inaccurate. Combination of ureteroscopic biopsy grade, imaging findings such as hydronephrosis, and urinary cytology may help in the decision-making process between radical nephroureterectomy (RNU) and kidney-sparing therapy [56,57]. While some studies suggest a higher rate of intravesical recurrence after RNU in patients who underwent diagnostic URS preoperatively [58,59], one study did not [60]. Technical developments in flexible ureteroscopes and the use of novel imaging techniques improve visualisation and diagnosis of flat lesions [61]. Narrow-band imaging is a promising technique, but results are preliminary [57,62,63]. Optical coherence tomography and confocal laser endomicroscopy (Cellvizio) have been used in vivo to evaluate tumour grade and/or for staging purposes, with a promising correlation with definitive histology in high-grade UTUC [64,65]. Recommendations are listed in Table 3.

## **6. Prognosis**

### **6.1. Prognostic factors**



UTUCs that invade the muscle wall usually have a very poor prognosis. The 5-yr-specific survival is <50% for pT2/pT3 and <10% for pT4 UTUC [66–69]. The main prognostic factors are briefly listed in the text. Figure 2 shows a more exhaustive list of those patients with the most increased risk.

### *6.1.1. Preoperative factors*

#### 6.1.1.1. Age and gender

Older age at the time of RNU is independently associated with decreased cancer-specific survival (CSS) [67,70,71] (LE: 3). However, even elderly patients can be cured with RNU [72]. Therefore, chronological age alone should not be a contraindication to RNU [71,72]. Gender has no impact on the prognosis of UTUC [9,67,73].

#### 6.1.1.2. Ethnicity

One multicentre study of academic centres did not show any difference in outcomes between races [74], but US population-based studies have indicated that African-American patients have worse outcomes than other ethnicities (LE: 3). Whether this is related to access to care or biological and/or patterns of care remains unknown. Another study has demonstrated differences between Chinese and American patients at presentation (risk factor, disease characteristics, and predictors of adverse oncological outcomes) [75].

#### 6.1.1.3. Tobacco consumption

Being a smoker at diagnosis increases the risk for disease recurrence and mortality after RNU [76,77] and recurrence within the bladder [78] (LE: 3). There is a close relationship between tobacco consumption and prognosis; smoking cessation improves cancer control.

#### 6.1.1.4. Tumour location, multifocality, size, and hydronephrosis

Initial location of the UTUC is a prognostic factor in some studies [79,80] (LE: 3). After adjustment for the effect of tumour stage, patients with ureteral and/or multifocal tumours seem to have a worse prognosis than patients diagnosed with renal pelvic tumours [67,79–84]. Hydronephrosis is associated with advanced disease and poor oncological outcome [36,40,48].

#### 6.1.1.5. Surgical delay

A delay between diagnosis of an invasive tumour and its removal may increase the risk of disease progression. Once a decision regarding RNU has been made, the procedure should be carried out within 12 wk, when possible [85–89] (LE: 3).

#### 6.1.1.6. Other

A higher American Society of Anesthesiologists score confers worse CSS after RNU [90] (LE: 3), as does poor performance status [91]. Obesity and higher body mass index adversely affect cancer-specific outcomes in patients treated with RNU [92] (LE: 3). High pretreatment-derived neutrophil-lymphocyte ratio [93,94] and low albumin [95] have been associated with worse cancer-specific mortality.

### 6.1.2. Postoperative factors

#### 6.1.2.1. Tumour stage and grade

The primary recognised prognostic factors are tumour stage and grade [8,56,67,96,97].

#### 6.1.2.2. LN involvement

LN metastasis and extranodal extension are powerful predictors of survival outcomes in UTUC [98,99]. Lymph node dissection (LND) performed at the time of RNU allows for optimal tumour staging, although its curative role remains controversial [69,99–101] (LE: 3).

#### 6.1.2.3. Lymphovascular invasion

Lymphovascular invasion is present in approximately 20% of UTUCs and is an independent predictor of survival [102–104]. Lymphovascular invasion status should be reported specifically in the pathological reports of all UTUC specimens [102,105,106] (LE: 3).

#### 6.1.2.4. Surgical margins

A positive soft tissue surgical margin is associated with a higher disease recurrence after RNU. Pathologists should look for and report positive margins at the level of ureteral transection and bladder cuff, and around the tumour [107] (LE: 3).

#### 6.1.2.5. Other pathological factors

Extensive tumour necrosis (>10% of the tumour area) is an independent prognostic predictor in patients who undergo RNU [108,109] (LE: 3). The architecture of UTUC is also a strong prognosticator with sessile growth pattern being associated with worse outcome [110,111] (LE: 3). Concomitant CIS in organ-

confined UTUC and a history of bladder CIS are associated with a higher risk of recurrence and cancer-specific mortality [112,113] (LE: 3). Macroscopic infiltration or invasion of peripelvic adipose tissue confers a higher risk of disease recurrence after RNU compared with microscopic infiltration of renal parenchyma [20,114].

### **6.2. Molecular markers**

Several studies have investigated the prognostic impact of molecular markers related to cell adhesion (E-cadherin [115] and CD24), microsatellite instability [116], cell differentiation [117,118], angiogenesis, cell proliferation (Ki-67), epithelial-mesenchymal transition, and mitosis), apoptosis, vascular invasion, programmed death (ligand) 1 (PD-1/PDL-1) expression [119], and c-MET protein [67,120]. Owing to the rarity of UTUC, the main limitations of molecular studies are their retrospective design and, for most studies, small sample size. None of the markers have yet fulfilled the criteria necessary to support their introduction in daily clinical decision making.

### **6.3. Predictive tools**

There are three pre-RNU models aiming at predicting which patient has muscle-invasive/non-organ-confined disease [121–123]. Five prognostic nomograms based on pathological characteristics are available [69,124–128].

### **6.4. Bladder recurrence**

A meta-analysis of available data has identified significant predictors of bladder recurrence after RNU [129] (LE: 3). Three categories of predictors of increased risk for bladder recurrence were identified:

1. Patient-specific factors such as male gender, previous bladder cancer, smoking, and preoperative chronic kidney disease
2. Tumour-specific factors such as positive preoperative urinary cytology, ureteral location, multifocality, invasive pT stage, and necrosis
3. Treatment-specific factors such as laparoscopic approach, extravesical bladder cuff removal, and positive surgical margins. In addition, the use of diagnostic URS has been associated with a higher risk of developing bladder recurrence after RNU [129] (LE: 3)

Recommendations are listed in Table 4.

### **6.5. Risk stratification**

It is useful to “risk stratify” UTUC between low- and high-risk tumours to identify those patients who are more likely to benefit from kidney-sparing treatment (Fig. 3) [130,131].

## **7. Disease management**

### **7.1. Localised nonmetastatic disease**

#### *7.1.1. Kidney-sparing surgery*

Kidney-sparing surgery for low-risk UTUC reduces the morbidity associated with radical surgery (eg, loss of kidney function), without compromising oncological outcomes [132]. In low-risk cancers, it is the preferred approach as survival is similar to that after RNU [132]. This option should therefore be discussed in all low-risk cases, irrespective of the status of the contralateral kidney. In addition, it can also be considered in select patients with a serious renal insufficiency or having a solitary kidney (LE: 3).

##### 7.1.1.1. Ureteroscopy

Endoscopic ablation should be considered in patients with clinically low-risk cancer [133,134]. A flexible ureteroscope is necessary in the management of pelvicalyceal tumours [135]. The patient should be informed of the need and be willing to comply with an early second-look URS [136] and stringent surveillance; complete tumour resection or destruction is necessary [136]. Nevertheless, a risk of disease progression remains with endoscopic management due to the suboptimal performance of imaging and biopsy for risk stratification and tumour biology [137].

##### 7.1.1.2. Percutaneous access

Percutaneous management can be considered for low-risk UTUC in the renal pelvis [134,138] (LE: 3). This may also be offered for low-risk tumours in the lower caliceal system that are inaccessible or difficult to manage by flexible URS. However, this approach is being used less due to the availability of improved endoscopic tools such as distal-tip deflection of recent ureteroscopes [134,138]. Moreover, a risk of tumour seeding remains with a percutaneous access.

##### 7.1.1.3. Ureteral resection

Segmental ureteral resection with wide margins provides adequate pathological specimens for staging and grading while preserving the ipsilateral kidney. Lymphadenectomy can also be performed during segmental ureteral resection [132]. Segmental resection of the proximal two-thirds of ureter is associated with higher failure rates than for the distal ureter [139,140] (LE: 3). Distal ureterectomy with ureteroneocystostomy are indicated for low-risk tumours in the distal ureter that cannot be removed

completely endoscopically and for high-risk tumours when kidney-sparing surgery for renal function preservation is desired [68,139,140] (LE: 3). A total ureterectomy with an ileal-ureteral substitution is technically feasible, but only in selected cases when a renal-sparing procedure is mandatory and the tumour is of low risk [141]. Recommendations are listed in Table 5.

#### 7.1.1.4. Upper urinary tract instillation of topical agents

Antegrade instillation of BCG or mitomycin C in the upper urinary tract via percutaneous nephrostomy after complete tumour eradication has been studied for CIS after kidney-sparing management [113,142] (LE: 3). Retrograde instillation through a single-J open-ended ureteric stent is also used. Both the antegrade and the retrograde approach can be dangerous due to possible ureteric obstruction and consecutive pyelovenous influx during instillation/perfusion. The reflux obtained from a double-J stent has been used, but this approach is suboptimal because the drug often does not reach the renal pelvis [143–146]. A recently published systematic review and meta-analysis, assessing the oncological outcomes of patients with papillary UTUC or CIS of the upper tract treated with kidney-sparing surgery and adjuvant endocavitary treatment, analysed the effect of adjuvant therapies (ie, chemotherapeutic agents and/or immunotherapy with BCG) after kidney-sparing surgery for papillary noninvasive (Ta-T1) UTUCs and of adjuvant BCG for the treatment of urinary tract CIS, finding no difference between the method of drug administration (antegrade vs retrograde vs combined approach) in terms of recurrence, progression, CSS, and overall survival (OS) [147].

### 7.1.2. Management of high-risk nonmetastatic UTUC

#### 7.1.2.1. Surgical approach

##### 7.1.2.1.1. Open RNU

Open RNU with bladder cuff excision is the standard treatment of high-risk UTUC, regardless of tumour location [8] (LE: 3). RNU must be performed according to oncological principles preventing tumour seeding [8]. Section 7.1.6 lists the recommendations for RNU.

##### 7.1.2.1.2. Minimally invasive RNU

Retroperitoneal metastatic dissemination and metastasis along the trocar pathway following manipulation of large tumours in a pneumoperitoneal environment have been reported in few cases [148,149]. Several precautions may lower the risk of tumour spillage:

1. Avoid entering the urinary tract.

2. Avoid direct contact between instruments and the tumour.
3. Perform the procedure in a closed system. Avoid morcellation of the tumour and use an Endobag for tumour extraction.
4. The kidney and ureter must be removed en bloc with the bladder cuff.
5. Invasive or large (T3/T4 and/or N+/M+) tumours are contraindications for minimally invasive RNU as the outcome is worse than that of an open approach [150,151].

Laparoscopic RNU is safe in experienced hands when adhering to strict oncological principles. There is a tendency towards equivalent oncological outcomes after laparoscopic or open RNU [149,152–155] (LE: 3). One prospective randomised study has shown that laparoscopic RNU is inferior to open RNU for non-organ-confined UTUC [151] (LE: 2). Oncological outcomes after RNU have not changed significantly over the past 3 decades despite staging and surgical refinements [156] (LE: 3). A robot-assisted laparoscopic approach can be considered with recent data suggesting oncological equivalence with the other approaches [157–159].

#### 7.1.2.1.3. Management of bladder cuff

Resection of the distal ureter and its orifice is performed because there is a considerable risk of tumour recurrence in this area and in the bladder [129,139,160–162]. Several techniques have been considered to simplify distal ureter resection, including the pluck technique, stripping, transurethral resection of the intramural ureter, and intussusception. None of these techniques has convincingly been shown to be equal to complete bladder cuff excision [7,160,161] (LE: 3).

#### 7.1.2.1.4. LN dissection

The use of an LND template is likely to have a greater impact on patient survival than the number of removed LNs [163]. Template-based and completeness of LND improves CSS in patients with muscle-invasive disease and reduces the risk of local recurrence [164]. Even in clinically [165] and pathologically [166] node-negative patients, LND improves survival. The risk of LN metastasis increases with advancing tumour stage [100]. LND appears to be unnecessary in cases of TaT1 UTUC because of the low risk of LN metastasis [167–170]; however, tumour staging is inaccurate preoperatively; therefore, a template-based LND should be offered to all patients who are planned for RNU. The templates for LND have been described [164,171,172].

#### 7.1.3. Perioperative chemotherapy

#### 7.1.3.1. Neoadjuvant chemotherapy

Several retrospective studies evaluating the role of neoadjuvant chemotherapy have shown promising pathological downstaging and complete response rates [173–177]. In addition, neoadjuvant chemotherapy has been shown to result in lower disease recurrence and mortality rates than RNU alone [178–180]. No randomised controlled trials (RCTs) have yet been published.

#### 7.1.3.2. Adjuvant chemotherapy

Conflicting results are available from retrospective studies evaluating adjuvant chemotherapy [181–183]. A population-based study has shown improved OS rates in pT3/T4 and/or pN+ patients ( $n = 3253$ ) [184], while a multicentre cohort study did not show any improvement in pT2–T4 and/or pN+ patients ( $n = 1544$ ) [182]. The main limitation of using adjuvant chemotherapy for advanced UTUC remains the limited ability to deliver full-dose cisplatin-based regimen after RNU, given that this surgical procedure is likely to impact renal function [185,186].

A phase III prospective randomised trial ( $n = 261$ ) on the benefit of gemcitabine-platinum combination chemotherapy initiated within 90 d after RNU has reported a significant improvement in disease-free survival in patients with locally advanced UTUC [187] (LE: 1).

#### 7.1.4. Adjuvant radiotherapy after RNU

Adjuvant radiation therapy has been suggested to control locoregional disease after surgical removal. The data remain controversial and insufficient for conclusions [188–191]. Moreover, its additive value to chemotherapy remains questionable [190].

#### 7.1.5. Postoperative bladder instillation

The rate of bladder recurrence after RNU for UTUC is 22–47% [131,161]. Two prospective randomised trials [192,193] and a meta-analysis [194] have demonstrated that a single postoperative dose of intravesical chemotherapy (mitomycin C and pirarubicin) 2–10 d after surgery reduces the risk of bladder tumour recurrence within the initial years after RNU (LE: 2). Prior to instillation, a cystogram might be considered in case of any concerns about extravasation. Whilst there is no direct evidence supporting the use of intravesical instillation of chemotherapy after kidney-sparing surgery, single-dose chemotherapy might be effective in that setting as well (LE: 4). Management is outlined in Figures 4 and 5. Recommendations are listed in Table 6.

## **7.2. Metastatic disease**

### *7.2.1. Radical nephroureterectomy*

The role of RNU in the treatment of patients with metastatic UTUC has recently been explored in several observational studies [195–198]. It is noteworthy that these benefits may be limited to those with only one metastatic site [197]. Nonetheless, given the high risk of bias of the observational studies addressing RNU for metastatic UTUC, indications for RNU in this setting should mainly be reserved for palliative patients, aimed at controlling symptomatic disease [76,199] (LE: 3). In patients who have a partial or complete response to induction chemotherapy, RNU may be discussed with the patient.

### *7.2.2. Metastasectomy*

There is no UTUC-specific study supporting the role of metastasectomy in patients with advanced disease. In the absence of data from RCTs, patients should be evaluated on an individual basis, and the decision to perform a metastasectomy (surgically or otherwise) should be taken in a shared decision-making process with the patient.

### *7.2.3. Systemic chemotherapy*

#### *7.2.3.1. First-line setting*

Extrapolating from the bladder cancer literature and small single-centre UTUC studies, platinum-based combination chemotherapy—especially using cisplatin—might be efficacious for first-line treatment of metastatic UTUC. A retrospective analysis of three RCTs showed that primary tumour location in the lower or upper urinary tract had no impact on progression-free survival or OS in patients with locally advanced or metastatic UC treated with platinum-based combination chemotherapy [200].

In addition, the role of immunotherapy has been evaluated in the first-line setting for cisplatin-ineligible UTUC patients, but limited data on pembrolizumab and atezolizumab are available in the literature [201,202].

#### *7.2.3.2. Second-line setting*

Similar to the bladder cancer setting, second-line treatment of metastatic UTUC remains challenging. In a post hoc subgroup analysis of locally advanced or metastatic UC, vinflunine was reported to be as effective in UTUC as in bladder cancer progressing after cisplatin-based chemotherapy [203]. More importantly, a phase III RCT including 542 patients who received prior platinum-based chemotherapy for advanced UC showed that pembrolizumab could decrease the risk of death by almost 50% in those with



UTUC ( $n = 75$ , 13.8%), although these results were borderline significant [204]. Immunotherapy combinations may be effective in the second-line setting, but data are currently limited [205–208]. Recommendations are listed in Table 7.

## **8. Follow-up**

The risk of recurrence and death evolves during the follow-up period after surgery [209]. Stringent follow-up (section 8.1) is mandatory to detect metachronous bladder tumours (probability increases over time [210]), local recurrence, and distant metastases. Surveillance regimens are based on cystoscopy and urinary cytology for >5 yr [5–7,131]. Bladder recurrence is not considered a distant recurrence. When kidney-sparing surgery is performed, the ipsilateral upper urinary tract requires careful follow-up due to the high risk of disease recurrence [135,211,212]. Despite endourological improvements, follow-up after kidney-sparing management is difficult and frequent, and repeated endoscopic procedures are necessary. Recommendations are listed in Table 8.

**Author contributions:** Morgan Rouprêt had full access to all the data in the study and takes responsibility for the integrity of the data and the accuracy of the data analysis.

*Study concept and design:* Rouprêt.

*Acquisition of data:* Rouprêt, Babjuk, Compérat, Zigeuner, Shariat.

*Analysis and interpretation of data:* Rouprêt, Babjuk, Burger, Capoun, Cohen, Compérat, Cowan, Dominguez-Escrig, Gontero, Mostafid, Palou, Peyronnet, Seisen, Soukup, Sylvester, van Rhijn, Zigeuner, Shariat.

*Drafting of the manuscript:* Rouprêt.

*Critical revision of the manuscript for important intellectual content:* Rouprêt, Babjuk, Burger, Capoun, Cohen, Compérat, Cowan, Dominguez-Escrig, Gontero, Mostafid, Palou, Peyronnet, Seisen, Soukup, Sylvester, van Rhijn, Zigeuner, Shariat.

*Statistical analysis:* None.

*Obtaining funding:* None.

*Administrative, technical, or material support:* None.

*Supervision:* Rouprêt, Shariat.

*Other:* None.

**Financial disclosures:** Morgan Rouprêt certifies that all conflicts of interest, including specific financial interests and relationships and affiliations relevant to the subject matter or materials discussed in the manuscript (eg, employment/affiliation, grants or funding, consultancies, honoraria, stock ownership or options, expert testimony, royalties, or patents filed, received, or pending), are the following: Morgan Rouprêt received company speaker honorarium from Roche, Zambon, Ipsen Pharma, Janssen, and Astellas; receives research support from GSK, Pfizer, and Roche; received consultancy fees from Lilly, GSK, Ipsen, Astellas, Takeda, Sanofi Pasteur, and Medac; received company speaker honorarium from Roche and Zambon; and participates in studies by Pfizer and Roche. Marko Babjuk is a company consultant for Astellas; received company speaker honoraria or consultancy fees from Ipsen Pharma s.r.o., Janssen, Olympus, and Astellas; holds an advisory board position for Ferring; and participates in trials run by Hamlet Pharma, Ferring, and Sotio. Max Burger is a company consultant for Medac GmbH and receives speaker honorarium from Medac GmbH. Otakar Capoun received consultation fees from Janssen; received company speaker honorarium from Janssen, Ipsen, Astellas, and Bayer; received fellowship/travel grants from Janssen, Ipsen, and Astellas; and participates in trials by Janssen, Aragon Pharmaceuticals, and Bayer s.r.o. Jose L. Dominguez-Escrig participates in trials by COMBAT BRS, BTS, Presurgy, Ipsen, STORZ, Arguer, and Angiodynamics. Paolo Gontero received grants from Ipsen and advisory board fees from Arkuer, Cepheid, and Ferring. A. Hugh Mostafid is a company consultant for Ferring and Bristol Meyers Squibb; received speaker honorarium from Olympus and Medac; and participates in trails by MSD, AstraZeneca PLC, Merck, and Cepheid UK Ltd. Joan Palou receives honoraria or consultation fees from Combat BRS, Olympus, Sanofi Pasteur, and Cepheid, and participates in trials by Ipsen, COMBAT BRS, Presurgy, STORZ, and Archer. Richard Sylvester receives consultation fees from Arquer Diagnostics Ltd. and Mediolanum Farmaceutici; is a company consultant for Mediolanum Farmaceutici, Medac GmbH, and Arquer Diagnostics Ltd.; and receives research support from Erring International Center SA. Bas van Rhijn is a company consultant for AstraZeneca. Richard Zigeuner receives company speaker honoraria from Pfizer, Ipsen, and Bristol-Myers Squibb GesmbH, and receives fellowships and travel grants from Pfizer, Astellas, Takeda, and Esai. Shahrokh Shariat receives company speaker honorarium from Astellas, AstraZeneca, Bayer, BMS, Cepheid, Ferring, Ipsen, Janssen, and Lilly; is a company consultant for Olympus and Jansen; participates in a company-sponsored speaker's bureau for BMS, MSD, Roche, Ipsen, and Olympus; participates in trials by Roche, MSD, and BMS; and owns the following patents: Method to determine prognosis after therapy for prostate cancer (granted 2002-09-06), Methods to determine prognosis after therapy for bladder cancer (granted 2003-06-19), Prognostic methods for patients with prostatic disease (granted 2004-08-05), and Soluble Fas urinary marker for the detection of bladder transitional cell carcinoma (granted 2010-07-20). Daniel Cohen, Eva M. Compérat, Nigel C. Cowan, Benoit Peyronnet, Thomas Seisen, and Viktor Soukup have nothing to disclose.

**Funding/Support and role of the sponsor:** None.

## References

- [1] Roupret M, Babjuk M, Comperat E, et al. European Association of Urology guidelines on upper urinary tract urothelial carcinoma: 2017 update. *Eur Urol* 2018;73:111–22.
- [2] Madigan Library at Penn College. Produced by Bob Phillips, Chris Ball, Dave Sackett, Doug Badenoch, Sharon Straus, Brian Haynes, Martin Dawes since November 1998. Updated by Jeremy Howick March 2009. Oxford Centre for evidence-based medicine: levels of evidence. May 2009. <http://www.cebmnet/index.aspx?o=1025>
- [3] Siegel RL, Miller KD, Jemal A. Cancer statistics, 2019. *CA Cancer J Clin* 2019;69:7–34.
- [4] Babjuk M, Burger M, Zigeuner R, et al. EAU guidelines on non-muscle-invasive urothelial carcinoma of the bladder: update 2013. *Eur Urol* 2013;64:639–53.
- [5] Cosentino M, Palou J, Gaya JM, Breda A, Rodriguez-Faba O, Villavicencio-Mavrich H. Upper urinary tract urothelial cell carcinoma: location as a predictive factor for concomitant bladder carcinoma. *World J Urol* 2013;31:141–5.
- [6] Xylinas E, Rink M, Margulis V, Karakiewicz P, Novara G, Shariat SF. Multifocal carcinoma in situ of the upper tract is associated with high risk of bladder cancer recurrence. *Eur Urol* 2012;61:1069–70.
- [7] Li WM, Shen J, Li CC, et al. Oncologic outcomes following three different approaches to the distal ureter and bladder cuff in nephroureterectomy for primary upper urinary tract urothelial carcinoma. *Eur Urol* 2010;57:963–9.
- [8] Margulis V, Shariat SF, Matin SF, et al. Outcomes of radical nephroureterectomy: a series from the Upper Tract Urothelial Carcinoma Collaboration. *Cancer* 2009;115:1224–33.
- [9] Shariat SF, Favaretto RL, Gupta A, et al. Gender differences in radical nephroureterectomy for upper tract urothelial carcinoma. *World J Urol* 2011;29:481–6.
- [10] Roupret M, Yates DR, Comperat E, Cussenot O. Upper urinary tract urothelial cell carcinomas and other urological malignancies involved in the hereditary nonpolyposis colorectal cancer (Lynch syndrome) tumor spectrum. *Eur Urol* 2008;54:1226–36.
- [11] Audenet F, Colin P, Yates DR, et al. A proportion of hereditary upper urinary tract urothelial carcinomas are misclassified as sporadic according to a multi-institutional database analysis: proposal of patient-specific risk identification tool. *BJU Int* 2012;110:E583–9.
- [12] Umar A, Boland CR, Terdiman JP, et al. Revised Bethesda guidelines for hereditary nonpolyposis colorectal cancer (Lynch syndrome) and microsatellite instability. *J Natl Cancer Inst* 2004;96:261–8.
- [13] Green DA, Rink M, Xylinas E, et al. Urothelial carcinoma of the bladder and the upper tract: disparate twins. *J Urol* 2013;189:1214–21.
- [14] Colin P, Koenig P, Ouzzane A, et al. Environmental factors involved in carcinogenesis of urothelial cell carcinomas of the upper urinary tract. *BJU Int* 2009;104:1436–40.
- [15] Chen C-H, Pu Y-S. Arsenics and urothelial carcinoma. In: Chen C-J, Chiou H-Y, editors. *Health hazards of environmental arsenic poisoning: from epidemic to pandemic*. Taipei, Taiwan: World Scientific; 2011.
- [16] Jelakovic B, Karanovic S, Vukovic-Lela I, et al. Aristolactam-DNA adducts are a biomarker of environmental exposure to aristolochic acid. *Kidney Int* 2012;81:559–67.
- [17] Roupret M, Drouin SJ, Cancel-Tassin G, Comperat E, Larre S, Cussenot O. Genetic variability in 8q24 confers susceptibility to urothelial carcinoma of the upper urinary tract and is linked with patterns of disease aggressiveness at diagnosis. *J Urol* 2012;187:424–8.
- [18] Sakano S, Matsuyama H, Kamiryo Y, et al. Impact of variant histology on disease aggressiveness and outcome after nephroureterectomy in Japanese patients with upper tract urothelial carcinoma. *Int J Clin Oncol* 2015;20:362–8.
- [19] Ouzzane A, Ghoneim TP, Udo K, et al. Small cell carcinoma of the upper urinary tract (UUT-SCC): report of a rare entity and systematic review of the literature. *Cancer Treat Rev* 2011;37:366–72.

- [20] Rink M, Robinson BD, Green DA, et al. Impact of histological variants on clinical outcomes of patients with upper urinary tract urothelial carcinoma. *J Urol* 2012;188:398–404.
- [21] Mori K, Janisch F, Parizi MK, et al. Prognostic value of variant histology in upper tract urothelial carcinoma treated with nephroureterectomy: a systematic review and meta-analysis. *J Urol* 2020;203:1075–84.
- [22] Olgac S, Mazumdar M, Dalbagni G, Reuter VE. Urothelial carcinoma of the renal pelvis: a clinicopathologic study of 130 cases. *Am J Surg Pathol* 2004;28:1545–52.
- [23] Perez-Montiel D, Wakely PE, Hes O, Michal M, Suster S. High-grade urothelial carcinoma of the renal pelvis: clinicopathologic study of 108 cases with emphasis on unusual morphologic variants. *Mod Pathol* 2006;19:494–503.
- [24] Desai FS, Nongthombam J, Singh LS. Retrospective evaluation of risk factors and immunohistochemical findings for pre-neoplastic and neoplastic lesions of upper urinary tract in patients with chronic nephrolithiasis. *Asian Pac J Cancer Prev* 2015;16:8293–8.
- [25] Medina Perez M, Valpuesta Fernandez I, Valero Puerta J. [Pyelocaliceal urothelial carcinoma associated with pelvis lithiasis]. *Arch Esp Urol* 1998;51:380–2.
- [26] Zamboni S, Foerster B, Abufaraj M, et al. Incidence and survival outcomes in patients with upper urinary tract urothelial carcinoma diagnosed with variant histology and treated with nephroureterectomy. *BJU Int* 2019;124:738–45.
- [27] Kim JK, Moon KC, Jeong CW, Kwak C, Kim HH, Ku JH. Variant histology as a significant predictor of survival after radical nephroureterectomy in patients with upper urinary tract urothelial carcinoma. *Urol Oncol* 2017;35:458 e9–15.
- [28] Roupret M, Babjuk M, Comperat E, et al. European Association of Urology guidelines on upper urinary tract urothelial cell carcinoma: 2015 update. *Eur Urol* 2015;68:868–79.
- [29] Babjuk M, Burger M, Compérat E, Gontero P. EAU guidelines on non-muscle-invasive bladder cancer (T1, T1 and CIS). EAU guidelines, Presented at the 35th EAU Annual Congress Amsterdam. EAU Guidelines Office; 2020.
- [30] Soukup V, Capoun O, Cohen D, et al. Prognostic performance and reproducibility of the 1973 and 2004/2016 World Health Organization grading classification systems in non-muscle-invasive bladder cancer: a European Association of Urology Non-muscle Invasive Bladder Cancer Guidelines Panel systematic review. *Eur Urol* 2017;72:801–13.
- [31] Brierley JD, Gospodarowicz MK, Wittekind C. TNM classification of malignant tumours. ed. 8. Wiley; 2016.
- [32] Sauter G. Tumours of the urinary system: non-invasive urothelial neoplasias. In: Sauter A, Amin M, editors. WHO classification of classification of tumours of the urinary system and male genital organs. Lyon, France: IARC Press; 2004.
- [33] Moch H, Humphrey PA, Ulbright TM, Reuter VE. WHO classification of tumours of the urinary system and male genital organs. ed 4. Lyon, France: IARC Press; 2016.
- [34] Inman BA, Tran VT, Fradet Y, Lacombe L. Carcinoma of the upper urinary tract: predictors of survival and competing causes of mortality. *Cancer* 2009;115:2853–62.
- [35] Cowan NC. CT urography for hematuria. *Nat Rev Urol* 2012;9:218–26.
- [36] Ito Y, Kikuchi E, Tanaka N, et al. Preoperative hydronephrosis grade independently predicts worse pathological outcomes in patients undergoing nephroureterectomy for upper tract urothelial carcinoma. *J Urol* 2011;185:1621–6.
- [37] Raman JD, Shariat SF, Karakiewicz PI, et al. Does preoperative symptom classification impact prognosis in patients with clinically localized upper-tract urothelial carcinoma managed by radical nephroureterectomy? *Urol Oncol* 2011;29:716–23.
- [38] Cowan NC, Turney BW, Taylor NJ, McCarthy CL, Crew JP. Multidetector computed tomography urography for diagnosing upper urinary tract urothelial tumour. *BJU Int* 2007;99:1363–70.

- [39] Janisch F, Shariat SF, Baltzer P, et al. Diagnostic performance of multidetector computed tomographic (MDCTU) in upper tract urothelial carcinoma (UTUC): a systematic review and meta-analysis. *World J Urol* 2020;38:1165–75.
- [40] Verhoest G, Shariat SF, Chromecki TF, et al. Predictive factors of recurrence and survival of upper tract urothelial carcinomas. *World J Urol* 2011;29:495–501.
- [41] Takahashi N, Glockner JF, Hartman RP, et al. Gadolinium enhanced magnetic resonance urography for upper urinary tract malignancy. *J Urol* 2010;183:1330–65.
- [42] Soria F, Shariat SF, Lerner SP, et al. Epidemiology, diagnosis, preoperative evaluation and prognostic assessment of upper-tract urothelial carcinoma (UTUC). *World J Urol* 2017;35:379–87.
- [43] Witjes JA, Redorta JP, Jacqmin D, et al. Hexaminolevulinic acid-guided fluorescence cystoscopy in the diagnosis and follow-up of patients with non-muscle-invasive bladder cancer: review of the evidence and recommendations. *Eur Urol* 2010;57:607–14.
- [44] Rosenthal DL, Kurtz DF. *The Paris system for reporting urinary cytology*. Cham, Switzerland: Springer International Publishing; 2016.
- [45] Messer J, Shariat SF, Brien JC, et al. Urinary cytology has a poor performance for predicting invasive or high-grade upper-tract urothelial carcinoma. *BJU Int* 2011;108:701–5.
- [46] Wang LJ, Wong YC, Chuang CK, Huang CC, Pang ST. Diagnostic accuracy of transitional cell carcinoma on multidetector computerized tomography urography in patients with gross hematuria. *J Urol* 2009;181:524–31; discussion 531.
- [47] Lee KS, Zeikus E, DeWolf WC, Rofsky NM, Pedrosa I. MR urography versus retrograde pyelography/ureteroscopy for the exclusion of upper urinary tract malignancy. *Clin Radiol* 2010;65:185–92.
- [48] Messer JC, Terrell JD, Herman MP, et al. Multi-institutional validation of the ability of preoperative hydronephrosis to predict advanced pathologic tumor stage in upper-tract urothelial carcinoma. *Urol Oncol* 2013;31:904–8.
- [49] Malm C, Grahn A, Jaremko G, Tribukait B, Brehmer M. Diagnostic accuracy of upper tract urothelial carcinoma: how samples are collected matters. *Scand J Urol* 2017;51:137–45.
- [50] Chen AA, Grasso M. Is there a role for FISH in the management and surveillance of patients with upper tract transitional-cell carcinoma? *J Endourol* 2008;22:1371–4.
- [51] Johannes JR, Nelson E, Bibbo M, Bagley DH. Voided urine fluorescence in situ hybridization testing for upper tract urothelial carcinoma surveillance. *J Urol* 2010;184:879–82.
- [52] McHale T, Ohori NP, Cieply KM, Sherer C, Bastacky SI. Comparison of urinary cytology and fluorescence in situ hybridization in the detection of urothelial neoplasia: an analysis of discordant results. *Diagn Cytopathol* 2019;47:282–8.
- [53] Rojas CP, Castle SM, Llanos CA, et al. Low biopsy volume in ureteroscopy does not affect tumor biopsy grading in upper tract urothelial carcinoma. *Urol Oncol* 2013;31:1696–700.
- [54] Smith AK, Stephenson AJ, Lane BR, et al. Inadequacy of biopsy for diagnosis of upper tract urothelial carcinoma: implications for conservative management. *Urology*. 2011;78:82–6.
- [55] Ishikawa S, Abe T, Shinohara N, et al. Impact of diagnostic ureteroscopy on intravesical recurrence and survival in patients with urothelial carcinoma of the upper urinary tract. *J Urol* 2010;184:883–7.
- [56] Clements T, Messer JC, Terrell JD, et al. High-grade ureteroscopic biopsy is associated with advanced pathology of upper-tract urothelial carcinoma tumors at definitive surgical resection. *J Endourol* 2012;26:398–402.
- [57] Brien JC, Shariat SF, Herman MP, et al. Preoperative hydronephrosis, ureteroscopic biopsy grade and urinary cytology can improve prediction of advanced upper tract urothelial carcinoma. *J Urol* 2010;184:69–73.

- [58] Marchioni M, Primiceri G, Cindolo L, et al. Impact of diagnostic ureteroscopy on intravesical recurrence in patients undergoing radical nephroureterectomy for upper tract urothelial cancer: a systematic review and meta-analysis. *BJU Int* 2017;120:313–9.
- [59] Guo RQ, Hong P, Xiong GY, et al. Impact of ureteroscopy before radical nephroureterectomy for upper tract urothelial carcinomas on oncological outcomes: a meta-analysis. *BJU Int* 2018;121:184–93.
- [60] Lee HY, Yeh HC, Wu WJ, et al. The diagnostic ureteroscopy before radical nephroureterectomy in upper urinary tract urothelial carcinoma is not associated with higher intravesical recurrence. *World J Surg Oncol* 2018;16:135.
- [61] Bus MT, de Bruin DM, Faber DJ, et al. Optical diagnostics for upper urinary tract urothelial cancer: technology, thresholds, and clinical applications. *J Endourol* 2015;29:113–23.
- [62] Abouassaly R, Alibhai SM, Shah N, Timilshina N, Fleshner N, Finelli A. Troubling outcomes from population-level analysis of surgery for upper tract urothelial carcinoma. *Urology* 2010;76:895–901.
- [63] Kata SG, Aboumarzouk OM, Zreik A, et al. Photodynamic diagnostic ureterorenoscopy: a valuable tool in the detection of upper urinary tract tumour. *Photodiagn Photodyn Ther* 2016;13:255–60.
- [64] Breda A, Territo A, Guttilla A, et al. Correlation between confocal laser endomicroscopy (Cellvizio((R))) and histological grading of upper tract urothelial carcinoma: a step forward for a better selection of patients suitable for conservative management. *Eur Urol Focus* 2018;4:954–9.
- [65] Bus MT, de Bruin DM, Faber DJ, et al. Optical coherence tomography as a tool for in vivo staging and grading of upper urinary tract urothelial carcinoma: a study of diagnostic accuracy. *J Urol* 2016;196:1749–55.
- [66] Jeldres C, Sun M, Isbarn H, et al. A population-based assessment of perioperative mortality after nephroureterectomy for upper-tract urothelial carcinoma. *Urology* 2010;75:315–20.
- [67] Lughezzani G, Burger M, Margulis V, et al. Prognostic factors in upper urinary tract urothelial carcinomas: a comprehensive review of the current literature. *Eur Urol* 2012;62:100–14.
- [68] Lughezzani G, Jeldres C, Isbarn H, et al. Nephroureterectomy and segmental ureterectomy in the treatment of invasive upper tract urothelial carcinoma: a population-based study of 2299 patients. *Eur J Cancer* 2009;45:3291–7.
- [69] Roupret M, Hupertan V, Seisen T, et al. Prediction of cancer specific survival after radical nephroureterectomy for upper tract urothelial carcinoma: development of an optimized postoperative nomogram using decision curve analysis. *J Urol* 2013;189:1662–9.
- [70] Kim HS, Jeong CW, Kwak C, Kim HH, Ku JH. Association between demographic factors and prognosis in urothelial carcinoma of the upper urinary tract: a systematic review and meta-analysis. *Oncotarget* 2017;8:7464–76.
- [71] Shariat SF, Godoy G, Lotan Y, et al. Advanced patient age is associated with inferior cancer-specific survival after radical nephroureterectomy. *BJU Int* 2010;105:1672–7.
- [72] Chromecki TF, Ehdaie B, Novara G, et al. Chronological age is not an independent predictor of clinical outcomes after radical nephroureterectomy. *World J Urol* 2011;29:473–80.
- [73] Fernandez MI, Shariat SF, Margulis V, et al. Evidence-based sex-related outcomes after radical nephroureterectomy for upper tract urothelial carcinoma: results of large multicenter study. *Urology* 2009;73:142–6.
- [74] Matsumoto K, Novara G, Gupta A, et al. Racial differences in the outcome of patients with urothelial carcinoma of the upper urinary tract: an international study. *BJU Int* 2011;108:E304–9.
- [75] Singla N, Fang D, Su X, et al. A Multi-institutional comparison of clinicopathological characteristics and oncologic outcomes of upper tract urothelial carcinoma in China and the United States. *J Urol* 2017;197:1208–13.
- [76] Simsir A, Sarsik B, Cureklibatir I, Sen S, Gunaydin G, Cal C. Prognostic factors for upper urinary tract urothelial carcinomas: stage, grade, and smoking status. *Int Urol Nephrol* 2011;43:1039–45.

- [77] Rink M, Xylinas E, Margulis V, et al. Impact of smoking on oncologic outcomes of upper tract urothelial carcinoma after radical nephroureterectomy. *Eur Urol* 2013;63:1082–90.
- [78] Xylinas E, Kluth LA, Rieken M, et al. Impact of smoking status and cumulative exposure on intravesical recurrence of upper tract urothelial carcinoma after radical nephroureterectomy. *BJU Int* 2014;114:56–61.
- [79] Yafi FA, Novara G, Shariat SF, et al. Impact of tumour location versus multifocality in patients with upper tract urothelial carcinoma treated with nephroureterectomy and bladder cuff excision: a homogeneous series without perioperative chemotherapy. *BJU Int* 2012;110:E7–13.
- [80] Uzzane A, Colin P, Xylinas E, et al. Ureteral and multifocal tumours have worse prognosis than renal pelvic tumours in urothelial carcinoma of the upper urinary tract treated by nephroureterectomy. *Eur Urol* 2011;60:1258–65.
- [81] Chromecki TF, Cha EK, Fajkovic H, et al. The impact of tumor multifocality on outcomes in patients treated with radical nephroureterectomy. *Eur Urol* 2012;61:245–53.
- [82] Williams AK, Kassouf W, Chin J, et al. Multifocality rather than tumor location is a prognostic factor in upper tract urothelial carcinoma. *Urol Oncol* 2013;31:1161–5.
- [83] Hurel S, Roupret M, Seisen T, et al. Influence of preoperative factors on the oncologic outcome for upper urinary tract urothelial carcinoma after radical nephroureterectomy. *World J Urol* 2015;33:335–41.
- [84] Isbarn H, Jeldres C, Shariat SF, et al. Location of the primary tumor is not an independent predictor of cancer specific mortality in patients with upper urinary tract urothelial carcinoma. *J Urol* 2009;182:2177–81.
- [85] Sundi D, Svatek RS, Margulis V, et al. Upper tract urothelial carcinoma: impact of time to surgery. *Urol Oncol* 2012;30:266–72.
- [86] Gadzinski AJ, Roberts WW, Faerber GJ, Wolf JS Jr. Long-term outcomes of immediate versus delayed nephroureterectomy for upper tract urothelial carcinoma. *J Endourol* 2012;26:566–73.
- [87] Lee JN, Kwon SY, Choi GS, et al. Impact of surgical wait time on oncologic outcomes in upper urinary tract urothelial carcinoma. *J Surg Oncol* 2014;110:468–75.
- [88] Waldert M, Karakiewicz PI, Raman JD, et al. A delay in radical nephroureterectomy can lead to upstaging. *BJU Int* 2010;105:812–7.
- [89] Xia L, Taylor BL, Pulido JE, Guzzo TJ. Impact of surgical waiting time on survival in patients with upper tract urothelial carcinoma: a national cancer database study. *Urol Oncol* 2018;36:10 e5–22.
- [90] Berod AA, Colin P, Yates DR, et al. The role of American Society of Anesthesiologists scores in predicting urothelial carcinoma of the upper urinary tract outcome after radical nephroureterectomy: results from a national multi-institutional collaborative study. *BJU Int* 2012;110:E1035–40.
- [91] Carrion A, Huguet J, Garcia-Cruz E, et al. Intraoperative prognostic factors and atypical patterns of recurrence in patients with upper urinary tract urothelial carcinoma treated with laparoscopic radical nephroureterectomy. *Scand J Urol* 2016;50:305–12.
- [92] Ehdaie B, Chromecki TF, Lee RK, et al. Obesity adversely impacts disease specific outcomes in patients with upper tract urothelial carcinoma. *J Urol* 2011;186:66–72.
- [93] Dalpiaz O, Pichler M, Mannweiler S, et al. Validation of the pretreatment derived neutrophil-lymphocyte ratio as a prognostic factor in a European cohort of patients with upper tract urothelial carcinoma. *Br J Cancer* 2014;110:2531–6.
- [94] Vartolomei MD, Kimura S, Ferro M, et al. Is neutrophil-to-lymphocytes ratio a clinical relevant preoperative biomarker in upper tract urothelial carcinoma? A meta-analysis of 4385 patients. *World J Urol* 2018;36:1019–29.
- [95] Liu J, Wang F, Li S, Huang W, Jia Y, Wei C. The prognostic significance of preoperative serum albumin in urothelial carcinoma: a systematic review and meta-analysis. *Biosci Rep* 2018;38:BSR20180214.

- [96] Mbeutcha A, Roupret M, Kamat AM, et al. Prognostic factors and predictive tools for upper tract urothelial carcinoma: a systematic review. *World J Urol* 2017;35:337–53.
- [97] Petrelli F, Yasser Hussein MI, Vavassori I, Barni S. Prognostic factors of overall survival in upper urinary tract carcinoma: a systematic review and meta-analysis. *Urology* 2017;100:9–15.
- [98] Fajkovic H, Cha EK, Jeldres C, et al. Prognostic value of extranodal extension and other lymph node parameters in patients with upper tract urothelial carcinoma. *J Urol* 2012;187:845–51.
- [99] Roscigno M, Brausi M, Heidenreich A, et al. Lymphadenectomy at the time of nephroureterectomy for upper tract urothelial cancer. *Eur Urol* 2011;60:776–83.
- [100] Lughezzani G, Jeldres C, Isbarn H, et al. A critical appraisal of the value of lymph node dissection at nephroureterectomy for upper tract urothelial carcinoma. *Urology* 2010;75:118–24.
- [101] Nazzani S, Mazzone E, Preisser F, et al. Rates of lymph node invasion and their impact on cancer specific mortality in upper urinary tract urothelial carcinoma. *Eur J Surg Oncol* 2019;45:1238–45.
- [102] Kikuchi E, Margulis V, Karakiewicz PI, et al. Lymphovascular invasion predicts clinical outcomes in patients with node-negative upper tract urothelial carcinoma. *J Clin Oncol* 2009;27:612–8.
- [103] Novara G, Matsumoto K, Kassouf W, et al. Prognostic role of lymphovascular invasion in patients with urothelial carcinoma of the upper urinary tract: an international validation study. *Eur Urol* 2010;57:1064–71.
- [104] Liu W, Sun L, Guan F, Wang F, Zhang G. Prognostic value of lymphovascular invasion in upper urinary tract urothelial carcinoma after radical nephroureterectomy: a systematic review and meta-analysis. *Dis Markers* 2019;2019:7386140.
- [105] Godfrey MS, Badalato GM, Hruby GW, Razmjoo M, McKiernan JM. Prognostic indicators for upper tract urothelial carcinoma after radical nephroureterectomy: the impact of lymphovascular invasion. *BJU Int* 2012;110:798–803.
- [106] Samaratunga H, Judge M, Delahunt B, et al. Data set for the reporting of carcinoma of the renal pelvis and ureter-nephroureterectomy and ureterectomy specimens: recommendations from the International Collaboration on Cancer Reporting (ICCR). *Am J Surg Pathol* 2019;43:e1–12.
- [107] Colin P, Ouzzane A, Yates DR, et al. Influence of positive surgical margin status after radical nephroureterectomy on upper urinary tract urothelial carcinoma survival. *Ann Surg Oncol* 2012;19:3613–20.
- [108] Zigeuner R, Shariat SF, Margulis V, et al. Tumour necrosis is an indicator of aggressive biology in patients with urothelial carcinoma of the upper urinary tract. *Eur Urol* 2010;57:575–81.
- [109] Seitz C, Gupta A, Shariat SF, et al. Association of tumor necrosis with pathological features and clinical outcome in 754 patients undergoing radical nephroureterectomy for upper tract urothelial carcinoma: an international validation study. *J Urol* 2010;184:1895–900.
- [110] Remzi M, Haitel A, Margulis V, et al. Tumour architecture is an independent predictor of outcomes after nephroureterectomy: a multi-institutional analysis of 1363 patients. *BJU Int* 2009;103:307–11.
- [111] Fritsche HM, Novara G, Burger M, et al. Macroscopic sessile tumor architecture is a pathologic feature of biologically aggressive upper tract urothelial carcinoma. *Urol Oncol* 2012;30:666–72.
- [112] Wheat JC, Weizer AZ, Wolf JS Jr, et al. Concomitant carcinoma in situ is a feature of aggressive disease in patients with organ confined urothelial carcinoma following radical nephroureterectomy. *Urol Oncol* 2012;30:252–8.
- [113] Redrow GP, Guo CC, Brausi MA, et al. Upper urinary tract carcinoma in situ: current knowledge, future direction. *J Urol* 2017;197:287–95.
- [114] Roscigno M, Cha EK, Rink M, et al. International validation of the prognostic value of subclassification for AJCC stage pT3 upper tract urothelial carcinoma of the renal pelvis. *BJU Int* 2012;110:674–81.
- [115] Favaretto RL, Bahadori A, Mathieu R, et al. Prognostic role of decreased E-cadherin expression in patients with upper tract urothelial carcinoma: a multi-institutional study. *World J Urol* 2017;35:113–20.



- [116] Roupret M, Fromont G, Azzouzi AR, et al. Microsatellite instability as predictor of survival in patients with invasive upper urinary tract transitional cell carcinoma. *Urology* 2005;65:1233–7.
- [117] Soria F, Moschini M, Haitel A, et al. HER2 overexpression is associated with worse outcomes in patients with upper tract urothelial carcinoma (UTUC). *World J Urol* 2017;35:251–9.
- [118] Bensalah K, Montorsi F, Shariat SF. Challenges of cancer biomarker profiling. *Eur Urol* 2007;52:1601–9.
- [119] Krabbe LM, Heitplatz B, Preuss S, et al. Prognostic value of PD-1 and PD-L1 expression in patients with high grade upper tract urothelial carcinoma. *J Urol* 2017;198:1253–62.
- [120] Scarpini S, Roupret M, Renard-Penna R, Camparo P, Cussenot O, Comperat E. Impact of the expression of Aurora-A, p53, and MIB-1 on the prognosis of urothelial carcinomas of the upper urinary tract. *Urol Oncol* 2012;30:182–7.
- [121] Margulis V, Youssef RF, Karakiewicz PI, et al. Preoperative multivariable prognostic model for prediction of nonorgan confined urothelial carcinoma of the upper urinary tract. *J Urol* 2010;184:453–8.
- [122] Favaretto RL, Shariat SF, Savage C, et al. Combining imaging and ureteroscopy variables in a preoperative multivariable model for prediction of muscle-invasive and non-organ confined disease in patients with upper tract urothelial carcinoma. *BJU Int* 2012;109:77–82.
- [123] Petros FG, Qiao W, Singla N, et al. Preoperative multiplex nomogram for prediction of high-risk nonorgan-confined upper-tract urothelial carcinoma. *Urol Oncol* 2019;37:292 e1–9.
- [124] Cha EK, Shariat SF, Kormaksson M, et al. Predicting clinical outcomes after radical nephroureterectomy for upper tract urothelial carcinoma. *Eur Urol* 2012;61:818–25.
- [125] Yates DR, Hupertan V, Colin P, et al. Cancer-specific survival after radical nephroureterectomy for upper urinary tract urothelial carcinoma: proposal and multi-institutional validation of a post-operative nomogram. *Br J Cancer* 2012;106:1083–8.
- [126] Seisen T, Colin P, Hupertan V, et al. Postoperative nomogram to predict cancer-specific survival after radical nephroureterectomy in patients with localised and/or locally advanced upper tract urothelial carcinoma without metastasis. *BJU Int* 2014;114:733–40.
- [127] Ku JH, Moon KC, Jung JH, Jeong SH, Kwak C, Kim HH. External validation of an online nomogram in patients undergoing radical nephroureterectomy for upper urinary tract urothelial carcinoma. *Br J Cancer* 2013;109:1130–6.
- [128] Krabbe LM, Eminaga O, Shariat SF, et al. Postoperative nomogram for relapse-free survival in patients with high grade upper tract urothelial carcinoma. *J Urol* 2017;197:580–9.
- [129] Seisen T, Granger B, Colin P, et al. A systematic review and meta-analysis of clinicopathologic factors linked to intravesical recurrence after radical nephroureterectomy to treat upper tract urothelial carcinoma. *Eur Urol* 2015;67:1122–33.
- [130] Roupret M, Colin P, Yates DR. A new proposal to risk stratify urothelial carcinomas of the upper urinary tract (UTUCs) in a predefinitive treatment setting: low-risk versus high-risk UTUCs. *Eur Urol* 2014;66:181–3.
- [131] Seisen T, Colin P, Roupret M. Risk-adapted strategy for the kidney-sparing management of upper tract tumours. *Nat Rev Urol* 2015;12:155–66.
- [132] Seisen T, Peyronnet B, Dominguez-Escrig JL, et al. Oncologic outcomes of kidney-sparing surgery versus radical nephroureterectomy for upper tract urothelial carcinoma: a systematic review by the EAU Non-muscle Invasive Bladder Cancer Guidelines Panel. *Eur Urol* 2016;70:1052–68.
- [133] Cutress ML, Stewart GD, Wells-Cole S, Phipps S, Thomas BG, Tolley DA. Long-term endoscopic management of upper tract urothelial carcinoma: 20-year single-centre experience. *BJU Int* 2012;110:1608–17.
- [134] Cutress ML, Stewart GD, Zakikhani P, Phipps S, Thomas BG, Tolley DA. Ureteroscopic and percutaneous management of upper tract urothelial carcinoma (UTUC): systematic review. *BJU Int* 2012;110:614–28.

- [135] Cornu JN, Roupret M, Carpentier X, et al. Oncologic control obtained after exclusive flexible ureteroscopic management of upper urinary tract urothelial cell carcinoma. *World J Urol* 2010;28:151–6.
- [136] Villa L, Cloutier J, Letendre J, et al. Early repeated ureteroscopy within 6-8 weeks after a primary endoscopic treatment in patients with upper tract urothelial cell carcinoma: preliminary findings. *World J Urol* 2016;34:1201–6.
- [137] Vemana G, Kim EH, Bhayani SB, Vetter JM, Strobe SA. Survival comparison between endoscopic and surgical management for patients with upper tract urothelial cancer: a matched propensity score analysis using Surveillance, Epidemiology and End Results-Medicare Data. *Urology* 2016;95:115–20.
- [138] Roupret M, Traxer O, Tligui M, et al. Upper urinary tract transitional cell carcinoma: recurrence rate after percutaneous endoscopic resection. *Eur Urol* 2007;51:709–13; discussion 714.
- [139] Jeldres C, Lughezzani G, Sun M, et al. Segmental ureterectomy can safely be performed in patients with transitional cell carcinoma of the ureter. *J Urol* 2010;183:1324–9.
- [140] Colin P, Ouzzane A, Pignot G, et al. Comparison of oncological outcomes after segmental ureterectomy or radical nephroureterectomy in urothelial carcinomas of the upper urinary tract: results from a large French multicentre study. *BJU Int* 2012;110:1134–41.
- [141] Ou YC, Hu CY, Cheng HL, Yang WH. Long-term outcomes of total ureterectomy with ileal-ureteral substitution treatment for ureteral cancer: a single-center experience. *BMC Urol* 2018;18:73.
- [142] Giannarini G, Kessler TM, Birkhauser FD, Thalmann GN, Studer UE. Antegrade perfusion with bacillus Calmette-Guerin in patients with non-muscle-invasive urothelial carcinoma of the upper urinary tract: who may benefit? *Eur Urol* 2011;60:955–60.
- [143] Irie A, Iwamura M, Kadowaki K, Ohkawa A, Uchida T, Baba S. Intravesical instillation of bacille Calmette-Guerin for carcinoma in situ of the urothelium involving the upper urinary tract using vesicoureteral reflux created by a double-pigtail catheter. *Urology* 2002;59:53–7.
- [144] Horiguchi H, Yoneyama T, Hatakeyama S, et al. Impact of bacillus Calmette-Guerin therapy of upper urinary tract carcinoma in situ: comparison of oncological outcomes with radical nephroureterectomy. *Med Oncol* 2018;35:41.
- [145] Tomisaki I, Kubo T, Minato A, Fujimoto N. Efficacy and tolerability of bacillus Calmette-Guerin therapy as the first-line therapy for upper urinary tract carcinoma in situ. *Cancer Invest* 2018;36:152–7.
- [146] Yossepowitch O, Lifshitz DA, Dekel Y, et al. Assessment of vesicoureteral reflux in patients with self-retaining ureteral stents: implications for upper urinary tract instillation. *J Urol* 2005;173:890–3.
- [147] Foerster B, D'Andrea D, Abufaraj M, et al. Endocavitary treatment for upper tract urothelial carcinoma: a meta-analysis of the current literature. *Urol Oncol* 2019;37:430–6.
- [148] Roupret M, Smyth G, Irani J, et al. Oncological risk of laparoscopic surgery in urothelial carcinomas. *World J Urol* 2009;27:81–8.
- [149] Ong AM, Bhayani SB, Pavlovich CP. Trocar site recurrence after laparoscopic nephroureterectomy. *J Urol* 2003;170:1301.
- [150] Peyronnet B, Seisen T, Dominguez-Escrig JL, et al. Oncological outcomes of laparoscopic nephroureterectomy versus open radical nephroureterectomy for upper tract urothelial carcinoma: an European Association of Urology guidelines systematic review. *Eur Urol Focus* 2019;5:205–23.
- [151] Simone G, Papalia R, Guaglianone S, et al. Laparoscopic versus open nephroureterectomy: perioperative and oncologic outcomes from a randomised prospective study. *Eur Urol* 2009;56:520–6.
- [152] Favaretto RL, Shariat SF, Chade DC, et al. Comparison between laparoscopic and open radical nephroureterectomy in a contemporary group of patients: are recurrence and disease-specific survival associated with surgical technique? *Eur Urol* 2010;58:645–51.
- [153] Walton TJ, Novara G, Matsumoto K, et al. Oncological outcomes after laparoscopic and open radical nephroureterectomy: results from an international cohort. *BJU Int* 2011;108:406–12.

- [154] Ni S, Tao W, Chen Q, et al. Laparoscopic versus open nephroureterectomy for the treatment of upper urinary tract urothelial carcinoma: a systematic review and cumulative analysis of comparative studies. *Eur Urol* 2012;61:1142–53.
- [155] Ariane MM, Colin P, Ouzzane A, et al. Assessment of oncologic control obtained after open versus laparoscopic nephroureterectomy for upper urinary tract urothelial carcinomas (UUT-UCs): results from a large French multicenter collaborative study. *Ann Surg Oncol* 2012;19:301–8.
- [156] Adibi M, Youssef R, Shariat SF, et al. Oncological outcomes after radical nephroureterectomy for upper tract urothelial carcinoma: comparison over the three decades. *Int J Urol* 2012;19:1060–6.
- [157] Clements MB, Krupski TL, Culp SH. Robotic-assisted surgery for upper tract urothelial carcinoma: a comparative survival analysis. *Ann Surg Oncol* 2018;25:2550–62.
- [158] Rodriguez JF, Packiam VT, Boysen WR, et al. Utilization and outcomes of nephroureterectomy for upper tract urothelial carcinoma by surgical approach. *J Endourol* 2017;31:661–5.
- [159] Aboumohamed AA, Krane LS, Hemal AK. Oncologic outcomes following robot-assisted laparoscopic nephroureterectomy with bladder cuff excision for upper tract urothelial carcinoma. *J Urol* 2015;194:1561–6.
- [160] Xylinas E, Rink M, Cha EK, et al. Impact of distal ureter management on oncologic outcomes following radical nephroureterectomy for upper tract urothelial carcinoma. *Eur Urol* 2014;65:210–7.
- [161] Xylinas E, Kluth L, Passoni N, et al. Prediction of intravesical recurrence after radical nephroureterectomy: development of a clinical decision-making tool. *Eur Urol* 2014;65:650–8.
- [162] Phe V, Cussenot O, Bitker MO, Roupert M. Does the surgical technique for management of the distal ureter influence the outcome after nephroureterectomy? *BJU Int* 2011;108:130–8.
- [163] Kondo T, Hashimoto Y, Kobayashi H, et al. Template-based lymphadenectomy in urothelial carcinoma of the upper urinary tract: impact on patient survival. *Int J Urol* 2010;17:848–54.
- [164] Dominguez-Escrig JL, Peyronnet B, Seisen T, et al. Potential benefit of lymph node dissection during radical nephroureterectomy for upper tract urothelial carcinoma: a systematic review by the European Association of Urology Guidelines Panel on Non-muscle-invasive Bladder Cancer. *Eur Urol Focus* 2019;5:224–41.
- [165] Dong F, Xu T, Wang X, et al. Lymph node dissection could bring survival benefits to patients diagnosed with clinically node-negative upper urinary tract urothelial cancer: a population-based, propensity score-matched study. *Int J Clin Oncol* 2019;24:296–305.
- [166] Lenis AT, Donin NM, Faiena I, et al. Role of surgical approach on lymph node dissection yield and survival in patients with upper tract urothelial carcinoma. *Urol Oncol* 2018;36:9 e1–9.
- [167] Moschini M, Foerster B, Abufaraj M, et al. Trends of lymphadenectomy in upper tract urothelial carcinoma (UTUC) patients treated with radical nephroureterectomy. *World J Urol* 2017;35:1541–7.
- [168] Zareba P, Rosenzweig B, Winer AG, Coleman JA. Association between lymph node yield and survival among patients undergoing radical nephroureterectomy for urothelial carcinoma of the upper tract. *Cancer* 2017;123:1741–50.
- [169] Xylinas E, Kluth L, Rieken M, et al. External validation of the pathological nodal staging score in upper tract urothelial carcinoma: a population-based study. *Urol Oncol* 2017;35:33 e21–6.
- [170] Xylinas E, Rink M, Margulis V, et al. Prediction of true nodal status in patients with pathological lymph node negative upper tract urothelial carcinoma at radical nephroureterectomy. *J Urol* 2013;189:468–73.
- [171] Matin SF, Sfakianos JP, Espiritu PN, Coleman JA, Spiess PE. Patterns of lymphatic metastases in upper tract urothelial carcinoma and proposed dissection templates. *J Urol* 2015;194:1567–74.
- [172] Kondo T, Hara I, Takagi T, et al. Template-based lymphadenectomy in urothelial carcinoma of the renal pelvis: a prospective study. *Int J Urol* 2014;21:453–9.

- [173] Matin SF, Margulis V, Kamat A, et al. Incidence of downstaging and complete remission after neoadjuvant chemotherapy for high-risk upper tract transitional cell carcinoma. *Cancer* 2010;116:3127–34.
- [174] Liao RS, Gupta M, Schwen ZR, et al. Comparison of pathological stage in patients treated with and without neoadjuvant chemotherapy for high risk upper tract urothelial carcinoma. *J Urol* 2018;200:68–73.
- [175] Meng X, Chao B, Vijay V, et al. High response rates to neoadjuvant chemotherapy in high-grade upper tract urothelial carcinoma. *Urology* 2019;129:146–52.
- [176] Almassi N, Gao T, Lee B, et al. Impact of neoadjuvant chemotherapy on pathologic response in patients with upper tract urothelial carcinoma undergoing extirpative surgery. *Clin Genitourin Cancer* 2018;16:e1237–42.
- [177] Martini A, Daza J, Poltiyelova E, et al. Pathological downstaging as a novel endpoint for the development of neoadjuvant chemotherapy for upper tract urothelial carcinoma. *BJU Int*. In press. <https://doi.org/10.1111/bju.14719>
- [178] Kubota Y, Hatakeyama S, Tanaka T, et al. Oncological outcomes of neoadjuvant chemotherapy in patients with locally advanced upper tract urothelial carcinoma: a multicenter study. *Oncotarget* 2017;8:101500–8.
- [179] Hosogoe S, Hatakeyama S, Kusaka A, et al. Platinum-based neoadjuvant chemotherapy improves oncological outcomes in patients with locally advanced upper tract urothelial carcinoma. *Eur Urol Focus* 2018;4:946–53.
- [180] Porten S, Siefker-Radtke AO, Xiao L, et al. Neoadjuvant chemotherapy improves survival of patients with upper tract urothelial carcinoma. *Cancer* 2014;120:1794–9.
- [181] Goldberg H, Klaassen Z, Chandrasekar T, et al. Does perioperative chemotherapy improve survival in upper tract urothelial carcinoma? A population based analysis. *Oncotarget* 2018;9:18797–810.
- [182] Necchi A, Lo Vullo S, Mariani L, et al. Adjuvant chemotherapy after radical nephroureterectomy does not improve survival in patients with upper tract urothelial carcinoma: a joint study by the European Association of Urology-Young Academic Urologists and the Upper Tract Urothelial Carcinoma Collaboration. *BJU Int* 2018;121:252–9.
- [183] Fujita K, Taneishi K, Inamoto T, et al. Adjuvant chemotherapy improves survival of patients with high-risk upper urinary tract urothelial carcinoma: a propensity score-matched analysis. *BMC Urol* 2017;17:110.
- [184] Seisen T, Krasnow RE, Bellmunt J, et al. Effectiveness of adjuvant chemotherapy after radical nephroureterectomy for locally advanced and/or positive regional lymph node upper tract urothelial carcinoma. *J Clin Oncol* 2017;35:852–60.
- [185] Kaag MG, O'Malley RL, O'Malley P, et al. Changes in renal function following nephroureterectomy may affect the use of perioperative chemotherapy. *Eur Urol* 2010;58:581–7.
- [186] Lane BR, Smith AK, Larson BT, et al. Chronic kidney disease after nephroureterectomy for upper tract urothelial carcinoma and implications for the administration of perioperative chemotherapy. *Cancer* 2010;116:2967–73.
- [187] Birtle A, Johnson M, Chester J, et al. Adjuvant chemotherapy in upper tract urothelial carcinoma (the POUT trial): a phase 3, open-label, randomised controlled trial. *Lancet (London, England)* 2020;395:1268–77.
- [188] Hahn AW, Giri S, Pathak R, Bhatt VR, Martin MG. Effect of adjuvant radiotherapy on survival in patients with locoregional urothelial malignancies of the upper urinary tract. *Anticancer Res* 2016;36:4051–5.
- [189] Huang YC, Chang YH, Chiu KH, Shindel AW, Lai CH. Adjuvant radiotherapy for locally advanced upper tract urothelial carcinoma. *Sci Rep* 2016;6:38175.

- [190] Czito B, Zietman A, Kaufman D, Skowronski U, Shipley W. Adjuvant radiotherapy with and without concurrent chemotherapy for locally advanced transitional cell carcinoma of the renal pelvis and ureter. *J Urol* 2004;172:1271–5.
- [191] Iwata T, Kimura S, Abufaraj M, et al. The role of adjuvant radiotherapy after surgery for upper and lower urinary tract urothelial carcinoma: a systematic review. *Urol Oncol* 2019;37:659–71.
- [192] O'Brien T, Ray E, Singh R, Coker B, Beard R. Prevention of bladder tumours after nephroureterectomy for primary upper urinary tract urothelial carcinoma: a prospective, multicentre, randomised clinical trial of a single postoperative intravesical dose of mitomycin C (the ODMIT-C Trial). *Eur Urol* 2011;60:703–10.
- [193] Ito A, Shintaku I, Satoh M, et al. Prospective randomized phase II trial of a single early intravesical instillation of pirarubicin (THP) in the prevention of bladder recurrence after nephroureterectomy for upper urinary tract urothelial carcinoma: the THP Monotherapy Study Group Trial. *J Clin Oncol* 2013;31:1422–7.
- [194] Fang D, Li XS, Xiong GY, Yao L, He ZS, Zhou LQ. Prophylactic intravesical chemotherapy to prevent bladder tumors after nephroureterectomy for primary upper urinary tract urothelial carcinomas: a systematic review and meta-analysis. *Urol Int* 2013;91:291–6.
- [195] Dong F, Fu H, Shi X, et al. How do organ-specific metastases affect prognosis and surgical treatment for patients with metastatic upper tract urothelial carcinoma: first evidence from population based data. *Clin Exp Metastasis* 2017;34:467–77.
- [196] Seisen T, Jindal T, Karabon P, et al. Efficacy of systemic chemotherapy plus radical nephroureterectomy for metastatic upper tract urothelial carcinoma. *Eur Urol* 2017;71:714–8.
- [197] Moschini M, Xylinas E, Zamboni S, et al. Efficacy of surgery in the primary tumor site for metastatic urothelial cancer: analysis of an international, multicenter, multidisciplinary database. *Eur Urol Oncol* 2020;3:94–101.
- [198] Nazzani S, Preisser F, Mazzone E, et al. Survival effect of nephroureterectomy in metastatic upper urinary tract urothelial carcinoma. *Clin Genitourin Cancer* 2019;17:e602–11.
- [199] Herr HW. Extravesical tumor relapse in patients with superficial bladder tumors. *J Clin Oncol* 1998;16:1099–102.
- [200] Moschini M, Shariat SF, Roupret M, et al. Impact of primary tumor location on survival from the European Organization for the Research and Treatment of Cancer Advanced Urothelial Cancer Studies. *J Urol* 2018;199:1149–57.
- [201] Balar AV, Castellano D, O'Donnell PH, et al. First-line pembrolizumab in cisplatin-ineligible patients with locally advanced and unresectable or metastatic urothelial cancer (KEYNOTE-052): a multicentre, single-arm, phase 2 study. *Lancet Oncol* 2017;18:1483–92.
- [202] Balar AV, Galsky MD, Rosenberg JE, et al. Atezolizumab as first-line treatment in cisplatin-ineligible patients with locally advanced and metastatic urothelial carcinoma: a single-arm, multicentre, phase 2 trial. *Lancet* 2017;389:67–76.
- [203] Heers H, Greeter PDE, Goebell PJ, et al. Vinflunine in the treatment of upper tract urothelial carcinoma—subgroup analysis of an observational study. *Anticancer Res* 2017;37:6437–42.
- [204] Bellmunt J, de Wit R, Vaughn DJ, et al. Pembrolizumab as second-line therapy for advanced urothelial carcinoma. *N Engl J Med* 2017;376:1015–26.
- [205] Sharma P, Retz M, Siefker-Radtke A, et al. Nivolumab in metastatic urothelial carcinoma after platinum therapy (CheckMate 275): a multicentre, single-arm, phase 2 trial. *Lancet Oncol* 2017;18:312–22.
- [206] Patel MR, Ellerton J, Infante JR, et al. Avelumab in metastatic urothelial carcinoma after platinum failure (JAVELIN solid tumor): pooled results from two expansion cohorts of an open-label, phase 1 trial. *Lancet Oncol* 2018;19:51–64.

- [207] Apolo AB, Infante JR, Balmanoukian A, et al. Avelumab, an anti-programmed death-ligand 1 antibody, in patients with refractory metastatic urothelial carcinoma: results from a multicenter, phase Ib study. *J Clin Oncol* 2017;35:2117–24.
- [208] Powles T, O'Donnell PH, Massard C, et al. Efficacy and safety of durvalumab in locally advanced or metastatic urothelial carcinoma: updated results from a phase 1/2 open-label study. *JAMA Oncol* 2017;3:e172411.
- [209] Ploussard G, Xylinas E, Lotan Y, et al. Conditional survival after radical nephroureterectomy for upper tract carcinoma. *Eur Urol* 2015;67:803–12.
- [210] Shigeta K, Kikuchi E, Hagiwara M, et al. The conditional survival with time of intravesical recurrence of upper tract urothelial carcinoma. *J Urol* 2017;198:1278–85.
- [211] Mandalapu RS, Remzi M, de Reijke TM, et al. Update of the ICUD-SIU consultation on upper tract urothelial carcinoma 2016: treatment of low-risk upper tract urothelial carcinoma. *World J Urol* 2017;35:355–65.
- [212] Bagley DH, Grasso M 3rd. Ureteroscopic laser treatment of upper urinary tract neoplasms. *World J Urol* 2010;28:143–9.

**Fig. 1 – Selection of patients with UTUC for Lynch syndrome screening during the first medical interview. UTUC = upper urinary tract urothelial cell carcinoma.**

**Fig. 2 – Upper urinary tract urothelial cell carcinoma—prognostic factors. ASA = American Society of Anesthesiologists; BMI = body mass index; ECOG PS = Eastern Cooperative Oncology Group performance status; UTUC = upper urinary tract urothelial cell carcinoma.**

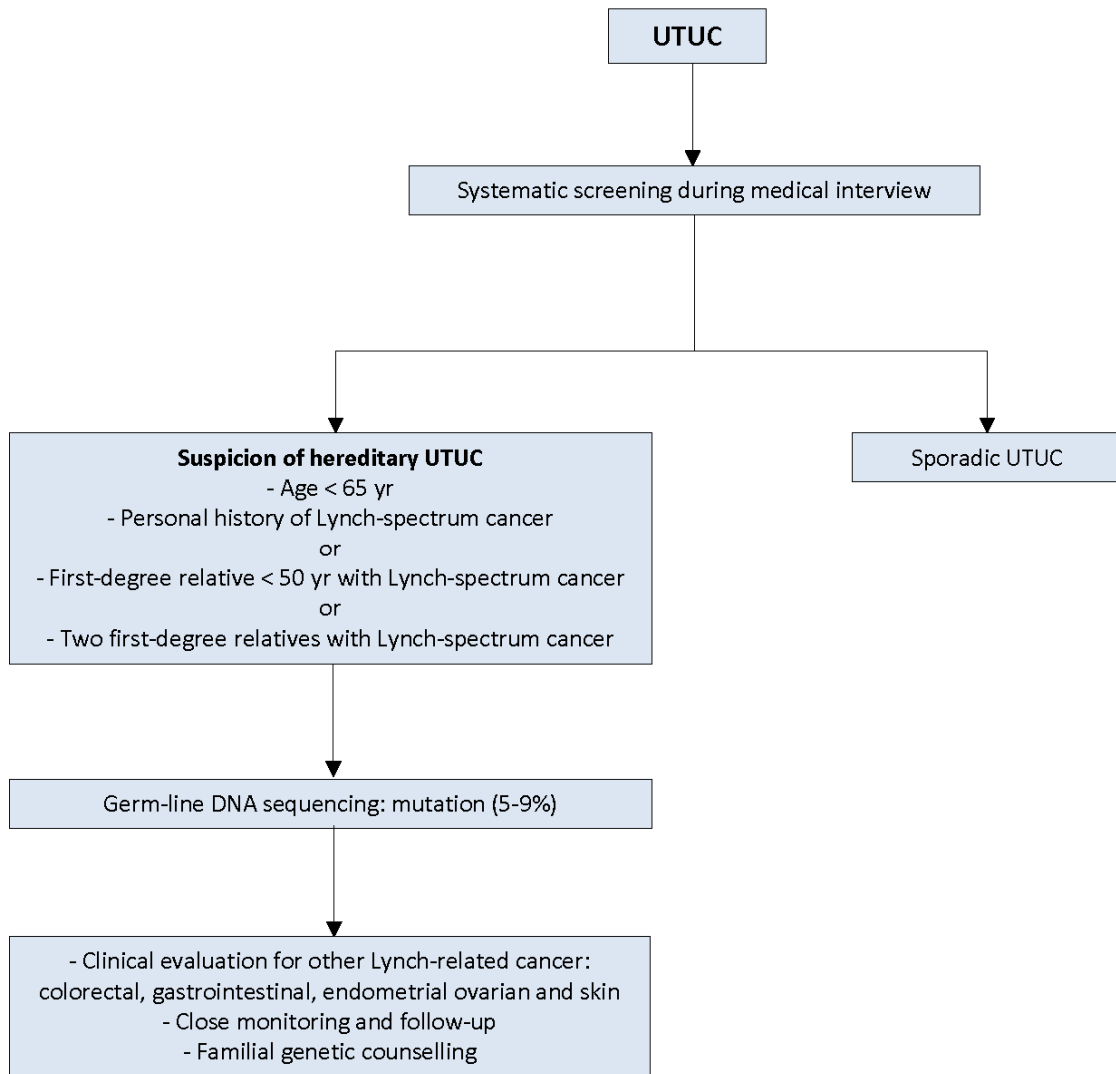
**Fig. 3 – Risk stratification of nonmetastatic UTUC. CTU = computed tomography urography; URS = ureteroscopy; UTUC = upper urinary tract urothelial cell carcinoma. <sup>a</sup> All these factors need to be present. <sup>b</sup> Any of these factors need to be present.**

**Fig. 4 – Proposed flowchart for the management of UTUC. CTU = computed tomography urography; RNU = radical nephroureterectomy; UTUC = upper urinary tract urothelial cell carcinoma. <sup>a</sup> In patients with a solitary kidney, consider a more conservative approach.**

**Fig. 5 – Surgical treatment according to location and risk status. LND = lymph node dissection; RNU = radical nephroureterectomy; URS = ureteroscopy; UTUC = upper urinary tract urothelial carcinoma. 1. First treatment option. 2. Secondary treatment option. <sup>a</sup> In case not amendable to endoscopic management.**

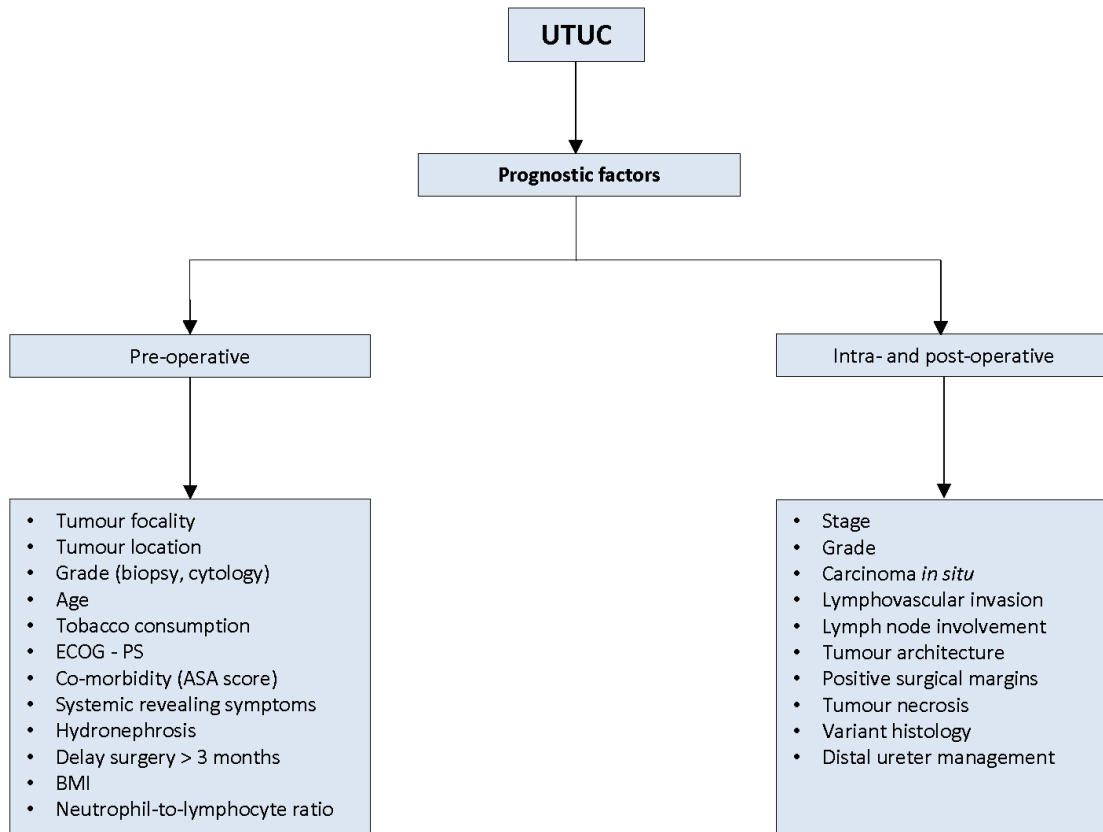
## Figures

Fig. 1: Selection of patients with UTUC for Lynch syndrome screening during the first medical interview



*DNA = deoxyribonucleic acid; UTUC = upper urinary tract urothelial cell carcinoma.*

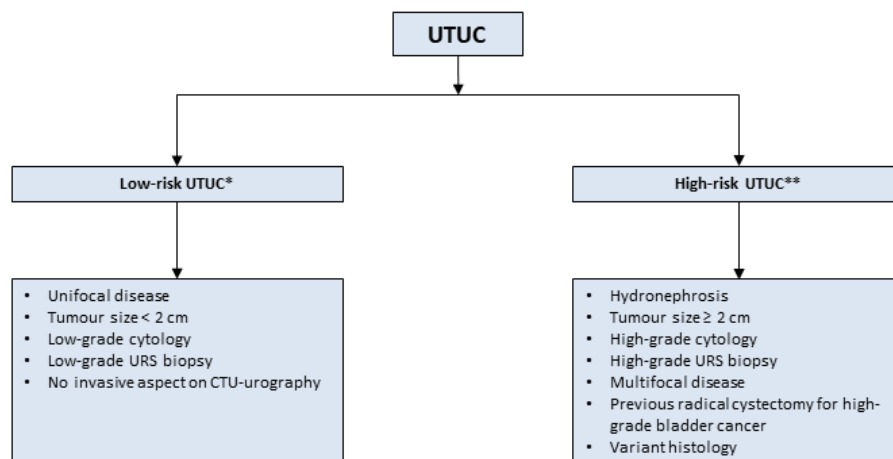
**Fig. 2: Upper urinary tract urothelial cell carcinoma - prognostic factors**



*ASA = American Society of Anesthesiologists; BMI = body mass index; ECOG PS = Eastern Cooperative Oncology Group performance status; PS = performance score; UTUC = upper urinary tract urothelial cell carcinoma.*



**Fig. 3: Risk stratification of non-metastatic UTUC**

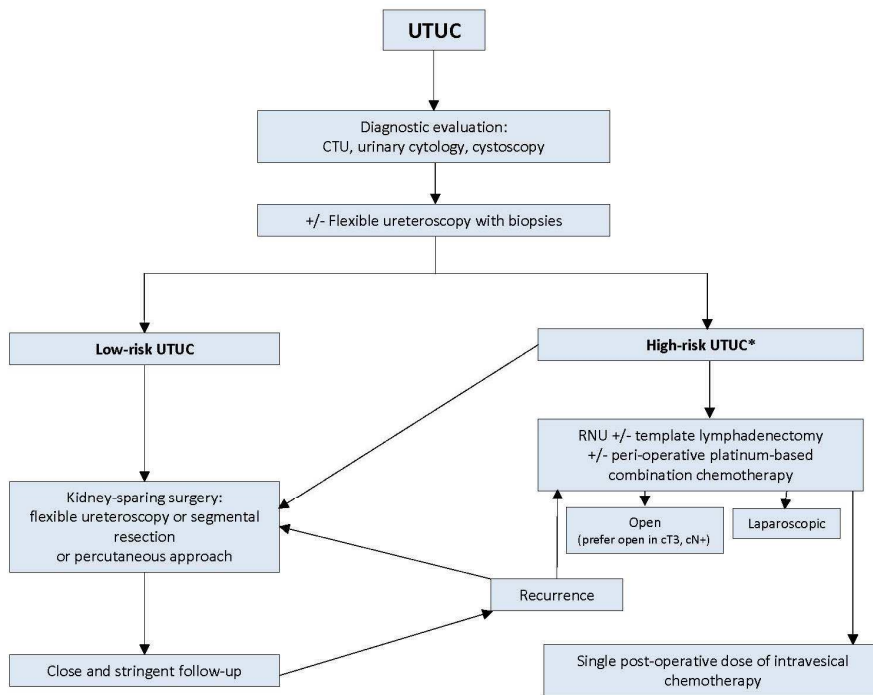


*CT urography= computed tomography urography; URS = ureteroscopy; UTUC = upper urinary tract urothelial cell carcinoma.*

*\* All of these factors need to be present.*

*\*\* Any of these factors need to be present.*

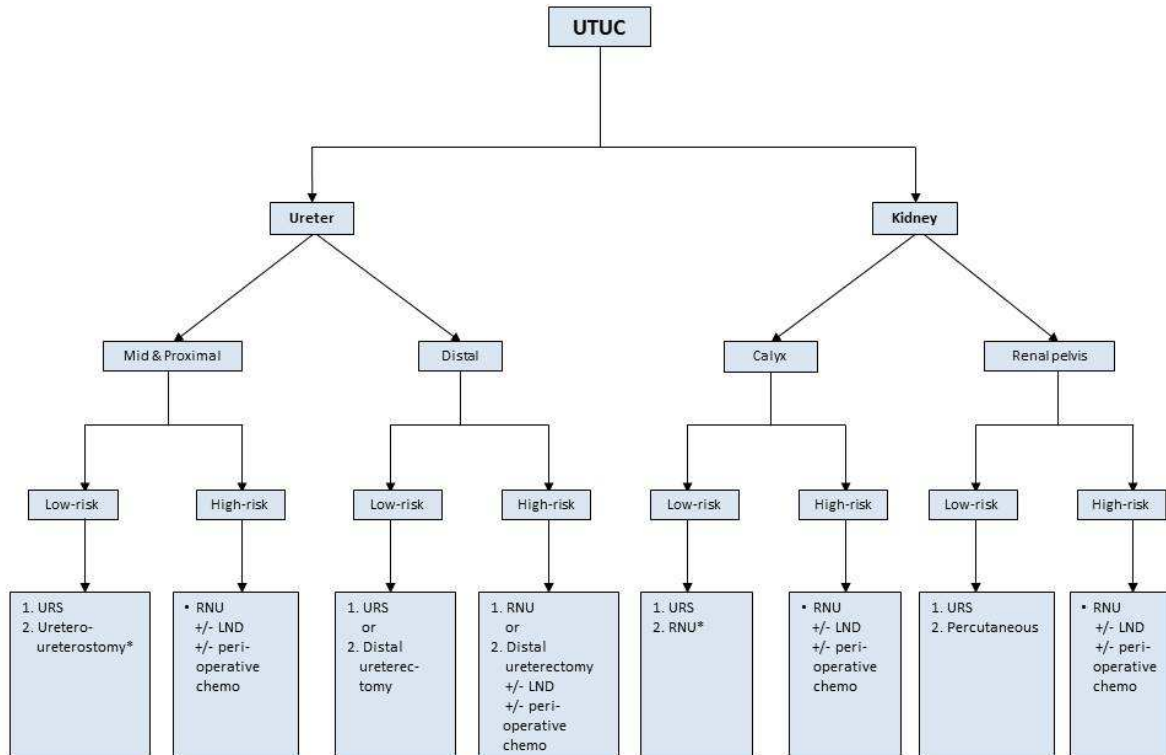
**Fig. 4: Proposed flowchart for the management of UTUC**



*CT = computed tomography; RNU = radical nephroureterectomy; UTUC = upper urinary tract urothelial cell carcinoma.*

*\* In patients with solitary kidney, consider a more conservative approach.*

**Fig. 5: Surgical treatment according to location and risk status**



1. First treatment option

2. Secondary treatment option

\*In case not amendable to endoscopic management.

LND = lymph node dissection; RNU = radical nephroureterectomy; URS = ureteroscopy; UTUC = upper urinary tract urothelial carcinoma.

**Table 1 – Summary of evidence and recommendations for epidemiology, aetiology, and pathology**

Summary of evidence	LE
Aristolochic acid and/or smoking exposure increases the risk for UTUC.	2
Patients with Lynch syndrome are at increased risk for UTUC.	3
Recommendations	Strength rating
Evaluate patient and family history based on the Amsterdam criteria to identify patients at increased risk of upper tract urothelial carcinoma.	Weak
Evaluate patient exposure to smoking and aristolochic acid.	Weak

LE = level of evidence; UTUC = upper tract urothelial carcinoma.

**Table 2 – TNM classification 2017 for upper tract urothelial cell carcinoma [31]**

---

*T—primary tumour*

TX Primary tumour cannot be assessed

T0 No evidence of primary tumour

Ta Noninvasive papillary carcinoma

Tis Carcinoma in situ

T1 Tumour invades subepithelial connective tissue

T2 Tumour invades muscularis

T3  
Renal pelvis: tumour invades beyond muscularis into peripelvic fat or renal parenchyma  
Ureter: tumour invades beyond muscularis into periureteric fat

T4 Tumour invades adjacent organs or through the kidney into perinephric fat

*N—regional lymph nodes*

NX Regional lymph nodes cannot be assessed

N0 No regional lymph node metastasis

N1 Metastasis in a single lymph node  $\leq 2$  cm in the greatest dimension

N2 Metastasis in a single lymph node  $> 2$  cm or multiple lymph nodes

*M—distant metastasis*

M0 No distant metastasis

M1 Distant metastasis

---

TNM = tumour, node, metastasis (classification).

**Table 3 – Summary of evidence and guidelines for the diagnosis of UTUC**

Summary of evidence	LE
The diagnosis and staging of UTUC are best done with CT urography and ureterorenoscopy.	2
Selective urinary cytology has high sensitivity for high-grade tumours, including carcinoma in situ.	3
Urethroscopy can detect concomitant bladder cancer.	2
Recommendations	Strength rating
Perform a urethroscopy to rule out bladder tumour.	Strong
Perform a CT urography for diagnosis and staging.	Strong
Use diagnostic ureteroscopy and biopsy if imaging and cytology are not sufficient for the diagnosis and/or risk stratification of the tumour.	Strong
Magnetic resonance urography may be used when CT is contraindicated.	Weak

CT = computed tomography; LE = level of evidence; UTUC = upper urinary tract urothelial carcinoma.

**Table 4 – Summary of evidence and recommendations for the prognosis of UTUC**

Summary of evidence	LE
Chronological age should not preclude radical nephroureterectomy with curative intent, where indicated.	3
Important prognostic factors include hydronephrosis, tumour multifocality, size, stage, grade, lymph node metastasis, lymphovascular invasion, and variant histology.	3
Recommendation	Strength rating
Use preoperative factors to risk stratify patients for therapeutic guidance.	Weak

LE = level of evidence; UTUC = upper tract urothelial carcinoma.

**Table 5 – Guidelines for kidney-sparing management of UTUC**

Recommendations	Strength rating
Offer kidney-sparing management as primary treatment option to patients with low-risk tumours.	Strong
Offer kidney-sparing management to patients with high-risk tumours limited to the distal ureter.	Weak
Offer kidney-sparing management to patients with solitary kidney and/or impaired renal function, provided that it will not compromise survival. This decision will have to be made on a case-by-case basis with the patient.	Strong

UTUC = upper tract urothelial carcinoma.



**Table 6 – Summary of evidence and guidelines for the management of high-risk nonmetastatic UTUC**

Summary of evidence	LE
Radical nephroureterectomy is the standard treatment for high-risk UTUC, regardless of tumour location.	2
Open, laparoscopic, and robotic approaches have similar oncological outcomes for organ-confined UTUC.	2
Failure to remove the bladder cuff completely increases the risk of bladder cancer recurrence.	3
Lymphadenectomy improves survival in muscle-invasive UTUC.	3
Postoperative chemotherapy improves survival.	1
Single postoperative intravesical instillation of chemotherapy lowers the bladder cancer recurrence rate.	1
Recommendations	Strength rating
Perform RNU in patients with high-risk nonmetastatic UTUC.	Strong
Perform open RNU in non-organ-confined UTUC.	Weak
Remove the bladder cuff in its entirety.	Strong
Perform a template-based lymphadenectomy in patients with presumed muscle-invasive UTUC.	Strong
Offer postoperative systemic platinum-based chemotherapy to patients with muscle-invasive UTUC.	Strong
Deliver a postoperative single-dose bladder instillation of chemotherapy to lower the intravesical recurrence rate.	Strong

LE = level of evidence; RNU = radical nephroureterectomy; UTUC = upper tract urothelial carcinoma.

**Table 7 – Summary of evidence and guidelines for the treatment of metastatic UTUC**

Summary of evidence	LE
Radical nephroureterectomy may improve quality of life and oncological outcomes in select metastatic patients.	3
Cisplatin-based combination chemotherapy can improve median survival.	2
Single-agent and carboplatin-based combination chemotherapy are less effective than cisplatin-based combination chemotherapy in terms of complete response and survival.	3
Nonplatinum combination chemotherapy has not been tested against standard chemotherapy in patients who are fit or unfit for cisplatin combination chemotherapy.	4
PD-1 inhibitor pembrolizumab has been approved for patients who have progressed during or after previous platinum-based chemotherapy based on the results of a phase III trial.	1b
PD-L1 inhibitor atezolizumab has been approved by the FDA for patients who have progressed during or after previous platinum-based chemotherapy based on the results of a phase II trial.	2a
PD-1 inhibitor nivolumab has been approved for patients who have progressed during or after previous platinum-based chemotherapy based on the results of a phase II trial.	2a
PD-1 inhibitor pembrolizumab has been approved for patients with advanced or metastatic UC ineligible for cisplatin-based first-line chemotherapy based on the results of a phase II trial, but use of pembrolizumab is restricted to PD-L1–positive patients.	2a
PD-L1 inhibitor atezolizumab has been approved for patients with advanced or metastatic UC ineligible for cisplatin-based first-line chemotherapy based on the results of a phase II trial, but use of atezolizumab is restricted to PD-L1–positive patients.	2a
Recommendations	Strength rating
Offer radical nephroureterectomy as a palliative treatment to symptomatic patients with resectable locally advanced tumours.	Weak
<i>First-line treatment for cisplatin-eligible patients</i>	
Use cisplatin-containing combination chemotherapy with GC, MVAC, preferably with G-CSF, HD-MVAC with G-CSF, or PCG.	Strong
Do not offer carboplatin and nonplatinum combination chemotherapy.	Strong
<i>First-line treatment in patients unfit for cisplatin</i>	
Offer checkpoint inhibitors pembrolizumab or atezolizumab depending on PD-L1 status.	Weak

Offer carboplatin combination chemotherapy if PD-L1 is negative. Strong

*Second-line treatment*

Offer checkpoint inhibitor (pembrolizumab) to patients with disease progression during or after platinum-based combination chemotherapy for metastatic disease. Strong

Offer checkpoint inhibitor (atezolizumab or nivolumab) to patients with disease progression during or after platinum-based combination chemotherapy for metastatic disease. Strong

Offer only vinflunine to patients for metastatic disease as second-line treatment if immunotherapy or combination chemotherapy is not feasible. Alternatively, offer vinflunine as third or subsequent treatment line. Strong

---

FDA = US Food and Drug Administration; GC = gemcitabine plus cisplatin; G-CSF = granulocyte colony-stimulating factor; HD-MVAC = high-dose MVAC; LE = level of evidence; MVAC = methotrexate, vinblastine, adriamycin plus cisplatin; PD-L1 = programmed death ligand 1; PCG = paclitaxel, cisplatin, gemcitabine; UC = urothelial carcinoma.

**Table 8 – Summary of evidence and guidelines for the follow-up of UTUC**

Summary of evidence	LE
Follow-up is more frequent and more stringent in patients who have undergone kidney-sparing treatment than in those undergoing radical nephroureterectomy.	3
Recommendations	Strength rating
<b>After radical nephroureterectomy</b>	
<i>Low-risk tumours</i>	
Perform cystoscopy at 3 mo. If negative, perform subsequent cystoscopy 9 mo later and then yearly, for 5 yr.	Weak
<i>High-risk tumours</i>	
Perform cystoscopy and urinary cytology at 3 mo. If negative, repeat subsequent cystoscopy and cytology every 3 mo for a period of 2 yr, every 6 mo thereafter until 5 yr, and then yearly.	Weak
Perform CT urography and chest CT every 6 mo for 2 yr and then yearly.	Weak
<b>After kidney-sparing management</b>	
<i>Low-risk tumours</i>	
Perform cystoscopy and CT urography at 3 and 6 mo, and then yearly for 5 yr.	Weak
Perform URS at 3 mo.	Weak
<i>High-risk tumours</i>	
Perform cystoscopy, urinary cytology, CT urography, and chest CT at 3 and 6 mo, and then yearly.	Weak
Perform URS and urinary cytology in situ at 3 and 6 mo.	Weak

CT = computed tomography; LE = level of evidence; URS = ureteroscopy UTUC = upper tract urothelial carcinoma..