



HAL
open science

Lack of association between chilblains outbreak and severe acute respiratory syndrome coronavirus 2: Histologic and serologic findings from a new immunoassay

Vivien Hébert, Anne-Bénédicte Duval-Modeste, Pascal Joly, Véronique Lemée, Lucie Cellier, Fabienne Jouen, Benoit Veber, Laurent Drouot, Olivier Boyer

► To cite this version:

Vivien Hébert, Anne-Bénédicte Duval-Modeste, Pascal Joly, Véronique Lemée, Lucie Cellier, et al.. Lack of association between chilblains outbreak and severe acute respiratory syndrome coronavirus 2: Histologic and serologic findings from a new immunoassay. *Journal of The American Academy of Dermatology*, 2020, 83, pp.1434 - 1436. <10.1016/j.jaad.2020.07.048>. <hal-03493500>

HAL Id: hal-03493500

<https://hal.science/hal-03493500v1>

Submitted on 17 Oct 2022

HAL is a multi-disciplinary open access archive for the deposit and dissemination of scientific research documents, whether they are published or not. The documents may come from teaching and research institutions in France or abroad, or from public or private research centers.

L'archive ouverte pluridisciplinaire HAL, est destinée au dépôt et à la diffusion de documents scientifiques de niveau recherche, publiés ou non, émanant des établissements d'enseignement et de recherche français ou étrangers, des laboratoires publics ou privés.



Distributed under a Creative Commons CC BY-NC 4.0 - Attribution - Non-commercial use - International License

1 **Lack of association between chilblains outbreak and SARS-CoV-2: histological and**
2 **serological findings from a new immunoassay**

3
4 Vivien Hébert, MD¹ ; Anne-Bénédicte Duval-Modeste, MD¹ ; Pascal Joly, MD, PhD¹ ; Véronique
5 Lemée, MD² ; Lucie Cellier, MD³ ; Fabienne Jouen, MD⁴ ; Benoit Veber, MD, PhD⁵ ; Laurent Drouot,
6 PhD⁴ ; Olivier Boyer, MD, PhD⁴

7
8 ¹ Normandie Univ, UNIROUEN, Inserm, U1234, FOCIS Center of Excellence PAn'THER, Rouen
9 University Hospital, Department of Dermatology, Rouen, France

10
11 ² Department of Virology, Rouen University Hospital, Rouen, France

12
13 ³ Department of Pathology, Rouen University Hospital, Rouen, France

14
15 ⁴ Normandie Univ, UNIROUEN, Inserm, U1234, FOCIS Center of Excellence PAn'THER, Rouen
16 University Hospital, Département of Immunology and Biotherapy, Rouen, France

17
18 ⁵ Department of Reanimation, Rouen University Hospital, Rouen, France

19
20
21 Word count = 556

22
23 References = 6

24
25 Figures / Tables = 2

26
27 I declare no funding sources

28
29 I declare no conflict of interest

30
31 Corresponding author:

32
33 Dr Vivien Hébert
34 Clinique dermatologique
35 CHU de Rouen
36 1 rue de Germont
37 76031 ROUEN
38 Tel number: (+33) 2 32 88 68 41
39 Fax: (+33) 2 32 88 88 55
40 Email: Vivien.Hebert@chu-rouen.fr

42 The Coronavirus disease-2019 (COVID-19), due to SARS-CoV-2, has been declared a worldwide
43 pandemic on March 11th 2020 (1,2).

44 Recently, numerous cases of acute chilblains-like lesions have been reported on social networks, from
45 Belgium, France and Italy. Despite weak evidence, in particular the absence of serological studies, the
46 hypothesis that these lesions were potentially related to the Covid-19 infection, as a pauci-
47 symptomatic form, rapidly grew (3–5) . An alert letter was even sent to the French Ministry of Health
48 and to French dermatologists, by the National Union of Dermatologists.

49 Since 33 patients (14 women, 19 men) with chilblains were referred to our Dermatology
50 Department within one week, we studied the relationship between these lesions and the Covid-19
51 infection. All patients (mean±SD age 23.4±8.7 years.) presented erythematous and purpuric papules
52 localised on the toes ± fingers (12 patients, 36.4%) (Figure1). Edema was present in 12 (36.4%), and
53 pruritus or burning sensation in 18 cases (54.5%). Median delay between the onset of dermatological
54 features and the first consultation was 8 days (IQR 6.5-18 days). Chilblains were the only clinical
55 manifestation in 23 cases (69.7%); ten patients (30.3%) presented other symptoms which occurred
56 prior to (n=6), concomitantly (n=1) or after skin symptoms (n=3) : asthenia (n=4), cough (n=3),
57 diarrhoea (n=3), fever (n=2), myalgia (n=2), headache (n=1) and odynophagia (n=1). No patient
58 reported contact with Covid-19 infected patients. Three patients recently tested for Covid-19 infection
59 had negative sinus RT-PCR.

60 Blood cell count was normal in 26 patients. A mild lymphopenia (mean 1.15 ±0.21 G/L) was
61 observed in seven patients. C-reactive protein and erythrocyte sediment rate were negative for all
62 patients. Two patients had positive ANA and three patients had Abs for a type III cryoglobulinemia.

63 Histology performed in five patients showed lymphocytic infiltrate in the superficial dermis
64 around vessels and eccrine glands in all cases, reminiscent of idiopathic chilblains. Direct
65 immunofluorescence showed fibrinogen and C3 deposits on endothelial cells in two cases. IIF assay
66 using the serum from a patient with anti-SARS-CoV-2 IgG Abs, and RT-PCR on lesional skin were
67 negative.

68 We developed an ALBIA-Spike S1 for detecting anti-SARS-CoV-2 antibodies, that allowed a
69 96% sensitivity and a 98% specificity (Drouot et al. in preparation). Anti-SARS-CoV-2 IgG Abs were

70 negative in all 33 sera, while 1/33 was positive for IgM at the first and the second consultation 14 days
71 later. No seroconversion was observed (Figure 2). Our findings were then confirmed using the
72 Abbott® SARS-CoV-2 IgG immunoassay performed on the Day 14 sera, without detectable
73 seropositivity.

74

75 The present data provide no argument for any link between these chilblains and infection with
76 SARS-CoV-2. Clinical and histological features were those of idiopathic chilblains. RT-PCR and IIF
77 on lesional skin when performed were negative. None of the 33 sera tested contained anti-SARS-CoV-
78 2 IgG Abs, while only one had IgM twice (3%), consistent with the current estimation of a rate of
79 SARS-CoV-2 infection from 5% to 10% in the general population in France (6).

80

81 We think that this hypothesis of “Covid-19 related chilblains” could be explained by a
82 cumulation of i) a temporality bias in this early-spring period when the average temperature
83 differences were the widest, ii) a confounding bias related to the young age, since pauci-symptomatic
84 forms of the infection are observed in young people, and iii) a recruitment bias related to the
85 shortening of the dermatology consultation delays due to the quarantine period.

86

87

88 **References:**

- 89 1. Zhu N, Zhang D, Wang W, Li X, Yang B, Song J, et al. A Novel Coronavirus from Patients with
90 Pneumonia in China, 2019. *N Engl J Med.* 20 2020;382(8):727-33.
- 91 2. Huang C, Wang Y, Li X, Ren L, Zhao J, Hu Y, et al. Clinical features of patients infected with
92 2019 novel coronavirus in Wuhan, China. *Lancet Lond Engl.* 15 2020;395(10223):497-506.
- 93 3. Bouaziz J, Duong T, Jachiet M, Velter C, Lestang P, Cassius C, et al. Vascular skin symptoms in
94 COVID-19: a french observational study. *J Eur Acad Dermatol Venereol.* 27 avr
95 2020;jdv.16544.
- 96 4. de Masson A, Bouaziz J-D, Sulimovic L, Cassius C, Jachiet M, Ionescu M-A, et al. Chilblains
97 are a common cutaneous finding during the COVID-19 pandemic: a retrospective nationwide
98 study from France. *J Am Acad Dermatol.* 4 mai 2020;
- 99 5. Kolivras A, Dehavay F, Delplace D, Feoli F, Meiers I, Milone L, et al. Coronavirus (COVID-19)
100 infection-induced chilblains: a case report with histopathological findings. *JAAD Case Rep*
101 [Internet]. 18 avr 2020 [cité 23 avr 2020];0(0). Disponible sur:
102 [https://www.jaadcasereports.org/article/S2352-5126\(20\)30282-4/abstract](https://www.jaadcasereports.org/article/S2352-5126(20)30282-4/abstract)
- 103 6. Covid-19 : une modélisation indique que près de 6% des Français ont été infectés [Internet].
104 Institut Pasteur. 2020 [cité 23 avr 2020]. Disponible sur: [https://www.pasteur.fr/fr/espace-](https://www.pasteur.fr/fr/espace-presse/documents-presse/covid-19-modelisation-indique-que-pres-6-francais-ont-ete-infectes)
105 [presse/documents-presse/covid-19-modelisation-indique-que-pres-6-francais-ont-ete-infectes](https://www.pasteur.fr/fr/espace-presse/documents-presse/covid-19-modelisation-indique-que-pres-6-francais-ont-ete-infectes)

106

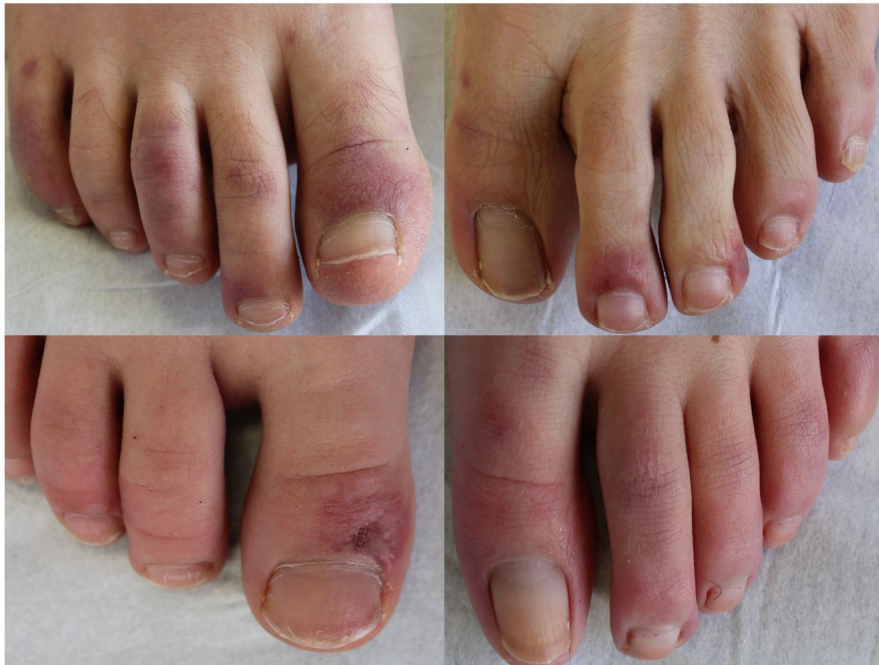

Figure 1: Exemple of 4 patients referred for chilblains

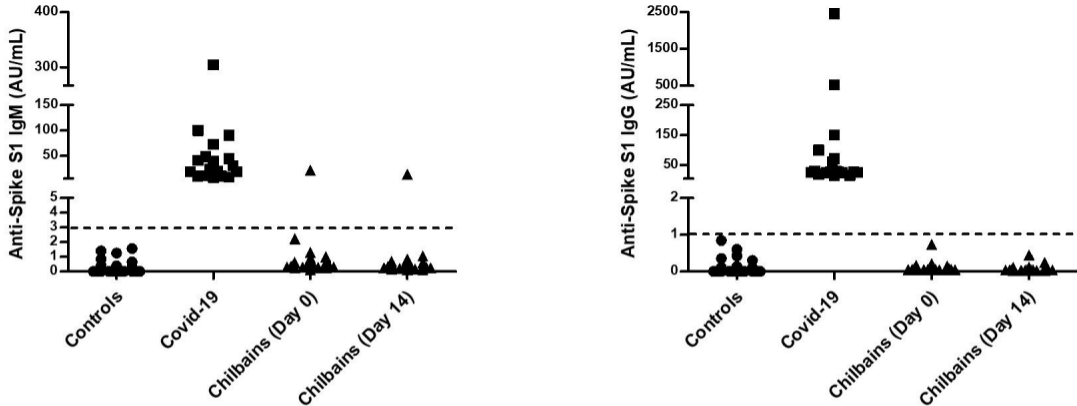


Figure 2: SARS-CoV-2 serology. Sera from negative control patients (circles, $n=130$, healthy donors of blood collected by the French *Etablissement Français du Sang* before the pandemic), Covid-19 patients (squares, $n=18$, RT-PCR⁺ patients from Rouen University Hospital) and patients with chilblains (triangles, $n=33$ at day 0 and 31 at day 14) were assayed for the presence of anti-Spike S1 antibodies (Left: IgM; Right: IgG; dotted line: threshold of positivity of the assay).