



HAL
open science

AA amyloidosis revealing mevalonate kinase deficiency: A report of 20 cases including two new French cases and a comprehensive review of literature

François Rodrigues, Jean-Baptiste Philit, Irina Giurgea, Dany Anglicheau,
Jean-Jacques Roux, Nadia Hoyeau, Gilles Grateau, Laurence Cuisset, Sophie
Georgin-Lavialle

► To cite this version:

François Rodrigues, Jean-Baptiste Philit, Irina Giurgea, Dany Anglicheau, Jean-Jacques Roux, et al.. AA amyloidosis revealing mevalonate kinase deficiency: A report of 20 cases including two new French cases and a comprehensive review of literature. *Seminars in Arthritis and Rheumatism*, 2020, 50, pp.1370 - 1373. 10.1016/j.semarthrit.2020.03.005 . hal-03493463

HAL Id: hal-03493463

<https://hal.science/hal-03493463>

Submitted on 15 Dec 2022

HAL is a multi-disciplinary open access archive for the deposit and dissemination of scientific research documents, whether they are published or not. The documents may come from teaching and research institutions in France or abroad, or from public or private research centers.

L'archive ouverte pluridisciplinaire **HAL**, est destinée au dépôt et à la diffusion de documents scientifiques de niveau recherche, publiés ou non, émanant des établissements d'enseignement et de recherche français ou étrangers, des laboratoires publics ou privés.



Distributed under a Creative Commons Attribution - NonCommercial 4.0 International License

Title: AA amyloidosis revealing mevalonate kinase deficiency: a report of 20 cases including two new French cases and a comprehensive review of literature.

Authors: François Rodrigues^{1,*}, Jean-Baptiste Philit², Irina Giurgea³, Dany Anglicheau⁴, Jean-Jacques Roux⁵, Nadia Hoyeau⁶, Gilles Grateau^{1,*}, Laurence Cuisset⁷, Sophie Georgin-Lavialle^{1,*}.

¹Internal medicine department, Tenon hospital, Assistance Publique - Hôpitaux de Paris, Sorbonne University, Paris, France

²Nephrology department, Chambéry hospital, Chambéry, France

³Medical genetics department, Armand-Trousseau hospital, Assistance Publique - Hôpitaux de Paris, Sorbonne University, Paris, France

⁴Nephrology department, Necker Enfants malades hospital, Assistance Publique - Hôpitaux de Paris, Université Paris 5 Descartes, Paris, France

⁵Department of pathology, Chambéry hospital, Chambéry, France

⁶Department of pathology, Saint-Antoine hospital, Assistance Publique - Hôpitaux de Paris, Sorbonne University, Paris, France

⁷Department of Genetics and Molecular Biology, Cochin hospital, Assistance Publique - Hôpitaux de Paris, Université Paris 5 Descartes, Paris France

*French national reference Center for autoinflammatory diseases (CEREMAIA).

Corresponding author

Sophie Georgin-Lavialle, Internal medicine department, Tenon hospital, Assistance Publique - Hôpitaux de Paris, Sorbonne University, 4 rue de la Chine, 75020 Paris, France. French national reference Center for autoinflammatory diseases. Tel 0033156016077; Fax: 0033156017146

E-mail: sophie.georgin-lavialle@aphp.fr

Abstract (246 words)

Introduction: Mevalonate kinase deficiency (MKD) is a rare autosomal recessive autoinflammatory disease that can lead to an inflammatory A amyloidosis (AA).

Methods: To study the occurrence of AA in MKD patients we performed a systemic review of the literature and described two novel patients.

Results: Amyloidosis occurred in 20 MKD patients, renal impairment being always the revealing symptom of AA. Although an accurate prevalence estimation is not possible since exact MKD prevalence is unknown, AA seems rare in MKD (about 6% if we estimate MKD prevalence at 300 patients worldwide). *MVK* gene study, available in 18 out of the 20 patients, confirmed two pathogenic mutations in all tested individuals. The most frequent genotype was V377I/I268T (n=9/18). Retrospective search of clinical signs of MKD established, in all patients carrying *MVK* pathogenic mutations, a disease onset within the first four years of life. Nephrotic syndrome (n=15), end-stage renal failure (n=5) or both (n=8) pointed out kidney amyloidosis. The youngest patient with renal amyloidosis was a European four-year-old girl previously misdiagnosed with PFAPA syndrome. Five patients died of AA amyloidosis despite the use of a biotherapy for two of them; kidney transplant was performed in nine individuals. Colchicine was not effective in any patient. Anti-interleukin-1 anakinra (n=8), anti TNF etanercept (n=7) and anti-interleukin 6 tocilizumab (n=5) treatments were partially effective.

Conclusion: Inflammatory A amyloidosis, a rare complication of MKD, can cause death or necessitate kidney transplantation. Early diagnosis and cytokine blocking biotherapy using anti-IL1, anti-TNF or anti-IL6 agents are required to prevent terminal renal failure.

Manuscript (1237 words)

Introduction

Mevalonate kinase deficiency (MKD) is a rare monogenic autosomal recessive autoinflammatory disease¹ caused mutations in *MVK*, the gene for coding the mevalonate kinase protein. The disease typically starts during the first months of life. The common features include recurrent fever associated with one or more of the following features: lymphadenopathy, mouth ulcers, arthralgia, headache, vomiting, abdominal pain, vaccine reaction and rash. In absence of accurate diagnosis and persistence of systemic chronic inflammation, MKD may be complicated by inflammatory A amyloidosis (AA) that can result in kidney failure and death.

To study the occurrence and prognosis of AA in MKD patients we performed a literature review of all published cases from 1947 to 2019 and a retrospective study of all French cases collected through the national referral center for inflammatory amyloidosis and hereditary recurrent fevers.

Methods

Pubmed and Medline databases were searched from 1947 to May 20th, 2019 for relevant articles using the keywords "amyloidosis" "mevalonate kinase deficiency" and "hyper IgD syndrome". All relevant articles were retrieved, and additional references quoted in these articles were checked by manual research. Abstracts from the congress of Familial Mediterranean Fever and Systemic Auto-inflammatory Diseases (ISSAID) and from the congress of Pediatric Rheumatology European Society were searched on titles from 2001 to 2019 and 1994 to 2019, respectively, for relevant articles.

Case reports

A 62-year old female patient of Spanish origin suffered since the age of 18 months from bouts of fever, abdominal pain, vomiting, arthromyalgias, cervical lymphadenopathy and oral ulcers, lasting one week and occurring twice monthly. She was referred to a nephrology clinic with proteinuria and AA was diagnosed by renal biopsy. Nephrotic syndrome and end stage renal failure requiring hemodialysis occurred respectively four and seven years later. At the age of 71 she presented to the emergency department for abdominal pain and constipation. CT scan showed a colic occlusion with sigmoid stenosis caused by an endoluminal mass.

Duodenal and sigmoid biopsies were positive for AA (figure 1). She refused any intervention and died two months later. Next-generation sequencing of a panel of 62 genes linked to autoinflammatory syndromes revealed two heterozygous mutations (I268T and V377I) in the *MVK* gene.

A 33-year old male of North African origin was referred to our reference center for exploration of renal and digestive AA amyloidosis. His parents were consanguineous. One brother and one sister had died at the ages of 8 and 5 respectively and had both been suffering from unexplained recurring fever since the first months of life. The patient suffered from fever, abdominal pain, vomiting, otitis and odynophagia episodes since the age of one. He displayed a growth delay and proteinuria since childhood. AA amyloid deposits were demonstrated on renal, duodenal and rectal biopsies at the age of 13 (figure 2). He went on to develop end-stage renal disease requiring hemodialysis at the age of 20. At that time he was not eligible for renal transplantation because of severe cachexia and malabsorption due to AA amyloidosis. Colchicine had been given since childhood with no effect. At the age of 28 years he started monthly injections with tocilizumab, which resulted in marked diminution of febrile episodes, diarrhea and weight gain. One year later the patient underwent renal transplantation. To date, he continues the treatment with tocilizumab. Targeted Sanger sequencing of *MEFV*, *MVK*, *NLRP3*, *TNFRSF11A* revealed two heterozygous variants (N205D and G336S) in *MVK* gene.

Results

Our keyword research found 44 references, of which 7 were relevant²⁻⁸. Manual research allowed five additional references to be added⁹⁻¹². Nineteen patients suffering from both MKD and AA amyloidosis were described in the literature, and we retained MKD diagnosis in eighteen of them. The excluded patient was clinically asymptomatic at the age of 47, carried two nonpathogenic *MVK* variants (S52N a likely benign variant and D386N a variant of unknown significance) and no measurement of mevalonate kinase enzymatic activity was available⁴.

A total of 20 cases were studied, two novel French patients and eighteen cases from literature described in eleven articles from 1996 to 2017 (table 1). Given a current estimate of 300 patients suffering from MKD worldwide¹³, the prevalence of AA is thus roughly estimated at about 6% of all MKD cases. Among the 20 patients with AA and MKD, 13 were men and 7 women with a median age of 26.5 years at AA diagnosis (extremes 4-62 years). The origin of the patients was varied: Northern Europe (n = 7), Italy (n = 3), Eastern Europe (n = 3), Great Britain (n = 3), Germany (n = 1), Spain (n = 1), Algeria (n=1) and Turkey (n = 1). With the exception of one patient¹², the diagnosis of MKD was always made after that of AA in this series. MKD clinical signs had always started in the first 4 years of life. The median delay between the first symptoms and MKD diagnosis was 24 years ranging from 4 to 70 years. *MVK* gene sequencing was performed in all but one patient and systematically revealed two pathogenic heterozygous mutations. The most common genotype was V377I/I268T (n=9). The main clinical signs of amyloidosis were nephrotic syndrome (n=15), isolated end stage renal disease (n=5) or nephrotic syndrome with end stage renal disease (n=8) and, less frequently, intestinal occlusion (n=1) or malabsorption (n=1). AA was histologically proven on kidney biopsy (n=18), digestive tract biopsy (n=5), as well as thyroid (n=1) and bronchial (n=1) tissue samples. The youngest patient was a 4 years girl, who was misdiagnosed with PFAPA syndrome⁵. Interestingly, two patients from Turkey and Algeria were wrongly diagnosed with familial Mediterranean fever because the prevalence of this autoinflammatory disease is particularly high in this regions¹¹.

Five patients died including two before the era of biotherapy; nine underwent a kidney transplant. Colchicine was tried in 7 patients, in the hypothesis of familial Mediterranean fever or PFAPA syndrome but was never effective. Several biotherapies have been used effectively: anti interleukine-1 type anakinra (n = 8, one success, five partial responses, two failures); anti-TNF alpha fusion protein etanercept (n = 7, four successes, one partial

response, two failures); anti-interleukin 6 tocilizumab (n = 5, four successes, one partial response). AA amyloidosis relapsed on three kidney grafts.

Discussion

This study describes clinical, biological and genetic characteristics of 20 patients with mevalonate kinase deficiency and AA amyloidosis. Diagnosis of MKD can be made late in life, secondary to the diagnosis of AA amyloidosis. To date we estimate that around 6% of all patients with MKD, in whom the diagnosis was missed, develop AA amyloidosis with a mortality rate of 25%. This estimation must be met with caution, since the actual prevalence of MKD is unknown and since our analysis of case reports is subject to selection and publication bias. Our results are congruent with those of Ter Haar et al¹², who described 5 patients with amyloidosis among a cohort of 114 MKD patients belonging to the Eurofever registry. In Ter Haar's series, rough prevalence estimate was of 4.3%, two patients out of five died of amyloidosis, and four patients out of five were diagnosed MKD after AA amyloidosis. In our series, all reported cases but one¹² received the MKD diagnosis after AA amyloidosis discovery, underscoring that this autoinflammatory disorder is still underdiagnosed. We highlight the importance of an early targeted gene sequencing to begin treatment and prevent the onset of AA, especially as the clinical presentation of MKD can mimic other autoinflammatory disease such as PFAPA and familial Mediterranean fever. Misdiagnosis is therapeutically relevant since colchicine is inefficient in mevalonate kinase deficiency in contrast to the two former autoinflammatory conditions^{1,13}. Patients with AA complicating MKD can benefit from a kidney transplant. Nevertheless, all MKD patients with AA should receive biotherapy targeting proinflammatory cytokines including anti-IL-1, anti-TNF or anti-IL6 receptor. Indeed, this data show that AA amyloidosis can relapse on the grafted kidney if the disease is not controlled after transplantation.

Regarding genotypes, 83% (15/18) of patients had variants located between the 205 to 268 aminoacids and 50% (9/18) of patients harbored the V377I/I268T genotype, which is fairly common in MKD.

In conclusion, early diagnosis of MKD is essential to start an effective treatment, such as a biotherapy targeting interleukins 1 or 6, in order to avoid systemic inflammation and thus to prevent AA occurrence.

References

- ¹ Schulert G, Favier L. Mevalonate kinase deficiency: current perspectives. *Appl Clin Genet* 2016 Jul;Volume 9:101–10.
- ² Obici L, Manno C, Muda AO, Picco P, D’Osualdo A, Palladini G, et al. First report of systemic reactive (AA) amyloidosis in a patient with the hyperimmunoglobulinemia D with periodic fever syndrome. *Arthritis Rheum* 2004 Sep;50(9):2966–9.
- ³ Li Cavoli G, Passantino D, Tortorici C, Bono L, Ferrantelli A, Giammarresi C, et al. Renal amyloidosis due to hyper-IgD syndrome. *Nefrologia* 2012;32(6):865–6.
- ⁴ Lane T, Loeffler JM, Rowczenio DM, Gilbertson JA, Bybee A, Russell TL, et al. AA amyloidosis complicating the hereditary periodic fever syndromes. *Arthritis Rheum* 2013 Apr;65(4):1116–21.
- ⁵ Kolsky A, Rowczenio D, Lachmann H, Vernerova Z, Votava F, Dolezalova P. P02-015 - A novel MVK mutation in a child with AA amyloid. *Pediatr Rheumatol* 2013;11(Suppl 1):A122.
- ⁶ Kallianidis AF, Ray A, Goudkade D, de Fijter JW. Amyloid A amyloidosis secondary to hyper IgD syndrome and response to IL-1 blockage therapy. *Neth J Med* 2016 Jan;74(1):43–6.
- ⁷ Lachmann HJ, Goodman HJB, Andrews PA, Gallagher H, Marsh J, Breuer S, et al. AA amyloidosis complicating hyperimmunoglobulinemia D with periodic fever syndrome: A report of two cases. *Arthritis Rheum* 2006 Jun;54(6):2010–4.
- ⁸ Rowczenio DM, Pozsonyi Z, Baginska A, et al. Two cases of AA amyloidosis complication Hyper-IgD and periodic fever syndrome (HIDS) diagnosed at the UK national amyloidosis centre. Poster session presented at: 9th International Congress of Familial and Mediterranean Fever and Systemic Auto-Inflammatory Diseases (ISSAID 2017); 2017 May 4-7; Northern Cyprus.

⁹ Ostuni P, Vertolli U, Marson P. Atypical hypergammaglobulinaemia D syndrome with amyloidosis: an overlap with familial Mediterranean fever? *Clin Rheumatol* 1996 Nov;15(6):610–2.

¹⁰ Siewert R, Ferber J, Horstmann RD, Specker C, Heering PJ, Timmann C. Hereditary Periodic Fever With Systemic Amyloidosis: Is Hyper-IgD Syndrome Really a Benign Disease? *Am J Kidney Dis* 2006 Sep;48(3):e41–5.

¹¹ Dusunsel R, Gunduz Z, Bastug F, et al. Amyloidosis in a child with Hyperimmunoglobulin D syndrome. *Pediatr Rheumatol Online J*. 2011;9(Suppl 1):P2. Published 2011 Sep 14. doi:10.1186/1546-0096-9-S1-P2

¹² ter Haar NM, Jeyaratnam J, Lachmann HJ, Simon A, Brogan PA, Doglio M, et al. The Phenotype and Genotype of Mevalonate Kinase Deficiency: A Series of 114 Cases From the Eurofever Registry: PHENOTYPE AND GENOTYPE OF MKD. *Arthritis & Rheumatology*. 2016 Nov;68(11):2795–805.

¹³ ter Haar NM, Oswald M, Jeyaratnam J, Anton J, Barron KS, Brogan PA, et al. Recommendations for the management of autoinflammatory diseases. *Ann Rheum Dis* 2015 Sep;74(9):1636–44.

Table 1: Main features of the 16 patients. .

Legend: NA : not available

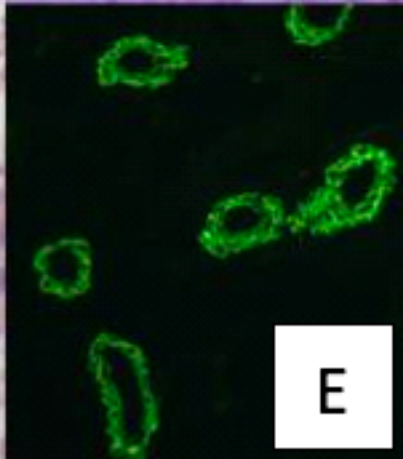
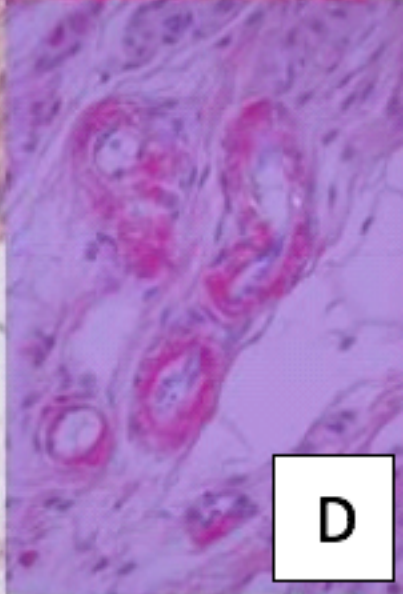
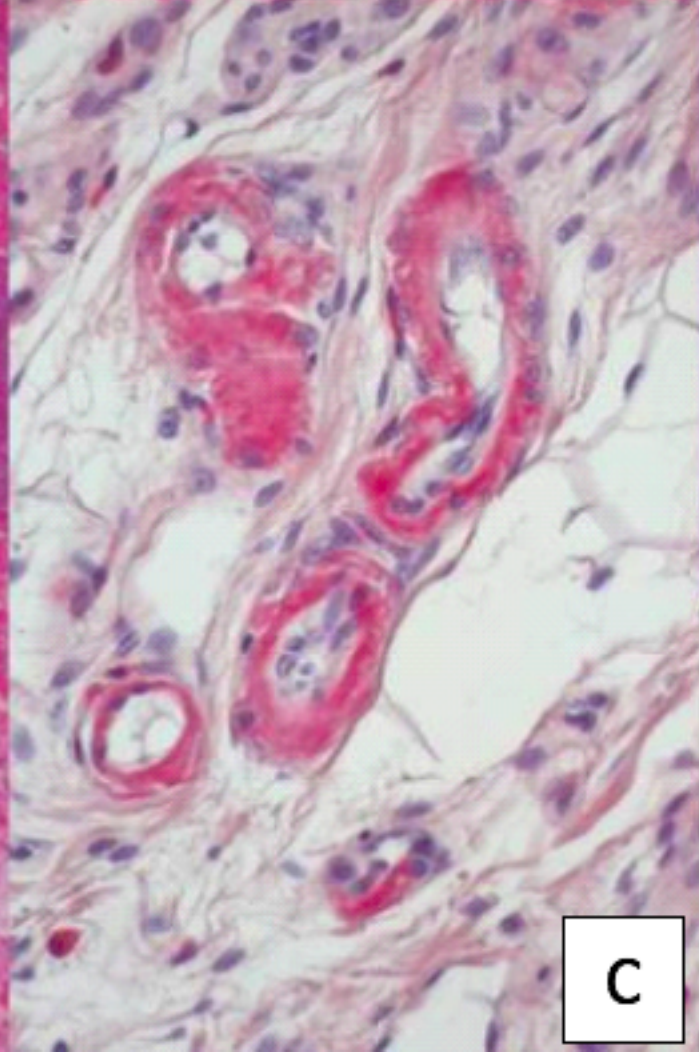
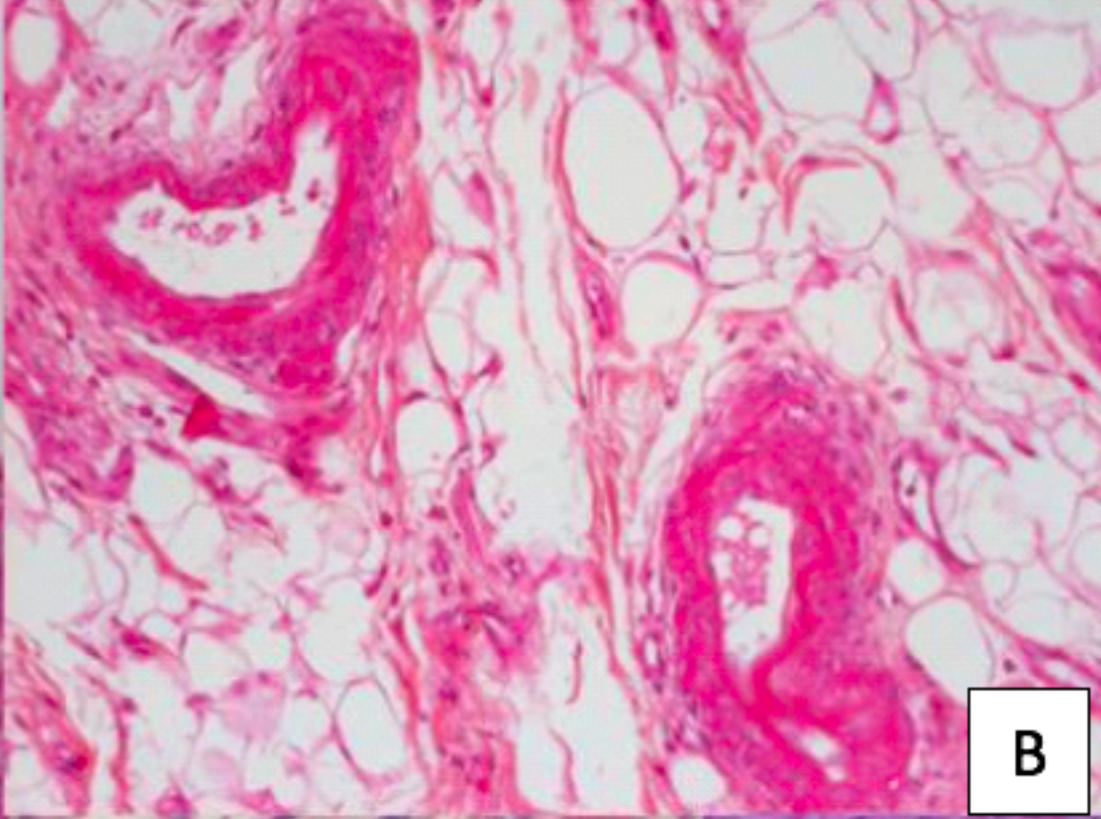
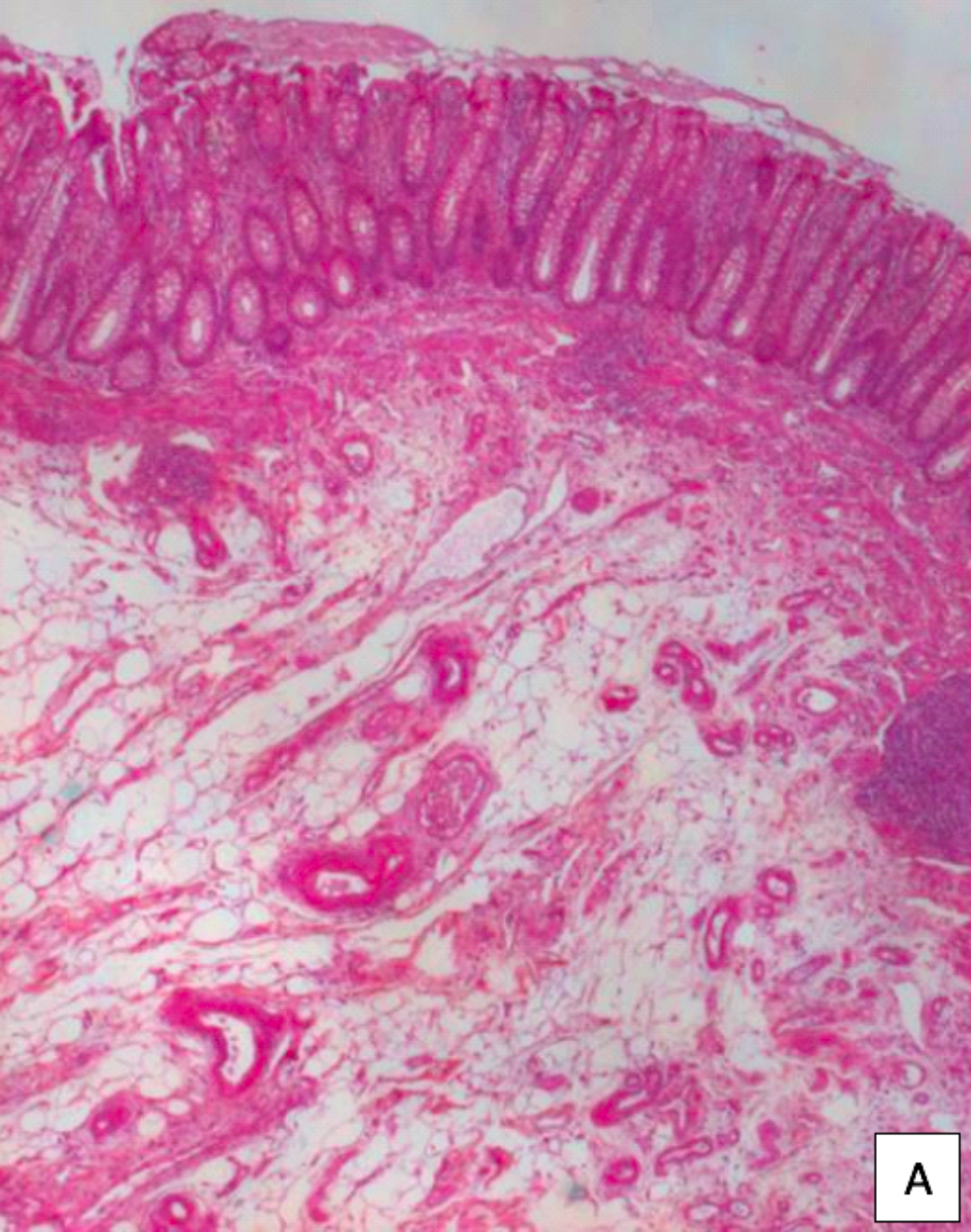
Figure's legends:

Figure 1.

Figure 1. Rectal mucosa biopsies of patient 19 showing amorphous eosinophilic amyloid deposits green-apple birefringence in polarized light. A: rectal mucosa, HES. B: zoom on vascular deposits, HES. C: Red Sirius without polarization microscopy. D: Red Sirius apple-green refringence with polarization microscopy. E: thioflavin-T staining with fluorescent microscopy. Staining was positive with anti-AA antibody and negative with anti-kappa and anti-lambda antibodies (not shown).

Figure 2.

Rectal biopsy of patient 20 showing amorphous eosinophilic amyloid deposits colored by red Congo staining. Staining was positive with anti-AA antibody and negative with anti-kappa and anti-lambda antibodies (not shown).



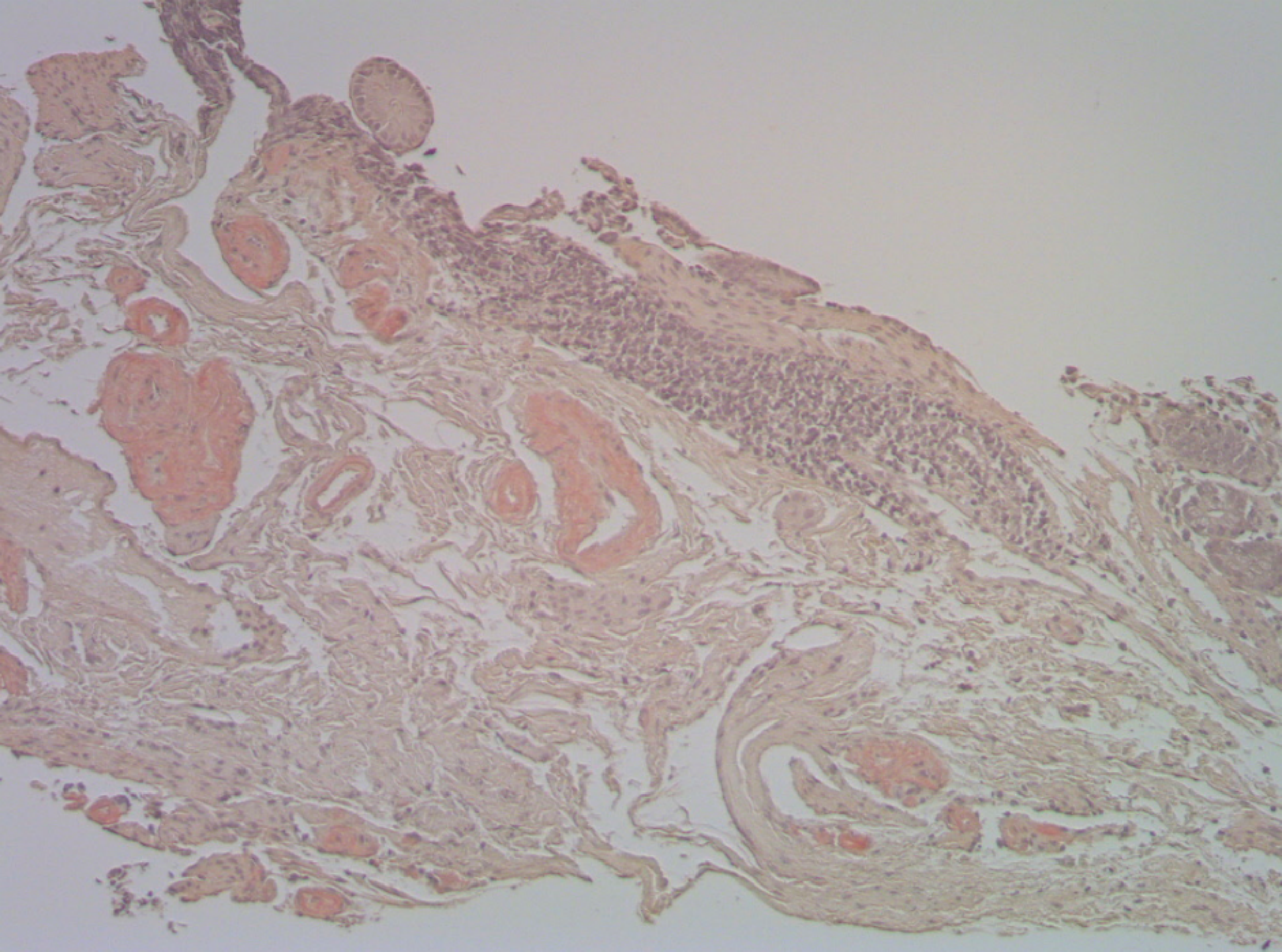


Table 1: Main features of the 16 patients.

Patient number [and reference]	Sex	Age on AA diagnosis (years)	Age on MKD diagnosis (years)	Age on first MKD symptoms (years)	Diagnosis delay (years)	MVK mutation	Origin	Death	Treatment by a biologic agent
1 ⁹	M	28	33	1	33	NA	Italian		No
2 ²	M	27	27	1	27	V377I/L265R	Italian		No
3 ⁷	M	19	19	1	19	V377I/I268T	British		Anti IL1
4 ¹²	M	37	27	3	24	V377I/I268T	British		Anti IL1
5 ⁷	M	22	22	1	22	V377I/L234P	German		Anti TNF
6 ¹⁰	M	22	22	1	22	H20P/V250I	Western European	yes	Anti TNF
7 ³	M	29	29	1	29	NA	Italian		Anti IL1
8 ¹¹	M	7	7	1	7	G326R/V377I	Turkish		Anti TNF
9 ⁴	M	23	23	NA	23	V377I/L234P	Northern European		Anti IL1 Anti IL6
10 ⁴	M	15	15	1	15	V377I/I268T	Northern European	yes	Anti IL1
11 ⁴	F	26	26	1	26	V377I/I268T	Northern European		Anti TNF
12 ⁶	F	62	62	NA	62	V377I/I268T	European	yes	Anti IL1
13 ¹²	M	39	43	2	41	V377I/L234P	European		Anti IL1 Anti IL6 Anti TNF
14 ¹²	F	27	27	4	23	V377I/I268T	European	yes	No
15 ¹²	F	8	18	0.1	18	V377I/I268T	European	yes	No
16 ⁵	F	4	4	2	4	V377I/C152W	European		Anti IL1
17 ⁸	F	32	32	1	31	V377I/I268T	European	no	No
18 ⁸	M	42	42	3	39	G336S/V377I/S52N	European	no	No

19	F	62	70	1.5	70	V377I/I268T	Spanish	yes	No
20	M	13	33	1	32	N205D/G336S	Algeria	no	Anti IL6
Median		26.5	27		24				