



**HAL**  
open science

## **Sensory innervation of the human shoulder joint: the three bridges to break**

Pierre Laumonerie, Yoann Dalmas, Meagan E. Tibbo, Suzanne Robert, Marie Faruch, Patrick Chaynes, Nicolas Bonneville, Pierre Mansat

### **► To cite this version:**

Pierre Laumonerie, Yoann Dalmas, Meagan E. Tibbo, Suzanne Robert, Marie Faruch, et al.. Sensory innervation of the human shoulder joint: the three bridges to break. *Journal of Shoulder and Elbow Surgery*, 2020, 29, pp.e499 - e507. <10.1016/j.jse.2020.07.017>. <hal-03493300>

**HAL Id: hal-03493300**

**<https://hal.science/hal-03493300v1>**

Submitted on 21 Nov 2022

**HAL** is a multi-disciplinary open access archive for the deposit and dissemination of scientific research documents, whether they are published or not. The documents may come from teaching and research institutions in France or abroad, or from public or private research centers.

L'archive ouverte pluridisciplinaire **HAL**, est destinée au dépôt et à la diffusion de documents scientifiques de niveau recherche, publiés ou non, émanant des établissements d'enseignement et de recherche français ou étrangers, des laboratoires publics ou privés.



Distributed under a Creative Commons CC BY-NC 4.0 - Attribution - Non-commercial use - International License

**LONG TITLE:** Sensory innervation of the human shoulder joint: the three bridges to break.

**SHORT TITLE:** Innervation of the shoulder joint

Pierre Laumonerie, MD MSc<sup>1,2</sup>

Yoann Dalmas, MD<sup>1</sup>

Meagan E Tibbo, MD<sup>3</sup>

Suzanne Robert, MD<sup>1</sup>

Marie Faruch, MD PhD<sup>4</sup>

Patrick Chaynes, MD PhD<sup>2</sup>

Nicolas Bonneville, MD PhD<sup>1</sup>

Pierre Mansat, MD PhD<sup>1</sup>

<sup>1</sup> Department of Orthopaedic surgery, Hôpital Pierre-Paul Riquet, Toulouse, 31059, France

<sup>2</sup> Anatomy Laboratory, Faculty of Medicine, Toulouse, 31062, France

<sup>3</sup> Department of Orthopedic Surgery, Mayo Clinic, Rochester, MN, 55905, USA

<sup>4</sup> Department of Radiology, Hôpital Pierre-Paul-Riquet,, Toulouse, 31059, France

**To whom correspondence should be addressed (corresponding author):**

Pierre Laumonerie, MD, MSc

Mail: Place du Docteur Baylac, Toulouse, 31059, France

Email: laumonerie.pierre@hotmail.fr

No institutional review board approval was required for this literature review.

**DISCLOSURES.** The authors report no conflicts of interest with respect the materials or methods used in this study or the findings specified herein.

1 **Sensory Innervation of the Human Shoulder Joint: the Three**  
2 **Bridges to Break. A systematic review**

3

4 **ABSTRACT**

5 **BACKGROUND.** Painful shoulders (PS) create a substantial socioeconomic burden and  
6 significant diagnostic challenge for shoulder surgeons. Consensus with respect to the anatomic  
7 location of sensory nerve branches is lacking. The aim of this literature review was to establish  
8 consensus with respect to the anatomic features of the articular branches (AB) (1) innervating  
9 the shoulder joint, and (2) the distribution of sensory receptors about its capsule and bursae.

10 **MATERIALS & METHODS.** Four electronic databases were queried, between January 1945  
11 and June 2019. Thirty original articles providing a detailed description of the distribution of  
12 sensory receptors about the shoulder joint capsule (13) and its articular branches (22) were  
13 reviewed.

14 **RESULTS.** The suprascapular, lateral pectoral, axillary, and lower subscapular nerves were  
15 found to provide AB to the shoulder joint. The highest density of nociceptors was found in the  
16 sub-acromial bursa. The highest density of mechanoreceptors was identified within the  
17 insertion of the glenohumeral ligaments. The most frequently identified innervation pattern was  
18 comprised of three nerve bridges (consisting of AB from suprascapular, axillary, and lateral  
19 pectoral nerves) connecting the trigger and the identified pain generators areas rich in  
20 nociceptors.

21 **CONCLUSION.** Current literature supports the presence of a common sensory innervation  
22 pattern for the human shoulder joint. Anatomic studies have demonstrated that the most  
23 common parent nerves supplying AB to the shoulder joint are the suprascapular, lateral

24 pectoral, and axillary nerves. Further studies are needed to assess both the safety and efficacy  
25 of selective denervation of the PS, while limiting the loss of proprioceptive function.

26 **LEVEL OF EVIDENCE:** Anatomy Study; Literature Review

27 **KEYWORDS:** Anatomy ; denervation ; pain ; shoulder joint; joint innervation

28

29 Painful shoulders (PS) create a substantial socioeconomic burden and significant diagnostic  
30 challenge for shoulder surgeons<sup>9, 25, 32, 50, 53</sup>. Almost 20% of the general population suffers  
31 from shoulder pain in their lifetime, making it the third most common musculoskeletal  
32 complaint<sup>15, 25</sup>. Painful shoulders also lead to impairments in patients' ability to work or  
33 perform activities of daily living<sup>20</sup>. Management of PS has been estimated to account for 4.5  
34 million physician visits and \$3 billion (£2.3bn; €2.6bn) in financial burden each year in the US  
35 alone<sup>32, 53</sup>. Ketola et al<sup>27</sup> reported that up to 20% of patients had persistently PS after  
36 subacromial surgery, and no significant benefit has been demonstrated following subacromial  
37 decompression for PS<sup>6, 38</sup>.

38 Prior reports have found that the highest density of nociceptors in the shoulder lies in  
39 the anterosuperior portion of subacromial bursa<sup>19, 21, 24, 45</sup>. With this information in mind,  
40 local nerve blocks<sup>37, 41, 42, 43</sup> and stimulation systems<sup>57</sup> have been trialed for the treatment of  
41 transient PS. More permanent techniques, including partial anterior shoulder denervation,  
42 involving the articular branches (AB) of the lateral pectoral nerve (LPN) has been  
43 demonstrated to provide pain relief in 92% of patients with persistently PS<sup>10, 11</sup>. Despite the  
44 success of this series, recent anatomic studies have demonstrated that several different parent  
45 nerves contribute to nociceptive shoulder innervation<sup>31, 48</sup>. Therefore, one might reasonably  
46 advocate for a denervation strategy that addresses all parent nerves (suprascapular, axillary,  
47 LPN) in an effort to completely eliminate persistent shoulder pain<sup>11</sup>.

48 Even with the recently published anatomic studies, there continues to be a lack of  
49 consensus with respect to the anatomic location of AB about the shoulder. Furthermore, the  
50 distribution and course of these branches does not seem to be reproducible<sup>31</sup>. We hypothesize  
51 that the efficiency of shoulder denervation could be improved once a consensus description of  
52 the distribution of nociceptors and articular nerve branches has been defined.

53 The aim of this literature review was to establish consensus with respect to (1) the  
54 anatomic features of the AB innervating the shoulder joint, and (2) the distribution of sensory  
55 receptors about its capsule and bursae.

56

## 57 **MATERIALS AND METHODS**

58 The aim of this study was to collect and review international literature describing the AB of the  
59 shoulder joint, as well as the sensory branches to its capsule, ligaments, and bursae. A  
60 literature search was performed using 5 different databases: Ovid Medline, Ovid Embase,  
61 Scopus, Web of Science, and Cochrane. Articles from 1945 – 2019 were included and the  
62 search was performed using the Medical Subject Headings (MeSH) and keywords. The search  
63 was limited to English language literature. The terms: shoulder joint, capsule, denervation,  
64 shoulder innervation, nerve, articular branch, sensory receptors, capsule, ligament and anatomy  
65 were used in various combinations with “AND” and “OR” to assist in review. Due to the  
66 limited historical timeframe that can be searched via these engines, references from the existing  
67 literature were also queried. The figures of dissections and descriptions of the course of each  
68 branch were also reviewed. A PRISMA flowchart was created to illustrate the inclusion and  
69 exclusion criteria (Fig. 1).

## 70 REVIEW OF LITERATURE

### 71 I. QUALITY OF STUDIES

72 Our electronic search yielded a total of 876 studies. After applying inclusion and exclusion  
73 criteria, articles underwent full-text evaluation. A total of 13 articles related to shoulder sensory  
74 receptors and 22 related to AB were included in the review. A summary of the search strategy is  
75 outlined in Figure 1.

### 76 II. SENSORY RECEPTORS

77 Sensory receptors include mechanoreceptors (ruffini, Pacinian, and golgi corpuscles) and  
78 nociceptors (free nerves endings). Both types were found in the shoulder joint capsule, its  
79 bursae, and its ligaments.

80 **CAPSULE.** Present literature, including immunohistochemical studies, would  
81 suggest that the density of sensory receptors about the shoulder varied based on anatomic  
82 location <sup>21</sup>. The highest density of noci- and mechanoreceptors has been identified in the  
83 antero- and posterosuperior portions of the glenohumeral capsule, and at the superior aspect of  
84 the capsulo-labral junction. Hashimoto et al <sup>21</sup> also recognized that the anteroinferior GH  
85 capsule is rich in mechanoreceptors. Witherspoon et al <sup>58</sup> further described this topographic  
86 map when they identified a mechanoreceptor gradient, with a concentration that peaked  
87 superficially and decreased with tissue depth. Finally, with respect to the labrum, the highest  
88 density of mechanoreceptors was found anteroinferiorly and at junction between the capsule as  
89 well as the glenoid rim <sup>58</sup>. No studies specifically addressed nociceptor distribution; however,  
90 multiple stated that these receptors were commonly found in the peripheral half of the glenoid  
91 labrum <sup>19-52</sup>.

92 **LIGAMENTS.** Guanche et al <sup>19</sup> note that the three parts of the anterior GH  
93 ligament are supplied by sensory receptors. They also found both mechano- and nociceptors in

94 three glenohumeral (GH) ligaments. The coracoacromial ligament, however, was described as  
95 aneural. Konttinen et al <sup>28</sup> demonstrated that connective tissue neighboring coracoacromial  
96 (CA) ligament was richly innervated with a high density of both mechano- and nociceptors.  
97 The density of mechanoreceptors was equal among all coracoclavicular ligaments and  
98 acromioclavicular joint ligaments <sup>52</sup>. Interestingly, nociceptor density in the coracoacromial and  
99 clavicular ligaments was increased in patients with rotator cuff disease <sup>47</sup>. Snow et al <sup>46</sup>  
100 reported on the presence of nociceptors and simultaneous absence of mechanoreceptors in the  
101 transverse humeral ligament (THL).

102           **SUBACROMIAL BURSA.** The SAB is the structure in the shoulder with the  
103 highest density of nociceptors <sup>26,27</sup>. In 1996, Ide et al <sup>24</sup> described three distinct areas within  
104 the SAB with the highest density of nociceptors. The aforementioned areas were the  
105 subdeltoid portion, the arch under the coracoacromial ligament, and greater tuberosity; the  
106 posteromedial portion of the SAB was found to be less densely innervated. Tomita et al <sup>48</sup> were  
107 the first to identify a positive correlation between the density of the sensory receptors in the  
108 SAB and the severity of rotator cuff disease. Mechanoreceptors have also been found under  
109 the CA ligament and about the great tuberosity <sup>19</sup>, albeit with decreased frequency.

110           **LONG HEAD OF BICEPS TENDON.** Guanche et al <sup>19</sup> reported on the  
111 presence of nociceptors in the long head of the biceps tendon (LHBT), the highest density  
112 being found at its proximal insertion. The density decreased progressively from proximal to  
113 distal until one reached the musculotendinous junction <sup>25</sup>. Mechanoreceptors have also been  
114 found in the central portion of the LHBT <sup>21</sup>.

115           **ACROMIOCLAVICULAR JOINT.** Vangness et al <sup>52</sup> noted the presence of  
116 mechanoreceptors in the acromioclavicular joint; however, no paper studying  
117 acromioclavicular joint nociceptors could be identified.

### 118 **III. NERVES AND ARTICULAR BRANCHES**

119 The articular nerve branches innervating the shoulder joint were found to arise from the  
120 suprascapular (SSN), LPN, lower subscapular (LSN), radial, and axillary (AN) nerves (Figure  
121 2; Tables 1).

122 **SUPRASCAPULAR NERVE.** Gardner <sup>16</sup> described a lateral AB of the SSN in 1948,  
123 which provided innervation to the coracoclavicular ligaments, and terminated its course in the  
124 superior aspect of the GH capsule. Aszmann et al <sup>4</sup> described this branch as a medial AB  
125 innervating coracoclavicular and coracohumeral ligaments and SAB. They also identified  
126 distal and lateral articular branches terminating within the posterior joint capsule. Vorster et al  
127 <sup>54</sup> provided data to support this medial AB course, and described the course of a new branch,  
128 splitting off from the parent nerve just proximal to the scapular neck, and running on the  
129 scapula deep to the supraspinatus before entering the infraspinatus near its tendon. Ebraheim  
130 et al <sup>13</sup> confirmed that the medial articular branch turns laterally along the base of the coracoid  
131 process and terminated in the acromioclavicular joint and SAB. They also described a second  
132 branch running laterally proximal to the infraspinous fossa, and entering the posterior aspect of  
133 the capsule deep to the infraspinatus. Eckmann et al <sup>14</sup> classified AB with respect to the  
134 spinoglenoid notch (superior and inferior). These ABs were reported to course laterally in the  
135 supraspinous (superior branch) and infraspinous (inferior branch) fossae of the scapula to  
136 innervate the posterior glenohumeral capsule, SAB, and posterior fascia of the head and neck  
137 of the humerus. The authors did not describe a discrete anatomic area of innervation in their  
138 manuscript <sup>14</sup>. In 2019, Laumonerie et al <sup>31</sup> described a lateral subacromial branch, which  
139 arose from the SSN distal to the suprascapular notch, and terminated over the supraspinatus  
140 muscle in the medial portion of the SAB and the acromial insertion of the acromioclavicular  
141 ligament. This study elucidated previously undescribed anatomy of the SSN and its 3 distinct  
142 AB courses: two subacromial branches (medial and lateral) and one posterior glenohumeral

143 branch to the shoulder joint. This arrangement, allowing for bipolar innervation of the SAB,  
144 was consistent with the bipolar distribution of the nociceptors in the medial and lateral part of  
145 the SAB described by Ide et al <sup>24</sup>.

146 **AXILLARY NERVE.** Gardner <sup>16</sup> initially described the AB as arising from 3 sites: the  
147 main trunk, as well as the anterior and posterior divisions. After the AN entered the  
148 quadrangular space, one or two AB take off from the main trunk. These AB traveled with the  
149 anterior circumflex humeral artery and coursed between the tendons of subscapularis and  
150 latissimus dorsi muscles. At the medial border of the humerus, the AB coursed superiorly,  
151 deep to the tendon of subscapularis <sup>49</sup>. Before they reached the capsule, each split into 2 main  
152 branches <sup>5</sup> which themselves ramified into small nerve bundles within the joint capsule. The  
153 medial branch mainly supplied the scapular aspect of the anteroinferior capsule and portions of  
154 the axillary recess, whereas the lateral branch innervated the humeral portion of the anterior  
155 capsule <sup>9</sup>. Duparc et al <sup>12</sup> described an additional 1 to 4 inconstant AB innervating the  
156 anteroinferior capsule. The first AB arised between the subscapularis muscle and the  
157 anterolateral border of the tendon of the long head of the triceps brachii while the other AB  
158 arised distal to it. The anterior division of the AN gave off the first AB which terminated in the  
159 anteroinferior capsule <sup>34, 60</sup>. Nasu et al <sup>36</sup> found an AB ascending on the lateral aspect of the  
160 humerus to terminate within the lateral edge of subacromial and subdeltoid bursae, and distal  
161 portion of the LHBT <sup>36, 45</sup>. Tran et al <sup>49</sup> later described 2 to 3 AB emerging from the anterior  
162 division that terminate in the transverse humeral ligament. After emerging from the  
163 quadrangular space, the posterior division of the AN gave off a branch to the teres minor from  
164 which 1 to 4 AB result <sup>14, 17</sup>. These AB entered the medial third of inferior GH ligament and  
165 divided into lateral and medial branches to innervate the posteroinferior capsule <sup>14, 17</sup>.

166 **LATERAL PECTORAL NERVE.** In 1948, Gardner described a small articular  
167 branch from the LPN innervating the anterosuperior capsule of the shoulder arising between

168 the coracoid process and the acromioclavicular joint <sup>16</sup>. Azsmann et al <sup>5</sup> detailed the course of  
169 the nerve. The LPN crossed the superomedial side of the coracoid process and sent small  
170 branches to the coracoclavicular ligament. Then the LPN coursed laterally and divided into 2  
171 main branches on the superior side of the coracoid process between the CA and  
172 coracoclavicular ligaments, respectively. The first branches supplied the anterior  
173 acromioclavicular joint; the second branch descended underneath the CA ligament to innervate  
174 the SAB <sup>2, 5, 14, 35 49</sup>. Nam et al <sup>35</sup> found that this second branch entered the shoulder after  
175 passing beneath the base of CA ligament; the entry point was identified at 4.6-cm medial to the  
176 lateral tip of the acromion. This AB innervated the anterosuperior portion of the GH capsule.  
177 In one case, Tran et al found that the LPN gave off another AB that terminated in the antero-  
178 inferior GH joint capsule <sup>49</sup>.

179 **LOWER SUBSCAPULAR NERVE.** In the aforementioned study, Gardner described  
180 a glenohumeral AB of the subscapular nerve arising from the posterior cord and descending  
181 obliquely across the ventral surface of the subscapularis muscle <sup>16</sup>. When it reached the tendon  
182 of this muscle, it divided into several smaller branches. One or two of those anastomosed with  
183 the branches from the axillary nerve to innervate the long head of biceps tendon. A few others  
184 pierced the tendon of the subscapularis muscle and entered the anterior capsule <sup>16,59</sup>. In 1996,  
185 Azsmann et al <sup>5</sup> described AB arising from the more lateral of the 3 lower subscapular nerve  
186 branches. Tran et al <sup>49</sup> detailed the course of these branches. The authors demonstrated that  
187 the most superior nerve to the subscapularis gave off 1–2 AB(s) which course with the sub-  
188 coracoid branch of the axillary artery, along the superior border of subscapularis, deep to the  
189 coracoid process. At the margin of the glenoid fossa, the AB coursed deep to subscapularis to  
190 innervate the anterosuperior quadrant of GH joint.

191           **RADIAL NERVE.** In the classic description, the radial nerves did not participate to the  
192 shoulder innervation <sup>5, 49</sup>. However, Gelber et al <sup>17</sup> found that the radial nerve's main trunk  
193 gave off a branch to the inferior GH ligament in 3.3% of shoulders.

194

## 195 **DISCUSSION**

196 The present literature reviewed summarized all described AB innervating the shoulder joint.  
197 The resulting frequency map of AB and sensory receptors provided an anatomical basis with  
198 which to design targeted denervation (Table 2, Figures 2-3).

199           There were several identifiable limitations of the reviewed literature. Providing a  
200 complete and detailed description of shoulder innervation has long been a challenge to the  
201 anatomist. For this reason, few studies have comprehensively described the anatomic features  
202 of each of the AB. This dearth of precise data provided a strong indication for a more precise  
203 and standardized description of the observations and measurements in dissection studies.  
204 However, the low number of specimens in each study (Table 1), the different methods of  
205 dissection, and their inherent high risk of elongation or section of the small AB could also  
206 contribute to the variability in the number and courses of described AB. Furthermore, the  
207 specific topography of the nociceptors about the GH capsule remained unknown; which limited  
208 our understanding of potential pain generators <sup>20</sup>.

209           Innervation of the shoulder joint was provided by the SSN, AN, LPN, and LSS (Figure  
210 3; Table 2); which is in accordance with the Hilton's law <sup>22</sup>. The SSN was found to be the  
211 greatest contributor to overall shoulder innervation <sup>31</sup>. It was found to provide sensory  
212 innervation to the posterior GH capsule, SAB, CA and acromioclavicular ligaments <sup>30</sup>. The  
213 AN was also found to innervate smaller areas involving the inferior portion of the anterior and  
214 posterior GH capsule <sup>48</sup>. The innervation pattern of the anterior shoulder joint was found to be

215 quite a bit more complex (Figure 2; Table 2). While the medial portion was found to be  
216 primarily innervated by muscular branches of LSN<sup>15, 49, 59</sup>, the lateral aspect of the capsule is  
217 supplied by AB arising directly from the AN<sup>36</sup>. The LPN also innervated the anterosuperior  
218 quadrant of the shoulder including the anterior edge of the SAB, the CA ligaments, and the GH  
219 capsule<sup>4, 16, 35</sup>.

220 Previous studies describing the neuroanatomical distribution of sensory receptors  
221 highlighted the proprioceptive role of the capsule and ligaments about the GH joint<sup>17, 19, 21, 28</sup>.  
222 The mechanoreceptors were most concentrated at the medial and lateral insertions of the  
223 anterior capsule, with relative scarcity of these receptors in the capsule's mid region<sup>19, 21, 29</sup>.  
224 Our review found that the receptor distribution also highlighted the important role that the  
225 LHBT, labrum, and inferomedial capsule play in shoulder stability, specifically with respect to  
226 the musculo-ligamentous protective reflex<sup>19, 29, 39</sup>. Nociceptors are primarily identified in the  
227 superior quadrant of the shoulder including the SAB, GH, CA and coracoclavicular ligaments,  
228 and the proximal portion of the LHBT (and the THL)<sup>19, 24, 29, 45</sup>. The SAB is the area of  
229 densest, tripolar nociceptive innervation<sup>45</sup>. These three nociceptive poles may correspond to  
230 the location of the lateral/medial subacromial branches of the SSN (ie lateral and medial poles)  
231 and to the AB of the LPN (anterior pole)<sup>24</sup>; fine AB from AN may also participate to the  
232 innervation lateral pole of the SAB<sup>36, 45</sup>.

233 Dellon et al<sup>10, 11</sup> previously proposed a partial anterior shoulder denervation involving  
234 the AB of LPN via a single incision over the coracoid for patients with anterosuperior PS. In a  
235 clinical series of 12 patients published in 2004, the authors<sup>10, 11</sup> reported a mean decrease in  
236 VAS pain scores from 8.5 to 1.8, in addition to an absence of short-term complications.  
237 However, Wilhlem<sup>56</sup> pointed out that innervation of the antero-superior quadrant of the  
238 shoulder is complex and cannot be reduced to the LPN alone. The subacromial branches from  
239 SSN and the fine ramifications from the AN to the LHBT (and the THL) and SAB have a well-

240 established, reproducible course within the most nociceptor-rich portion of the shoulder <sup>31, 36</sup>.  
241 Total shoulder denervation is unrealistic as almost all of the AB innervating the capsule are too  
242 fine to be identified <sup>5, 16, 58</sup>. Given the data summarized in this review, selective shoulder  
243 denervation with a focus on branches of the LPN, SSN, and AN would be most feasible and  
244 most likely to provide clinically relevant pain relief.

245

## 246 **LESSONS LEARNED**

247 Data summarized herein has allowed for identification of anatomic pain generators, defined as  
248 those areas with the highest nociceptive density, including the SAB, CA and coracoclavicular  
249 ligaments, LHBT, and THL. It also demonstrated that these pain generators were innervated  
250 by the same nerves that innervated anatomic regions at particularly high risk of injury (rotator  
251 cuff and GH joint): the SSN, LPN, and AN (Figure 3). Tomita et al <sup>48</sup> and Tamai et al's <sup>47</sup>  
252 studies also demonstrated an increasing density of nociceptors in the SAB and CA ligaments in  
253 patients with rotator cuff injuries. Based on their findings, as well as the reviewed literature,  
254 we propose the existence of a “nerve bridge” principle (Figure 4). We posit that these nerves  
255 may transmit stimulation from the injured trigger areas to areas rich in nociceptors there by  
256 creating (or nociceptor sensitization) secondary pain sites away from the primary injured  
257 structure <sup>18, 28, 29</sup>. This may explain typical clinical presentations of patient's with rotator cuff  
258 tears who present with pain over the CA ligament. Selective denervation would ideally spare  
259 the medial and lateral insertions of the GH capsule where the majority of mechanical receptors  
260 are located as these receptors participate in dynamic stabilization via the musculo-ligamentous  
261 protective reflex <sup>19, 29, 39</sup>. Overly aggressive denervation of the GH capsule and ligaments  
262 could, therefore, worsen instability and/ or accelerate degenerative arthritis <sup>19, 29, 39</sup>.

263

264 **FUTURE DIRECTIONS**

265 The concept of nerve connectivity between pain generator areas and areas rich in nociceptors,  
266 as described above, leads us to believe that “*Breaking the three nerve bridges*” may be a  
267 solution to treat persistently PS (Figure 4). The pain generators and their parent nerves (AN,  
268 LPN, SSN) should be the target of treatment as well as the injured trigger areas (i.e. rotator cuff  
269 or GH joint). A selective denervation focused on the nociceptive branches arising from the  
270 SSN, LPN and AN could neutralize the pain generator areas: SAB, AC and coracoclavicular  
271 ligaments, and the LPB. Furthermore, this technique would maintain the integrity of  
272 mechanoreceptors primarily located in the anterior capsule and GH ligaments<sup>19, 29, 39</sup>. This  
273 selective denervation could be considered as a complimentary treatment strategy, or alternative,  
274 to currently utilized arthroscopic rotator cuff repair or Latarjet procedure<sup>7, 30</sup>.

275

276 **CONCLUSION**

277 The SSN, LPN, AN, and LSN were found to supply AB to the shoulder joint. The highest  
278 density of nociceptors and mechanoreceptors was identified in SAB and anterior GH  
279 capsule/ligaments, respectively. Further studies are needed to assess both the safety and  
280 efficacy of selective denervation of the PS, while limiting the loss of proprioceptive function.

281

282 **REFERENCES**

- 283 1. Ajmani ML. The cutaneous branch of the human suprascapular nerve. J Anat. 1994;  
284 185:439–42.
- 285 2. Akita K, Kawashima T, Shimokawa T, Sato K, Sato T. Cutaneous nerve to the subacromial  
286 region originating from the lateral pectoral nerve. Ann Anat. 2002;184:15–9. doi:  
287 10.1016/S0940-9602(02)80026-7

- 288 3. Alpantaki K. Sympathetic and Sensory Neural Elements in the Tendon of the Long Head of  
289 the Biceps. *J Bone Joint Surg Am.* 2005; 87:1580. doi: 10.2106/JBJS.D.02840
- 290 4. Aszmann O, Dellon A. The Internal Topography of the Axillary Nerve: An Anatomic and  
291 Histologic Study as it Relates to Microsurgery. *J Reconstr Microsurg.* 1996; 12:359-63.
- 292 5. Aszmann OC, Dellon AL, Birely BT, McFarland EG. Innervation of the Human Shoulder  
293 Joint and Its Implications for Surgery. *Clin Orthop Relat Res.* 1996; 330:202–7.
- 294 6. Beard DJ, Rees JL, Cook JA, Rombach I, Cooper C, Merritt N, et al. Arthroscopic  
295 subacromial decompression for subacromial shoulder pain (CSAW): a multicentre, pragmatic,  
296 parallel group, placebo-controlled, three-group, randomised surgical trial. *The Lancet.* 2018;  
297 391:329–38. doi: 10.1016/S0140-6736(17)32457-1
- 298 7. Burkhart SS, Lo IKY. Arthroscopic Rotator Cuff Repair. *J Am Acad Orthop Surg.* 2006;  
299 14:333–46. doi: 10.5435/00124635-200606000-00003
- 300 8. Chillemi C, Petrozza V, Franceschini V, Garro L, Pacchiarotti A, Porta N, et al. The role of  
301 tendon and subacromial bursa in rotator cuff tear pain: a clinical and histopathological study.  
302 *Knee Surg Sports Traumatol Arthrosc.* 2016; 24:3779–86. doi: 10.1007/s00167-015-3650-4
- 303 9. Dean BJB, Gwilym SE, Carr AJ. Why does my shoulder hurt? A review of the  
304 neuroanatomical and biochemical basis of shoulder pain. *Br J Sports Med.* 2013; 47:1095–104.  
305 doi: 10.1136/bjsports-2012-091492
- 306 10. Dellon AL. Partial joint denervation I: wrist, shoulder, and elbow. *Plast Reconstr Surg.*  
307 2009;123:197-207. doi:10.1097/PRS.0b013e31818cc23f
- 308 11. Dellon AL. Shoulder Denervation. In: *Joint Denervation: Anatomic Atlas of Surgical*  
309 *Techniques.* Springer Nature; 2019:107-132. doi:10.1007/978-3-030-05538-7\_8
- 310
- 311 12. Duparc F, Bocquet G, Simonet J, Freger P. Anatomical basis of the variable aspects of  
312 injuries of the axillary nerve (excluding the terminal branches in the deltoid muscle). *Surg*  
313 *Radiol Anat.* 1997;19:127–32.
- 314 13. Ebraheim NA, Whitehead JL, Alla SR, Moral MZ, Castillo S, McCollough AL, et al. The  
315 suprascapular nerve and its articular branch to the acromioclavicular joint: an anatomic study.  
316 *Journal of Shoulder and Elbow Surgery.* 2011; 20:e13–17. doi: 10.1016/j.jse.2010.09.004t

- 317 14. Eckmann MS, Bickelhaupt B, FehI J, Benfield JA, Curley J, Rahimi O, et al. Cadaveric  
318 Study of the Articular Branches of the Shoulder Joint. *Reg Anesth Pain Med.* 2017; 42:564–70.  
319 doi: 10.1097/AAP.0000000000000652
- 320 15. Fish DE, Gerstman BA, Lin V. Evaluation of the Patient with Neck Versus Shoulder Pain.  
321 *Phys Med Rehabil Clin N Am.* 2011; 22:395–10. doi: 10.1016/j.pmr.2011.03.009
- 322 16. Gardner E. The innervation of the shoulder joint. *Anat Rec.* 1948; 102:1–18.
- 323 17. Gelber PE, Reina F, Monllau JC, Yema P, Rodriguez A, Caceres E. Innervation patterns of  
324 the inferior glenohumeral ligament: Anatomical and biomechanical relevance. *Clin Anat.* 2006;  
325 19:304–11. doi: 10.1002/ca.20172
- 326 18. Gold MS, Gebhart GF. Nociceptor sensitization in pain pathogenesis. *Nat Med.* 2010;  
327 16:1248–57. doi: 10.1038/nm.2235
- 328 19. Guanche CA, Noble J, Solomonow M, Wink CS. Periarticular neural elements in the  
329 shoulder joint. *Orthopedics.* 1999; 22:615–7.
- 330 20. Harkness EF. Mechanical and psychosocial factors predict new onset shoulder pain: a  
331 prospective cohort study of newly employed workers. *Occup Environ Med.* 2003;60:850–7.  
332 doi: 10.1136/oem.60.11.850
- 333 21. Hashimoto T, Hamada T, Sasaguri Y, Suzuki K. Immunohistochemical approach for the  
334 investigation of nerve distribution in the shoulder joint capsule. *Clin Orthop Relat Res.* 1994;  
335 273–282.
- 336 22. Hébert-Blouin M-N, Shane Tubbs R, Carmichael SW, Spinner RJ. Hilton’s law revisited:  
337 Hilton’s Law Revisited. *Clin Anat.* 2014; 27:548–55. doi: 10.1002/ca.22348.
- 338 23. Horiguchi M. The cutaneous branch of some human suprascapular nerves. *J Anat.* 1980;  
339 130:191–95.
- 340 24. Ide K, Shirai Y, Ito H, Ito H. Sensory nerve supply in the human subacromial bursa. *J*  
341 *Shoulder Elbow Surg.* 1996; 5:371–82.
- 342 25. Juel NG, Natvig B. Shoulder diagnoses in secondary care, a one year cohort. *BMC*  
343 *Musculoskelet Disord.* 2014; 15:89. doi: 10.1186/1471-2474-15-89

- 344 26. Kennedy MS, Nicholson HD, Woodley SJ. Clinical anatomy of the subacromial and related  
345 shoulder bursae: A review of the literature: The Subacromial and Related Shoulder Bursae.  
346 *Clin Anat.* 2017; 30:213–26. doi: 10.1002/ca.22823
- 347 27. Ketola S, Lehtinen J, Rousi T, Nissinen M, Huhtala H, Arnala I. Which patients do not  
348 recover from shoulder impingement syndrome, either with operative treatment or with  
349 nonoperative treatment? Subgroup analysis involving 140 patients at 2 and 5 years in a  
350 randomized study. *Bone Joint Res.* 2013; 2:132-9. doi: 10.1302/2046-3758.27.2000163.
- 351 28. Konttinen YT. Innervation of the Joint and Role of Neuropeptides. *Ann N Y Acad Sci.*  
352 2006; 1069:149–54. doi: 10.1196/annals.1351.013
- 353 29. Konttinen YT, Santavirta S, Paavolainen P, Antti-Poika I, Tiainen T, Nordström D, et al.  
354 Immunoreactive neuropeptide nerves in ligamentous tissue in chronic shoulder pain. *Arch*  
355 *Orthop Trauma Surg.* 1992; 111:341–4.
- 356 30. Lafosse L, Boyle S, Gutierrez-Aramberri M, Shah A, Meller R. Arthroscopic Latarjet  
357 Procedure. *Orthop Clin North Am.* 2010; 41:393–405. doi: 10.1016/j.ocl.2010.02.004
- 358 31. Laumonerie P, Blasco L, Tibbo ME, Bonneville N, Labrousse M, Chaynes P, et al.  
359 Sensory innervation of the subacromial bursa by the distal suprascapular nerve: a new  
360 description of its anatomic distribution. *J Shoulder Elbow Surg.* 2019; 28:1788–94. doi:  
361 10.1016/j.jse.2019.02.016
- 362 32. Linsell L, Dawson J, Zondervan K, Rose P, Randall T, Fitzpatrick R, et al. Prevalence and  
363 incidence of adults consulting for shoulder conditions in UK primary care; patterns of  
364 diagnosis and referral. *Rheumatology.* 2006; 45:215–21. doi: 10.1093/rheumatology/kei139
- 365 33. Loomer R, Graham B. Anatomy of the axillary nerve and its relation to inferior capsular  
366 shift. *Clin. Orthop. Relat. Res.* 1989; 100–5.
- 367 34. Loukas M, Grabska J, Tubbs RS, Apaydin N, Jordan R. Mapping the axillary nerve within  
368 the deltoid muscle. *Surg Radiol Anat.* 2009; 31:43–7. doi: 10.1007/s00276-008-0409-3
- 369 35. Nam Y-S, Panchal K, Kim I-B, Ji J-H, Park M-G, Park S-R. Anatomical study of the  
370 articular branch of the lateral pectoral nerve to the shoulder joint. *Knee Surg Sports Traumatol*  
371 *Arthrosc.* 2016; 24:3820–7. doi: 10.1007/s00167-015-3703-8

- 372 36. Nasu H, Nimura A, Yamaguchi K, Akita K. Distribution of the axillary nerve to the  
373 subacromial bursa and the area around the long head of the biceps tendon. *Knee Surg Sports*  
374 *Traumatol Arthrosc.* 2015; 23:2651–7. doi: 10.1007/s00167-014-3112-4
- 375 37. Neuts A, Stessel B, Wouters PF, Dierickx C, Cools W, Ory JP, et al. Selective  
376 Suprascapular and Axillary Nerve Block Versus Interscalene Plexus Block for Pain Control  
377 After Arthroscopic Shoulder Surgery: A Noninferiority Randomized Parallel-Controlled  
378 Clinical Trial. *Reg Anesth Pain Med.* 2018; 43:738-44. doi: 10.1097/AAP.0000000000000777
- 379 38. Paavola M, Malmivaara A, Taimela S, Kanto K, Inkinen J, Kalske J, et al. Subacromial  
380 decompression versus diagnostic arthroscopy for shoulder impingement: randomised, placebo  
381 surgery controlled clinical trial. *BMJ.* 2018; 362:k2860. doi: 10.1136/bmj.k2860
- 382 39. Petrie S, Collins JG, Solomonow M, Wink C, Chuinard R, D'Ambrosia R.  
383 Mechanoreceptors in the human elbow ligaments. *J Hand Surg Am.* 1998; 23:512–8.
- 384 40. Porzionato A, Macchi V, Stecco C, Loukas M, Tubbs RS, De Caro R. Surgical anatomy of  
385 the pectoral nerves and the pectoral musculature. *Clin Anat.* 2012; 25:559–75. doi:  
386 10.1002/ca.21301
- 387 41. Price D. Axillary (Circumflex) Nerve Block Used in Association With Suprascapular  
388 Nerve Block for the Control of Pain Following Total Shoulder Joint Replacement. *Reg Anesth*  
389 *Pain Med.* 2008; 33:280–1. doi: 10.1016/j.rapm.2007.12.008
- 390 42. Price D. Optimizing the Combined Suprascapular and Axillary Nerve (SSAX) Block. *Reg*  
391 *Anesth Pain Med.* 2017;42:122. doi: 10.1097/AAP.0000000000000518
- 392 43. Price DJ. The Shoulder Block: A New Alternative to Interscalene Brachial Plexus  
393 Blockade for the Control of Postoperative Shoulder Pain. *Anaesth Intensive Care.* 2007;  
394 35:575–81. doi: 10.1177/0310057X0703500418
- 395 44. Seo CM, Kim K, Jeon A, Uhm CS, Lee JH, Han SH. Clinical Anatomy for the Innervated  
396 Pattern and Boundary of the Subdeltoid Bursa. *Biomed Res Int.* 2018; 2018:1–6. doi:  
397 10.1155/2018/4535031
- 398 45. Soifer TB, Levy HJ, Miller Soifer F, Kleinbart F, Vigorita V, Bryk E. Neurohistology of  
399 the subacromial space. *Arthroscopy.* 1996; 12:182–6.

- 400 46. Snow BJ, Narvy SJ, Omid R, Atkinson RD, Vangsness CT. Anatomy and Histology of the  
401 Transverse Humeral Ligament. *Orthopedics*. 2013; 36:e1295–8. doi: 10.1097/00003086-  
402 200004000-00015
- 403 47. Tamai M, Okajima S, Fushiki S, Hirasawa Y. Quantitative Analysis of Neural Distribution  
404 in Human Coracoacromial Ligaments. *Clin Orthop Relat Res*. 2000; 373:125–34.
- 405 48. Tomita Y, Ozaki J, Sakurai G et al. Neurohistology of the subacromial bursa in rotator cuff  
406 tear. *J Orthop Sci* 1997; 2:295-300.
- 407 49. Tran J, Peng PWH, Agur AMR. Anatomical study of the innervation of glenohumeral and  
408 acromioclavicular joint capsules: implications for image-guided intervention. *Reg Anesth Pain*  
409 *Med*. 2019; 44:452–8. doi: 10.1136/rapm-2018-100152
- 410 50. Urwin M, Symmons D, Allison T, Brammah T, Busby H, Roxby M, et al. Estimating the  
411 burden of musculoskeletal disorders in the community: the comparative prevalence of  
412 symptoms at different anatomical sites, and the relation to social deprivation. *Annals of the*  
413 *Rheumatic Diseases*. 1998;57:649–55.
- 414 51. Uz A, Apaydin N, Bozkurt M, Elhan A. The anatomic branch pattern of the axillary nerve.  
415 *J Shoulder Elbow Surg*. 2007; 16:240–4. doi: 10.1016/j.jse.2006.05.003
- 416 52. Vangsness CT, Ennis M, Taylor JG, Atkinson R. Neural anatomy of the glenohumeral  
417 ligaments, labrum, and subacromial bursa. *Arthroscopy*. 1995;11:180–4.
- 418 53. Virta L, Joranger P, Brox JI, Eriksson R. Costs of shoulder pain and resource use in  
419 primary health care: a cost-of-illness study in Sweden. *BMC Musculoskelet Disord*. 2012;  
420 13:17. doi: 10.1186/1471-2474-13-17
- 421 54. Vorster W, Lange CPE, Briët RJP, Labuschagne BCJ, du Toit DF, Muller CJF, et al. The  
422 sensory branch distribution of the suprascapular nerve: An anatomic study. *J Shoulder Elbow*  
423 *Surg*. 2008; 17:500–2. doi: 10.1016/j.jse.2007.10.008
- 424 55. Wiegel M, Moriggl B, Schwarzkopf P, Petroff D, Reske AW. Anterior Suprascapular  
425 Nerve Block Versus Interscalene Brachial Plexus Block for Shoulder Surgery in the Outpatient  
426 Setting: A Randomized Controlled Patient- and Assessor-Blinded Trial. *Reg Anesth Pain Med*.  
427 2017; 42:310–8. doi: 10.1097/AAP.0000000000000573
- 428 56. Wilhelm A. Partial Joint Denervation: Wrist, Shoulder, and Elbow: Plastic and  
429 Reconstructive Surgery. 2010; 126:345–7. doi: 10.1097/PRS.0b013e3181dab5f3

- 430 57. Wilson RD, Bennett ME, Nguyen VQC, Bock WC, O'Dell MW, Watanabe TK, et al. Fully  
431 Implantable Peripheral Nerve Stimulation for Hemiplegic Shoulder Pain: A Multi-Site Case  
432 Series With Two-Year Follow-Up. *Neuromodulation*. 2018; 21:290–5. doi: 10.1111/ner.12726
- 433 58. Witherspoon JW, Smirnova IV, McIff TE. Neuroanatomical distribution of  
434 mechanoreceptors in the human cadaveric shoulder capsule and labrum. *J. Anat.* 2014;  
435 225:337–45. doi: 10.1111/joa.12215
- 436 59. Wrete M. The Sensory Pathways from the Shoulder Joint. *Journal of Neurosurgery*. 1949;  
437 6:351–60.
- 438 60. Zhao X, Hung LK, Zhang GM, Lao J. Applied Anatomy of the Axillary Nerve for  
439 Selective Neurotization of the Deltoid Muscle: *Clin Orthop Relat Res.* 2001; 390:244–51.

440

441

## 442 **FIGURES AND TABLES LEGEND**

443

444 **Table 1.** Summary of studies describing parent nerves which provide branches to the shoulder  
445 joint.

446 **Table 2.** Innervation of anatomic regions of the shoulder joint by parent nerves.

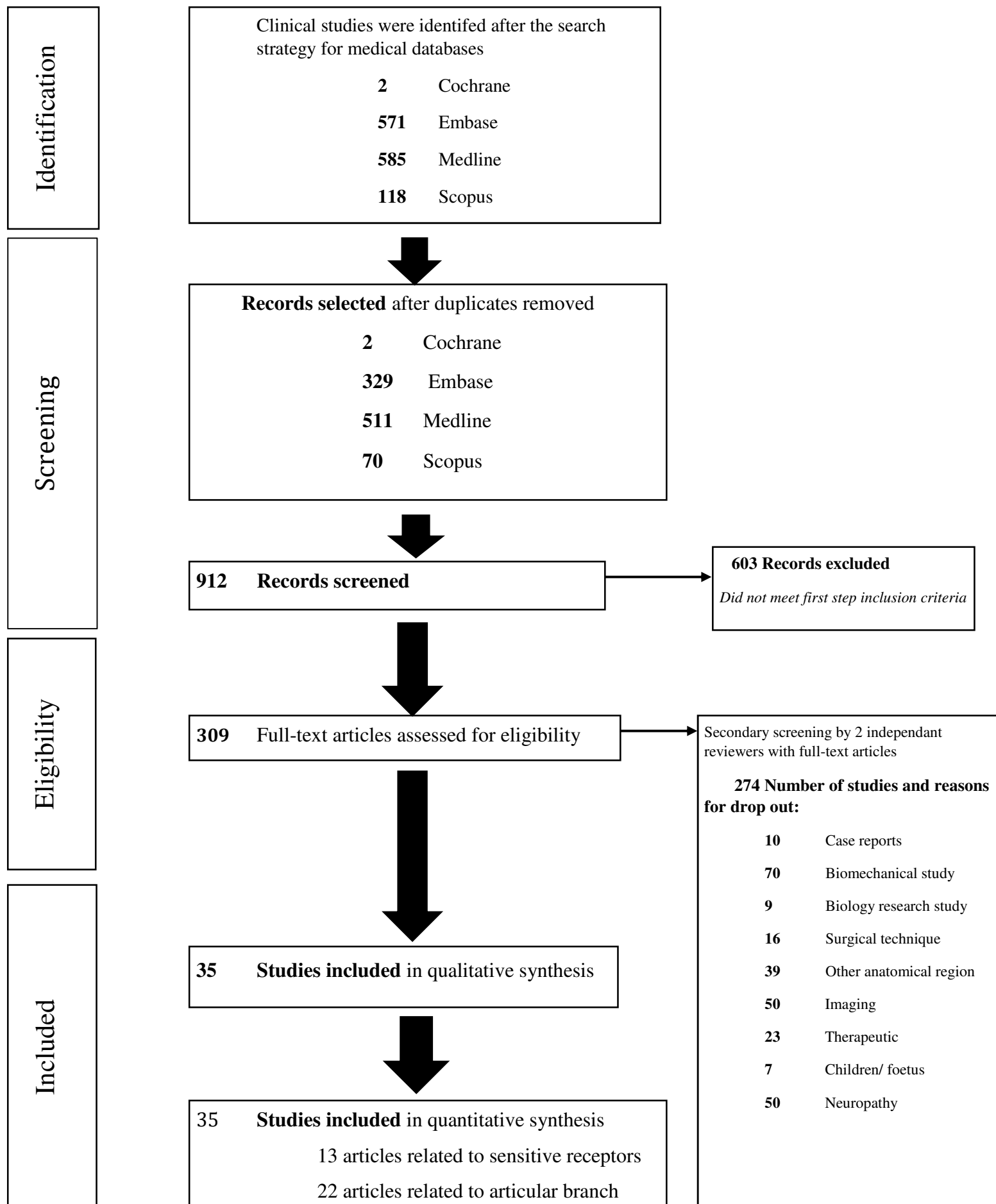
447 **Figure 1.** Summary of search strategy (Preferred Reporting Items for Systematic Reviews and  
448 Meta-Analyses-flow chart) for relevant studies on sensory innervation of the shoulder joint.

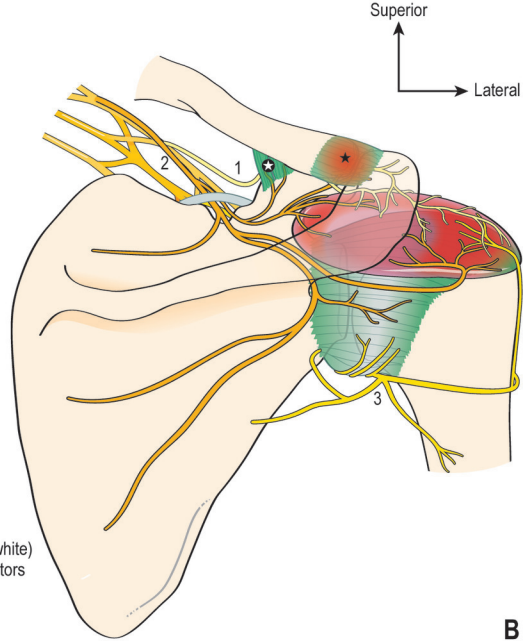
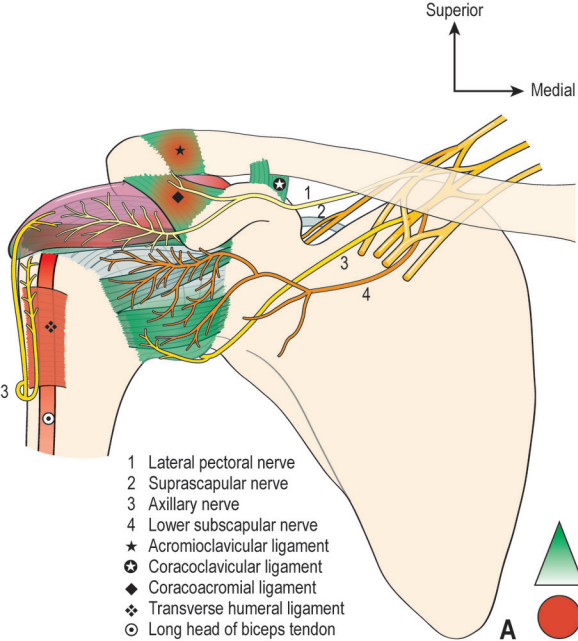
449 **Figure 2.** Schematic diagram of sensory innervation of the shoulder joint (A, anterior view ; B  
450 posterior view).

451 **Figure 3.** Summary of the innervation of quadrants of the shoulder joint.

452 **Figure 4.** The common innervation in the shoulder allowed painful diffusion from injured  
453 triggers (rotator cuff, gleno-humeral joint) to the identified pain generators (subacromial bursa,  
454 the coracoacromial ligament, and the LHTB) areas by the three nerve bridges (Axillary,  
455 Suprascapular and Lateral pectoral nerves).

**Figure 1**



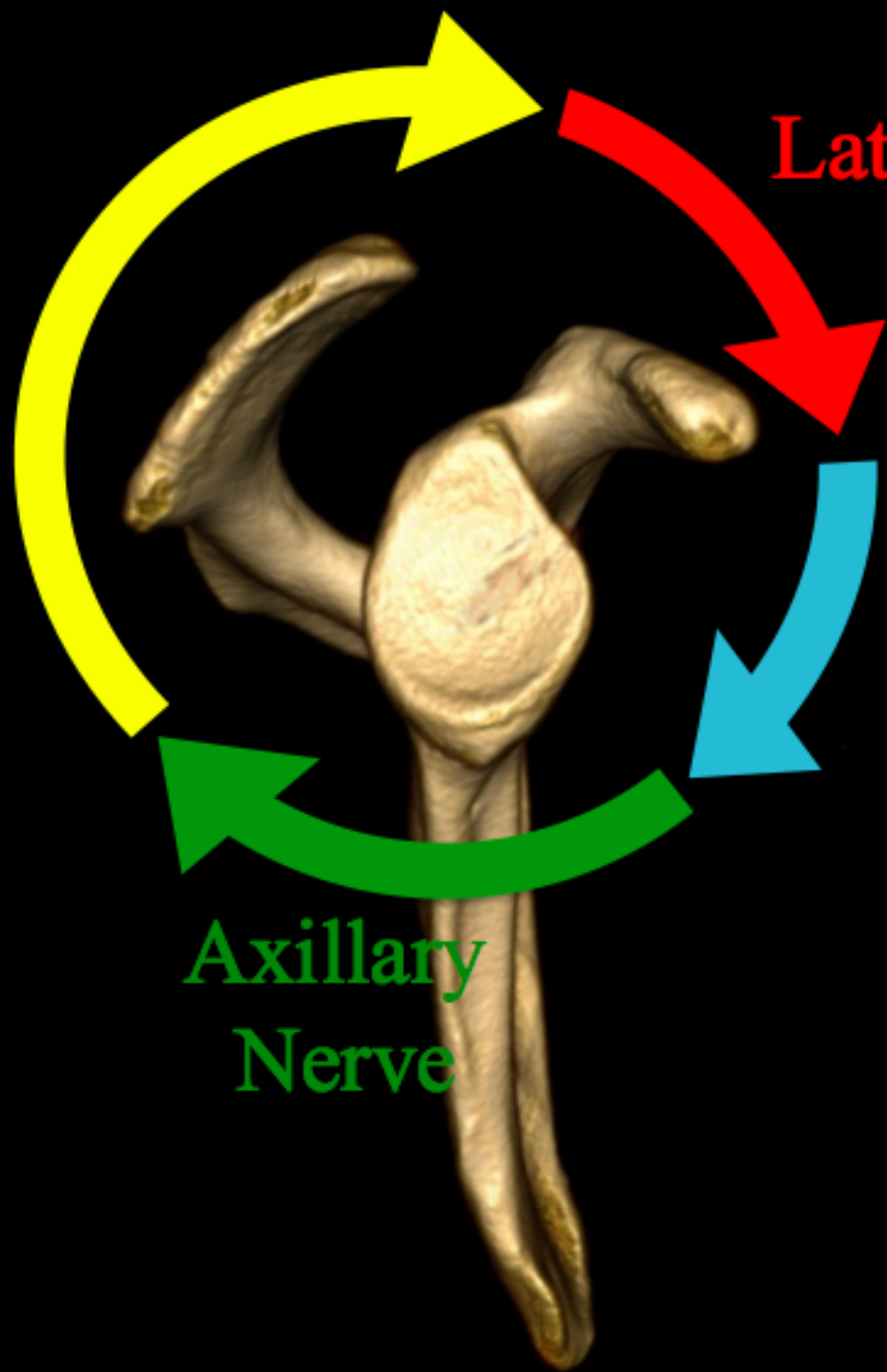

High (in green) to low (white)  
density of mechanoreceptors



High density areas  
of nociceptor

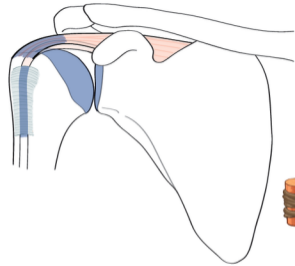
**Suprascapular  
nerve**



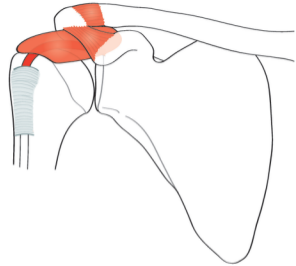
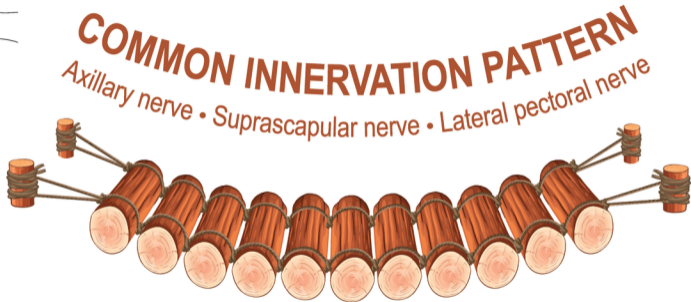**Lateral pectoral  
nerve**

**Lower Subscapular  
nerve**

**Axillary  
Nerve**



**TRIGGER  
AREAS**



**PAIN GENERATOR  
AREAS**

**Table 1**

Author and year	Nb shoulders	Axillary nerve	Suprascapular nerve	Lower scapular nerve	Lateral pectoral nerve
Gardner, 1948 [15]	7	X	X	X	X
Wrete, 1949 [58]	5	X	X	X	
Horiguchi, 1980 [22]	6		X		
Loomer, 1988 [32]	12	X			
Ajmani, 1994 [1]	NA		X		
Azsmann et al., 1996 [5]	25	X	X	X	X
Duparc et al., 1997 [11]	32	X			
Zhao et al., 2001 [59]	40	X			
Akita et al., 2002 [2]	125				X
Gelber et al., 2006 [16]	61	X	X		
Uz et al., 2007 [50]	30	X			
Loukas et al., 2008 [33]	100	X			
Vorster et al., 2008 [53]	31		X		
Porzionato et al., 2011 [39]	802 <sup>R</sup>				X
Ebraheim et al., 2011 [12]	12		X		
Dean, 2013 [9]	NA	X	X	X	X
Nasu et al., 2014 [35]	20	X	X		
Nam et al., 2015 [34]	43				X
Eckmann et al., 2017 [13]	21	X	X		X
Seo et al., 2018 [43]	18	X			
Laumonerie et al., 2019 [30]	37		X		
Tran, 2019 [48]	15	X	X	X	X

<sup>R</sup>, Literature review; NA, Not available

**Table 2**

	ANTERIOR CAPSULE		POSTERIOR CAPSULE		SUBACROMIAL BURSA		SUBDELTOID BURSA	LONG HEAD OF BICEPS TENDON	ACROMIO CLAVICULAR JOINT
	Superior	Inferior	Superior	Inferior	Anterior	Posterior			
<b>Axillary nerve</b>		*		*	*	*	*	*	
<b>Supra scapular nerve</b>			*		*	*			*
<b>Lower subscapular nerve</b>	*							*	
<b>Lateral pectoral nerve</b>	*	*			*				*

**Sup**, Superior ; **Inf**, inferior ; **Ant**, Anterior ; **Post**, Posterior ; **GH**, Glenohumeral ; **CA**, Coracoacromial ; **CCI**, Coracoclavicular ; **ACI**, Acromioclavicular