



HAL
open science

Extracorporeal Treatment with High Intensity Focused Ultrasound of an Incompetent Perforating Vein in a Patient with Active Venous Ulcers

Alfred Obermayer, Jean-François Aubry, Nesrine Barnat

► **To cite this version:**

Alfred Obermayer, Jean-François Aubry, Nesrine Barnat. Extracorporeal Treatment with High Intensity Focused Ultrasound of an Incompetent Perforating Vein in a Patient with Active Venous Ulcers. *EJVES Vascular Forum*, 2021, 50, pp.1 - 5. 10.1016/j.ejvsf.2020.11.005 . hal-03493278

HAL Id: hal-03493278

<https://hal.science/hal-03493278>

Submitted on 2 Jan 2023

HAL is a multi-disciplinary open access archive for the deposit and dissemination of scientific research documents, whether they are published or not. The documents may come from teaching and research institutions in France or abroad, or from public or private research centers.

L'archive ouverte pluridisciplinaire **HAL**, est destinée au dépôt et à la diffusion de documents scientifiques de niveau recherche, publiés ou non, émanant des établissements d'enseignement et de recherche français ou étrangers, des laboratoires publics ou privés.



Distributed under a Creative Commons Attribution - NonCommercial 4.0 International License

1 **CASE REPORT**

2 **Extracorporeal Treatment With High Intensity Focused Ultrasound of an Incompetent**
3 **Perforating Vein in a Patient With Active Venous Ulcers**

4
5 Alfred Obermayer ^a, Jean-François Aubry ^b and Nesrine Barnat ^{b,c,*}

6
7 ^a Institute for Functional Phlebosurgery, Karl Landsteiner Society, Melk, Austria

8 ^b Physics for Medicine Paris, INSERM, ESPCI Paris, CNRS, PSL Research University, Paris,
9 France

10 ^c Theraclion, Malakoff, France

11

12 *Corresponding author. 102 rue Etienne Dolet, 92240 Malakoff, France.

13 nesrine.barnat@theraclion.com (Nesrine Barnat).

14

15 **Introduction:** Endovenous techniques such as ultrasound guided foam sclerotherapy, thermal
16 methods, or glues are generally recommended to occlude incompetent veins. However, these
17 methods can be technically challenging and risky for patients with severe atrophic skin
18 disorders like lipodermatosclerosis or atrophie blanche. A non-invasive alternative method
19 can be high intensity focused ultrasound (HIFU), which has been shown to coagulate and
20 occlude veins successfully. This case report details ultrasound guided HIFU to occlude non-
21 invasively a refluxing perforator vein causing active ulcers.

22 **Report:** A 95-year-old man presented to the Institute for Functional Phlebology (Melk,
23 Austria) with painful recurrent ulcers in his left medial calf. His limb was scored C2,3,4a, b,6,
24 Ep, Ap, Pr,18 according to the Clinical, Etiologic, Anatomic and Pathophysiologic (CEAP)
25 classification. Ultrasound examination of his lower limb revealed a refluxing posterior tibial
26 perforating vein, measuring 2.7 mm in diameter at the level of the fascia. Extracorporeal
27 HIFU pulses were delivered on this vein with the Sonovein device (Theraclion, Malakoff,
28 France). Sonications were applied for eight seconds at a mean acoustic power of 80 W. The
29 patient was followed up for three months post-treatment and occlusion was evaluated by
30 duplex ultrasound. No complications occurred during the treatment or follow up. Three
31 months after the treatment, reflux was abolished and the two initially active ulcers healed.

32 **Discussion:** Although this is an early report, this study shows that HIFU can be successful in
33 ablation of incompetent perforator veins in the treatment of venous leg ulcers.
34

35 **Keywords:** High intensity focused ultrasound, Perforating vein, Thermal ablation, Vein wall
36 coagulation, Venous ulcer
37

38 INTRODUCTION

39 Current options for the treatment of incompetent perforating veins (IPVs) include minimally
40 invasive techniques like endovenous thermal ablation (EVTA) or surgical options.

41 Regardless of the technique used, occluding IPVs is technically challenging compared
42 with the ablation of the great saphenous vein (GSV).¹

43 While EVTA for GSV incompetence has a success rate of > 96%,¹ lower success rates
44 are reported for the ablation of IPVs (59% – 90%). These higher closer failures of perforating
45 veins are explained by the difficulties cannulating them.¹ Perforating veins are frequently
46 deep, tortuous, and located close to damaged and ulcerated skin.¹ An extracorporeal approach
47 using HIFU to treat an IPV causing active ulcers in an elderly patient is proposed.
48

49 CASE REPORT

50 A 95-year-old man presented with painful recurrent left leg ulcers after a six year ulcer free
51 period. The patient was in relatively good general health but had a medical history of prior
52 ischaemic stroke and coronary artery disease. In 2012, he had undergone a stripping of his left
53 GSV and simultaneous shave therapy with mesh graft transplantation to treat the initial ulcer.

54 The clinical examination revealed in the left medial calf two active ulcers located in an
55 area of severe lipodermatosclerosis, atrophie blanche, hyperpigmentation, and mild oedema
56 (Fig. 1A). Both ulcers were exuding, with diameters of 10 mm. The Clinical, Etiologic,
57 Anatomic and Pathophysiologic (CEAP) classification of his left limb was
58 C2,3,4a,b,6,Ep,Ap,Pr,18.

59 Before treatment, a detailed ultrasound examination of the left limb was performed
60 using a Terason scanner (Burlington, MA, USA).

61 Examination revealed a status postflush ligation and partial stripping of the GSV to
62 knee level without recurrence. No deep venous incompetence was observed. To identify the
63 origin of the venous leg ulcers, a “sourcing” technique described by Obermayer and Garzon
64 was performed.² This technique, carried out with the patient standing, consists of softly
65 compressing and releasing the ulcerated area and investigating, under duplex ultrasound, the
66 routes of venous reflux penetrating into the ulcer area.

67 A refluxing posterior tibial perforating vein at a distance of 18 cm from the floor and
68 with a systolic and diastolic outward flow > 1.5 seconds was identified as the source of the
69 local venous hypertension (Fig. 1B, C) feeding superficial varicose veins. A diameter of 2.7
70 mm was measured at the level of the fascia.

71 The patient was placed in the Trendelenburg position and was treated in an outpatient
72 setting.

73 A Sonovein device was used for the treatment. This ultrasound guided device
74 encompasses a motorised treatment head mounted on an articulated arm. The treatment head
75 (Fig. 2, right) is a removable part incorporating both an imaging transducer (7.5 MHz, 128
76 elements) and a therapy transducer (3 MHz, single element, diameter 56 mm, -6 dB focal spot
77 width 0.5 mm) that can treat target tissues located at least 10 mm under the skin.

78 The system operates in conjunction with a single use disposable kit called EPack (Fig.
79 3). A fluid filled balloon was fixed to the transducer to ensure acoustic coupling between the
80 transducer and the target. The coupling liquid was continuously circulated and cooled at 10°C
81 to prevent skin burns.

82 The treatment head was first manually positioned in the region of interest and then the
83 precise position was adjusted robotically (Fig. 4). To ensure the targeted vein was located at
84 least 10 mm below the skin, 8 mL 0.1% lidocaine was injected subcutaneously under
85 ultrasound guidance. This local anaesthesia was also performed to prevent pain and to
86 compress the vein mechanically, which increases energy deposition on the vein wall.³⁻⁵
87 Owing to the fragility of the skin and to avoid an infection, the injection was performed with a

88 21 G needle (0.80 × 120 mm; B Braun, Melsungen, Germany) inserted from dorsal, outside
89 the lesion.

90 Thirty-one eight second pulses were delivered to the IPV at a mean ± standard
91 deviation acoustic power 80 ± 21 W. Acoustic power was adjusted during the treatment
92 according to the appearance of hyperechoic regions on the ultrasound image.⁵ A minimal
93 pause time of 30 seconds was observed between each pulse to allow the skin to cool down.

94 After the procedure, a compression bandage was applied for seven days and the patient
95 returned to his normal activities.

96 Clinical follow up appointments were scheduled at seven days and three months post-
97 treatment.

98 A visual analogue pain score (from 0 to 10) was given to the patient before treatment,
99 at day seven post-treatment, and at three months. A patient satisfaction questionnaire was
100 additionally completed at the last clinical visit.

101 The patient initially reported a pain score of 3 before treatment and 0 on day seven and
102 three months post-treatment.

103 Seven days postoperatively, the vein was not occluded and the ulcers were still active,
104 but at three months the vein was occluded and the ulcers healed (Fig. 5B). The patient scored
105 the treatment as very satisfactory. No complications occurred during the treatment or during
106 the follow-up.

107 Approval was obtained to publish this case.

108

109 **DISCUSSION**

110 This article describes the first results of the treatment of IPVs with HIFU.

111 This technique, currently used for many clinical applications like the treatment of
112 benign and malignant solid tumours,⁶ uses high intensity focused beams to concentrate
113 acoustic energy into a small soft tissue volume. The focusing of a high-power acoustic beam
114 allows induction of high temperatures locally at the focus (approaching 100°C) producing a
115 localised tissue ablation.

116 Owing to the heat and for patient comfort, a small amount (8 mL) of anaesthetic was
117 injected before the sonications. The volume used was considerably less than the amount of
118 tumescent anaesthesia infiltrated around truncal veins during EVTA (> 250 mL).

119 The use of HIFU to occlude veins has been investigated in preclinical studies.^{3,7} In
120 particular, the ability of occluding veins of similar size (mean diameters of 2.0 – 4.8 mm) has

121 been demonstrated with the same device.³⁻⁵ Dedicated chronic *in vivo* experiments were
122 performed in a sheep model to assess the long term efficacy and safety of the procedure.⁴
123 Eighteen saphenous veins (mean diameter 3.2 mm) were exposed to pulses similar to those
124 delivered here (mean 84 W, eight seconds). Animals were followed up to 90 days post-
125 treatment and after completion of the follow up vein segments were harvested and assessed
126 microscopically. Histological findings revealed vein wall changes similar to the ones reported
127 after EVTA (vein wall coagulation and fibrosis). In a human study with a six week follow up,
128 Whiteley⁸ reported that the closure rates observed in five patients treated with the Sonovein
129 appeared to be as good as those after EVTA in the same short time with the major advantage
130 of being non-invasive. In the same study, HIFU was delivered to treat varicose veins, venous
131 leg ulcers, and other manifestations of venous reflux disease.⁸ The mechanisms through which
132 HIFU produces vascular occlusion are discussed in Barnat.⁵ Vascular occlusion is thought to
133 occur as a result of numerous contributing factors, including vein wall collagen coagulation
134 and endothelial damage. Transmural death of the cells in the vein wall may lead to permanent
135 closure of the targeted vein by fibrosis.⁸ Although EVTA has proven to be effective, these
136 methods can be arduous and risky as vein wall perforation may occur.⁹ With HIFU, as nothing
137 is inserted into the vein, infection and bleeding risks are minimal. HIFU can be particularly
138 interesting for patients with a risk of bleeding .⁸ Contrary to EVTA methods, the occlusion
139 does not seem to occur immediately but rather after a short delay of time (here, after seven
140 days).

141 This initial experience suggests that the Sonovein may be useful for ablation of
142 refluxing veins.

143 Although this technique is new, early results are encouraging, as illustrated by the
144 present case.

145

146 **CONFLICTS OF INTEREST**

147 Nesrine Barnat is an employee of Theraclion.

148

149 **FUNDING**

150 Research grant.

151

152 **REFERENCES**

153 1 Dillavou ED, Harlander-Locke M, Labropoulos N, Elias S, Ozsvath KJ. Current state of the

154 treatment of perforating veins. *J Vasc Surgery Venous Lymphat Disord* 2016;**4**:131–5.
155 2 Obermayer A, Garzon K. Identifying the source of superficial reflux in venous leg ulcers
156 using duplex ultrasound. *J Vasc Surg* 2010;**52**:1255–61.
157 3 Barnat N, Grisey A, Lecuelle B, Anquez J, Gerold B, Yon S, et al. Noninvasive vascular
158 occlusion with HIFU for venous insufficiency treatment: preclinical feasibility experience in
159 rabbits. *Phys Med Biol* 2019;**64**:12.
160 4 Barnat N, Grisey A, Gerold B, Yon S, Anquez J, Aubry J-F. Efficacy and safety assessment
161 of an ultrasound- based thermal treatment of varicose veins in a sheep model. *Int J Hyperth*
162 2020;**37**:231–44.
163 5 Barnat N. Design and validation of a non-invasive method for the treatment of varicose
164 veins using high-intensity focused ultrasound. Doctoral dissertation, Paris Sciences et Lettres,
165 2019.
166 6 Kennedy JE. High-intensity focused ultrasound in the treatment of solid tumours. *Nat Rev*
167 *Cancer* 2005;**5**:321–7.
168 7 Zhou Y, Kargl SG, Hwang JH. The effect of the scanning pathway in high-intensity focused
169 ultrasound therapy on lesion production. *Ultrasound Med Biol* 2011;**37**:1457–68.
170 8 Whiteley MS. High intensity focused ultrasound (HIFU) for the treatment of varicose veins
171 and venous leg ulcers – a new non-invasive procedure and a potentially disruptive technology.
172 *Curr Med Res Opin* 2020;**36**:509–12.
173 9 Quehe P, Alavi Z, Kurylo-Touz T, Saliou A-H, Badra A, Baudino L, et al. Endovenous
174 Celon radiofrequency-induced thermal therapy of great saphenous vein: a retrospective study
175 with a 3-year follow-up. *SAGE Open Med* 2018;**6**:2050312118794591.

176 **FIGURE LEGENDS**

177 **Figure 1.** (A) Left calf showing two exuding ulcers (dark dotted circles). Location of the
178 incompetent perforating vein is indicated by the blue star. (B) Colour Doppler image of the
179 incompetent perforating vein showing outward flow (“blow out”).

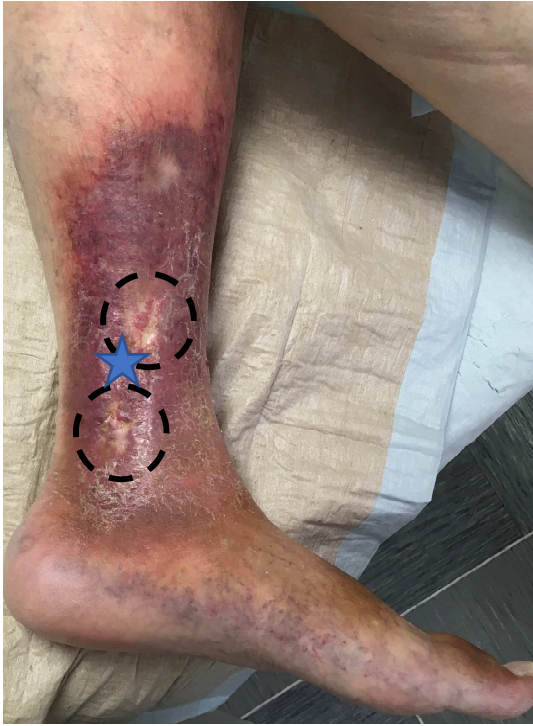180 **Figure 2.** Sonovein high intensity focused ultrasound (HIFU) device.

181 **Figure 3.** EPack. The kit comprises a prefilled pouch of degassed liquid, a balloon, and tubes
182 to connect the balloon to the pouch. The pouch is incorporated in a dedicated bracket and
183 placed in the cooling unit to cool the liquid; the balloon is mounted on the transducer; and the
184 tubes are placed in the pumps, which allow the circulation of the liquid from the pouch to the
185 balloon and back.

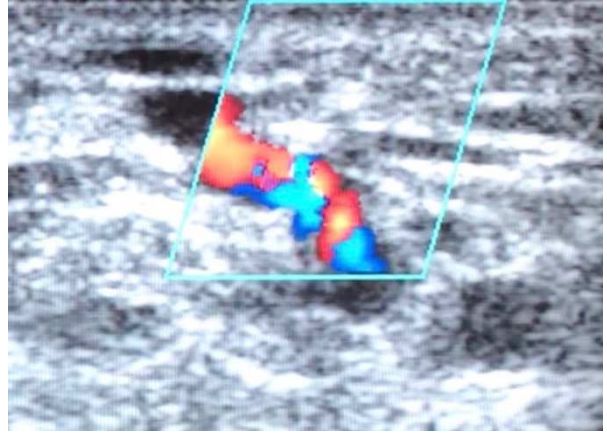
186 **Figure 4.** (A) Positioning of the high intensity focused ultrasound transducer on the calf. (B)
187 Robotic adjustment on the treatment screen of the therapy transducer position. To be properly
188 centred on the targeted vein (white arrow), the focal point position is adjusted with the green
189 directional command arrows. Note here the presence of the subcutaneous infiltration (white
190 star) creating depth between the skin (pink line) and the anterior vein wall.


191 **Figure 5.** Appearance of the left calf (A) before treatment and (B) three months after
192 treatment.

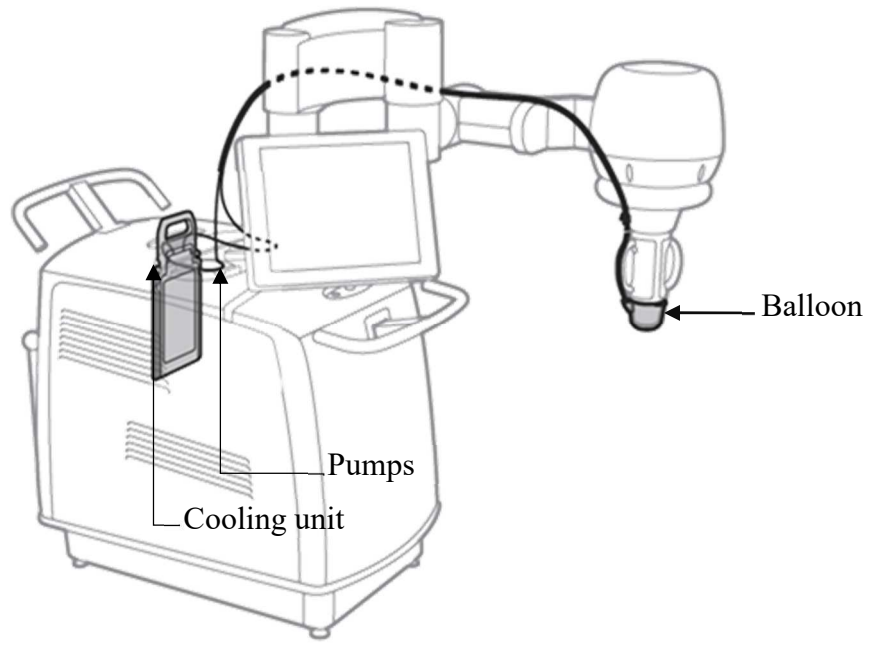
(A)



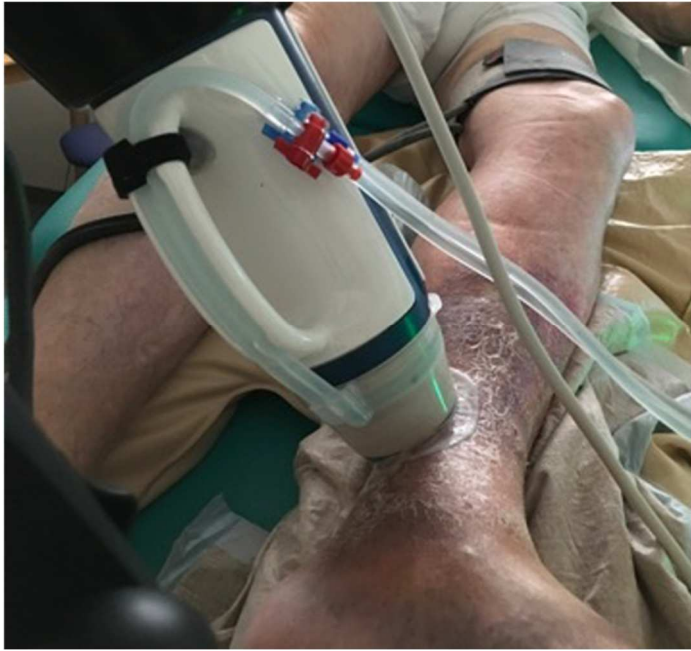(B)



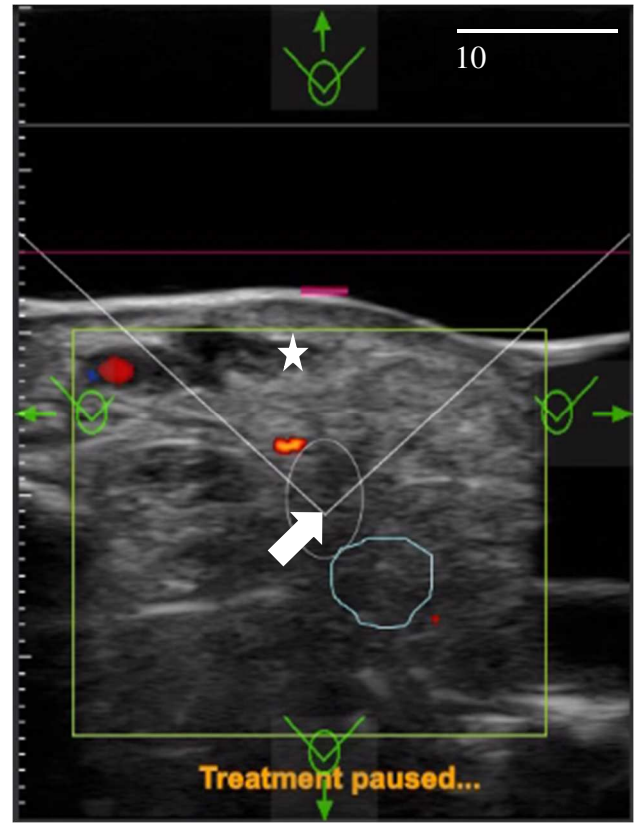




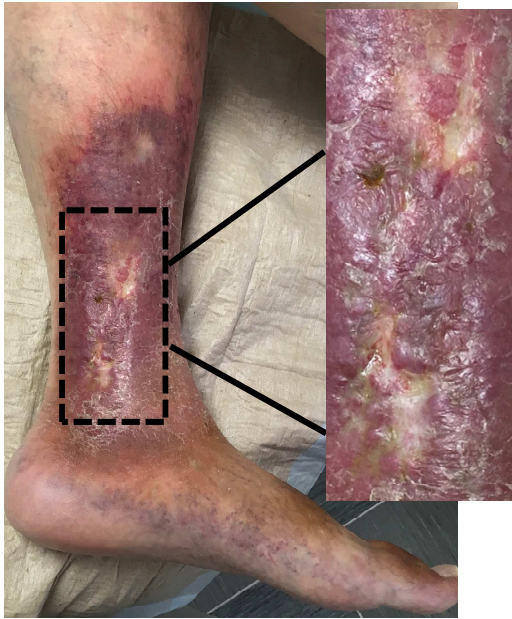(A)



(B)



(A) Before treatment



(B) Three months after treatment

