



HAL
open science

Role of therapeutic plasma exchanges in systemic vasculitis

Alexis Régent, Luc Mouthon, Loïc Guillevin, Benjamin Terrier

► To cite this version:

Alexis Régent, Luc Mouthon, Loïc Guillevin, Benjamin Terrier. Role of therapeutic plasma exchanges in systemic vasculitis. *Transfusion and Apheresis Science*, 2020, 59, pp.102992 -. <10.1016/j.transci.2020.102992>. <hal-03493023>

HAL Id: hal-03493023

<https://hal.science/hal-03493023v1>

Submitted on 15 Dec 2022

HAL is a multi-disciplinary open access archive for the deposit and dissemination of scientific research documents, whether they are published or not. The documents may come from teaching and research institutions in France or abroad, or from public or private research centers.

L'archive ouverte pluridisciplinaire HAL, est destinée au dépôt et à la diffusion de documents scientifiques de niveau recherche, publiés ou non, émanant des établissements d'enseignement et de recherche français ou étrangers, des laboratoires publics ou privés.



Distributed under a Creative Commons CC BY-NC 4.0 - Attribution - Non-commercial use - International License

Role of Therapeutic Plasma Exchanges in Systemic Vasculitis

Alexis Régent^{1,2}, Luc Mouthon^{1,2}, Loïc Guillevin¹ and Benjamin Terrier^{1,3}

⁽¹⁾ Service de Médecine interne, Centre de Référence Maladies auto-immunes et systémiques rares d'Ile de France, Hôpital Cochin, Assistance Publique Hôpitaux de Paris (AP-HP), 27 rue du Faubourg Saint Jacques, Paris, France ; ⁽²⁾ Université de Paris, INSERM U1016, CNRS UMR 8104, LabEx INFLAMEX, F-75014, Paris, France ; ⁽³⁾ Université de Paris, INSERM U970, PARCC, F-75015, Paris, France.

Corresponding author: Dr Alexis Régent, Service de médecine interne, Hôpital Cochin, 27 rue du Faubourg Saint Jacques, Paris, France

Phone : + 33(0)158411455 ; Fax : + 33(0)158411579

Word and (Page) count from Introduction to Figure: 3394 (15)

Figure: 1

Abbreviation

AAV: ANCA-associated vasculitides

ANCA: anti-neutrophil cytoplasmic antibodies

CYC: cyclophosphamide

EGPA: eosinophilic granulomatosis with polyangiitis

GBM: glomerular basement membrane

GC: glucocorticoid

GPA: granulomatosis with polyangiitis

HBV: Hepatitis B virus

Ig: immunoglobulin

IV: intravenous

MPA: microscopic polyangiitis

MPO: myeloperoxidase

PAN: polyarteritis nodosa

PLEX: plasma exchange

PR3: proteinase 3

RPGN: rapidly progressive glomerulonephritis

RTX: rituximab

Abstract

Therapeutic management of systemic vasculitides is based on glucocorticoids (GCs), in combination or not with immunosuppressive and/or immunomodulatory agents. Plasma exchange (PLEX) has been used in some vasculitides, with various levels of evidence. Indeed, it is part of the first-line therapy in patients with anti-glomerular basement membrane (GBM) antibodies and in patients with severe hepatitis B related polyarteritis nodosa (PAN). PLEX might also be considered in some selected patients with ANCA-associated vasculitis and cryoglobulinemia vasculitis. Studies support the use of PLEX as second line therapy in refractory Kawasaki disease. Finally, there is not robust data to support the use of PLEX in unselected patients with non-HBV-related PAN or IgA vasculitis. Additional studies are required to address its role in these settings.

Introduction

Systemic vasculitides are a heterogeneous group of diseases, defined by the inflammation of the vessel wall, ranging from large vessels to small-size vessels, i.e. arteries, capillaries and/or venules. Histopathology may provide additional information according to each type of vasculitis, such as fibrinoid necrosis, granulomatous inflammation, eosinophil-rich infiltrates and/or giant cells. Thrombosis and the subsequent lumen obstruction as consequences of vasculitis are responsible for ischemic manifestations. Different classifications have been proposed, but they are applicable in patients in whom the diagnosis of vasculitis has been made, a reason why they should not be considered for diagnostic purposes. The most widely used system to define vasculitis is the International Chapel Hill Consensus Conference [1] that has been revised in 2012 [2]. This nomenclature has the major advantage of providing a clear classification based on the size of the vessels involved and histological and immunological findings (**Figure 1**).

Therapeutic management of systemic vasculitides is based on glucocorticoids (GC), in combination or not with immunosuppressive and/or immunomodulatory agents, and is decided according to vasculitis subtype, disease severity, patients' characteristics, comorbidities and predictable outcome. Plasma exchanges (PLEX) have been used in some vasculitides, with various levels of evidence. PLEX relies on the removal from the blood of various substances, including autoantibodies, paraproteins or immune complexes. Clearance of other molecules such as cytokines or activated complement components may also be beneficial in some diseases. PLEX are mainly expected to have rapid but short-term effect, to reduce organ damage and bridge the gap with GC and/or immunosuppressive or immunomodulatory agents related efficacy. Overall, PLEX represents a major aspect

of the treatment of anti-Glomerular Basement Membrane (anti-GBM) disease and hepatitis B virus-related (HBV) polyarteritis nodosa, and as a potential complementary treatment in severe patients with antineutrophil cytoplasmic antibodies (ANCA)-associated vasculitides and cryoglobulinemia vasculitis and non HBV-related PAN.

In this review, we will thus focus on these vasculitis and discuss the role of PLEX in therapeutic management.

ANCA-associated vasculitis

ANCA-associated vasculitides (AAV) encompass microscopic polyangiitis (MPA), granulomatosis with polyangiitis (GPA) and eosinophilic granulomatosis with polyangiitis (EGPA). ANCA are frequently observed and target either myeloperoxidase (MPO) or proteinase 3 (PR3). They are found in 75-90% of patients with MPA [3], usually targeting MPO, in 90 % of patients with GPA, usually targeting PR3, and in only one third of patients with EGPA [4], usually targeting MPO.

1. Microscopic polyangiitis

MPA is classified by the Chapel Hill Consensus Conference[1,2] as a nongranulomatous necrotizing small-sized vessel vasculitis, with little or no immune-complex deposition, that primarily affects the kidneys and lungs. MPA may develop insidiously, with nonspecific signs of systemic inflammation (eg, weight loss, loss of appetite, low-grade fever), arthralgia or myalgia. Pulmonary-renal syndrome can reveal the disease or occur during its evolution. It usually associates alveolar with hemorrhage and rapidly progressive glomerulonephritis (RPGN), defined as renal function decreased <50% within weeks/days and crescent formation in >50% of the

glomeruli. Other clinical manifestations include palpable purpura, mononeuritis multiplex, or, less frequently, gastrointestinal involvement.

2. Granulomatosis with polyangiitis (Wegener)

GPA is characterized by ear, nose and throat manifestations (rhinitis with crusts, bleeding, sinusitis, otitis, subglottic stenosis), lung manifestations and RPGN. Lung assessment usually reveals nodules, usually bilateral and multiple, sometimes with cavities, the latter feature being characteristic of GPA. Lung hemorrhage is possible, as well as pulmonary-renal syndrome similar to what is described in MPA. Other clinical manifestations are also comparable to what has been observed in MPA.

3. Eosinophilic Granulomatosis with polyangiitis (Churg-Strauss)

EGPA is characterized by the combination of asthma, blood and tissue (eosinophilia $\geq 1000/\text{mm}^3$ in peripheral blood) and manifestations suggestive of vasculitis (involving at least two extra-pulmonary sites). Sinusitis or nasal polyps are found in 70% of patients. Other symptoms include purpura, urticaria, mononeuritis multiplex, gastrointestinal involvement, and, more rarely, central nervous involvement, eye involvement or RPGN. Specific cardiac involvement, especially cardiomyopathy, myocarditis or endomyocardial fibrosis, is found in roughly 40% of patients, and represents a severe manifestation.

4. Role of PLEX in the treatment of ANCA-associated vasculitis

Treatment of AAV successively includes two phases: a remission-induction phase based on GCs, associated or not with cyclophosphamide (CYC) or rituximab

(RTX), and a maintenance phase to avoid the risk of relapse based on semestrial infusions of RTX for 2 to 4 years.

PLEX has been proposed in combination with other remission-induction treatments for patients with rapidly progressive glomerulonephritis and/or alveolar hemorrhage [5]. Before the 2000, a retrospective study of 32 patients with RPGN (28 MPA and 4 EGPA) did not find any benefit on kidney survival at 1 year, although a trend toward superiority was observed on the survival rate at 5 years [6].

PLEX was then compared to pulses of methylprednisolone in conjunction with GC and oral cyclophosphamide (CYC) for AAV patients presenting with RPGN and a serum creatinin $>500 \mu\text{mol/L}$, showing significant benefit of PLEX on renal function at 3 and 12 months [7]. However, long-term analysis did not support any sustained benefit of PLEX [8], and the role of PLEX started to be questionable to prevent end-stage renal disease. Their interest in AAV-related severe alveolar haemorrhage was evaluated in small case series, where PLEX, in adjunction to GCs and CYC, were found to rapidly improve pulmonary function, whereas the effect on renal function was unclear [9,10].

More recently, the PEXIVAS trial, a randomized trial with a 2-by-2 factorial design, was conducted to evaluate the use of PLEX together with RTX or CYC according to local medical practice, and two regimens of oral GC in patients with severe AAV, defined by an estimated glomerular filtration rate of $<50 \text{ ml/min/1.73 m}^2$ or diffuse pulmonary haemorrhage. Patients were then randomly assigned to undergo PLEX (seven PLEX within 14 days) or no PLEX (control group). Patients were also randomly assigned to follow either a standard-dose regimen or a reduced-dose regimen of oral GCs. The PEXIVAS trial showed that the use of PLEX did not reduce the incidence of death or end-stage renal disease. Also, a reduced-dose regimen of

GCs was non-inferior to a standard-dose regimen with respect to the same primary endpoint [11]. However, a trend towards lower mortality was observed for patients with severe alveolar haemorrhage requiring mechanical ventilation and some authors still support use of PLEX in severe alveolar haemorrhage [12].

Overall, the French recommendations were made to define for physicians the role of PLEX [13]. According to the expert panel, the situations in which PLEX should be considered a therapeutic option are:

- Severe alveolar haemorrhage (massive haemoptysis, acute respiratory distress);
- Persistent worsening of renal insufficiency despite conventional glucocorticoids with cyclophosphamide or rituximab;
- RPGN and/or alveolar haemorrhage without a definite diagnosis, at least until anti-GBM antibody test results become available and/or a definitive diagnosis (with subsequent PLEX discontinuation, once AAV is diagnosed).

In EGPA, the role of PLEX is difficult to determine. No benefit was found in a study on patients with EGPA and a five factor score (FFS) ≥ 1 treated by GC and oral CYC [14]. However, PLEX can still be proposed for some patients, especially those in the same situations as describe above [15].

Anti-GBM disease

Anti-glomerular basement membrane (anti-GBM) disease or Goodpasture's syndrome is a rare small vessel vasculitis. It is mediated by autoantibodies against the glomerular and alveolar basement membrane and typically leads to pulmonary-renal syndrome. Interestingly, a positive ANCA can be detected in 20 to 60% of anti-GBM disease cases [16]. However, renal immunofluorescence associated with anti-

GBM disease is characterized by linear deposit of IgG along the GBM. Since its initial description, an interest in combined GC, CYC and PLEX was suggested [17] and the benefit of PLEX was then confirmed in a small randomised trial including 17 patients [18]. Combined treatment with GC, PLEX and CYC was also found to be superior to GC and CYC on kidney and patient survival in a retrospective analysis of 221 patients [19]. Treatment should be started if the diagnosis is highly suspected or confirmed. Therapeutic PLEX is performed daily, with 5% human albumin solution or in combination with fresh frozen plasma in patients with pulmonary haemorrhage. PLEX is continued for 14 days or until anti-GBM antibody levels are fully suppressed. Prednisone or prednisolone is prescribed orally at 1 mg/kg/day (maximum 60 mg/day) and the dose is then reduced weekly to 20 mg/day by week 6 and more slowly further on to be completely stopped by 6 months. CYC is classically administered orally, at 2 to 3 mg/kg/day for a duration of 2 to 3 months. Importantly, no maintenance therapy is recommended [20]. Compared to patients with anti-GBM only, patients with a double anti-GBM and ANCA positivity have a higher risk of relapse and might require maintenance therapy.

Also, rituximab was suggested to represent an additional and/or alternative therapy for the treatment of anti-GBM disease in case reports and small series [21].

Cryoglobulinemia vasculitis

Cryoglobulinemia vasculitis is an immune complex-mediated vasculitis involving small-sized vessels. Cryoglobulins are defined by the presence of circulating immunoglobulins (Ig) that precipitate as the serum is cooled below core body temperature and resolubilize when rewarmed. Cryoglobulins are immunochemically categorized into three types by the method of Brouet [22]. Type I

cryoglobulins are single monoclonal Ig linked to a B-cell or plasma cell proliferative disorder. Type II consists of polyclonal IgG with a monoclonal IgM component with rheumatoid factor activity. Types III are comprised of polyclonal IgG and IgM with rheumatoid factor activity.

Mixed cryoglobulinemia vasculitis used to be associated with hepatitis C virus infection in up to 90% of cases, but the emergence of highly effective antiviral therapies has changed the etiologic picture of cryoglobulinemia vasculitis [23]. Disease presentation is typically dominated by purpura but cutaneous ulcers may occur, arthralgia, peripheral neuropathy, in roughly one third of cases with membranoproliferative glomerulonephritis, and less frequently with gastrointestinal involvement or central nervous vasculitis [24]. Raynaud's phenomenon and acrocyanosis, and cutaneous necrosis can also occur, especially in type 1 cryoglobulinemia.

Very scarce prospective controlled trials are available. A randomized controlled study randomly assigned 17 patients to receive PLEX every 2-3 days versus no PLEX, from week 12 to 24 after different immunosuppressive regimens. A clinical improvement was observed in patients with PLEX at W24 compared to those not receiving PLEX [25]. In contrast, reviews and retrospective studies support the use of PLEX despite the lack of evidence-based data in cryoglobulinemia vasculitis, especially in type 1 cryoglobulinemia during which the cryoglobulin level may be high [24,26]. Altogether, the place of PLEX, GC or immunosuppressive therapy has not been clearly established in cryoglobulinemia vasculitis and practice varies according to centres [27].

Polyarteritis nodosa (PAN)

In contrast to the previous vasculitis, PAN is a medium-sized vessel vasculitis. Patients present with severe constitutional symptoms together with arthralgia, myalgia, skin lesions and arterial hypertension. Mononeuritis multiplex and intestinal ischemia are other frequent and severe manifestations. The diagnosis can be supported by the presence of abdominal or renal aneurysms, sometimes responsible for acute bleeding. Before the 2000, PAN used to be secondary to recent hepatitis B virus (HBV) infection, whereas it is now almost always a primary vasculitis.

In the early 80's, patients with PAN were included in a protocol without considering their HBV status [28]. In non-HBV-related PAN, two studies including 48 and 60 patients with or without severe clinical presentation, respectively, did not find any benefit for PLEX [14,29]. Thus, addition of PLEX in non-HBV PAN is not recommended in unselected patients with PAN, but we cannot exclude a role in most severe patients on an expert-based opinion [30].

The benefit of PLEX has been evaluated and demonstrated in the setting of HBV-related PAN. In 33 patients with HBV-related PAN, after a two-week GC treatment, PLEX in combination with vidarabin was found to be effective in disease control. In this study, 24 patients recovered and harboured no clinical or laboratory evidence of systemic vasculitis at the end of follow-up [31]. Small non-randomized prospective studies confirmed the efficacy of the proposed therapeutic scheme with use of interferon or lamivudin as anti-viral therapy [32,33]. However, despite detectable HBV DNA at the end of treatment, lamivudin alone was suggested to be efficient in treating vasculitis symptoms [34], questioning the exact role of PLEX in the treatment of HBV-related PAN. Nevertheless, we can probably consider that PLEX is part of the

treatment in severe HBV-related PAN, while in the case of non-severe vasculitis, anti-viral therapy alone could be sufficient.

Other vasculitis

Kawasaki disease is an acute, systemic vasculitis that occurs predominantly in infants and young children, and the main risk is the development of an acute coronary aneurysm. PLEX was evaluated in children with KD unresponsive to intravenous Ig (IVIg). Twenty-seven children underwent a 3-day PLEX therapy and 3 of them developed coronary lesions as compared to 23 of the 48 children who received a second intravenous IVIg cycle [35]. Also, on the basis of small uncontrolled case series, PLEX has also been proposed for some patients with severe IgA vasculitis [36,37] but further evaluation is required in this vasculitis.

Technique of PLEX in vasculitis

The schedule and total number of PLEX sessions varied across time and regarding the type of underlying vasculitis.

In the early 80's, patients with non HBV-related vasculitis underwent 13 PLEX in 6 months with which 5 during the first 2 weeks [28]. The schedule was then reduced and patients underwent 9 PLEX sessions during the first 3 weeks of treatment (3 each week) [14]. Later on, PLEX sessions were again reduced to 7 sessions during 14 days [7], usually every other day [10]. Despite a lack of data supporting this reduced scheme, it is the PLEX regimen that is currently used nowadays in ANCA-associated vasculitis and non-HBV-related PAN.

In anti-GBM disease, the number of PLEX sessions is guided by the results of anti-GBM antibody positivity and disease activity.

In cryoglobulinemia vasculitis, the schedule and total number of PLEX vary among studies without any consensual scheme of PLEX therapy [26].

A combined treatment with PLEX and anti-viral therapy was specifically tailored for patients with HBV-related PAN [28]. In these patients, PLEX was initiated after a short GC therapy aimed at controlling the disease [31]. Patients had PLEX sessions three times a week for 3 weeks, then reduced to twice a week and slowly tapered until discontinuation for an average of 15-20 PLEX sessions [31–33].

The amount of plasma replacement for each session is often 60 ml/kg of body weight and replacement fluid usually consists of albumin [11,28,29]. Fresh-frozen plasma is used in patients with decreased levels of coagulation factors, a situation often occurring with daily PLEX sessions [14], or in the setting of severe alveolar hemorrhage.

Centrifugation, filtration and adsorption have all been used in systemic vasculitis and there is no evidence of the superiority of one over the other [23]. Apart from hypotension and allergic reactions during PLEX, some side effects attributable to PLEX have been described among which are anemia, infections and fever, thrombocytopenia, venous thrombosis or bleeding and cardiac arrhythmia [15,38]. Incidence of infection was high in patients with PAN or EGPA treated with PLEX although the respective role of PLEX, GC or CYC is unclear. There was no difference in the occurrence of the frequency of side effects although more PLEX sessions were stopped for moderate to severe hypotension when intermittent flow centrifugation was used compared to continuous flow centrifugation or filtration [39].

Conclusion

PLEX is recommended as first-line therapy in anti-GBM disease and severe

HBV-related PAN. In other systemic vasculitis, despite a theoretical interest, PLEX is part of first-line therapy in selected patients only. However, additional data are needed for more accurate assessment of indications, practical modalities and benefits of PLEX.

References

- [1] Jennette JC, Falk RJ, Andrassy K, Bacon PA, Churg J, Gross WL, et al. Nomenclature of systemic vasculitides. Proposal of an international consensus conference. *Arthritis Rheum* 1994;37:187–92.
- [2] Jennette JC, Falk RJ, Bacon PA, Basu N, Cid MC, Ferrario F, et al. 2012 revised International Chapel Hill Consensus Conference Nomenclature of Vasculitides. *Arthritis Rheum* 2013;65:1–11. <https://doi.org/10.1002/art.37715>.
- [3] Guillevin L, Durand-Gasselin B, Cevallos R, Gayraud M, Lhote F, Callard P, et al. Microscopic polyangiitis: clinical and laboratory findings in eighty-five patients. *Arthritis Rheum* 1999;42:421–30. [https://doi.org/10.1002/1529-0131\(199904\)42:3<421::AID-ANR5>3.0.CO;2-6](https://doi.org/10.1002/1529-0131(199904)42:3<421::AID-ANR5>3.0.CO;2-6).
- [4] Chang H-C, Chou P-C, Lai C-Y, Tsai H-H. Antineutrophil cytoplasmic antibodies and organ-specific manifestations in eosinophilic granulomatosis with polyangiitis: A systematic review and meta-analysis. *J Allergy Clin Immunol Pract* 2020. <https://doi.org/10.1016/j.jaip.2020.07.038>.
- [5] Rifle G, Chalopin JM, Zech P, Deteix P, Ducret F, Vialtel P, et al. Treatment of idiopathic acute crescentic glomerulonephritis by immunodepression and plasma-exchanges. A prospective randomised study. *Proc Eur Dial Transplant Assoc* 1981;18:493–502.
- [6] Guillevin L, Cevallos R, Durand-Gasselin B, Lhote F, Jarrousse B, Callard P. Treatment of glomerulonephritis in microscopic polyangiitis and Churg-Strauss syndrome. Indications of plasma exchanges, Meta-analysis of 2 randomized studies on 140 patients, 32 with glomerulonephritis. *Ann Med Interne (Paris)* 1997;148:198–204.
- [7] Jayne DRW, Gaskin G, Rasmussen N, Abramowicz D, Ferrario F, Guillevin L,

et al. Randomized trial of plasma exchange or high-dosage methylprednisolone as adjunctive therapy for severe renal vasculitis. *J Am Soc Nephrol* 2007;18:2180–8. <https://doi.org/10.1681/ASN.2007010090>.

[8] Walsh M, Casian A, Flossmann O, Westman K, Höglund P, Pusey C, et al. Long-term follow-up of patients with severe ANCA-associated vasculitis comparing plasma exchange to intravenous methylprednisolone treatment is unclear. *Kidney Int* 2013;84:397–402. <https://doi.org/10.1038/ki.2013.131>.

[9] Geri G, Terrier B, Heshmati F, Moussaoui H, Massot J, Mira J-P, et al. Effect of plasma exchange in acute respiratory failure due to Anti-neutrophil cytoplasmic antibody-associated vasculitis. *Crit Care* 2018;22:328. <https://doi.org/10.1186/s13054-018-2264-x>.

[10] Klemmer PJ, Chalermkulrat W, Reif MS, Hogan SL, Henke DC, Falk RJ. Plasmapheresis therapy for diffuse alveolar hemorrhage in patients with small-vessel vasculitis. *Am J Kidney Dis* 2003;42:1149–53. <https://doi.org/10.1053/j.ajkd.2003.08.015>.

[11] Walsh M, Merkel PA, Peh C-A, Szpirt WM, Puéchal X, Fujimoto S, et al. Plasma Exchange and Glucocorticoids in Severe ANCA-Associated Vasculitis. *N Engl J Med* 2020;382:622–31. <https://doi.org/10.1056/NEJMoa1803537>.

[12] Derebail VK, Falk RJ. ANCA-Associated Vasculitis - Refining Therapy with Plasma Exchange and Glucocorticoids. *N Engl J Med* 2020;382:671–3. <https://doi.org/10.1056/NEJMe1917490>.

[13] Terrier B, Charles P, Aumaître O, Belot A, Bonnotte B, Crabol Y, et al. ANCA-associated vasculitides: Recommendations of the French Vasculitis Study Group on the use of immunosuppressants and biotherapies for remission induction and maintenance. *Presse Med* 2020;49:104031.

<https://doi.org/10.1016/j.lpm.2020.104031>.

[14] Guillevin L, Lhote F, Cohen P, Jarrousse B, Lortholary O, G n reau T, et al. Corticosteroids plus pulse cyclophosphamide and plasma exchanges versus corticosteroids plus pulse cyclophosphamide alone in the treatment of polyarteritis nodosa and Churg-Strauss syndrome patients with factors predicting poor prognosis. A prospective, randomized trial in sixty-two patients. *Arthritis Rheum* 1995;38:1638–45. <https://doi.org/10.1002/art.1780381116>.

[15] de Luna G, Chauveau D, Aniort J, Carron P-L, Gobert P, Karras A, et al. Plasma exchanges for the treatment of severe systemic necrotizing vasculitides in clinical daily practice: Data from the French Vasculitis Study Group. *J Autoimmun* 2015;65:49–55. <https://doi.org/10.1016/j.jaut.2015.08.003>.

[16] DE Zoysa J, Taylor D, Thein H, Yehia M. Incidence and features of dual anti-GBM-positive and ANCA-positive patients. *Nephrology (Carlton)* 2011;16:725–9. <https://doi.org/10.1111/j.1440-1797.2011.01484.x>.

[17] Lockwood CM, Rees AJ, Pearson TA, Evans DJ, Peters DK, Wilson CB. Immunosuppression and plasma-exchange in the treatment of Goodpasture’s syndrome. *Lancet* 1976;1:711–5. [https://doi.org/10.1016/s0140-6736\(76\)93089-0](https://doi.org/10.1016/s0140-6736(76)93089-0).

[18] Johnson JP, Moore J, Austin HA, Balow JE, Antonovych TT, Wilson CB. Therapy of anti-glomerular basement membrane antibody disease: analysis of prognostic significance of clinical, pathologic and treatment factors. *Medicine (Baltimore)* 1985;64:219–27. <https://doi.org/10.1097/00005792-198507000-00003>.

[19] Cui Z, Zhao J, Jia X, Zhu S, Jin Q, Cheng X, et al. Anti-glomerular basement membrane disease: outcomes of different therapeutic regimens in a large single-center Chinese cohort study. *Medicine (Baltimore)* 2011;90:303–11. <https://doi.org/10.1097/MD.0b013e31822f6f68>.

- [20] Salama AD, Levy JB, Lightstone L, Pusey CD. Goodpasture's disease. *Lancet* 2001;358:917–20. [https://doi.org/10.1016/S0140-6736\(01\)06077-9](https://doi.org/10.1016/S0140-6736(01)06077-9).
- [21] Touzot M, Poisson J, Faguer S, Ribes D, Cohen P, Geffray L, et al. Rituximab in anti-GBM disease: A retrospective study of 8 patients. *J Autoimmun* 2015;60:74–9. <https://doi.org/10.1016/j.jaut.2015.04.003>.
- [22] Brouet JC, Clauvel JP, Danon F, Klein M, Seligmann M. Biologic and clinical significance of cryoglobulins. A report of 86 cases. *Am J Med* 1974;57:775–88. [https://doi.org/10.1016/0002-9343\(74\)90852-3](https://doi.org/10.1016/0002-9343(74)90852-3).
- [23] Marson P, Monti G, Montani F, Riva A, Mascia MT, Castelnovo L, et al. Apheresis treatment of cryoglobulinemic vasculitis: A multicentre cohort study of 159 patients. *Transfus Apher Sci* 2018;57:639–45. <https://doi.org/10.1016/j.transci.2018.06.005>.
- [24] Retamozo S, Díaz-Lagares C, Bosch X, Bové A, Brito-Zerón P, Gómez M-E, et al. Life-Threatening Cryoglobulinemic Patients With Hepatitis C: Clinical Description and Outcome of 279 Patients. *Medicine (Baltimore)* 2013;92:273–84. <https://doi.org/10.1097/MD.0b013e3182a5cf71>.
- [25] Stefanutti C, Vivenzio A, Di Giacomo S, Labbadia G, Mazza F, D'Alessandri G, et al. Immunoabsorption apheresis and immunosuppressive drug therapy in the treatment of complicated HCV-related cryoglobulinemia. *J Clin Apher* 2009;24:241–6. <https://doi.org/10.1002/jca.20222>.
- [26] Rockx MA, Clark WF. Plasma exchange for treating cryoglobulinemia: a descriptive analysis. *Transfus Apher Sci* 2010;42:247–51. <https://doi.org/10.1016/j.transci.2010.03.001>.
- [27] Montero N, Favà A, Rodriguez E, Barrios C, Cruzado JM, Pascual J, et al. Treatment for hepatitis C virus-associated mixed cryoglobulinaemia. *Cochrane*

Database Syst Rev 2018;5:CD011403.

<https://doi.org/10.1002/14651858.CD011403.pub2>.

[28] Guillevin L, Lhote F. Treatment of polyarteritis nodosa and Churg-Strauss syndrome: indications of plasma exchanges. *Transfus Sci* 1994;15:371–88.

[https://doi.org/10.1016/0955-3886\(94\)90170-8](https://doi.org/10.1016/0955-3886(94)90170-8).

[29] Guillevin L, Fain O, Lhote F, Jarrousse B, Le Thi Huong D, Bussel A, et al. Lack of superiority of steroids plus plasma exchange to steroids alone in the treatment of polyarteritis nodosa and Churg-Strauss syndrome. A prospective, randomized trial in 78 patients. *Arthritis Rheum* 1992;35:208–15.

<https://doi.org/10.1002/art.1780350214>.

[30] Jarrousse B, Guillevin L, Gie S, Bletry O, Barrier J, Cassuto-Viguier E, et al. [Prognosis and treatment of glomerulonephritis of periarteritis nodosa. The role of plasma exchange]. *Ann Med Interne (Paris)* 1988;139 Suppl 1:23–5.

[31] Guillevin L, Lhote F, Leon A, Fauvelle F, Vivitski L, Trepo C. Treatment of polyarteritis nodosa related to hepatitis B virus with short term steroid therapy associated with antiviral agents and plasma exchanges. A prospective trial in 33 patients. *J Rheumatol* 1993;20:289–98.

[32] Guillevin L, Lhote F, Sauvaget F, Deblois P, Rossi F, Levallois D, et al.

Treatment of polyarteritis nodosa related to hepatitis B virus with interferon-alpha and plasma exchanges. *Ann Rheum Dis* 1994;53:334–7.

<https://doi.org/10.1136/ard.53.5.334>.

[33] Guillevin L, Mahr A, Cohen P, Larroche C, Queyrel V, Loustaud-Ratti V, et al.

Short-term corticosteroids then lamivudine and plasma exchanges to treat hepatitis B virus-related polyarteritis nodosa. *Arthritis Rheum* 2004;51:482–7.

<https://doi.org/10.1002/art.20401>.

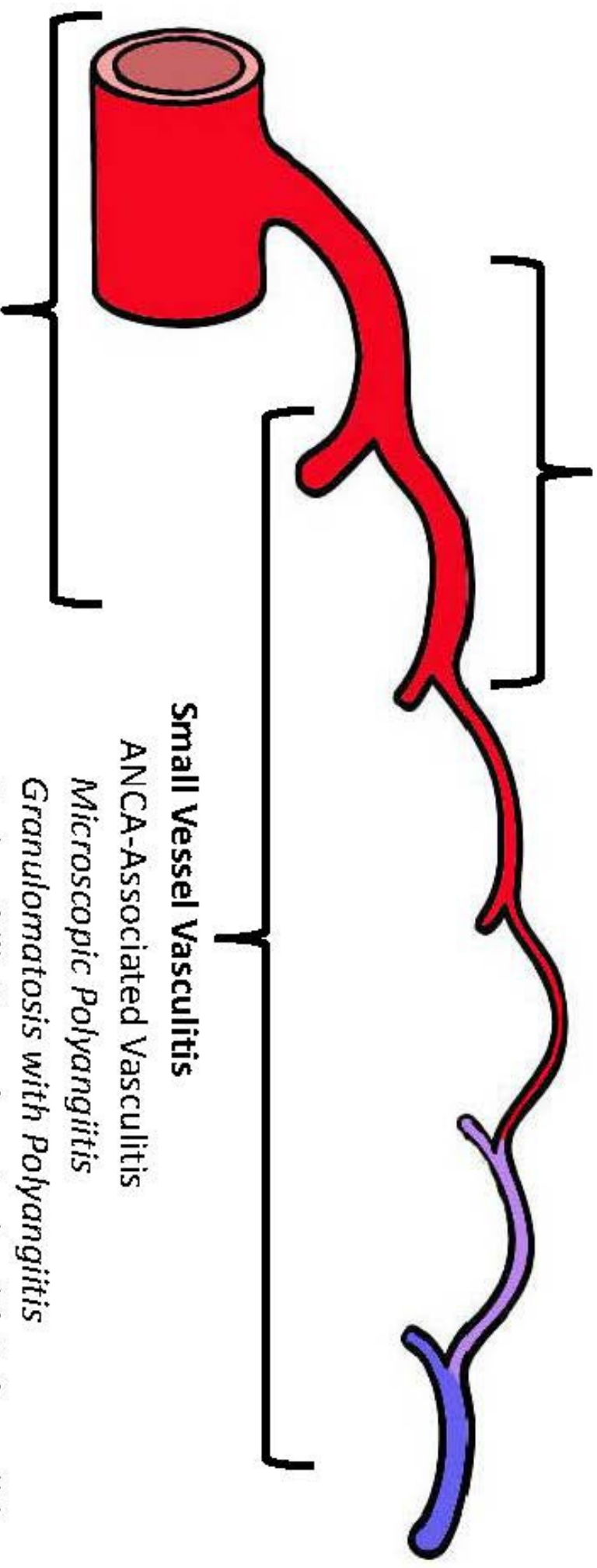
- [34] Filer A, Hughes A, Kane K, Mutimer D, Jobanputra P. Successful treatment of hepatitis B-associated vasculitis using lamivudine as the sole therapeutic agent. *Rheumatology (Oxford)* 2001;40:1064–5.
<https://doi.org/10.1093/rheumatology/40.9.1064>.
- [35] Imagawa T, Mori M, Miyamae T, Ito S, Nakamura T, Yasui K, et al. Plasma exchange for refractory Kawasaki disease. *Eur J Pediatr* 2004;163:263–4.
<https://doi.org/10.1007/s00431-003-1267-y>.
- [36] Hattori M, Ito K, Konomoto T, Kawaguchi H, Yoshioka T, Khono M. Plasmapheresis as the sole therapy for rapidly progressive Henoch-Schönlein purpura nephritis in children. *Am J Kidney Dis* 1999;33:427–33.
[https://doi.org/10.1016/s0272-6386\(99\)70178-2](https://doi.org/10.1016/s0272-6386(99)70178-2).
- [37] Augusto J-F, Sayegh J, Delapierre L, Croue A, Tollis F, Cousin M, et al. Addition of plasma exchange to glucocorticosteroids for the treatment of severe Henoch-Schönlein purpura in adults: a case series. *Am J Kidney Dis* 2012;59:663–9.
<https://doi.org/10.1053/j.ajkd.2011.12.015>.
- [38] Lhote F, Guillevin L, Leon A, Bussel A, Lok C, Sobel A, et al. Complications of plasma exchange in the treatment of polyarteritis nodosa and Churg-Strauss angiitis and the contribution of adjuvant immunosuppressive therapy: a randomized trial in 72 patients. *Artif Organs* 1988;12:27–33. <https://doi.org/10.1111/j.1525-1594.1988.tb01520.x>.
- [39] Lhote F, Guillevin L, Bussel A, Leon A, Lok C, Toledano D, et al. Side effects of therapeutic plasma exchange during treatment of polyarteritis nodosa. Comparison of filtration and centrifugation. 718 sessions in 63 patients. *Life Support Syst* 1987;5:359–66.

Figure 1

Distribution of vessel involvement by large vessel vasculitis, medium vessel vasculitis, and small vessel vasculitis according to Jennette et al. [2]

Medium Vessel Vasculitis

Polyarteritis Nodosa
Kawasaki Disease



Large Vessel Vasculitis

Takayasu Arteritis
Giant Cell Arteritis

Small Vessel Vasculitis

ANCA-Associated Vasculitis
Microscopic Polyangiitis
Granulomatosis with Polyangiitis
Eosinophilic Granulomatosis with Polyangiitis
Immune Complex SV
Anti-GBM Disease
Cryoglobulinemic Vasculitis
IgA Vasculitis (Henoch-Schönlein)
Hypocomplementemic Urticarial Vasculitis
(Anti-C1q Vasculitis)