



HAL
open science

Laparoscopic closure of the pouch of Douglas by a peritoneal running suture. A minimally invasive and prosthetic-free technique to prevent excessive dose delivery to the small bowel during pelvic irradiation for prostate cancer

Maxime Loo, Carlos Martinez-Gomez, Jonathan Khalifa, Martina-Aida Angeles, Ciprian Chira, Lucie Piram, Elodie Martin, Bernard Malavaud, Gwenaël Ferron, Pierre Graff-Cailleaud

► To cite this version:

Maxime Loo, Carlos Martinez-Gomez, Jonathan Khalifa, Martina-Aida Angeles, Ciprian Chira, et al.. Laparoscopic closure of the pouch of Douglas by a peritoneal running suture. A minimally invasive and prosthetic-free technique to prevent excessive dose delivery to the small bowel during pelvic irradiation for prostate cancer. *Clinical and Translational Radiation Oncology*, 2021, 26, pp.71 - 78. 10.1016/j.ctro.2020.11.015 . hal-03493011

HAL Id: hal-03493011

<https://hal.science/hal-03493011>

Submitted on 15 Dec 2022

HAL is a multi-disciplinary open access archive for the deposit and dissemination of scientific research documents, whether they are published or not. The documents may come from teaching and research institutions in France or abroad, or from public or private research centers.

L'archive ouverte pluridisciplinaire **HAL**, est destinée au dépôt et à la diffusion de documents scientifiques de niveau recherche, publiés ou non, émanant des établissements d'enseignement et de recherche français ou étrangers, des laboratoires publics ou privés.



Distributed under a Creative Commons Attribution - NonCommercial 4.0 International License

Title

Laparoscopic closure of the pouch of Douglas by a peritoneal running suture. A minimally invasive and prosthetic-free technique to prevent excessive dose delivery to the small bowel during pelvic irradiation for prostate cancer.

Authors

Maxime Loo¹, Carlos Martinez-Gomez^{2,3}, Jonathan Khalifa^{1,3}, Martina-Aida Angeles², Ciprian Chira¹, Lucie Piram¹, Elodie Martin⁴, Bernard Malavaud⁵, Gwenaël Ferron^{2,6}, Pierre Graff-Cailleaud¹.

¹ Department of Radiation Oncology, Institut Universitaire du Cancer de Toulouse, 1, avenue Irène Joliot-Curie 31100 Toulouse (France)

² Department of Surgical Oncology, Institut Universitaire du Cancer de Toulouse, 1, avenue Irène Joliot-Curie 31100 Toulouse (France)

³ INSERM CRCT Team 1, Tumor Immunology and Immunotherapy, 2 Avenue Hubert Curien, 31100 Toulouse (France).

⁴ Department of Biostatistics, Institut Universitaire du Cancer de Toulouse, 1, avenue Irène Joliot-Curie 31100 Toulouse (France)

⁵ Department of Urology, Institut Universitaire du Cancer de Toulouse, 1, avenue Irène Joliot-Curie 31100 Toulouse (France)

⁶ INSERM CRCT Team 19, ONCOSARC-Oncogenesis of sarcomas, 2 Avenue Hubert Curien, 31100 Toulouse (France).

Email addresses of the authors

Maxime Loo: Loo.Maxime@iuct-oncopole.fr

Carlos Martinez-Gomez : cmartgomez@gmail.com

Jonathan Khalifa : Khalifa.Jonathan@iuct-oncopole.fr

Martina-Aida Angeles : AngelesFite.Martina@iuct-oncopole.fr

Ciprian Chira: Chira.Ciprian@iuct-oncopole.fr

Lucie Piram : Piram.Lucie@iuct-oncopole.fr

Elodie Martin : Martin.Elodie@iuct-oncopole.fr

Bernard Malavaud : bernard.malavaud@me.com

Gwenaël Ferron : Ferron.Gwenael@iuct-oncopole.fr

Pierre Graff-Cailleaud : graffcailleaud@gmail.com

Corresponding author

Pierre Graff-Cailleaud

Department of Radiation Oncology, Institut Universitaire du Cancer de Toulouse, 1, avenue Irène Joliot-Curie 31100 Toulouse (France)

Phone: +33 (0) 640 952 567

e-mail: graffcailleaud@gmail.com

Abstract

Background and purpose: Prostate radiotherapy relies on the delivery of high doses that can be obstructed when a small bowel loop descends in the pelvis. We present a laparoscopic minimally invasive prosthetic-free technique closing the Douglas' pouch with a peritoneal running suture to cordon off the bowel from the pelvis and hence allow optimal irradiation.

Materials and methods: Prostate cancer patients referred for radiotherapy and whose planning-CT revealed a bowel loop trapped in the pelvis were proposed the procedure, followed by a new planning-CT. This proof-of-concept study reports postoperative follow-up and dosimetric benefits.

Results: The procedure was performed in ten patients (2016-2020) as a same-day surgery for nine. Median operative time was 34 minutes (range 22-50) and no relevant intraoperative complication occurred. The third patient of the series presented a small bowel hernia through the peritoneal suture at the 15th postoperative day requiring a laparotomic desincarceration without major consequences. Regarding the small bowel, median D1cc (dose to 1cc) was 65.5 Gy and 55.5 Gy (p=0.005) before and after procedure. Median V60 (volume receiving ≥ 60 Gy) was 10.2 cc and 0.0 cc (p=0.005). In the immediate vicinity of the small bowel (5mm), median D1cc was 68.3 Gy and 57.7 Gy (p=0.005). Radiotherapy was safely delivered to all patients.

Conclusion: Laparoscopic closure of the Douglas' pouch by a peritoneal suture is an efficient technique to cordon off inconvenient ectopic small bowel loops. It prevents excessive bowel irradiation and hence facilitates curative prostate radiotherapy. The technique could be applied to other pelvic malignancies.

Keywords

Prostatic neoplasm

Radiotherapy

Radiation-induced enteritis

Small bowel

Douglas' pouch

Laparoscopy

Manuscript

1. Introduction

Radiation therapy is a keystone treatment for prostate cancer that requires the delivery of high doses in the close vicinity of multiple organs at risk (OARs).[1,2] Bladder, sigmoid and rectum are radiation tolerant but the small bowel is much more sensitive [3] and chronic radiation-induced enteritis is a complication which can adversely affect a patient's quality of life.[4]

In most cases, when targeting pelvic tumors, the small bowel is not in close proximity to the area of highest dose delivery. Though, it may happen that an ectopic small bowel loop descends in the pelvis near the main target of treatment. This proximity can compromise the ability to deliver a curative dose despite the use of modern radiation techniques. To overcome this issue, a few surgical methods using implant of prosthetic material -such as intraabdominal prosthesis [5], tissue expanders [6] or biosynthetic meshes [7]- have been described to push the bowel away from the irradiation field.

We developed a minimally invasive prosthetic-free laparoscopic technique by closing the pouch of Douglas with a peritoneal running suture, which represents a fast and easy method requiring basic surgical skills. The aim of the present study is to report the feasibility of this procedure, its ability to prevent excessive small bowel irradiation and hence allow optimal treatment.

2. Materials and Methods

Beginning in December 2016, prostate cancer patients referred to our institution for exclusive or post-prostatectomy radiotherapy and whose planning-CT revealed the presence of small

bowel loops trapped in the pelvis which jeopardized an optimal treatment planning, were proposed a laparoscopic obturation of the pouch of Douglas, followed by a new radiation treatment planning with the hope of an improved dose distribution.

As a monocentric proof-of-concept study, we report the postoperative follow-up of all patients who benefited from this approach until June 2020 as well as the dosimetric benefits by comparing dose distribution before and after procedure.

Institutional review board approval was obtained from our center.

2.1. Surgical technique

The principle of this surgery is to seal the pouch of Douglas by employing a peritoneal running suture that joins the sigmoid loop, the pelvic brim and the dome of the bladder (**Figure 1**). In supine position, an umbilical incision is made and a 12-mm trocar is placed by an optical access technique. Carbon dioxide is insufflated into the abdominal cavity to a pressure of 10 mm of Hg. Then, one accessory trocar of 5 mm is placed in the left iliac fossa and a second one of 10 mm in a pararectal position in the left upper quadrant. If required, adhesiolysis is performed using cold scissors and bipolar forceps. The patient is placed in a steep Trendelenburg position, inclined around 30°. The small bowel prolapsed into the pouch of Douglas is grasped and cranially mobilized. A 3-0 absorbable suture with a loop length of 20 cm is introduced by the 10-mm trocar. The peritoneum is grasped and the suture is knotted at the right side of the pelvis lateral to the ureter and to the external iliac vessels. Then, the suture runs, joining the peritoneum from the mesosigmoid, the pelvic brim, and the dome of the bladder until reaching the left side of the pelvis where the end-knot is tied. Alternatively, the suture can be divided into two equal halves. The suture is carefully checked and, in case of a peritoneal breach, interrupted stitches are performed to reduce the risk of bowel incarceration through the peritoneal defect. Finally, the pneumoperitoneum is evacuated

through the trocars with the help of the Valsalva maneuver and the umbilical fascia and the skin are closed in the usual manner. Neither bowel preparation nor urinary catheterization are required as the partial filling of the bladder facilitates the grasp of the peritoneum. The postoperative care is carried out according to Enhanced Recovery After Surgery protocols.[8]

2.2. Radiotherapy and dosimetric analysis

Radiotherapy was exclusive or delivered as a post-prostatectomy salvage treatment. Concomitant/adjuvant androgen deprivation could be recommended. All patients were planned for intensity modulated radiation therapy (IMRT) delivered by volumetric modulated arc therapy (VMAT, Trubeam-Varian®). Contrast planning-CTs were performed before and after the laparoscopic closure of the pouch of Douglas (the so-called procedure), patient in the supine position with a foam positioner under the knees, empty rectum, and comfortably full bladder. The high-dose clinical target volume (CTV_{HD}) was the prostate or the tumor bed. When several dose levels were prescribed, the simultaneous integrated boost technique was used. Depending on the clinical situation, intermediate-dose and low-dose CTVs could be delineated. **Table 1** summarizes treatment planning protocols and margins applied from CTVs to planning target volumes (PTVs). OARs delineation followed the Radiation Therapy Oncology Group (RTOG) consensus for genitourinary tumors.[9] As such, the small bowel was included in the delineation of a bowel bag. Yet, because it is more radioresistant than the small bowel, any part of the sigmoid located in the pelvis was individually delineated.[10] Delineation was performed on pre and post-procedure planning-CTs by the same radiation oncologist. Inverse planning was conducted on both planning-CTs according to the ICRU 83 report with the mandatory goal of 95% of each PTV receiving $\geq 95\%$ of its corresponding dose prescription (D₉₅ $\geq 95\%$) while respecting OARs dose-constraints as far as possible.[11] The dose delivered to the OARs could then be compared before and after procedure. To highlight steep dose-gradient in the vicinity of the small bowel, the dose delivered to the

bowel plus a 5 mm expansion was recorded as well. All patients but one received a normofractionated treatment (<2.2 Gy/fraction). For the one patient moderately hypofractionated (60 Gy/20 fraction), the doses delivered to the OARs were reported as an equivalent-dose in 2 Gy per fraction (EQD2) assuming α/β of 2 Gy.

We tried to address the risk of undertreatment if the laparoscopic closure of the pouch of Douglas had not been performed but instead the inverse planning system had been forced to prioritize the small bowel protection against CTV_{HD} coverage. To do so, the optimization was reiterated on the pre-procedure planning-CT while enforcing a strict respect of OARs dose-constraints.

During treatment, daily positioning was performed with kV-kV portal images using bone landmarks (salvage radiotherapy) or intraprostatic fiducials (exclusive radiotherapy). A kV-CBCT was performed at least once for every patient before the first fraction of treatment to attest that the small bowel was actually away from PTV_{HD}.

2.3. Statistical analysis

All data were described by median and range for continuous variables. Dosimetric parameters before and after surgery were compared using Wilcoxon matched-pairs signed-ranks test.

3. Results

The laparoscopic closure of the pouch of Douglas was performed in 10 consecutive prostate cancer patients (7 exclusive and 3 salvage radiotherapy). Median age 76 year-old (66-84). Performance status 0-1. Median follow-up 27 months (6-46).

The surgical procedure was a same-day surgery for 9 patients. One patient was discharged on the first postoperative day due to current therapeutic-dose anticoagulation. Median operative

time from incision to skin closure was 34 minutes (range 22-50) and no intraoperative bleeding or relevant complication were observed.

One patient was admitted to the emergency department at the 15th postoperative day with sub-occlusion symptoms (abdominal pain, distension, nausea and vomiting). CT-scan and laparoscopic emergency procedure confirmed the herniation of a small bowel loop through the peritoneal suture. The surgery required a conversion to laparotomy to check the perfusion of the bowel and hopefully, no intestinal ischemia or damage was observed in the incarcerated segment. The radiotherapy could be delivered as planned. All nine other patients did not present any surgical complication.

Because recommendations for bladder and rectum filling on the days of planning-CTs and OARs delineation rules didn't vary, the volumes (cc) of those organs remained nearly constant before and after the procedure. For the bladder, 258 cc (60-544) and 270 cc (132-670), respectively (p=0.65). For the rectum, 73 cc (54-143) and 76 cc (48-168), respectively (p=0.44).

Table 2 and Figure 2 summarize the dosimetric comparison before and after the laparoscopic closure of the pouch of Douglas. Regarding the small bowel, the median D1cc (dose received by 1cc) was 65.5 Gy (62.2-73.3) and 55.5 Gy (2.7-60.1) before and after procedure, respectively (p=0.005). The median V60 (volume receiving ≥ 60 Gy) was 10.2 cc (1.6-29.6) and 0.0 cc (0.0-1.3), respectively (p=0.005). Considering the small bowel plus a 5 mm margin (close vicinity), the median D1cc was 68.3 Gy (65.0-75.6) and 57.7 Gy (3.6-61.4), respectively (p=0.005).

When the optimization was reiterated on the pre-procedure planning-CT forcing the system for prioritization of the small bowel protection (**Table 3, Figure 2**), it was possible to decrease the small bowel median D1cc from 65.5 Gy (62.2-73.3) to 59.8 (45.6-59.9)

($p=0.005$) but at the expense of the decrease of the median PTV_{HD} D95 (% of PTV_{HD} receiving $\geq 95\%$ of the prescribed dose) from 96.5% (94.9-97.6) to 94.9% (88.0-97.4) ($p=0.005$). The median D1cc for the small bowel plus 5 mm remained high at 67.2 Gy (64.0-74.9) highlighting persistence of a steep dose gradient close to that organ.

A median of 8 (1-41) CBCTs were performed during treatment. The small bowel remained isolated from the pelvis on every image. An example is presented **Figure 3**.

No small bowel related late toxicity was recorded.

4. Discussion

A dose/response relationship is well established for prostate cancer in the setting of exclusive and salvage radiotherapy.[1,2] The presence of an ectopic small bowel loop trapped in the pelvis may challenge the ability of fully delivering the required dose to target volumes and then obstruct the chance of cure. On the other hand, excessive dose to the small bowel risks radiation-induced enteritis, a chronic complication which can adversely affect a patient's quality of life.[4] This is of special concern in a population with expected long-survival.

Sharp dose fall-off provided by brachytherapy makes it the optimal approach to limit nearby OARs irradiation including the small bowel, but not all patients are candidates. Modern radiation techniques such as IMRT, VMAT and Tomotherapy can sharply conform isodoses to circumvent a specific OAR in the close vicinity of the target volume. However, when OAR's tolerance and target's requirement widely differ, there is sometimes no dosimetric solution to the intractable dilemma between undertreatment versus risk of harm. In our series, prioritizing the protection of the bowel impaired the dose received by 95% of PTV_{HD} below 95% of the prescribed dose ($D95 < 95\%$) for 5 out of 10 patients, reaching only 88% of the prescribed dose for 2 of them. For all patients, pushing the optimization process led to a very sharp dose gradient between the bowel and PTV_{HD} as shown by a median D1cc for the bowel

plus 5 mm of 67.2 Gy (64.0-74.9). One should be aware that such sharp dose gradient next to a mobile and/or deformable OAR such as the bowel increases the risk of the planning-treatment not being fully representative of the actual treatment delivery, even when 3D onboard images are used for patients repositioning.

Another common solution is to perform a planning-CT in the prone position on a belly board device but dosimetric advantages stay modest.[12–14] Moreover, a randomized trial emphasized less reproducible positioning and worse prostate mobility requiring larger CTV to PTV margins and resulting in increased delivery of high doses (≥ 60 Gy) to the small bowel.[15] A more comfortable feeling is also associated with the supine position. Nevertheless, because a significant decrease of small bowel volume within the vicinity of PTV can be obtained thanks to the prone position [16], we think the approach is worth being tested before proposing a surgical procedure, especially in the post-prostatectomy setting when target motion is less of an issue.

A few invasive surgical solutions have been described. The day-to-day transitory filling of the peritoneal cavity with nitrous oxide proposed by Cole et al has inherent limitations due to injection difficulty and instability.[17] Prosthetic material has been used to push the bowel away such as breast implants [5], saline-filled tissue expanders [6,18] and meshes [7,19–21], initially implanted using an open approach and later with laparoscopic procedure. Joyce et al. reported a significant decrease in the maximum point dose (Dmax) received by the small bowel going from a range of 63.9-75.8 Gy to 24.5-47.5 Gy without and with mesh implant, respectively (p=0.028).[22]

The use of prosthetic material has many disadvantages in comparison to the technique we described. These include a second surgery to remove the prosthesis with risk of bowel injury in an irradiated pelvis; a longer operative time and a longer length of stay with a median

duration above 80 minutes [7,23] and a 3-5 days hospitalization for meshes; a superior cost of the procedure due to the prosthetic material; the risk of implant rupture, even if it is low.[24] Moreover, publications with animal models have warned about the risk of intraperitoneal tumor growth associated to biosynthetic meshes which was not observed with biological meshes.[25,26] Priority should then be given to the use of native tissues.

Other prosthetic-free techniques have been described such as the use of an omental-J flap to fill the pouch of Douglas in women treated for cervical cancer but, in male patients, the lack of a solid organ in the middle compartment of the pelvis -such as the uterus- leaves a too large area to fill.[27] The sigmoid has also been used as a hammock fixated to the abdominal wall for treatment of metastatic Ewing's sarcoma but this was heavy surgical procedure with temporary colostomy.[28]

A single patient in our series presented a postoperative complication (bowel incarceration) requiring urgent surgery with a fast favorable outcome. This was probably due to a bowel internal herniation caused either by a postoperative tear in the peritoneum or by large bites of the running suture. Afterwards, we paid more attention to perform small bites and divided the running suture into two equal halves to reduce tension. The use of synthetic mesh has also been associated with this complication, but has the additional risk of bowel perforation and obstruction.[29]

To note, because the pouch of Douglas is closed but not sealed, the peritoneal fluid can flow into the pouch and then circulate back into the peritoneal cavity, thus limiting the risk of local collection. Even in the case of a complete pouch sealing caused by adhesion, the volume of fluid collected in the pouch would remain limited and therefore, asymptomatic. As a result, we didn't observe any case of symptomatic seroma of the pouch.

A dose-volume relationship has been described for radiation-induced small bowel toxicities in various pelvic malignancies but it is not well quantified.[30–33] Data come from the pre-IMRT era and are confounded by variations in the way that organ was delineated.[10] Emami et al. suggested a probability of 5% at 5 years (TD5/5) for severe chronic complications if more than 5% of the small bowel received >50 Gy in conventional fractionation.[34,35] The estimated TD50/5 (50% probability at 5 years) was 60 Gy for partial small bowel irradiation which was largely undocumented. More recently, the QUANTEC review [32] recommended $V_{45} < 195\text{cc}$ (mostly correlated to acute toxicity) and Kavanagh et al. [33] reported 2% to 9% late obstruction or perforation in case of partial small bowel irradiation >50 Gy.

The RTOG prostate consensus group [3] proposed a small bowel Dmax <52 Gy which appears quite conservative regarding recent IMRT data suggesting good toxicity profile beyond this limit. Ling et al. reported 94 abdominopelvic IMRT (median follow-up 20.1 months) with a median small bowel Dmax of 65.5 Gy.[36] The Dmax was >70 Gy in 22 patients and >80 Gy in 2 patients. Only 3 patients presented a grade 3 chronic toxicity. Of note, the small bowel receiving >60 Gy was limited to 10 cc and >70 Gy to 5 cc. Green and al. reported similar findings in 73 prostate cancer patients (median follow-up 2.5 years).[37] Twenty-five received >52 Gy to the small bowel (up to 80 Gy) and none presented grade ≥ 3 late toxicity. The mean volume receiving >60 Gy was 10 cc (0-34).

Although these data may reassure in delivering high doses to limited volumes of small bowel, uncertainties remain and caution is warranted especially regarding the very high doses (74-80 Gy) required for prostate cancer cure and the actual development of moderate and extreme hypofractionated schedules. In that setting, the RTOG 0415, CHHIP and PROFIT protocols that endorsed the non-inferiority of moderately hypofractionated radiotherapy required no contact between small bowel and PTV volumes and Duke University proposed $V_{40} < 1\%$

(<1% of the bowel receiving >40Gy) for a prescribed dose of 70 Gy in 28 fractions of 2.5 Gy.[38]

To our knowledge, our series is the first report of feasibility of a peritoneal running suture made by minimally invasive surgery to exclude the bowel from the pouch of Douglas before pelvic irradiation. However, we do recognize some weaknesses including the unicentric design and the occurrence of a complication that required urgent surgical management. Despite a limited number of patients inherent to the rarity of the situation, it is the longest series of patients treated for prostate cancer that have undergone a surgical suspension of the bowel prior to irradiation. This proof-of-concept study introduces an attractive technique that could be useful in many other malignancies such as bladder cancer, pelvic sarcoma or gynecologic cancers. It could also be of great interest when reirradiation is considered for local or regional recurrences in previously irradiated pelvis.

5. Conclusion

The laparoscopic closure of the pouch of Douglas by a peritoneal suture is a minimally invasive prosthetic-free technique that was successfully used to cordon off ectopic small bowel loops from the pelvis where their position compromised the optimal irradiation of prostate cancer patients. This is a fast and easy procedure requiring basic surgical skills. It prevents excessive small bowel irradiation and hence facilitates curative irradiation with no risk of late major intestinal complication. It could be applied to other pelvic malignancies.

Acknowledgements

The authors acknowledge the contribution of Frederique Recordon, medical dosimetrist.

References

- [1] Hou Z, Li G, Bai S. High dose versus conventional dose in external beam radiotherapy of prostate cancer: a meta-analysis of long-term follow-up. *J Cancer Res Clin Oncol* 2015;141:1063–71. <https://doi.org/10.1007/s00432-014-1813-1>.
- [2] King CR. The dose-response of salvage radiotherapy following radical prostatectomy: A systematic review and meta-analysis. *Radiother Oncol J Eur Soc Ther Radiol Oncol* 2016;121:199–203. <https://doi.org/10.1016/j.radonc.2016.10.026>.
- [3] Lawton CAF, Michalski J, El-Naqa I, Buyyounouski MK, Lee WR, Menard C, et al. RTOG GU Radiation Oncology Specialists Reach Consensus on Pelvic Lymph Node Volumes for High-Risk Prostate Cancer. *Int J Radiat Oncol Biol Phys* 2009;74:383–7. <https://doi.org/10.1016/j.ijrobp.2008.08.002>.
- [4] Stacey R, Green JT. Radiation-induced small bowel disease: latest developments and clinical guidance. *Ther Adv Chronic Dis* 2014;5:15–29. <https://doi.org/10.1177/2040622313510730>.
- [5] Sugarbaker PH. Intrapelvic prosthesis to prevent injury of the small intestine with high dosage pelvic irradiation. *Surg Gynecol Obstet* 1983;157:269–71.
- [6] McKay GD, Wong K, Kozman DR. Laparoscopic insertion of pelvic tissue expander to prevent radiation enteritis prior to radiotherapy for prostate cancer. *Radiat Oncol Lond Engl* 2011;6:47. <https://doi.org/10.1186/1748-717X-6-47>.
- [7] Bachmann R, Heinzelmann F, Müller AC, Ladurner R, Schneider CC, Königsrainer A, et al. Laparoscopic pelvic mesh placement with closure of pelvic floor entrance to prevent small intestine radiation trauma - A retrospective cohort analysis. *Int J Surg Lond Engl* 2015;23:62–7. <https://doi.org/10.1016/j.ijsu.2015.08.082>.
- [8] Melnyk M, Casey RG, Black P, Koupparis AJ. Enhanced recovery after surgery (eras) protocols: Time to change practice? *J Can Urol Assoc* 2011;5:342–8. <https://doi.org/10.5489/cuaj.11002>.
- [9] Gay HA, Barthold HJ, O'Meara E, Bosch WR, El Naqa I, Al-Lozi R, et al. Pelvic normal tissue contouring guidelines for radiation therapy: a Radiation Therapy Oncology Group consensus panel atlas. *Int J Radiat Oncol Biol Phys* 2012;83:e353-362. <https://doi.org/10.1016/j.ijrobp.2012.01.023>.
- [10] Yang H, Mir R, Díez P, Tsang Y, Conibear J, Simões R, et al. Provision of Organ at Risk Contouring Guidance in UK Radiotherapy Clinical Trials. *Clin Oncol R Coll Radiol G B* 2020;32:e60–6. <https://doi.org/10.1016/j.clon.2019.09.054>.
- [11] ICRU Report 83: Prescribing, recording and reporting photon-beam intensity modulated radiation therapy. *J Int Comm Radiat Units Meas* 2010;10. <https://doi.org/10.1093/jicru/10.1.Report83>.
- [12] Kim TH, Kim DY, Cho KH, Kim YH, Jung KH, Ahn J-B, et al. Comparative analysis of the effects of belly board and bladder distension in postoperative radiotherapy of rectal cancer patients. *Strahlenther Onkol Organ Dtsch Rontgengesellschaft AI* 2005;181:601–5. <https://doi.org/10.1007/s00066-005-1398-3>.
- [13] Pinkawa M, Gagel B, Demirel C, Schmachtenberg A, Asadpour B, Eble MJ. Dose-volume histogram evaluation of prone and supine patient position in external beam radiotherapy for cervical and endometrial cancer. *Radiother Oncol* 2003;69:99–105. [https://doi.org/10.1016/S0167-8140\(03\)00244-5](https://doi.org/10.1016/S0167-8140(03)00244-5).
- [14] Kószó R, Varga L, Fodor E, Kahán Z, Cserhádi A, Hideghéty K, et al. Prone Positioning on a Belly Board Decreases Rectal and Bowel Doses in Pelvic Intensity-Modulated Radiation Therapy (IMRT) for Prostate Cancer. *Pathol Oncol Res* 2019;25:995–1002. <https://doi.org/10.1007/s12253-018-0436-2>.

- [15] Bayley AJ, Catton CN, Haycocks T, Kelly V, Alasti H, Bristow R, et al. A randomized trial of supine vs. prone positioning in patients undergoing escalated dose conformal radiotherapy for prostate cancer. *Radiother Oncol J Eur Soc Ther Radiol Oncol* 2004;70:37–44. <https://doi.org/10.1016/j.radonc.2003.08.007>.
- [16] Sawayanagi S, Yamashita H, Ogita M, Kiritoshi T, Nakamoto T, Abe O, et al. Volumetric and dosimetric comparison of organs at risk between the prone and supine positions in postoperative radiotherapy for prostate cancer. *Radiat Oncol Lond Engl* 2018;13:70. <https://doi.org/10.1186/s13014-018-1023-0>.
- [17] Cole H. Displacement of Small Bowel From Pelvic Radiation Field. *The Lancet* 1988;332:1341–2. [https://doi.org/10.1016/S0140-6736\(88\)90872-0](https://doi.org/10.1016/S0140-6736(88)90872-0).
- [18] Hoffman JP, Sigurdson ER, Eisenberg BL. Use of saline-filled tissue expanders to protect the small bowel from radiation. *Oncol Williston Park N* 1998;12:51–4; discussion 54, 60, 62, passim.
- [19] Feldman MI, Kavanah MT, Devereux DF, Choe S. New surgical method to prevent pelvic radiation enteropathy. *Am J Clin Oncol* 1988;11:25–33. <https://doi.org/10.1097/00000421-198802000-00007>.
- [20] Soper JT, Clarke-Pearson DL, Creasman WT. Absorbable synthetic mesh (910-polyglactin) intestinal sling to reduce radiation-induced small bowel injury in patients with pelvic malignancies. *Gynecol Oncol* 1988;29:283–9. [https://doi.org/10.1016/0090-8258\(88\)90227-2](https://doi.org/10.1016/0090-8258(88)90227-2).
- [21] Rodier JF, Janser JC, Rodier D, Dauplat J, Kauffmann P, Le Bouedec G, et al. Prevention of radiation enteritis by an absorbable polyglycolic acid mesh sling. A 60-case multicentric study. *Cancer* 1991;68:2545–9. [https://doi.org/10.1002/1097-0142\(19911215\)68:12<2545::aid-cnrc2820681202>3.0.co;2-f](https://doi.org/10.1002/1097-0142(19911215)68:12<2545::aid-cnrc2820681202>3.0.co;2-f).
- [22] Joyce M, Thirion P, Kiernan F, Byrnes C, Kelly P, Keane F, et al. Laparoscopic pelvic sling placement facilitates optimum therapeutic radiotherapy delivery in the management of pelvic malignancy. *Eur J Surg Oncol* 2009;35:348–51. <https://doi.org/10.1016/j.ejso.2008.01.035>.
- [23] Joyce M, Thirion P, Kiernan F, Byrnes C, Kelly P, Keane F, et al. Laparoscopic pelvic sling placement facilitates optimum therapeutic radiotherapy delivery in the management of pelvic malignancy. *Eur J Surg Oncol J Eur Soc Surg Oncol Br Assoc Surg Oncol* 2009;35:348–51. <https://doi.org/10.1016/j.ejso.2008.01.035>.
- [24] Coroneos CJ, Selber JC, Offodile AC, Butler CE, Clemens MW. US FDA Breast Implant Postapproval Studies: Long-term Outcomes in 99,993 Patients. *Ann Surg* 2019;269:30–6. <https://doi.org/10.1097/SLA.0000000000002990>.
- [25] Lee PK, Windsperger AP, Wilson CM, McCarthy JB, Wasiluk KR, Rothenberger DA, et al. The Effect of a Hyaluronan-Carboxymethylcellulose Membrane vs. Polyglactin 910 Mesh on Intra-Abdominal Tumor Formation in Mice. *Dis Colon Rectum* 2008;51:1403–7. <https://doi.org/10.1007/s10350-008-9299-z>.
- [26] Guerry L, Matti U, Kaci R, Pocard M, Lo Dico R. Biosynthetic mesh increases peritoneal metastasis growth in animal model, the biological mesh does not! *Eur J Surg Oncol* 2019;45:e149. <https://doi.org/10.1016/j.ejso.2018.10.498>.
- [27] Leblanc E, Narducci F, Bresson L, Durand-Labrunie J, Taieb S, Vanlerenberghe E, et al. A new laparoscopic method of bowel radio-protection before pelvic chemoradiation of locally advanced cervix cancers. *Surg Endosc Interv Tech* 2014;28:2713–8. <https://doi.org/10.1007/s00464-014-3533-7>.

- [28] Irtan S, Mascard E, Bolle S, Brugières L, Sarnacki S. The small bowel in its hammock: how to avoid irradiation thanks to the sigmoid. *J Laparoendosc Adv Surg Tech A* 2015;25:77–80. <https://doi.org/10.1089/lap.2014.0270>.
- [29] Kokotovic D, Bisgaard T, Helgstrand F. Long-term recurrence and complications associated with elective incisional hernia repair. *JAMA - J Am Med Assoc* 2016;316:1575–82. <https://doi.org/10.1001/jama.2016.15217>.
- [30] Gallagher MJ, Brereton HD, Rostock RA, Zero JM, Zekoski DA, Poys LF, et al. A prospective study of treatment techniques to minimize the volume of pelvic small bowel with reduction of acute and late effects associated with pelvic irradiation. *Int J Radiat Oncol Biol Phys* 1986;12:1565–73. [https://doi.org/10.1016/0360-3016\(86\)90279-8](https://doi.org/10.1016/0360-3016(86)90279-8).
- [31] Roeske JC, Bonta D, Mell LK, Lujan AE, Mundt AJ. A dosimetric analysis of acute gastrointestinal toxicity in women receiving intensity-modulated whole-pelvic radiation therapy. *Radiother Oncol J Eur Soc Ther Radiol Oncol* 2003;69:201–7. <https://doi.org/10.1016/j.radonc.2003.05.001>.
- [32] Marks LB, Yorke ED, Jackson A, Ten Haken RK, Constine LS, Eisbruch A, et al. Use of normal tissue complication probability models in the clinic. *Int J Radiat Oncol Biol Phys* 2010;76:S10-19. <https://doi.org/10.1016/j.ijrobp.2009.07.1754>.
- [33] Kavanagh BD, Pan CC, Dawson LA, Das SK, Li XA, Ten Haken RK, et al. Radiation dose-volume effects in the stomach and small bowel. *Int J Radiat Oncol Biol Phys* 2010;76:S101-107. <https://doi.org/10.1016/j.ijrobp.2009.05.071>.
- [34] Emami B, Lyman J, Brown A, Coia L, Goitein M, Munzenrider JE, et al. Tolerance of normal tissue to therapeutic irradiation. *Int J Radiat Oncol Biol Phys* 1991;21:109–22. [https://doi.org/10.1016/0360-3016\(91\)90171-y](https://doi.org/10.1016/0360-3016(91)90171-y).
- [35] Emami B. Tolerance of Normal Tissue to Therapeutic Radiation. *Rep Radiother Oncol* 2013;1:123–7.
- [36] Ling A, Furhang E, Ryemon SN, Ennis RD. Late small bowel toxicity after aggressive abdominopelvic intensity modulated radiation therapy. *Adv Radiat Oncol* 2017;2:615–23. <https://doi.org/10.1016/j.adro.2017.09.005>.
- [37] Green G, Williams R, Zhang J, Azawi S. Dose-Volume Relationship of Acute and Late Small Bowel Toxicity From Radiation Therapy for Prostate Cancer: A Veteran Affairs Study. *Int J Radiat Oncol Biol Phys* 2014;90:S456. <https://doi.org/10.1016/j.ijrobp.2014.05.1427>.
- [38] Bekelman JE, Lee WR. Six Questions to Ask Before We Shorten Radiation Treatments for Intact Prostate Cancer. *Int J Radiat Oncol Biol Phys* 2017;97:718–21. <https://doi.org/10.1016/j.ijrobp.2016.11.038>.

Tables

Table 1: Internal protocols used for treatment planning (depending on the clinical situation).

Target volumes			
	<i>Volume</i>	<i>Margin to PTV</i>	<i>Prescription dose / number of fractions</i>
CTV_{HD}	- Prostate	- 7 mm/5 mm posterior	- 60 Gy/20 # OR 73.5-75.6 Gy/35-36 #
	- Operative bed (+/- recurrent nodule)	- 8 mm/6 mm posterior (5 mm around nodule)	- 66 Gy/33 # (69.3 Gy/33 #)
CTV_{ID}	- Seminal vesicles	- 10 mm/8mm posterior	- 63-64.8 Gy/35-36 #
CTV_{LD}	- Pelvic lymph nodes	- 5 mm	- 57.75-59.4 Gy/35-36 # OR 54.45 Gy/33 #
Organs at risk dose constraints[#]			
Rectum	D1cc \leq 76 Gy; V74 < 5%; V70 < 25%; V60 < 50%		
Sigmoid	D1cc as low as possible (\leq 76 Gy)		
Bladder	D1cc \leq prescription dose; V70 < 25%; V60 < 50%		
Small bowel	D1cc \leq 60 Gy; V45 < 150 cc; V15 < 830 cc		

CTV: clinical target volume, PTV: planning target volume

HD: high dose; ID: intermediate dose; LD: low dose

D1cc: dose received by 1cc of the organ; VX: volume of the organ (% or cc) receiving \geq X Gy

only valid for normofractionated treatments not for hypofractionated treatments (60 Gy/20 fractions)

Table 2: Dosimetric comparison before and after the laparoscopic closure of the pouch of Douglas by a peritoneal running suture. Both treatment plannings were performed prioritizing the adequate coverage of PTV_{HD}.

	Planning pré-procedure	Planning post-procedure	p
Small bowel			
D1cc (Gy)	65.5 (62.2-73.3)	55.5 (2.7-60.1)	0.005
V45 (cc)	166.0 (4.8-528.0)	135.5 (0.0-298.0)	0.20
V60 (cc)	10.2 (1.6-29.6)	0.0 (0.0-1.3)	0.005
Small bowel + 5mm			
D1cc (Gy)	68.3 (65.0-75.6)	57.7(3.6-61.4)	0.005
Rectum			
D1cc (Gy)	69.7 (59.5-74.3)	72.4 (66.0-74.9)	0.26
V70 (%)	2.6 (0.0-7.7)	3.5 (0.0-9.0)	0.79
V60 (%)	13.3 (2.7-22.9)	12.9 (5.3-35.0)	0.44
Bladder			
D1cc (Gy)	73.8 (67.1-75.8)	73.4 (66.8-76.1)	0.14
V70 (%)	13.7 (0.0-39.0)	12.2 (0.0-35.6)	0.44
V60 (%)	48.2 (15.6-60.4)	40.1 (23.1-69.6)	0.68
PTV_{HD}			
D95 (%)	96.5 (94.9-97.6)	96.5 (95.6-97.4)	0.80

Results are presented as median (range).

D1cc: dose (Gy) received by 1cc of the volume

VX: volume (cc or %) receiving $\geq X$ Gy

D95: volume (%) receiving $\geq 95\%$ of the prescribed dose.

PTV_{HD}: high-dose planning target volume.

Table 3: Dosimetric comparison when the optimization was performed prioritizing the adequate coverage of PTV_{HD} versus the protection of the small bowel. Both treatment plannings were performed on the pre-procedure planning-CT.

	Priority to PTV _{HD} coverage	Priority to bowel protection	p
Small bowel			
D1cc (Gy)	65.5 (62.2-73.3)	59.8 (45.6-59.9)	0.005
V45 (cc)	166.0 (4.8-528.0)	164.0 (1.0-571.0)	0.92
V60 (cc)	10.2 (1.6-29.6)	0.7 (0.1-4.5)	0.005
Small bowel + 5mm			
D1cc (Gy)	68.3 (65.0-75.6)	67.2 (64.0-74.9)	0.005
Rectum			
D1cc (Gy)	69.7 (59.5-74.3)	71.8 (65.8-74.6)	0.79
V70 (%)	2.6 (0.0-7.7)	2.6 (0.0-7.5)	0.03
V60 (%)	13.3 (2.7-22.9)	12.6 (1.9-16.9)	0.04
Bladder			
D1cc (Gy)	73.8 (67.1-75.8)	73.7 (67.2-78.2)	0.50
V70 (%)	13.7 (0.0-39.0)	12.6 (0.0-37.6)	0.04
V60 (%)	48.2 (15.6-60.4)	47.2 (15.4-58.6)	0.02
PTV_{HD}			
D95 (%)	96.5 (94.9-97.6)	94.9 (88.0-97.4)	0.005

Results are presented as median (range).

D1cc: dose (Gy) received by 1cc of the volume

VX: volume (cc) receiving $\geq X$ Gy

D95: volume (%) receiving $\geq 95\%$ of the prescribed dose.

PTV_{HD}: high-dose planning target volume.

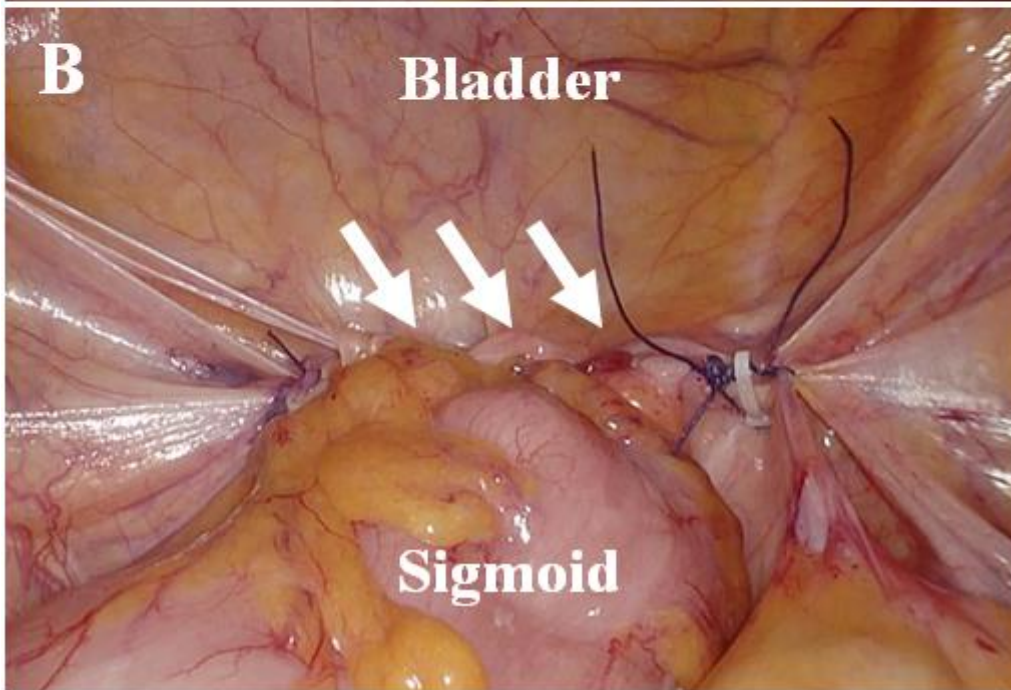
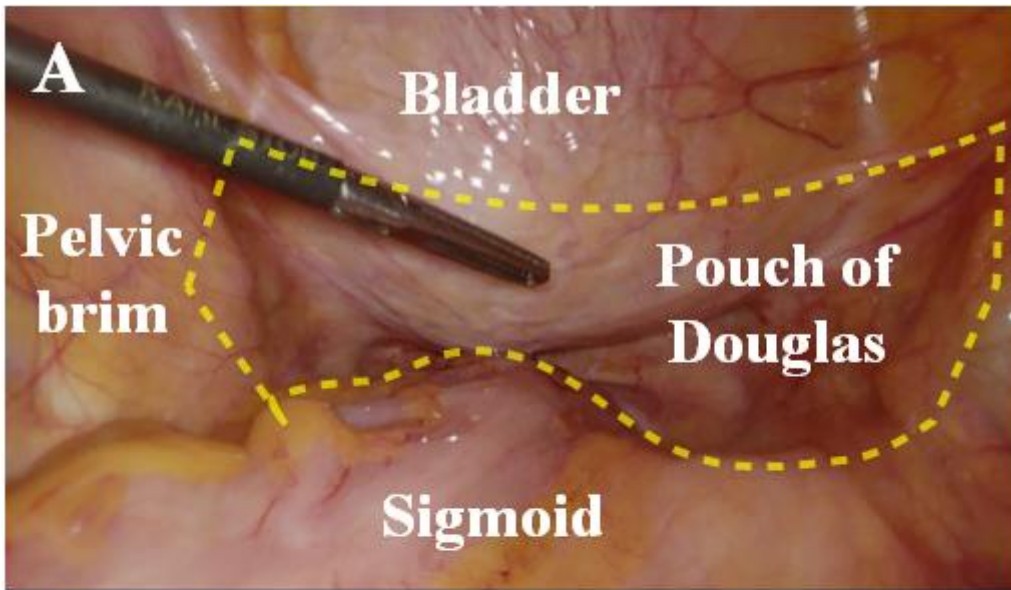
Figure 1: Laparoscopic view of the pelvis during the surgical procedure.

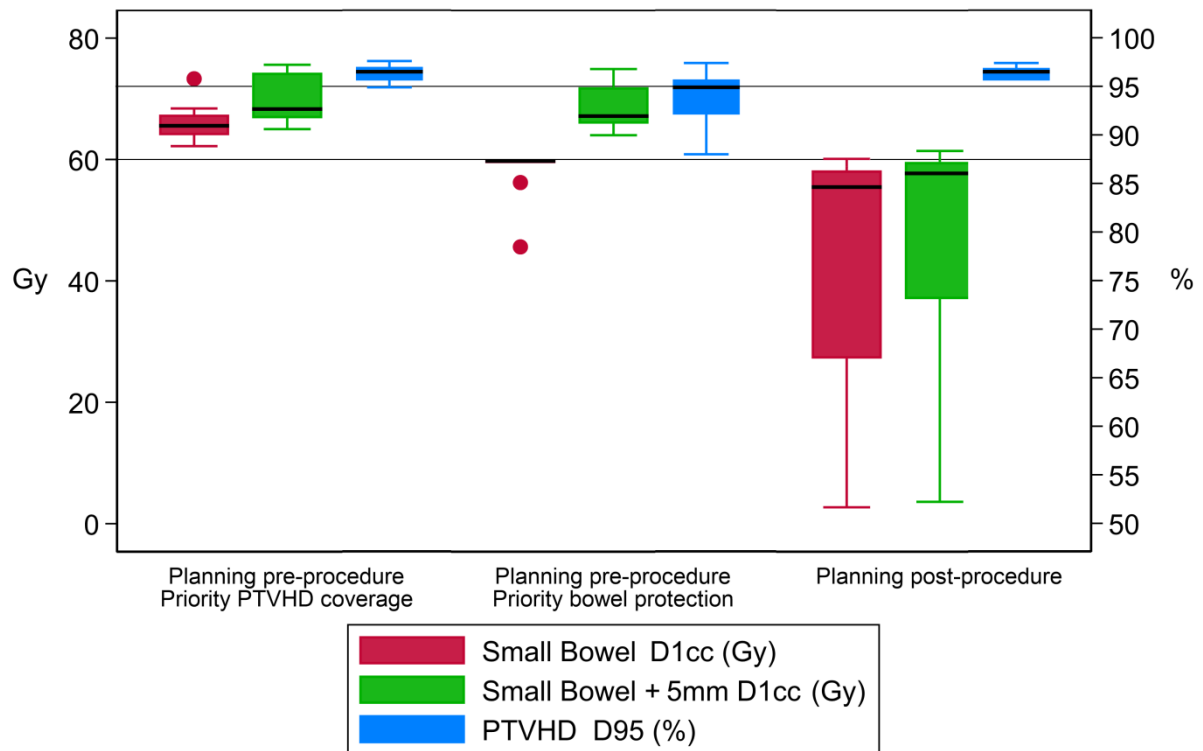
A: Initial view with a yellow dotted line indicating the surgical edges of the peritoneal running suture. **B:** Final view after the closure of the pouch of Douglas with white arrows indicating the running suture. Notice the complete obliteration of the pouch of Douglas.

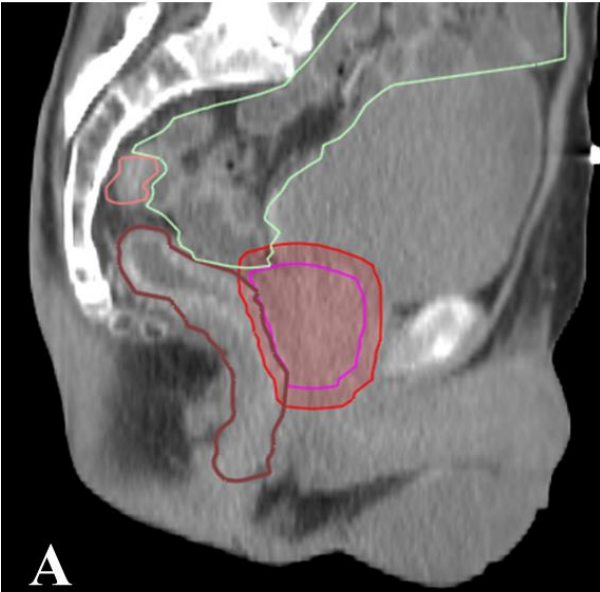
Figure 2: Boxplot depicting the main dosimetric data obtained from treatment planning performed before the laparoscopic closure of the pouch of Douglas (with priority given to PTV_{HD} coverage or to the small bowel protection) and treatment planning performed after the procedure.

Figure 3: A visual example of the small bowel location before and after the laparoscopic closure of the pouch of Douglas by a peritoneal running suture (patient #10).

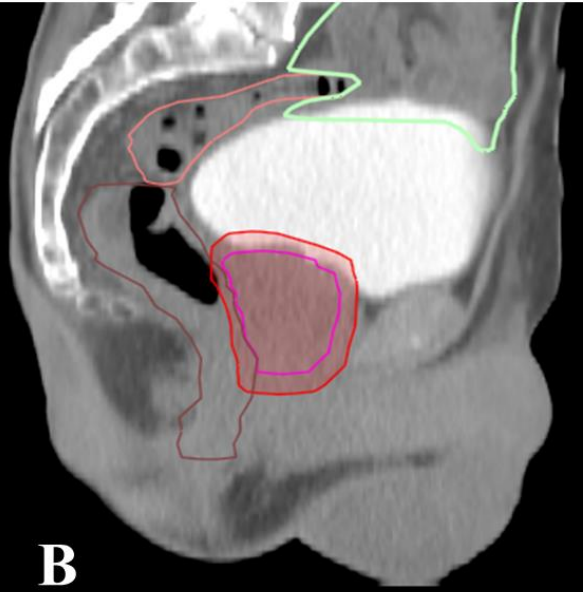
A: Preoperative planning-CT. **B:** Postoperative planning-CT. **C:** Image of the operating procedure. The sigmoid is used to seal the pouch of Douglas. The peritoneal suture (*white arrows*) joins the peritoneum from the sigmoid, the dome of the bladder and the pelvic brim. **D:** kV-CBCT performed before the first fraction of treatment with the overlay of the main volumes of interest. (*Green:* small bowel, *brown:* rectum, *orange:* sigmoid, *pink:* prostate, *red:* high-dose planning target volume).



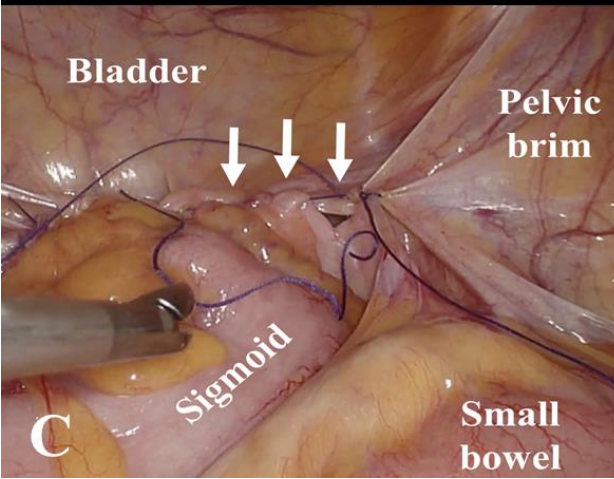




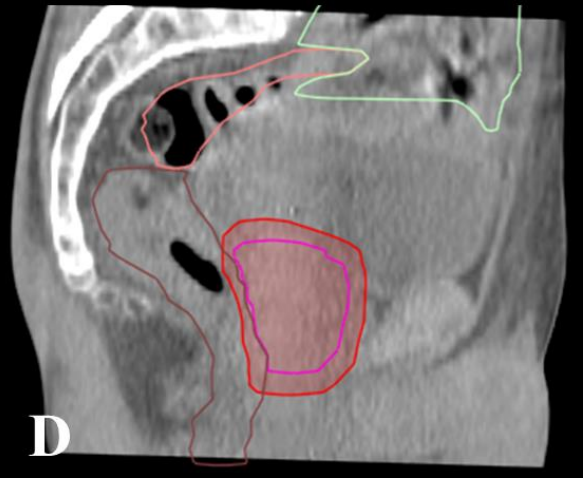
A



B



C



D