



HAL
open science

Outcomes of laparoscopic and open surgical treatment of intestinal malrotation in children

Aurélien Scalabre, Igor Duquesne, Jérôme Deheppe, Guillaume Rossignol, Sabine Irtan, Alexis Arnaud, Quentin Ballouhey, Olivier Abbo, Pierre-Yves Rabattu, Aurélien Binet, et al.

► To cite this version:

Aurélien Scalabre, Igor Duquesne, Jérôme Deheppe, Guillaume Rossignol, Sabine Irtan, et al.. Outcomes of laparoscopic and open surgical treatment of intestinal malrotation in children. *Journal of Pediatric Surgery*, 2020, 55, pp.2777 - 2782. 10.1016/j.jpedsurg.2020.08.014 . hal-03493005

HAL Id: hal-03493005

<https://hal.science/hal-03493005>

Submitted on 15 Dec 2022

HAL is a multi-disciplinary open access archive for the deposit and dissemination of scientific research documents, whether they are published or not. The documents may come from teaching and research institutions in France or abroad, or from public or private research centers.

L'archive ouverte pluridisciplinaire **HAL**, est destinée au dépôt et à la diffusion de documents scientifiques de niveau recherche, publiés ou non, émanant des établissements d'enseignement et de recherche français ou étrangers, des laboratoires publics ou privés.



Distributed under a Creative Commons Attribution - NonCommercial 4.0 International License

Outcomes of laparoscopic and open surgical treatment of intestinal malrotation in children

Aurélien Scalabre¹, Igor Duquesne², Jérôme Deheppe¹, Guillaume Rossignol³, Sabine Irtan², Alexis Arnaud⁴, Quentin Ballouhey⁵, Olivier Abbo⁶, Pierre-Yves Rabattu⁷, Aurélien Binet⁸, François Varlet¹

¹Department of Pediatric Surgery, CHU de Saint-Etienne, Saint-Etienne, France.

²Department of Pediatric Surgery, Trousseau Hospital - Assistance Publique des Hôpitaux de Paris, Paris, France.

³Department of Pediatric Surgery, Hospices Civils de Lyon, France

⁴Department of Pediatric Surgery, CHU de Rennes, Rennes, France.

⁵Department of Pediatric Surgery, CHU de Limoges, Limoges, France.

⁶Department of Pediatric Surgery, CHU de Toulouse, Toulouse, France.

⁷Department of Pediatric Surgery, CHU de Grenoble, Grenoble, France.

⁸Department of Pediatric Surgery, CHU de Tours, Tours, France.

Corresponding author:

Dr Aurélien Scalabre, MD, PhD,

aurelien.scalabre@chu-st-etienne.fr

Department of Pediatric Surgery, CHU de Saint-Etienne, Hôpital Nord, Avenue Albert Raimond,

42055 Saint-Etienne cedex 2, France

Introduction

The standard surgical procedure to treat malrotation and prevent midgut volvulus was described in 1936 by William E. Ladd [1]. It is performed through a transverse incision in the upper abdomen, followed by counterclockwise detorsion of midgut volvulus if present, division of the bands between the cecum and the duodenum, widening of the mesenteric root to prevent further volvulus, positioning of intestines into the nonrotation configuration, and often appendectomy to prevent future diagnostic confusion.

Laparoscopic surgery for intestinal malrotation was first reported in 1995, and has become more popular over the years [2]. The potential benefits of laparoscopic surgery are increased visualization, smaller incisions, lower post-operative pain, shorter length of stay, better cosmesis and decreased rate of adhesive bowel obstruction and wound infection [3,4]. However, the effectiveness and the safety of this approach for the treatment of malrotation and midgut volvulus remain controversial [5]. The decreased post-operative adhesion formation after laparoscopy theoretically lessens the risk of post-operative small bowel obstruction, but it could also be associated with a greater risk of post-operative volvulus [3,6]. The feasibility of the Ladd's procedure using a laparoscopic approach is also debated in neonates with acute midgut volvulus [7,8].

Objective:

This study aims to compare the outcomes of laparoscopic and open surgical treatment of intestinal malrotation in children.

Methods:

Following institutional approval, a multicentric retrospective study was conducted including all consecutive pediatric cases of intestinal malrotation operated on between 2005 and 2016 in 8 pediatric surgery departments. Patients were identified through operating rooms records. Only patients aged less than 18 years were included. Patients with a previous surgical treatment of intestinal atresia, gastroschisis, omphalocele or diaphragmatic hernia were excluded, because in such cases the pathophysiology of intestinal malrotation is different. Analyzed data included demographic data, clinical and imaging findings, surgical reports, peroperative and post-operative complications and outcomes Data were collected by

a surgeon from each center and compiled in an anonymized database. Patients were divided in groups: elective surgery for intestinal malrotation or emergency surgery (according to reports from the medical files), and neonates or patients aged > 1 year. Elective procedures were scheduled days or weeks in advance, while emergency procedures were performed as soon as possible after diagnosis. Surgeons choose to operate either by laparoscopy or by laparotomy, based on the clinical presentation of each patient, their experience and personal preference.

All patients underwent the classic Ladd's procedure. Regardless of the chosen approach, the abdomen was first inspected for the presence of volvulus, the viability and the rotational status of the bowel, before performing derotation. The next steps of the procedure were adhesiolysis of peritoneal bands, widening the root of the mesentery by incising the peritoneum and gaining length between the vascular arcades of the superior mesenteric artery, appendectomy and positioning the small bowel on the right side of the abdomen and the cecum and colon on the left side. Patients were discharged after regaining full feeds.

The overall complications rate was calculated in each group (number of patients with at least one reported complication divided by the total number of patients in the group).

Statistics

Data were reported as median and ranges for continuous variables and percentages for categorical variables. The normality of the distribution was assessed using the Shapiro-Wilk test. None of the analyzed variables showed compliance with a normal distribution. Therefore, the Fisher exact test was used for categorical variables and the Mann-Whitney test was used for continuous variables to determine differences between groups. All statistical tests were performed with a p-value < 0.05 considered to be significant.

A multivariate analysis with linear regression was performed with incorporation of significant factors at the limit of $p < 0.20$ after univariate analysis. Statistical calculations were performed using SPSS ® version 23.0 software.

Results

227 children (87 females and 140 males) with a mean age of 1.6 years \pm 3.5 (median age of 17 days, range 1 day to 17.2 years) were included. 166 (73.1%)

patients had an emergency procedure and 61 (26.9%) had an elective Ladd's procedure. Demographic and clinical data are summarized in **Table 1**.

Twenty-seven patients (11.9%) were asymptomatic and the diagnosis of intestinal malrotation was made incidentally by ultrasonography and further confirmed by upper gastrointestinal contrast study (UGI).

Flow diagrams showing the chosen approaches, the diagnosis of midgut volvulus and outcomes are presented in **Figure 1** for elective surgeries and **Figure 2** for emergency procedures.

Amongst 61 children who underwent elective surgery, 13 (21.3%) had midgut volvulus, although there was no intestinal ischemia. Two of them were asymptomatic and the 11 others suffered from chronic abdominal pain (6/11), vomiting (6/11) and abnormal intestinal transit (constipation or diarrhea) (5/11).

Overall, 46 (20.3%) procedures were started by laparoscopy and 181 (79.7%) by laparotomy. The choice of a laparoscopic approach was more frequent for elective surgery than for emergency procedures (45.9%, 28/61 vs 10.8%, 18/166) ($p < 0.001$) (Table 2 and Table 3). The percentage of procedures started by laparoscopy was variable (from 3.5% to 66.7%) between centers. The overall conversion rate was 37.0% (17/46). Conversions were significantly more frequent during emergency procedures (66.7%, 12/18) than during elective surgeries (17.9%, 5/28) ($p = 0.001$). Among 161 patients with midgut volvulus, 13 (8.1%) required a bowel resection. Patients younger than 6 months were more likely to have a volvulus than older patients (78.9%, 127/161 vs 51.5%, 24/66) ($p < 0.001$). Outcomes after laparoscopy and laparotomy were compared in the group of patient aged < 1 year and in older children (Table 4 and Table 5).

Three patients treated for a midgut volvulus died 1 hour, 2 days and 4 days after surgery, and 5 other patients had short bowel syndrome at last news.

Twenty-two children experienced post-operative small bowel obstruction secondary to adhesions after a median time of 2.6 months (range 0-79.2, mean 14.7 +/- 20.1). Two were treated conservatively with no oral intake, nasogastric intubation and intravenous rehydration. Twenty required surgical treatment.

There were 13 post-operative volvulus after a median time of 5.5 months (range 0.2-12.8, mean 5.6 +/- 5.3), including 12 recurrences of volvulus and 1 volvulus in a child

initially operated on for a malrotation without volvulus. There were 4 incisional hernias in the group of children operated on by laparotomy. Overall 39 children had complications requiring another abdominal surgery, either because of small bowel obstruction, midgut volvulus, incisional hernia or short bowel syndrome.

Patients operated on by laparoscopy were older than patients operated on by laparotomy (including laparoscopy converted to laparotomy) (4.27 years \pm 4.80 vs 0.93 years \pm 2.78, $p < 0.001$). The mean operative time (100 min \pm 41 by laparoscopy and 89 min \pm 39 by laparotomy, $p = 0.4$) (missing data in 41 cases) and the mean hospital stay (6.2 days \pm 6.3 by laparoscopy and 12.7 days \pm 17.5 by laparotomy, $p = 0.2$) were not significantly different. The youngest child treated by laparoscopy without conversion was 3 days old. After a median follow-up of 11.6 months (range 1-127, mean 23.5 \pm 30.4, no significant differences were found between laparoscopy and laparotomy considering the overall post-operative complication rate (17.2% (5/29) vs 22.2% (4/198), $p = 0.6$), the rates of post-operative volvulus (10.3% (3/29) vs 5.1% (10/198), $p = 0.2$), post-operative bowel obstructions (6.9% (2/29) vs 10.1% (20/198), $p = 0.7$), and post-operative incisional hernias (0%, 0/29 vs 2.0%, 4/198) ($p = 1$).

The comparison between the outcomes of laparoscopy and laparotomy in the subgroups of elective surgeries and emergency procedures is shown in **tables 2 and 3**.

Elective surgeries

Considering only elective surgeries, the mean operative time and the mean hospital stay were significantly shorter in the laparoscopy group (77 min \pm 14 vs 100 min \pm 35, $p = 0.04$; and 5.3 days \pm 5.2 vs 10.1 days \pm 13, $p = 0.01$).

The mean operative time was not significantly different in patients undergoing initial laparoscopic surgery (completed laparoscopies and conversions) compared to patients undergoing initial laparotomy. (98 min \pm 37 vs 92.2 \pm 24, $p = 0.7$) The frequency of post-operative volvulus was significantly higher in the laparoscopy group (13% vs 0%, $p = 0.04$), but the overall complication rate was not significantly different (15.8% after laparotomy vs 21.7% after laparoscopy, $p = 0.7$).

Emergency procedures

Considering emergency procedures, outcomes were not significantly different when comparing the two approaches. Amongst 166 emergency surgeries, only 6 (3.6%) Ladd's procedures were completed by laparoscopy without conversion.

Hospital stay

The mean hospital stay was significantly shorter in children aged > 1 year (7.4 days +/-10.7) compared with neonates (13.4 days +/-17.9)(p=0.003). It was also significantly shorter after electives surgeries (8.2 days +/-10.8) than after emergency procedures (13.2 days +/-18.1) (p=0.04), and shorter in the laparoscopy group (6.2 days +/-1.2 vs 12.7 +/-17.5 in the laparotomy group) (p<0.001). Length of stay was not statistically associated with other factors, especially sex, volvulus or associated malformations. None of these factors were associated with the length of stay after multivariate statistical analysis.

Discussion

Laparoscopy has progressively become the standard of care replacing the conventional open approach in a large number of standard procedures, such as appendectomy or cholecystectomy, but its indications for the treatment of intestinal malrotation remain controversial. This large series of intestinal malrotation in children highlights the pros and cons of the laparoscopic approach.

We confirmed the feasibility of the technique, as the present series includes 5 children with intestinal malrotation and midgut volvulus who underwent a complete laparoscopic Ladd's procedure without any intra or post-operative complication. The choice of a laparoscopic approach was not associated with a longer operative time. Although post-operative pain and cosmetic results were not evaluated in this retrospective study, the mean hospital stay after elective laparoscopic Ladd's procedure was shorter than after laparotomy, as previously reported by other authors [3,9-11]. Stanfill et al. showed that patients are discharged earlier after laparoscopy because the time to starting feeds and amount of time to reach full feeding is less than after laparotomy [11].

Laparoscopy is also highly beneficial when the diagnosis of malrotation is uncertain [5,8,9,12,13].

The main issue regarding the better surgical approach for the treatment of malrotation is the rate of postoperative complication. In a large metaanalysis including 744 open and 259 laparoscopic Ladd's procedure, Catania et al. found a significantly higher rate of post-operative complication after open surgery (22%) in comparison to laparoscopy (13.7%) [3]. We found comparable results in the present study, although the difference was not significant, probably because of a smaller cohort.

Another controversy is the minimum age required to perform an effective laparoscopic Ladd's procedure. Previous authors stated that the laparoscopic approach couldn't be recommended in neonates due to limited working space and vision [14]. In our series the youngest patient operated on by laparoscopy was 3 days old, which proves that an experienced surgical team can perform this surgery in neonates using adequate 3 mm diameter instrumentation [4,7,13,15,16]. However, mobilization of the gut is easier in older children and consistently with previous studies, patients operated on by laparoscopy were older than patients operated on by laparotomy in the present series [3,4,8-11,14].

Although the laparoscopic approach is associated with less post-operative pain, shorter time to reach full feed, less scaring and fewer post-operative complications than laparotomy, it is not without downsides and the open approach remains more popular for the time being [17].

The laparoscopic procedure is difficult to achieve and should not be attempted by junior clinicians without the help of an experienced laparoscopic surgeon. This technique needs a degree of expertise and excellent vision of the operative field. It is essential to proceed from known landmarks to unknown, carefully identifying digestive structures without creating torsion. At the end of the dissection, one should be able to follow the straightened duodenum and the wide-base mesentery. In the context of volvulus with small bowel obstruction, the intestinal dilatation makes the working space smaller and mobilization of the small bowel more difficult. Complete derotation of the bowel can be difficult to assess due to limited vision. The risk of intestinal perforation is high when manipulating ischemic bowel, and grasping of the ischemic segments should be avoided [7]. Moreover, Ischemia caused by midgut volvulus can lead to intestinal necrosis, which requires conversion to laparotomy and bowel resection. In the present series, 8.1% of patients with midgut volvulus needed bowel resections, which is consistent with the rate of 10% previously reported in a

large series of 292 patients [18]. The delay caused by hospital-to-hospital transfer and cardiac comorbidities are identified risk factors for bowel resection [18,19]. The laparoscopic approach should be performed only on selected cases, hemodynamically stable, with an early diagnosis after presentation [7]. These difficulties explain why pediatric surgeons were more prone to choose open approach for emergency surgery, while laparoscopy was more frequent in the group of elective surgery.

Moreover, the major concern with the laparoscopic treatment of malrotation is the risk of recurrent midgut volvulus. As laparoscopy creates fewer adhesions than laparotomy, it is believed to be associated with a higher risk of recurrent midgut volvulus [9,17]. Previous studies have reported contradictory results regarding this risk of recurrence after laparoscopic Ladd's procedure ranging from 0 to 30% [4,10,11,14,20-22]. We reported a higher risk of post-operative volvulus after elective laparoscopic Ladd's procedure compared with laparotomy. The metaanalysis by catania et al. showed that the incidence of post-operative volvulus was 3.5% after laparoscopy and 1.4% after laparotomy [3]. Recurrences typically occur within 6 months after surgery, but we report a case of volvulus diagnosed at 13 post-operative months and this risk should not be underestimated in the long term [4].

While post-operative volvulus is more frequent after a laparoscopic approach, laparotomy is commonly believed to be associated with more adhesion formation and a higher risk of post-operative bowel obstruction [17]. We reported an incidence of 10% of small bowel obstruction following open Ladd's procedure, consistently with previous study reporting rates of 0% to 15%. Two patients who were operated on by laparoscopy also suffered from post-operative small bowel obstruction, but their symptoms were moderate and ultimately they were managed conservatively. To our knowledge no study confirmed that open Ladd's procedure would be associated with a higher risk of post-operative small bowel obstruction, although this remains a common belief [17].

We emphasize that our results should be interpreted with caution, as patients operated on by laparoscopy were older than patients operated on by laparotomy in our series, and the two groups are therefore not completely comparable. Patients were also more severe and midgut volvulus was more frequent in the laparotomy group. A prospective study comparing the outcomes of both approaches is needed.

Managing a child with intestinal malrotation, the main focus of the pediatric surgeon should always be the treatment and prevention of midgut volvulus. Thus, conversion to an open procedure should be done with a low threshold when there is any doubt that an adequate result can be reached laparoscopically [15,20].

As a matter of fact, we found conversion to be significantly more frequent during emergency procedures. Catania et al. reported a conversion rate of 25%, mostly because of inadequate view and impossibility to reduce midgut volvulus [3]. Previous studies have also shown that conversions are more frequent in the beginning of a surgeon experience, which suggests an important learning curve for this challenging procedure [4,10]. This can also explain the high variability in previously reported rates of conversion between 8 and 73% [3,4,10,14,17,20-22]. The parents must be aware of a potential conversion from laparoscopy to open surgery before starting procedure [7].

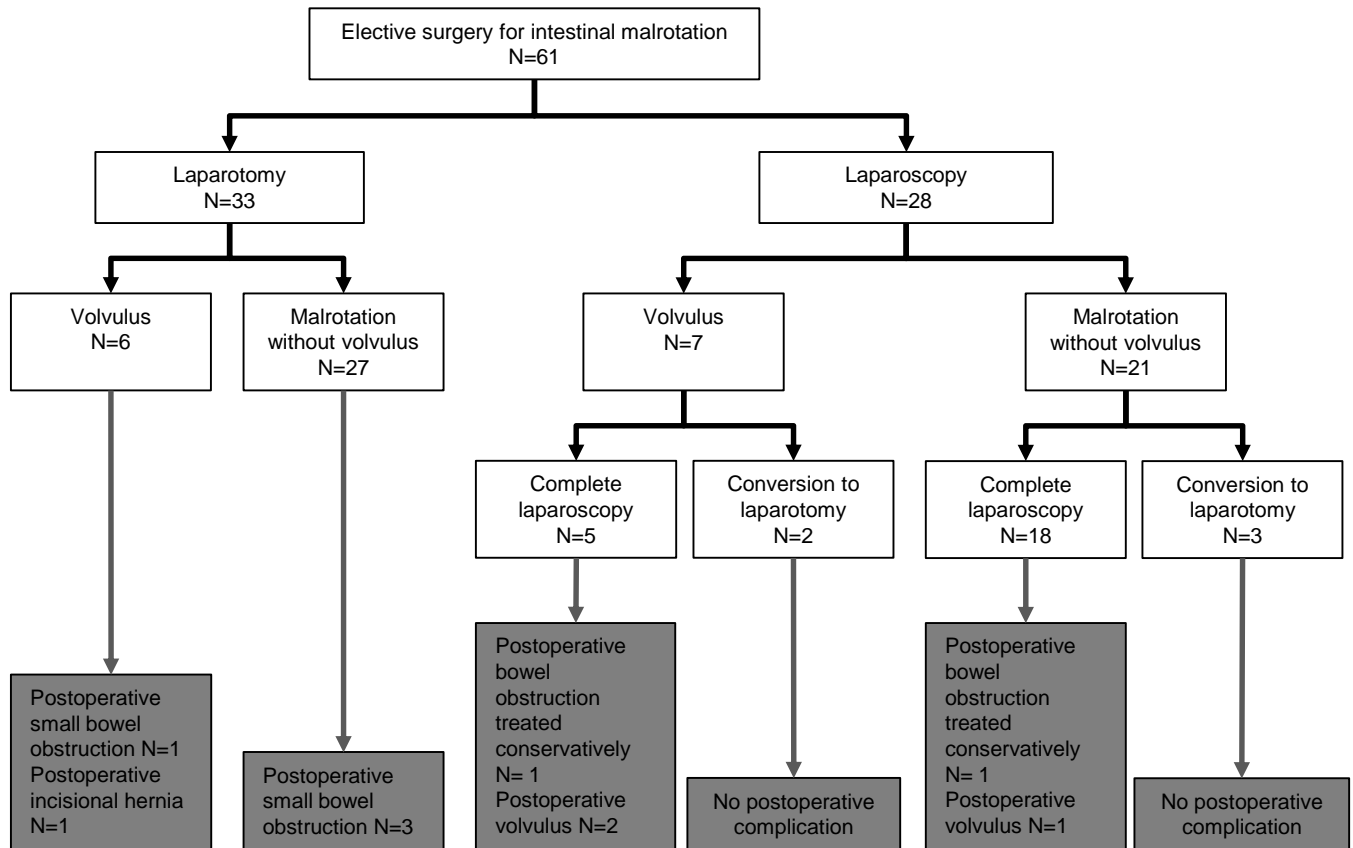
Conclusion

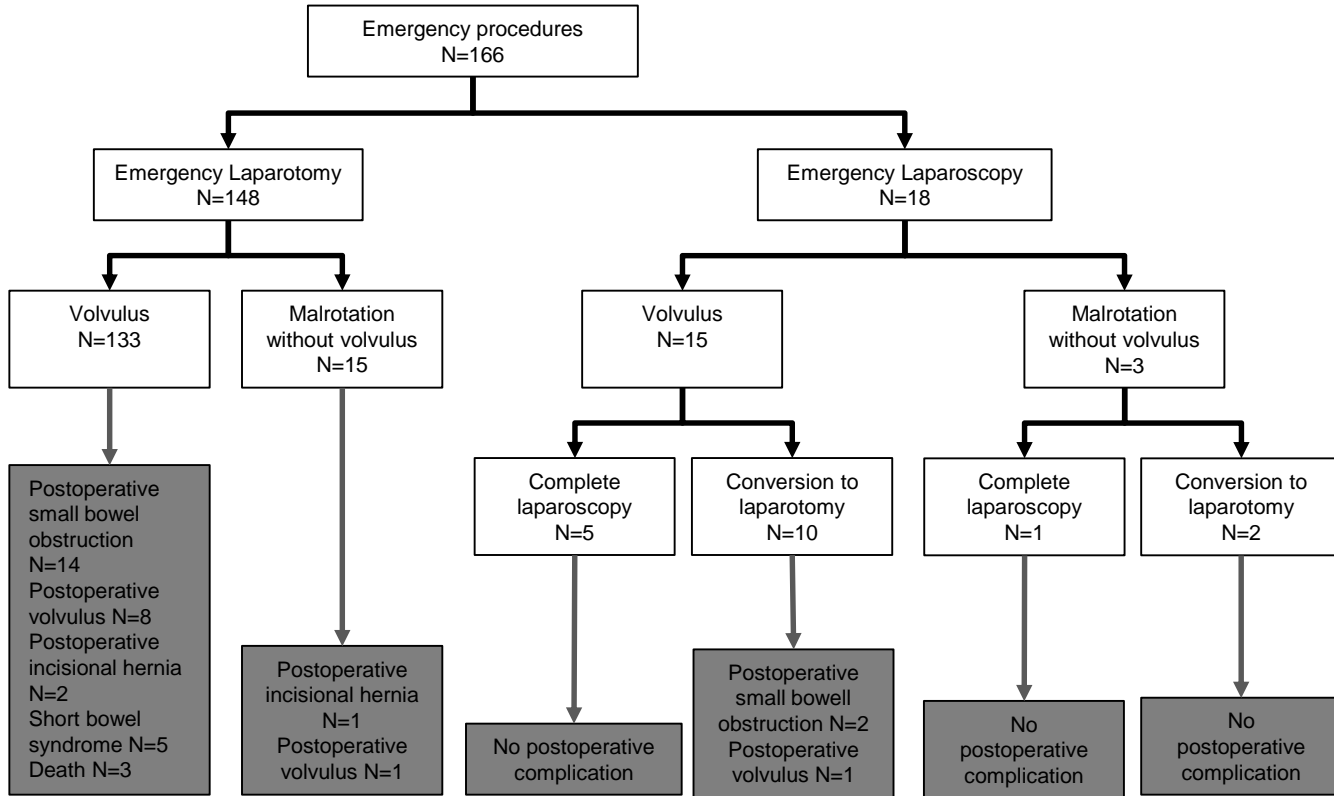
If performed by an experienced surgical team, the treatment of intestinal malrotation can be achieved by a laparoscopic approach, even in neonates with midgut volvulus. However, conversion to open surgery should be done with a low threshold, as the rate of volvulus recurrence is concerning.

References

1. Ladd W. Surgical diseases of the alimentary tract in infants. *N Engl J Med* 1936;17:705-8.
2. van der Zee DC, Bax NM. Laparoscopic repair of acute volvulus in a neonate with malrotation. *Surg Endosc* 1995;9:1123-4.
3. Catania VD, Lauriti G, Pierro A, Zani A. Open versus laparoscopic approach for intestinal malrotation in infants and children: a systematic review and meta-analysis. *Pediatr Surg Int* 2016;32:1157-64.
4. Arnaud AP, Suply E, Eaton S, Blackburn SC, Giuliani S, Curry JI, et al. Laparoscopic Ladd's procedure for malrotation in infants and children is still a controversial approach. *J Pediatr Surg* 2019;54:1843-7.
5. Graziano K, Islam S, Dasgupta R, Lopez ME, Austin M, Chen LE, et al. Asymptomatic malrotation: diagnosis and surgical management: an American Pediatric Surgical Association outcomes and evidence based practice committee systematic review. *J Pediatr Surg* 2015;50:1783–90.
6. Isani MA, Schlieve C, Jackson J, Elizee M, Asuelime G, Rosenberg D, et al. Is less more? Laparoscopic versus open Ladd's procedure in children with malrotation. *J Surg Res* 2018;229:351-6.
7. Kalfa N, Zamfir C, Lopez M, Forgues D, Raux O, Guibal MP, et al. Conditions required for laparoscopic repair of subacute volvulus of the midgut in neonates with intestinal malrotation: 5 cases. *Surg Endosc* 2004;18:1815-7.
8. Hsiao M, Langer JC. Surgery for suspected rotation abnormality: selection of open vs laparoscopic surgery using a rational approach. *J Pediatr Surg* 2012;47:904–10.
9. Huntington JT, Lopez JJ, Mahida JB, AMbeba EJ, Asti L, Deans KH, et al. Comparing laparoscopic versus open Ladd's procedure in pediatric patients. *J Pediatr Surg* 2017;52:1128-31.
10. Ooms N, Matthyssens LE, Draaisma JM, de Blaauw I, Wijnen MH. Laparoscopic Treatment of Intestinal Malrotation in Children. *Eur J Pediatr Surg* 2016;26:376-81.
11. Stanfill AB, Pearl RH, Kalvakuri K, Wallace LJ, Vegunta RK. Laparoscopic Ladd's procedure: treatment of choice for midgut malrotation in infants and children. *J Laparoendosc Adv Surg Tech A* 2010;20:369-72.
12. Bass KD, Rothenberg SS, Chang JHT. Laparoscopic Ladd's procedure in infants with malrotation. *J Pediatr Surg* 1998;33:279–81.

13. Lampl B, Levin TL, Berdon WE, Cowles RA. Malrotation and midgut volvulus: a historical review and current controversies in diagnosis and management. *Pediatr Radiol* 2009;39:359–66.
14. Miyano G, Fukuzawa H, Morita K, Kaneshiro M, Miyake H, Nouse H, et al. Laparoscopic repair of malrotation: What are the indications in neonates and children? *J Laparoendosc Adv Surg Tech A* 2015;25:155–8.
15. Hagendoorn J, Vieira-Travassos D, van der Zee D. Laparoscopic treatment of intestinal malrotation in neonates and infants: retrospective study. *Surg Endosc* 2011;25:217-20.
16. Draus Jr JM, Foley DS, Bond SJ. Laparoscopic Ladd procedure: a minimally invasive approach to malrotation without midgut volvulus. *Am Surg* 2007;73:693-6.
17. Kinlin C, Sawyer AC. The surgical management of malrotation: A Canadian Association of Pediatric Surgeons survey. *J Pediatr Surg* 2017;52:853-8.
18. Do WS, Marengo CW, Horton JD, Escobar MA Jr. Predictors of Bowel Resection During Nonelective Ladd Procedure for Pediatric Malrotation. *J Surg Res* 2019;243:419-26.
19. Polites SF, Lautz TB, Jenkins TM, Dasgupta R. Implications of transfer status on bowel loss in children undergoing emergency surgery for malrotation. *J Pediatr Surg* 2019;54:1848-53.
20. Fraser JD, Aguayo P, Sharp SW, Ostlie DJ, St Peter SD. The role of laparoscopy in the management of malrotation. *J Surg Res* 2009;156:80–2.
21. Ferrero L, Ahmed YB, Philippe P, Reinberg O, Lacreuse I, Schneider A, et al. Intestinal Malrotation and Volvulus in Neonates: Laparoscopy Versus Open Laparotomy. *J Laparoendosc Adv Surg Tech A* 2017;27:318-21.
22. Zhu H, Zheng S, Alganabi M, Peng X, Dong K, Pierro A, et al. Reoperation after Ladd's procedure in the neonatal period. *Pediatr Surg Int* 2019;35:117-20.





	Laparoscopy (before conversion)	Laparotomy	p*	Total
n	46 (20.3)	181 (79.7)		227
Male, n (%)	29 (63.0)	111 (61.3)	0.9	140 (61.7)
Female, n (%)	17 (37.0)	70 (38.7)		87 (38.3)
Age at time of surgery in months			<0.001	0.6 (0.0-209.4)
Mean +/-SD	51.9 +/-58.3	11.4 +/-33.7		
Median (range)	29.2 (0.1-205.2)	0.3 (0.0-209.4)		
Asymptomatic, n (%)	12 (26.1)	15 (8.3)	0.003	27 (11.9)
Symptomatic, n (%)	34 (73.9)	166 (91.7)		200 (88.1)
Vomiting, n (%)	18 (39.1)	129 (71.3)	<0.001	147 (64.8)
Abdominal pain, n (%)	22 (47.8)	100 (55.2)	0.4	122 (53.7)
Abnormal intestinal transit (constipation or diarrhea), n (%)	3 (6.5)	33 (18.2)	0.07	36 (15.9)
Elective surgery, n(%)	28 (60.9)	33 (18.2)	<0.001	61 (26.9)
Emergency surgery, n(%)	18 (39.1)	148 (81.8)		166 (73.1)
Associated malformations or pathologies, n (%)	7 (15.2)	26 (14.4)	0.9	33 (14.5)

Table 1: Demographic and clinical data of children operated on for an intestinal malrotation, * the Fisher exact test was used for categorical variables and the Mann-Whitney test was used for continuous variables. SD= Standard Deviation

	Elective surgery			Emergency surgery		
	Laparotomy N=33	Laparoscopy N=28	p	Laparotomy N=148	Laparoscopy N=18	p
Age at time of surgery in months						
Mean +/-SD	12.1 +/-19.9	62.9 +/-61.5	<0.001	11.3 +/-36.2	34.9 +/-49	<0.001
Median (range)	3.2 (0-79.2)	39.2 (0.3-205.2)		0.2 (0-209.4)	5.9 (0.1-158.2)	
Operative time in minutes						
Mean +/-SD	98 +/-38	92 +/-24	0.6	79 +/-34	130 +/-49	<0.001
Median (range)	108 (40-145)	91 (60-124)		70 (40-180)	118 (75-210)	
Conversion		5 (17.9)			12 (66.7)	
Hospital stay in days						
Mean +/-SD	12.1 +/-14.4	6.0 +/-4.9	0.003	16.2 +/-19.5	9.3 +/-6.2	0.05
Median (range)	7 (2-76)	5 (1-27)		10 (3-183)	7 (4-28)	
Post-operative volvulus, n (%)	0 (0)	3 (10.7)	0.09	9 (6.1)	1 (5.6)	1
Post-operative small bowel obstruction, n (%)	4 (12.1)	2 (7.1)	0.7	14 (9.5)	2 (11.1)	0.7
Post-operative incisional hernia, n (%)	1 (3.0)	0 (0)	1	3 (2.0)	0 (0)	1
Short bowel syndrome, n(%)	0 (0)	0 (0)	-	5 (3.4)	0 (0)	1
Need for subsequent abdominal surgery, n(%)	4 (12.1)	3 (10.7)	1	29 (19.6)	3 (16.7)	1
Death, n (%)	0 (0)	0(0)	-	3 (2.0)	0 (0)	1

Table 2: Outcomes of elective and emergency surgery for intestinal malrotation in children with comparison between procedures started by laparoscopy and laparotomy. SD = Standard Deviation

	Elective surgery			Emergency surgery		
	Laparotomy N=38 (including 5 laparoscopy converted to laparotomy)	Laparoscopy N=23	p	Laparotomy N=160 (including 12 laparoscopy converted to laparotomy)	Laparoscopy N=6	p
Age at time of surgery in months						
Mean +/-SD	1.7 +/-2.7	4.9 +/-5.3	0.01	1.1 +/-3.1	2.1 +/-4.9	0.4
Median (range)	4.7 (0-116.7)	37 (0.3-205.2)		0.3 (0-209.4)	0.4 (0.1-148.3)	
Operative time in minutes						
Mean +/-SD	100 +/-35	77 +/-14	0.04	85 +/-40	121 +/-49	0.06
Median (range)	108 (40-145)	75 (60-97)		73.5 (40-210)	95 (80-191)	
Hospital stay in days						
Mean +/-SD	10.1 +/-13.0	5.3 +/-5.2	0.02	13.4 +/-18.4	10.2 +/-8.9	0.4
Median (range)	7 (2-76)	4 (1-27)		10 (3-183)	7 (4-28)	
Post-operative volvulus, n (%)	0 (0)	3 (13)	0.04	10 (6.3)	0 (0)	1
Post-operative small bowel obstruction, n (%)	4 (10.5)	2 (8.7)	1	16 (10.0)	0 (0)	1
Post-operative incisional hernia, n (%)	1 (2.6)	0 (0)	1	3 (1.9)	0 (0)	1
Short bowel syndrome, n(%)	0 (0)	0 (0)	-	5 (3.0)	0 (0)	1
Need for subsequent abdominal surgery, n(%)	4 (10.5)	3 (13.0)	1	32 (20.0)	0 (0)	0.6
Death, n (%)	0 (0)	0(0)	-	3 (1.9)	0 (0)	1

Table 3: Outcomes of elective and emergency surgery for intestinal malrotation in children with comparison between completed laparoscopy procedures and laparotomy. SD = Standard Deviation

	Age < 1 year			Age > 1 year		
	Laparotomy N=154	Laparoscopy N=16	p	Laparotomy N= 27	Laparoscopy N=30	p
Age at time of surgery in months						
Mean +/-SD	1.0 +/-1.8	3.0 +/-3.4	0.001	70.8 +/-59.6	78.1 +/-56.9	0.5
Median (range)	0.2 (0.0-9.9)	1.7 (0.1-11)		50.6 (12.8-209.4)	64.2 (13.3-205.2)	
Operative time in minutes						
Mean +/-SD	80 +/-35	115 +/-54	0.01	99.5 +/-30.8	113.6 +/-23	0.4
Median (range)	68 (40-180)	90 (60-210)		107 (40-144)	124 (75-138)	
Conversion, n (%)		5 (31.3)			12 (40.0)	
Hospital stay in days						
Mean +/-SD	16.1 +/-19.2	10.5 +/-8.1	0.1	11.2 +/-15.7	5.5 +/-2.6	0.04
Median (range)	11 (2-183)	7 (3-28)		7 (3-81)	6 (1-14)	
Post-operative volvulus, n (%)	9 (5.8)	1 (6.3)	1	0 (0)	3 (10.0)	0.2
Post-operative small bowel obstruction, n (%)	14 (9.1)	2 (12.5)	0.6	4 (14.8)	2 (6.7)	0.4
Post-operative incisional hernia, n (%)	4 (2.6)	0 (0)	1	0 (0)	0 (0)	-
Short bowel syndrome, n(%)	5 (3.2)	0 (0)	1	1 (3.7)	0 (0)	0.5
Need for subsequent abdominal surgery, n(%)	28 (18.2)	2 (12.5)	0.7	5 (18.5)	4 (13.3)	0.7
Death, n (%)	3 (1.9)	0 (0)	1	0 (0)	0 (0)	-

Table 4: Outcomes of surgery for intestinal malrotation in neonates and children aged more than 1 year, with comparison between procedures started by laparoscopy and laparotomy. SD = Standard Deviation

	Age < 1 year			Age > 1 year		
	Laparotomy N=159 (including 5 laparoscopy converted to laparotomy)	Laparoscopy N=11	p	Laparotomy N= 39 (including 12 laparoscopy converted to laparotomy)	Laparoscopy N=18	p
Age at time of surgery in months						
Mean +/-SD	1.1 +/-1.9	2.9 +/-3.6	0.1	70.7 +/-54.4	83.2 +/-65.4	0.5
Median (range)	0.2 (0.0-9.9)	1.5 (0.1-11)		52.3 (12.8-209.4)	62.9 (13.3-205.2)	
Operative time in minutes						
Mean +/-SD	84 +/-41	100 +/-43	0.3	105.5 +/-28.9	105.8 +/-37	0.7
Median (range)	71 (40-210)	85 (60-191)		108 (40-144)	97 (54-172)	
Hospital stay in days						
Mean +/-SD	16.0 +/-18.9	9.7 +/-8.9	0.9	9.9 +/-13.0	4.4 +/-2.1	0.09
Median (range)	11 (2-183)	6 (3-28)		7 (3-81)	4 (1-9)	
Post-operative volvulus, n (%)	9 (5.7)	1 (9.1)	0.5	1 (2.6)	2 (11.1)	0.2
Post-operative small bowel obstruction, n (%)	15 (9.4)	1 (9.1)	1	5 (12.8)	1 (5.6)	0.6
Post-operative incisional hernia, n (%)	4 (2.5)	0 (0)	1	0 (0)	0 (0)	-
Short bowel syndrome, n(%)	5 (3.1)	0 (0)	1	1 (2.6)	0 (0)	1
Need for subsequent abdominal surgery, n(%)	29 (18.2)	1 (9.1)	0.7	7 (17.9)	2 (11.1)	0.7
Death, n (%)	3 (1.9)	0 (0)	1	0 (0)	0 (0)	-

Table 5: Outcomes of surgery for intestinal malrotation in neonates and children aged more than 1 year, with comparison between completed laparoscopy procedures and laparotomy. SD = Standard Deviation