



HAL
open science

Prediction of Post-Traumatic Enophthalmos Based on Orbital Volume Measurements: A Systematic Review

Matthias Schlund, Jean-Christophe Lutz, Camille Sentucq, Benjamin Bouet,
Joël Ferri, Romain Nicot

► **To cite this version:**

Matthias Schlund, Jean-Christophe Lutz, Camille Sentucq, Benjamin Bouet, Joël Ferri, et al.. Prediction of Post-Traumatic Enophthalmos Based on Orbital Volume Measurements: A Systematic Review. *Journal of Oral and Maxillofacial Surgery*, 2020, 78, pp.2032 - 2041. 10.1016/j.joms.2020.05.049 . hal-03492974

HAL Id: hal-03492974

<https://hal.science/hal-03492974v1>

Submitted on 7 Nov 2022

HAL is a multi-disciplinary open access archive for the deposit and dissemination of scientific research documents, whether they are published or not. The documents may come from teaching and research institutions in France or abroad, or from public or private research centers.

L'archive ouverte pluridisciplinaire **HAL**, est destinée au dépôt et à la diffusion de documents scientifiques de niveau recherche, publiés ou non, émanant des établissements d'enseignement et de recherche français ou étrangers, des laboratoires publics ou privés.



Distributed under a Creative Commons Attribution - NonCommercial 4.0 International License

Prediction of posttraumatic enophthalmos based on orbital volume measurements: a systematic review

Matthias Schlund, Jean-Christophe Lutz, Camille Sentucq, Benjamin Bouet, Joël Ferri, Romain Nicot

Matthias Schlund, MD, MSc, Chief Resident

-Univ. Lille, CHU Lille, INSERM, Service de Chirurgie Maxillo-Faciale et Stomatologie, U1008 - Controlled Drug Delivery Systems and Biomaterials, F-59000 Lille, France

Jean-Christophe Lutz, MD, PhD, Senior Lecturer

- Univ. Strasbourg, CHU Strasbourg, Service de Chirurgie Maxillo-Facialet et Stomatologie, F-67000 Strasbourg, France

- CNRS, UMR 7357, ICUBE, Laboratory of Engineering Science, Computer Science and Imaging, F-67000 Strasbourg, France

Camille Sentucq, MD, Chief Resident

-Univ. Lille, CHU Lille, Service de Chirurgie Maxillo-Faciale et Stomatologie, F-59000 Lille, France

Benjamin Bouet, Resident

-Univ. Lille, CHU Lille, Service de Chirurgie Maxillo-Faciale et Stomatologie, F-59000 Lille, France

Joël Ferri, MD, PhD, Professor, Department Head

-Univ. Lille, CHU Lille, INSERM, Service de Chirurgie Maxillo-Faciale et Stomatologie, U1008 - Controlled Drug Delivery Systems and Biomaterials, F-59000 Lille, France

Romain Nicot, MD, MSc, Senior Lecturer

-Univ. Lille, CHU Lille, INSERM, Service de Chirurgie Maxillo-Faciale et Stomatologie, U1008 - Controlled Drug Delivery Systems and Biomaterials, F-59000 Lille, France

Corresponding author :

Dr. Matthias Schlund

Service de Chirurgie Maxillo-Faciale et Stomatologie

Hôpital Roger Salengro – CHU Lille

Rue Emile Laine

59037 Lille Cedex

France

Tel : +33320443676

Fax : +33320445860

e-mail : matthias.schlund@chru-lille.fr

Prediction of posttraumatic enophthalmos based on orbital volume measurements: a systematic review

Abstract

Purpose: Enophthalmos greater than 2 mm is considered clinically relevant and may be responsible for esthetic and functional morbidity. The difficulty has always been how to accurately determine when the orbital wall displacement would lead to a clinically relevant enophthalmos. None of the currently used techniques is able to accurately predict posttraumatic enophthalmos (PE). The aim of this study was to systematically review the use of orbital volumetric tools in the prediction of PE after orbital fracture.

Methods: The terms searched in each database were “(orbital volumetry) and enophthalmos”, “volumetry and enophthalmos”, “volume and enophthalmos”, “volumetric and enophthalmos”. The relationship between PE and orbital volume was assessed.

Results: The initial search yielded a total of 346 results. 14 papers were included and analyzed. Every study stated a different numerical relationship between orbital volume (OV) and PE with a mean enophthalmos of 0.80mm following a 1cm³ increase of OV.

Conclusion: This review showed that most studies concluded on a direct relationship between OV and PE, even defining the degree of PE in relation to the volume expansion. Enophthalmos assessment based on radiological evaluation provides increased accuracy and reproducibility compared to clinical measurement using an exophthalmometer. It is notoriously difficult to determine when the orbital wall displacement will lead to a clinically relevant enophthalmos. OV could be part of the set of arguments helping in the surgical or conservative treatment decision.

Keywords: orbital volume; enophthalmos; volumetry; orbital fracture

Introduction

Orbital fracture is common in facial trauma, occurring in 16% of all facial fractures, and most frequently in males in their second decade of life^{1,2}. It has to be properly managed as vision is a sense of paramount importance and gaze is a major social interaction tool. Mismanagement can therefore lead to severe functional, psychological and social morbidity^{1,2}. However, surgery is not advocated in every case, since in the absence of clinical symptoms the fracture usually heals spontaneously without complication^{1,3,4}. If the impairment of ocular movement is easily detected immediately, posttraumatic enophthalmos (PE) is usually diagnosed only at a later stage. Enophthalmos greater than 2 mm is considered clinically relevant and may be responsible for esthetic and functional morbidity⁵⁻⁷. PE pathophysiology is not entirely understood. It is linked to orbital volume modification due to displacement of the orbital walls but orbital fat atrophy may also play a role^{8,9}. However, it is difficult to accurately determine when orbital wall displacement leads to clinically relevant enophthalmos.

Several methods using computed tomography (CT) imaging have been developed to try to predict PE based on the fractured wall (medial or inferior)^{10,11}, size of the fracture¹²⁻¹⁵, volume of herniated tissue^{16,17}, a specifically designed line¹⁸, or shape modifications to the inferior or medial rectus muscle¹⁹⁻²¹. However, none of these techniques are able to predict PE accurately, since they are all based on the analysis of a two dimensional image, whereas the orbit is a three dimensional (3D) pyramid²² and CT imaging offers 3D data. The orbital volume is about 30cm³, and the difference between both orbits of the same skull is within 0.6cm³²³. Considering only lines and areas instead of the volume of a 3D object can lead to biased conclusions. It would seem that analysis of orbital volume modification might be a reliable method of PE prediction. The main drawback is the difficulty of accurately measuring

orbital volume. This is because the orbit includes numerous foramina and fissures, has thin bony walls and the base of the orbital pyramid, the *aditus orbitalis*, is open at the front. Reproducibility requires a strict placement of these anatomical landmarks. Several techniques have been developed to measure orbital volume: manual segmentation or planimetry, semi-automatic and automatic methods. Planimetry, which has been used since the 1980s²⁴, is based on the summation of manually-delineated areas obtained from a CT image²⁵. It is therefore extremely time-consuming to obtain an accurate result and the manual delineation may lead to low reproducibility. A fully automatic method would therefore be preferable, but as yet, only one automatic technique has been developed and its results were unsatisfactory²⁶. Semi-automatic methods, such as stereology, are a good compromise as they rely on software computation along with manual adjustments^{27,28}. Several such pieces of software are currently on the market as tools to measure orbital volume. Orbital volume measurements are becoming increasingly popular as diagnosis, prognosis and therapeutic tools with the development of mirroring techniques and patient-specific implants to treat orbital fractures or late PE^{29,30}.

Accurate PE prediction would help surgeons in the management of orbital fracture, as it would offer decisive insight on whether to perform surgery. The aim of this study was to systematically review the use of orbital volumetric tools in the prediction of PE after orbital fracture.

Material & Method

This systematic review was performed according to Preferred Reporting Items for Systematic Reviews and Meta-Analyses (PRISMA) guidelines³¹. The following databases were searched: MEDLINE, the Cochrane library, clinicaltrials.gov, and the WHO International Clinical Trials Registry Platform. The terms searched in each database were “(orbital volumetry) and enophthalmos”, “volumetry and enophthalmos”, “volume and enophthalmos”, and “volumetric and enophthalmos”. There were no limits in the search (even publication dates), which was performed up to November 21, 2019. Studies were eligible if the relationship between PE and orbital volume was assessed. Exclusion criteria were as follows: case reports and studies with less than 15 patients, absence of orbital volume measurements, language other than English, or when the full paper was not available.

Studies were first screened based on a combination of their title and abstract, with double reviewing (authors MS and RN). The full paper was then reviewed and was included if no exclusion criteria were met. The results concerning the relationship between PE and orbital volume were assessed. This relationship was either expressed directly (enophthalmos in mm responsible for a 1cm³ increase in OV) or using the orbital volume ratio (OVR), defined as: (the volume of the traumatized orbit) / (orbital volume of normal side) x 100.

Results

The initial search yielded a total of 346 results (Figure 1). From these, 48 were duplicates, leaving 298 studies, out of which 262 were not eligible, since they did not assess the relationship between OV and PE. Therefore, 36 full papers were reviewed; but of these, six studies included less than 15 patients, six did not measure the OV, three were not in English language (Italian, German and Chinese), and for a further three the full papers were not available. A further four papers seemed eligible based on the title and the abstract but, upon reviewing the full papers, the relationship between OV and PE was not assessed; hence, they were not eligible. A final total of 14 papers was included and analyzed^{11,17,32-43}.

The results are shown in Tables 1 and 2. Three were prospective studies^{32,39,40} and two included more than 50 patients^{32,33}. Patients had unilateral orbital wall blowout fracture in each study except two: one included only orbital floor fracture³⁷ and the other included only zygomaticomaxillary complex (ZMC) fractures³². OV was measured mostly using planimetry: either manual planimetry in the earlier publications³⁹⁻⁴³ or software-aided planimetry^{11,17,32,33,35-38}. One study used a semi-automatic method³⁴. PE was assessed either clinically using a Hertel's exophthalmometer^{11,33-35,37,38,40,41} or radiologically with CT^{17,36,42,43} or MRI imaging³⁹. One study used both clinical and radiological assessment³². PE was assessed at two time points following trauma: early PE was defined as being assessed less than a month after trauma^{32,34,42,43} while late PE was defined as being assessed over a month post-trauma^{11,33-39,41}. In two studies, PE was the inclusion criteria and timing regarding the initial trauma was not provided^{17,40}. In late PE, studies evaluated conservative treatment^{11,33,37,38}, surgical treatment^{34,39} or both^{35,36,41}; early PE is assessed before a treatment decision is made.

Eleven studies showed a correlation between OV and PE expressed either directly or

using the OVR. Every study stated a different numerical relationship between OV and PE with a mean enophthalmos of 0.80mm following a 1cm³ increase in OV (Figure 2). The mean OVR leading to 2mm enophthalmos was 110.62% (Figure 3). Three studies did not find a statistically significant correlation between OV and PE^{34,17,37}.

The relationship between OV and enophthalmos was evaluated in subgroups of orbital fracture, such as inferior fracture group (I), infero-medial fracture group (IM), and medial fracture group (M), in some studies. The OVR leading to a 2mm enophthalmos was of 112.02% in the I group, 110.40% in the IM group, and 113.12% in the M group (112.18% every group combined) in Choi *et al.*¹¹, the I group showing the steepest gradient relationship between OVR and enophthalmos. Enophthalmos and OVR were more elevated in the IM group according to Choi *et al.*³⁵. Alinasab *et al.*³⁷ focused only on orbital floor fracture, which may corresponds to the inferior and infero-medial fracture groups; however, they did not found a statistically significant correlation.

These studies are all descriptive based on objective imaging and therefore bias may arise from inter- or intra-observer variability in the measurement of OV. Ebrahimi *et al.*³² analyzed this variability and found an inter-observer correlation coefficient of 0.87 when assessing OV, 0.82 when assessing enophthalmos with CT scan, and 0.76 when assessing enophthalmos with a Hertel's exophthalmometer; and intra-observer variability was measured at 0.93. It is the sole study to have performed this assessment. Another possible source of bias is linked with enophthalmos assessment, which relies either on clinical evaluation using a Hertel's exophthalmometer or on radiological evaluation based on CT imaging. Ebrahimi *et al.*³² is the sole study to have evaluated enophthalmos based on the two methods, and found that clinical evaluation underestimated PE: following a 1cm³ increase of OV a mean enophthalmos of 0.72mm was found when assessed with Hertel's exophthalmometer versus 0.88mm when assessed with CT imaging (Figure 2).

There are also selection biases: timing of PE evaluation varies from early to late, and patients were either at the initial trauma stage or after conservative or surgical treatment (Table 3). The population analyzed is therefore heterogeneous. A 1cm³ increase in OV was deemed responsible for an enophthalmos of 0.85mm at an early stage, versus 0.72mm in late PE (Figure 4).

Discussion

PE diagnosis at the initial stage is notoriously difficult. Algorithms trying to predict PE and therefore to assign patients to conservative or surgical treatments traditionally rely on herniated tissue volume and fracture surface^{3,12,44}. This review showed that most studies found a direct relationship between OV and PE, even defining the degree of PE based on the volume increase. An algorithm of treatment of orbital blowout fracture based on OV measurement recommends surgical treatment in every case of abnormal OV and recorded no PE in the conservative treatment branch⁴⁵.

Orbital fractures can be divided in inferior, infero-medial and medial orbit fractures. No conclusion could be drawn based on the studies reviewed concerning their individual relationship between OV and enophthalmos. Indeed, Choi *et al.* found non-concordant results in their 2016¹¹ and 2017³⁵ publications: in the first, OVR is more elevated in medial orbit fractures, whereas, in the second, OVR was more elevated in infero-medial orbit fractures. The only study focusing exclusively to orbital floor fracture, which may encompass inferior and infero-medial orbit fractures, found no statistically significant correlation between OV and enophthalmos. More studies focusing on the relationship between each of these specific fractures, OV and enophthalmos should be performed.

Interest in OV measurement has recently increased, since it can be performed in a clinical setting. Once it has been measured for diagnosis and prognosis purposes, OV can also be used for therapeutic purposes such as the design of patient-specific implants. Manual planimetry, as performed in earlier studies^{24,41-43}, is extremely time-consuming as it requires manual tracing of complex borders in a slice-by-slice fashion. Therefore, it only has a place as a research tool. Current software using thresholding, sampling points and volumetric reconstruction offers a fast and accurate alternative, and could be used in a routine clinical

care^{32,33,46}. Segmentation time has been evaluated as under 2 minutes for experienced operators⁴⁷. Although CT imaging itself is objective, the measurements taken and the determination of the sampling points used to define OV are still defined by the observer, hence there may still be inter- and intra-observer variability leading to bias. However, this variability has been evaluated as low^{32,47}.

We found some assessment bias in PE measurement. PE can be assessed either clinically with an exophthalmometer or radiologically with CT imaging. Only one study³² compared both methods, and reported an underestimation using a Hertel's exophthalmometer. When comparing the results of the studies using a Hertel's exophthalmometer with those using CT imaging, this tendency to underestimate the enophthalmos clinically is also found (Figure 2). The traditional method of PE evaluation relies on an exophthalmometer, such as Hertel's, Mourits's and Naugle's^{48,49}. The last two are more reliable as they do not use the lateral orbital rim as reference, which can be displaced in the traumatic context. Measurement using these devices is difficult, and accuracy is therefore strongly linked with experience, leading to low reproducibility^{49,50}. CT scanning, which delivers an objective image, offers both accuracy and reproducibility of enophthalmos measurements^{48,49}. Ebrahimi et al.³² found inter-observer variability to be greater in clinical assessment than in radiological assessment. Therefore, further studies evaluating enophthalmos should use CT imaging in preference to a clinical exophthalmometer to enhance accuracy and reproducibility between studies. CT evaluation of enophthalmos may use various measurement techniques, always based on an axial slice in the neuro-ocular plane, such as: the zygomaticofrontal process baseline to the back of the lens; the zygomaticofrontal process baseline to the cornea; the oculo-orbital index (ratio $a/b \times 100$, where "a" is the distance between the cornea and the zygomaticofrontal process baseline and "b" is the total length of the ocular globe); and the distance between the cornea and the optic foramen^{43,51}. The measurement techniques based on the

zygomaticofrontal process baseline have the same drawback as Hertel's exophthalmometer since they cannot be used in ZMC fractures where this process is fractured. The technique used to evaluate enophthalmos radiologically is not stated in most of the studies analyzed. A standardized procedure to assess enophthalmos is necessary to obtain reproducible results.

Other biases were linked with the timing of PE evaluation and the care provided (initial evaluation, and after conservative or surgical treatment). Some studies measure globe position less than a month after trauma (early setting) while others evaluated this more than a month after trauma (late setting). Interestingly, enophthalmos following a 1cm³ increase in OV was more severe when measured in the early setting. This may be related to selection bias: in the early setting every blowout fracture was included in the studies, whereas in the late setting some studies included only patients undergoing conservative treatment and others included patients undergoing surgery or both treatment. The population included in late PE evaluation may be more heterogeneous since conservative treatment will not be offered to patient with significant OV increase. It could be inferred that patients included in studies concentrating on surgical treatment would have more severe orbital fractures. Moreover, surgical treatment repairs the fractured orbital wall using grafted material, which varied between studies: bone autograft, polydioxanone, and titanium patient-specific implant were all used. There may be an effect linked to the material, especially since polydioxanone is a resorbable material whereas bone autograft and titanium are not. A study evaluating patients repeatedly (early and late setting) would be necessary to further characterize the relationship between OV and enophthalmos in time.

The outcome was mostly represented as a direct correlation between OV expansion and enophthalmos, although some studies used the OVR. For both methods, the issue is that calculation of normal orbital volume is based on the non-fractured side. However, it has been demonstrated that orbital volume is physiologically different between each side, within a

0.6cm³ range²³. Bearing this in mind, OV should not be the only factor on which to base therapeutic decision. It should be used in combination with the volume of herniated tissue, which is not affected by this physiological asymmetry.

Conclusion

OV and PE are directly correlated, according to most studies, with a mean enophthalmos of 0.80mm following an increase of OV of 1cm³. Studies investigating enophthalmos should favor radiological evaluation over clinical evaluation via exophthalmometer for increased accuracy and reproducibility. It is difficult to determine when the orbital wall displacement will lead to a clinically relevant enophthalmos. OV could be part of the set of arguments helping in the surgical or conservative treatment decision. However, if a direct correlation between OV and PE is clearly established, their precise numerical relationship varies from one study to another and needs further characterization. This study sought to review the correlation between OV and PE, its purpose was not to provide the exact numbers to be used for OV restoration in orbital reconstruction.

References

1. Kholaki O, Hammer DA, Schlieve T: Management of Orbital Fractures. *Atlas Oral Maxillofac Surg Clin North Am* 27: 157, 2019.
2. Cruz AAV, Eichenberger GCD: Epidemiology and management of orbital fractures. *Curr Opin Ophthalmol* 15: 416, 2004.
3. Boyette JR, Pemberton JD, Bonilla-Velez J: Management of orbital fractures: challenges and solutions. *Clin Ophthalmol Auckl NZ* 9: 2127, 2015.
4. Gart MS, Gosain AK: Evidence-based medicine: Orbital floor fractures. *Plast Reconstr Surg* 134: 1345, 2014.
5. Dulley B, Fells P: Long-term follow-up of orbital blow-out fractures with and without surgery. *Mod Probl Ophthalmol* 14: 467, 1975.
6. Osguthorpe JD: Orbital wall fractures: evaluation and management. *Otolaryngol Head Neck Surg* 105: 702, 1991.
7. Brady SM, McMann MA, Mazzoli RA, Bushley DM, Ainbinder DJ, Carroll RB: The diagnosis and management of orbital blowout fractures: update 2001. *Am J Emerg Med* 19: 147, 2001.
8. Ramieri G, Spada MC, Bianchi SD, Berrone S: Dimensions and volumes of the orbit and orbital fat in posttraumatic enophthalmos. *Dentomaxillofac Radiol* 29: 302, 2000.
9. Kim SM, Jeong YS, Lee IJ, Park MC, Park DH: Prediction of the development of late enophthalmos in pure blowout fractures: delayed orbital tissue atrophy plays a major role. *Eur J Ophthalmol* 27: 104, 2017.
10. Hazani R, Yaremchuk MJ: Correction of posttraumatic enophthalmos. *Arch Plast Surg* 39: 11, 2012.
11. Choi J, Park SW, Kim J, Park J, Kim JS: Predicting late enophthalmos: Differences between medial and inferior orbital wall fractures. *J Plast Reconstr Aesthetic Surg* 69: e238, 2016.
12. Jin HR, Shin SO, Choo MJ, Choi YS: Relationship between the extent of fracture and the degree of enophthalmos in isolated blowout fractures of the medial orbital wall. *J Oral Maxillofac Surg* 58: 617, 2000.
13. Lee WT, Kim HK, Chung SM: Relationship between small-size medial orbital wall fracture and late enophthalmos. *J Craniofac Surg* 20: 75, 2009.
14. Kunz C, Sigron GR, Jaquiéry C: Functional outcome after non-surgical management of orbital fractures--the bias of decision-making according to size of defect: critical review of 48 patients. *Br J Oral Maxillofac Surg* 51: 486, 2013.
15. Ahmad Nasir S, Ramli R, Abd Jabar N: Predictors of enophthalmos among adult patients with pure orbital blowout fractures. *PloS One* 13: e0204946, 2018.
16. Harris GJ, Garcia GH, Logani SC, Murphy ML, Sheth BP, Seth AK: Orbital blow-out fractures: correlation of preoperative computed tomography and postoperative ocular motility. *Trans Am Ophthalmol Soc* 96: 329, 1998.
17. Zhang Z, Zhang Y, He Y, An J, Zwahlen RA: Correlation between volume of herniated orbital contents and the amount of enophthalmos in orbital floor and wall fractures. *J Oral Maxillofac Surg* 70: 68, 2012.
18. Lee HB, Lee SH: A Straightforward Method of Predicting Enophthalmos in Blowout Fractures Using Enophthalmos Estimate Line. *J Oral Maxillofac Surg* 74: 2457, 2016.
19. Levine LM, Sires BS, Gentry LR, Dortzbach RK: Rounding of the inferior rectus muscle: a helpful radiologic findings in the management of orbital floor fractures. *Ophthal Plast Reconstr Surg* 14: 141, 1998.
20. Banerjee A, Moore CC, Tse R, Matic D: Rounding of the inferior rectus muscle as an

- indication of orbital floor fracture with periorbital disruption. *J Otolaryngol* 36: 175, 2007.
21. Kim YK, Park CS, Kim HK, Lew DH, Tark KC: Correlation between changes of medial rectus muscle section and enophthalmos in patients with medial orbital wall fracture. *J Plast Reconstr Aesthetic Surg* 62: 1379, 2009.
 22. René C: Update on orbital anatomy. *Eye Lond Engl* 20: 1119, 2006.
 23. McGurk M, Whitehouse RW, Taylor PM, Swinson B: Orbital volume measured by a low-dose CT scanning technique. *Dentomaxillofac Radiol* 21: 70, 1992.
 24. Bite U, Jackson IT, Forbes GS, Gehring DG: Orbital volume measurements in enophthalmos using three-dimensional CT imaging. *Plast Reconstr Surg* 75: 502, 1985.
 25. Bontzos G, Mazonakis M, Papadaki E, Maris TG, Blazaki S, Drakonaki EE, Detorakis ET: Ex vivo orbital volumetry using stereology and CT imaging: A comparison with manual planimetry. *Eur Radiol* 29: 1365, 2019.
 26. Jansen J, Schreurs R, Dubois L, Maal TJJ, Gooris PJJ, Becking AG: Orbital volume analysis: validation of a semi-automatic software segmentation method. *Int J Comput Assist Radiol Surg* 11: 11, 2016.
 27. Strong EB, Fuller SC, Chahal HS: Computer-aided analysis of orbital volume: a novel technique. *Ophthal Plast Reconstr Surg* 29: 1, 2013.
 28. Shyu VB-H, Hsu C-E, Chen C-H, Chen C-T: 3D-assisted quantitative assessment of orbital volume using an open-source software platform in a Taiwanese population. *PloS One* 10: e0119589, 2015.
 29. Pedemonte C, Sáez F, Vargas I, González LE, Canales M, Salazar K: Can customized implants correct enophthalmos and delayed diplopia in post-traumatic orbital deformities? A volumetric analysis. *Int J Oral Maxillofac Surg* 45: 1086, 2016.
 30. Nicot R, Schlund M, Sentucq C, Raoul G: A New Orbito-Zygomatic Complex Reconstruction Technique Using Computer-Aided Design and Manufacturing-Assisted Harvest of Autologous Calvarial Bone in Cases of Orbito-Zygomatic Benign Tumor. *J Oral Maxillofac Surg* 77: 1082, 2019.
 31. Moher D, Liberati A, Tetzlaff J, Altman DG, Group TP: Preferred Reporting Items for Systematic Reviews and Meta-Analyses: The PRISMA Statement. *PLOS Med* 6: e1000097, 2009.
 32. Ebrahimi A, Kalantar Motamedi MH, Rasouli HR, Naghdi N: Enophthalmos and Orbital Volume Changes in Zygomaticomaxillary Complex Fractures: Is There a Correlation Between Them? *J Oral Maxillofac Surg* 77: 134.e1, 2019.
 33. Yang J-H, Hwang SB, Shin JY, Roh S-G, Chang SC, Lee N-H: 3-Dimensional Volumetric Analysis of Relationship Between the Orbital Volume Ratio and Enophthalmos in Unoperated Blowout Fractures. *J Oral Maxillofac Surg* 77: 1847, 2018.
 34. Schönegg D, Wagner M, Schumann P, Essig H, Seifert B, Rücker M, Gander T: Correlation between increased orbital volume and enophthalmos and diplopia in patients with fractures of the orbital floor or the medial orbital wall. *J Craniomaxillofac Surg* 46: 1544, 2018.
 35. Choi SH, Kang DH: Prediction of Late Enophthalmos Using Preoperative Orbital Volume and Fracture Area Measurements in Blowout Fracture. *J Craniofac Surg* 28: 1717, 2017.
 36. Sugiura K, Yamada H, Okumoto T, Inoue Y, Onishi S: Quantitative assessment of orbital fractures in Asian patients: CT measurement of orbital volume. *J Craniomaxillofac Surg* 45: 1944, 2017.
 37. Alinasab B, Beckman MO, Pansell T, Abdi S, Westermark AH, Stjärne P: Relative difference in orbital volume as an indication for surgical reconstruction in isolated orbital floor fractures. *Craniomaxillofacial Trauma Reconstr* 4: 203, 2011.
 38. Ahn HB, Ryu WY, Yoo KW, Park WC, Rho SH, Lee JH, Choi SS: Prediction of

- enophthalmos by computer-based volume measurement of orbital fractures in a Korean population. *Ophthal Plast Reconstr Surg* 24: 36, 2008.
39. Kolk A, Pautke C, Wiener E, Schott V, Wolff K-D, Horch H-H, Rummeny EJ: Isotropic proton-density-weighted high-resolution MRI for volume measurement of reconstructed orbital fractures--a comparison with multislice CT. *Magn Reson Imaging* 26: 1167, 2008.
 40. Fan X, Li J, Zhu J, Li H, Zhang D: Computer-assisted orbital volume measurement in the surgical correction of late enophthalmos caused by blowout fractures. *Ophthal Plast Reconstr Surg* 19: 207, 2003.
 41. Raskin EM, Millman AL, Lubkin V, Rocca RC della, Lisman RD, Maher EA: Prediction of late enophthalmos by volumetric analysis of orbital fractures. *Ophthal Plast Reconstr Surg* 14: 19, 1998.
 42. Yab K, Tajima S, Ohba S: Displacements of eyeball in orbital blowout fractures. *Plast Reconstr Surg* 100: 1409, 1997.
 43. Whitehouse RW, Batterbury M, Jackson A, Noble JL: Prediction of enophthalmos by computed tomography after "blow out" orbital fracture. *Br J Ophthalmol* 78: 618, 1994.
 44. Alinasab B, Borstedt K-J, Rudström R, Ryott M, Qureshi AR, Beckman MO, Stjärne P: New Algorithm for the Management of Orbital Blowout Fracture Based on Prospective Study. *Craniomaxillofacial Trauma Reconstr* 11: 285, 2018.
 45. Karameşe M, Akdağ O, Selimoğlu MN, Koplay TG, Bakbak B, Koplay M, Tosun Z: Analysis of unilateral complex orbital fractures with a new treatment algorithm. *J Plast Surg Hand Surg* 49: 121, 2015.
 46. Regensburg NI, Kok PHB, Zonneveld FW, Baldeschi L, Saeed P, Wiersinga WM, Mourits MP: A new and validated CT-based method for the calculation of orbital soft tissue volumes. *Invest Ophthalmol Vis Sci* 49: 1758, 2008.
 47. Dreizin D, Nam AJ, Hirsch J, Bernstein MP: New and emerging patient-centered CT imaging and image-guided treatment paradigms for maxillofacial trauma. *Emerg Radiol* 25: 533, 2018.
 48. Delmas J, Loustau J-M, Martin S, Bourmault L, Adenis J-P, Robert P-Y: Comparative study of 3 exophthalmometers and computed tomographic biometry. *Eur J Ophthalmol* 28: 144, 2018.
 49. Nightingale CL, Shakib K: Analysis of contemporary tools for the measurement of enophthalmos: a PRISMA-driven systematic review. *Br J Oral Maxillofac Surg*, 2019.
 50. Musch DC, Frueh BR, Landis JR: The reliability of Hertel exophthalmometry. Observer variation between physician and lay readers. *Ophthalmology* 92: 1177, 1985.
 51. Moret A, Paré A, Sury F, Goga D, Laure B: [Posttraumatic enophthalmos correction by bone graft: Why the unpredictable results?]. *Ann Chir Plast Esthet* 60: 276, 2015.

List of Tables

Table 1: included studies and their outcome

Table 2: included studies and their methods

Table 3: bias assessment

List of Figures

Figure 1: Flow-chart following PRISMA statement

Figure 2: Enophthalmos following a 1cm³ increase in orbital volume

Figure 3: Orbital volume ratio responsible of a 2mm enophthalmos

Figure 4: Enophthalmos following a 1cm³ increase in orbital volume: assessment of early versus late enophthalmos

Authors, year	Number of patient included	Design	Outcome	Significance
Ebrahimi et al., 2019	96	Prospective	1cm ³ increase of OV = 0.68mm clinical enophthalmos (Hertel) and 0.71 mm radiographic enophthalmos (CT)	p < 0.0001
Yang et al., 2018	161	Retrospective	OVR = 106.85% = 2mm enophthalmos	p = 0.001
Schöneegg et al., 2018	44	Retrospective	No statistically significant correlation between OV or OVR and enophthalmos either pre- or postoperatively	p = 0.201 (p = 0.329)
Choi and Kang, 2017	72	Retrospective	OVR = 112.82% = 2mm enophthalmos	p < 0.05
Sugiura et al., 2017	47	Retrospective	2.25cm ³ of orbital volume = 2.0mm of enophthalmos	p < 0.01
Choi et al., 2016	38	Retrospective	1% increase of OVR = 0.145mm enophthalmos (OVR = 112.18% = 2mm enophthalmos)	p < 0.05
Zhang et al., 2012	23	Retrospective	No statistically significant correlation between OV and enophthalmos	p > 0.05
Alinasab et al., 2011	23	Retrospective	No statistically significant correlation between OV and enophthalmos	p > 0.05
Ahn et al., 2008	35	Retrospective	1cm ³ increase OV = 0.84 mm enophthalmos	p < 0.0001
Kolk et al., 2008	37	Prospective	1cm ³ increase of OV = 0.93mm enophthalmos	p < 0.05
Fan et al., 2003	16	Prospective	1cm ³ increase of OV = 0.89mm enophthalmos	p < 0.0001
Raskin et al., 1998	30	Retrospective	1cm ³ increase of OV = 0.47 mm enophthalmos	p = 0.0002
Yab et al., 1997	32	Retrospective	OV increase ≤ 2cm ³ = 1 mm enophthalmos. OV increase > 2cm ³ and ≤ 4cm ³ = proportional increase of enophthalmos	p < 0.0001
Whitehouse et al., 1994	36	Retrospective	1cm ³ increase of OV = 0.77 mm enophthalmos	p < 0.001

Table 1

Authors	Type of	OV Measurement	Evaluation	Care when	Measurment
---------	---------	----------------	------------	-----------	------------

	fracture		of PE	enophthalmos is assessed	ent time of PE
Ebrahimi et al., 2019	Zygomaxillary complex fractures	CT images: Mimics, planimetry	CT + Hertel exophthalmometer	Before treatment decision	24 hours
Yang et al., 2018	Orbital wall blowout fracture	CT images: 3D Workstation, planimetry	Hertel exophthalmometer	Conservative treatment	3 months
Schönegg et al., 2018	Orbital wall blowout fracture	CT images: iPlan 3.0.5, semi-automatic	Hertel exophthalmometer	Preoperative and Surgical treatment (PSI titanium)	first appointment and 6 months
Choi and Kang, 2017	Orbital wall blowout fracture	CT images: Manual planimetry	Hertel exophthalmometer	Conservative and Surgical treatment (unknown material)	6 months
Sugiura et al., 2017	Orbital wall blowout fracture	CT images: Mimics, planimetry	CT	Conservative and Surgical treatment (bone autograft)	6 months
Choi et al., 2016	Orbital wall blowout fracture	CT images: Rapidia Image Post-processing system, planimetry	Hertel exophthalmometer	Conservative treatment	6 months
Zhang et al., 2012	Orbital wall blowout fracture	CT images: Mimics, planimetry	CT	Conservative treatment with PE	PE as an inclusion criteria
Alinasaib et al., 2011	Orbital floor blowout fracture	CT images: Volume Viewer, planimetry	Hertel exophthalmometer	Conservative treatment	> 6 months
Ahn et al., 2008	Orbital wall blowout fracture	CT images: Rapidia Image Post-processing system, planimetry	Hertel exophthalmometer	Conservative treatment	3 months
Kolk et al., 2008	Orbital wall blowout fracture	MRI images: Manual planimetry	MRI	Surgical treatment (PDS)	3-4 months
Fan et al., 2003	Orbital wall blowout fracture	CT images: Manual planimetry	Hertel exophthalmometer	Conservative treatment with PE	PE as an inclusion criteria
Raskin et al., 1998	Orbital wall blowout fracture	CT images: Manual planimetry	Hertel exophthalmometer	Conservative and Surgical treatment (unknown material)	> 4 weeks
Yab et al.,	Orbital wall blowout	CT images: Manual planimetry	CT	Before treatment decision	10 days

1997	fracture				
Whitehouse et al., 1994	Orbital wall blowout fracture	CT images: Manual planimetry	CT	Before treatment decision	Within 20 days

Table 2

Authors, year	Design of study	Number of patient	Control group	Evaluation of PE
Ebrahimi et al., 2019	Low	Low	No	Very low
Yang et al., 2018	High	Low	No	High
Schöneegg et al., 2018	High	Moderate	No	High
Choi and Kang, 2017	High	Low	No	High
Sugiura et al., 2017	High	Moderate	No	Low
Choi et al., 2016	High	Moderate	No	High
Zhang et al., 2012	High	High	No	Low
Alinasab et al., 2011	High	High	No	High
Ahn et al., 2008	High	Moderate	No	High
Kolk et al., 2008	Low	Moderate	No	Low
Fan et al., 2003	High	High	No	High
Raskin et al., 1998	High	Moderate	No	High
Yab et al., 1997	High	Moderate	No	Low
Whitehouse et al., 1994	High	Moderate	No	Low

Table 3

Identification

Records identified through
database searching
(n = 346)

Additional records identified
through other sources
(n = 0)

Screening

Records after duplicates removed
(n = 298)

Records screened
(n = 298)

Records excluded
(n = 262)

Eligibility

Full-text articles assessed
for eligibility
(n = 36)

Full-text articles excluded
(n = 22)
< 15 patients (n = 6)
no orbital volume
measurements (n = 6)
not eligible based on full text
(n = 4)
full-text not available (n = 3)
full-text not in english (n = 3)

Included

Studies included in
qualitative synthesis
(n = 14)

Figure 2 - Enophthalmos following a 1cm³ increase in orbital volume

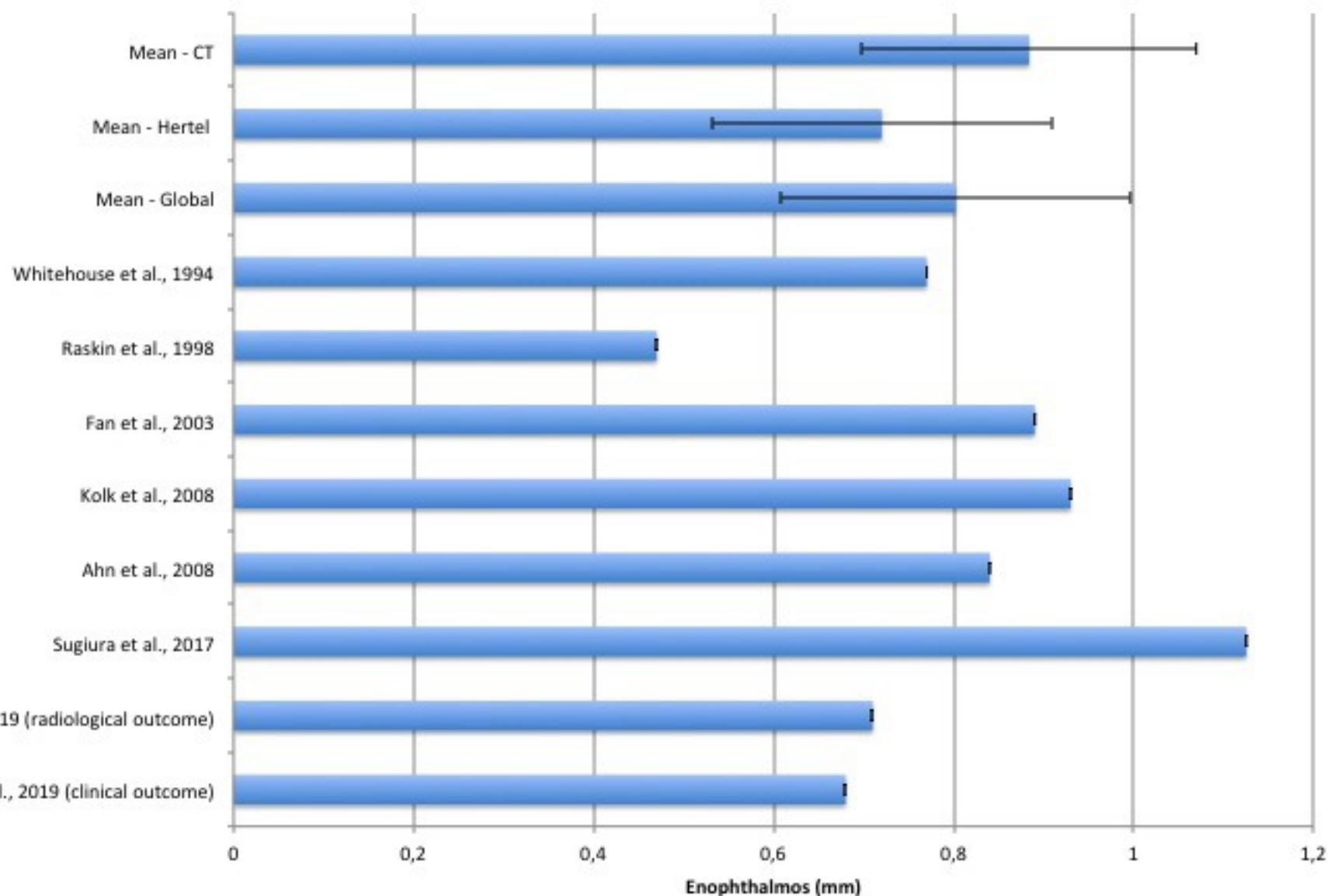


Figure 3 - Orbital volume ratio responsible of a 2 mm enophthalmos

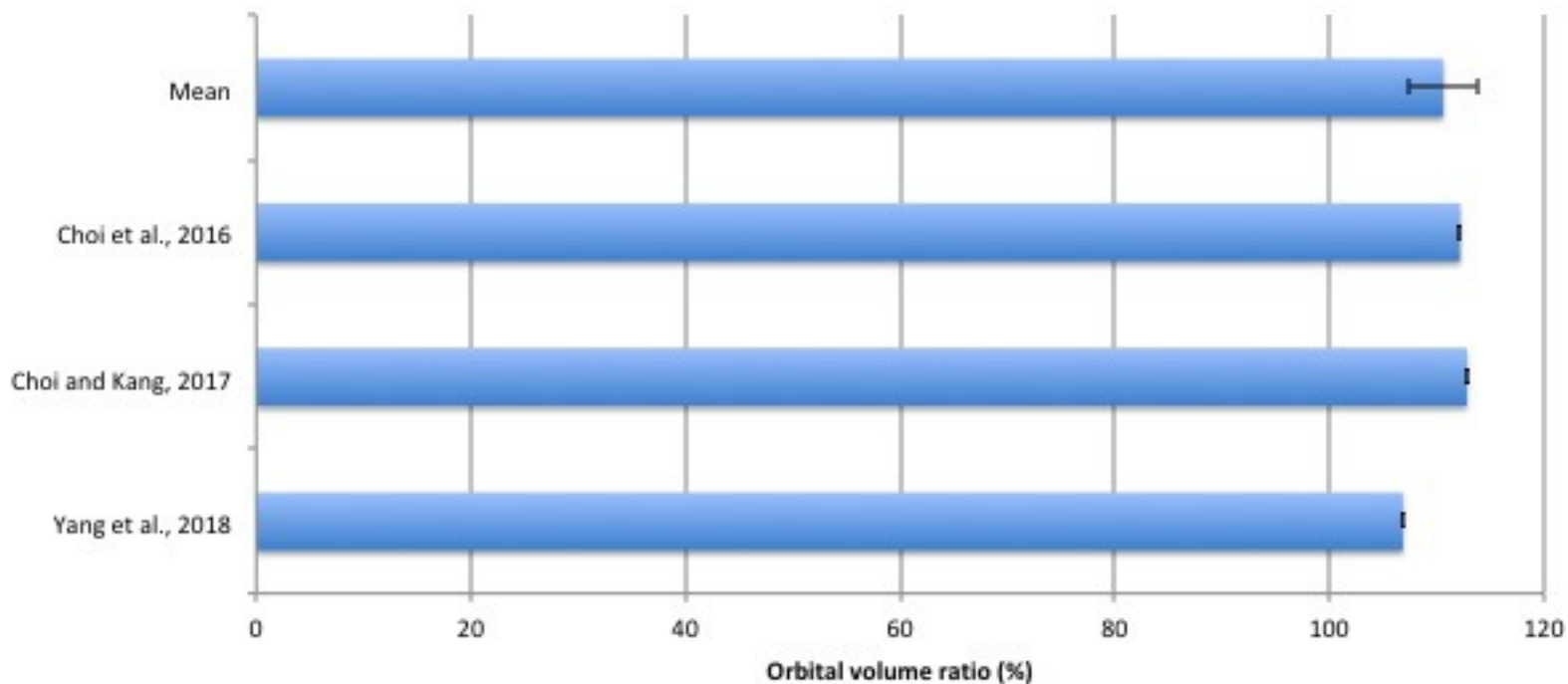


Figure 4 - Exophthalmos following a 1cm³ increase in orbital volume: assessment of early versus late exophthalmos

