



**HAL**  
open science

## The Cryo-immunologic effect: A therapeutic advance in the treatment of glioblastomas?

H. Cebula, G. Noel, J. Garnon, J. Todeschi, H. Burckel, M. de Mathelin, A. Gangi, F. Proust

### ► To cite this version:

H. Cebula, G. Noel, J. Garnon, J. Todeschi, H. Burckel, et al.. The Cryo-immunologic effect: A therapeutic advance in the treatment of glioblastomas?. *Neurochirurgie*, 2020, 66, pp.455 - 460. 10.1016/j.neuchi.2020.06.135 . hal-03492927

**HAL Id: hal-03492927**

**<https://hal.science/hal-03492927v1>**

Submitted on 15 Dec 2022

**HAL** is a multi-disciplinary open access archive for the deposit and dissemination of scientific research documents, whether they are published or not. The documents may come from teaching and research institutions in France or abroad, or from public or private research centers.

L'archive ouverte pluridisciplinaire **HAL**, est destinée au dépôt et à la diffusion de documents scientifiques de niveau recherche, publiés ou non, émanant des établissements d'enseignement et de recherche français ou étrangers, des laboratoires publics ou privés.



Distributed under a Creative Commons Attribution - NonCommercial 4.0 International License

## The Cryo-immunologic effect: a therapeutic advance in the treatment of glioblastomas?

L'Effet immunitaire de la cryothérapie : une nouvelle thérapeutique dans le traitement des glioblastomes ?

Cebula H.<sup>1</sup>, Noel G.<sup>2</sup>, Garnon J.<sup>3</sup>, Todeschi J.<sup>1</sup>, Burckel H.<sup>2</sup>, DeMathelin M.<sup>4</sup>, Gangi A.<sup>3</sup>, Proust F<sup>1</sup>.

<sup>1</sup> Department of Neurosurgery, University Hospital of Strasbourg, 67100, France

<sup>2</sup> Department of Radiotherapy, ICANS, Strasbourg, 67100, France

<sup>3</sup> Department of Interventional Radiology, University Hospital of Strasbourg, 67100, France

<sup>4</sup> Icube-UMR 7357 Télécom Physique, Strasbourg, 67100, France

Words : 2211

Tables number: 3

References number: 39

Auteur Correspondant:

CEBULA Hélène

Department of Neurosurgery,

Hautepierre Hospital, Strasbourg, France

helene.cebula@hotmail.fr

## **Abstract**

The immunotherapy of cerebral glioblastoma has become a hot topic. Immune checkpoint blockade antibodies have progressively acquired a role in the management of malignant tumors. A multimodal approach using surgery, radiotherapy, chemotherapy in combination with immunotherapy represent a potent weapon against glioblastomas. In parallel, clinical applications of cryotherapy – freezing tumors based on repetition of rapid freeze-slow thaw cycle - for various cancers such as skin, lung, breast, esophagus, hepatic, kidney, prostate and bone tumors were developed. The future immunomodulatory approaches might be combined with brain tumors cryoablation to increase the cryoimmune response.

The objective of this study was to analyze from the literature the relationship between cerebral cryosurgery and immunomodulation using PRISMA method. The animals' studies demonstrate the dendritic cells maturation and activation with the enhancement of antigen-presenting function after cryotherapy suggesting the potential usefulness of the association of cryotherapy and immunomodulator in the management of gliomas.

## **Key words**

Cryotherapy- Brain Oncology- MRI imaging guided- Brain tumors- Immunotherapy

## **Résumé**

L'immunothérapie dans le traitement du glioblastome est un sujet d'actualité notamment avec l'essor des inhibiteurs de point de contrôle immunitaire marquant un changement de paradigme dans le traitement du cancer. Le traitement du glioblastome passera probablement par le développement de stratégies multimodales associant chirurgie, chimiothérapie, radiothérapie et immunothérapie. En parallèle, s'est développée la cryothérapie pour d'autres types de cancers ; peau, poumon, œsophage, foie, sein, rein, prostate et tumeurs osseuses ; basée sur la répétition de cycle rapide de gel et lent de dégel. L'immunomodulation pourrait être combinée à la cryothérapie dans les tumeurs cérébrales potentialisant ainsi la réponse immunitaire créée par la cryothérapie.

L'objectif de cette étude était d'analyser la relation entre la cryothérapie pour les tumeurs cérébrales et le système immunitaire, basée sur une revue de la littérature selon la méthode PRISMA. Les études animales ont démontré l'activation et la maturation des cellules dendritiques avec une augmentation de la fonction présentatrice d'antigènes après la cryothérapie suggérant une association potentielle entre cryothérapie et immunothérapie dans le traitement des glioblastomes.

## **Mots-clés**

Cryothérapie - Oncologie cérébrale - Imagerie guidée par IRM – Tumeurs cérébrales-  
Immunotherapie

Cryotherapy- Brain Oncology- MRI imaging guided- Brain tumors- Immunotherapy

Declaration of interest: non

## INTRODUCTION

Glioblastoma remains a therapeutic challenge. Surgery, radiotherapy and chemotherapy are currently the pillars of the cure intend treatment. However, since the publication of Stupp et al., therapeutic advances in glioblastoma seem to have stalled[1]. Consequently, every new treatment approach can be considered as a real opportunity to improve outcome of patients with glioblastoma.

The immunotherapy of cerebral glioblastoma has become a hot topic[2][3][4]. Immune checkpoint blockade antibodies, particularly the program death 1 PD-1/PD-1 ligand pathway, have progressively acquired a role in the management of malignant tumors such as melanoma, lung cancer, breast cancer, prostate cancer and kidney cancer, since the first Food and Drug Agency (FDA) approval in 2014 of Pembrolizumab (a PD-1 inhibitor) to treat metastatic melanoma[5][6][7][8][9]. More recently, efficiency of immune system was shown in the central nervous system, despite the blood-brain barrier. Lead by microglia cells, glymphatic system and the cervical lymphatic node system that present antigens immune reaction can be observed [4]. A constant interaction between the extra and intracranial immune responses was demonstrated and this relation can mount appropriate immune responses[4].

Thus, different cerebral immunomodulatory pathways of glioblastoma are under development: vaccine-based strategies vaccine-based therapies; the use of convection-enhanced delivery to introduce tumoricidal viruses into the tumor microenvironment, leading to secondary immune responses; the emerging use of adoptive cell therapy; and future frontiers, such as the use of cerebral microdialysis for immune monitoring and the use of sequencing to develop patient-specific therapeutics or signaling blockages such as CTLA4 and PD-1[4].

In parallel, clinical applications of cryotherapy – freezing tumors based on repetition of rapid freeze-slow thaw cycle - for various cancers such as skin, lung, breast, esophagus, hepatic, kidney, prostate and bone tumors were developed [10].

The applications of cryosurgery to endocranial lesions, study mainly in the 70s was phased out due to efficiency of microsurgery [11][12][13][14][15]. The current advances of imaging techniques, especially MRI-guided, and the development of technical competency of cryogenic devices stimulated again the interest of this procedure for neurosurgical lesions. As for the management of other solid tumors, one may wonder about the relevance of cryosurgery combined with immunotherapy to treat the glioblastoma[16]. The combination of immunotherapy and cryotherapy could represent a new approach to treat glioblastomas.

The objective of this study was to analyze from the literature the relationship between brain cryosurgery and **and its effect on immune system** using PRISMA method[17].

## METHODS

### **Data sources and study selection**

A **comprehensive** review of articles published from January 2000 to September 2019 was conducted. It was carried out on EMBASE, MEDLINE and the Cochrane Library. The search strategy contained the subject heading: “Brain AND Cryotherapy, Brain AND cryosurgery, animal study AND cryotherapy, Gliomas AND Cryotherapy, Cryoablation AND brain”. We included article in English **and/or French** language. Study designs included case reports and series of case reports, human studies and animal studies. The exclusion criteria were historical review and analyze of cryotherapy without glioma model for animal study.

### **Quality assessment**

The current analysis is reported in accordance with Preferred Reporting Items for Systematic Reviews and Meta-Analysis (PRISMA) [17]. Two investigators independently reviewed and selected abstracts from the database and full articles. The description of the data was summarized on tables.

The objectives, animal model, glioma cell lines, markers of inflammation, immune response were analyzed in each study.

## RESULTS

On database searches through January 2000, 38 articles were identified. Twenty-eight were excluded secondary to: 8 articles were not available in English; Ten were a review of literature, nine were not an animal model of gliomas and one had only abstract available.

Ten articles were eligible: eight experimental studies included cryotherapy and model of gliomas and two feasibility studies of cryotherapy on brain tumors (Table 1).

#### a) Experimental studies

Models and the glioma cell line were detailed in table 2.

In 5 studies, the animal model was mice (C57BL/6 for five studies and among these five studies, two used also BALB/c mice model in more)[18][19][20][21][22]. In all these studies, the tumor was developed from GL261 glioma cell line. In three studies, the animal model was Wistar rat and the implanted cells were C6 glioma cell line[23][24][25].

The cell injection were heterotopic in seven studies [18][23][19][20][26][21][22]and orthotopic in one study[24].

The procedures of Cryotherapy varied according to the different studies: variation of number of cycles (from 1 to 3 cycles) and temperature target (from -140°C to -196°C), detailed in Table 2. The size of cryoprobe varied between two or three millimeters. The argon-helium cryocare system were used in seven studies (Endocare, [18][19][20][26][22][23], no precision for argon-helium device in one study [21]) and one nitrogen system in one study (Frigitronics, Inc., Shelton, USA[24]).

All authors analyzed the reaction of the immune system after cryotherapy.

- Dendritic cells

Dendritic cells (DC) are the most potent antigen-presenting cells. The mature DCs migrate to tumor-draining lymph nodes. By production of large proinflammatory cytokines such as IL-2, the mature DCs induced T-cell immunity where they present tumor antigens to tumor-specific T cells, inducing their activation. [18].

By the release of large amounts tumor antigens induced by cryoablation, the cryosurgery could enhance the migration of DCs and increase the T cell immunity.

In vivo, Yin et al. reported the efficiency of cryoablation as immunostimulation procedure by induction of DCs maturation, increasing expression of immunostimulatory cytokines with higher level of cytotoxicity against glioma cells[18]. Li and al. analyzed the effect on cellular immunity after treatment of subcutaneous gliomas in rats (Wistar rat models) by argon-helium cryotherapy[23]. Cryosurgery, compared with surgical resection, resulted in increased



percentages of CD3<sup>+</sup> and CD4<sup>+</sup> ( $p < 0.005$ ) with an increase of the CD4<sup>+</sup>/CD8<sup>+</sup> cell ratios 14 days after the cryotherapy. Highlighted on C6 glioma-bearing animals models, the association of cryotherapy and injection of Interleukine 12 (cytokine and immunomodulator factor which induced a direct antagonistic effect against tumors) activated the Th1-type immunity with an increase of CD11<sup>+</sup> and CD86<sup>+</sup> [23].

Huang et al. found a synergic anti-tumor action (on glioma C6 model orthotopically implanted) of cryotherapy and TNF- $\alpha$  (tumor necrosis factor-alpha, inducing apoptosis via Caspase 3) secondary to inhibition of proliferation and induction of apoptosis[24]. Other authors demonstrated that the injection of dendritic cells (DC), in a murine subcutaneous GL261 glioma model, combined with cryosurgery reduces tumor size and significantly prolonged survival in comparison with injection of DC alone, or, with cryosurgery alone [21]. This association increase the percentages of CD3<sup>+</sup>, CD3<sup>+</sup>CD4<sup>+</sup> cells and the ratio of CD3<sup>+</sup>CD4<sup>+</sup>/CD3<sup>+</sup>CD8<sup>+</sup>, the level of serum interleukine 12, which stimulated Th1 response and tumor-specific cytotoxic T lymphocytes cells[21]. Li et al. explored changes in tumor tissues of glioma rat that underwent argon-helium cryoablation combined with interleukin 12 treatment. This association boosted the immune function and increases antitumor ability[25]. Other authors analyze the synergism between cryoablation and GM-CSF (granulocyte macrophage colony-stimulating factor stimulating DCs). This association could recruit and activate DCs developing the tumoricidal T-cell responses. They demonstrated an activation of dendritic cells (DC) after cryoablation via the increase of rate of CD80, CD86, CD3, CD4, CD4/CD8, CD8+, CD11+, CD86+ [18][23][26][21][22]. These increases prove an activation of dendritic cells resulting of increase of cellular immunity.

The increase of the immunostimulatory cytokines IL6, IL1 $\beta$ , IL 12 and TNF $\alpha$  activate the DC antigen-presenting function and the cytotoxic T lymphocytes to kill tumor cells [21][18]. Zhang

et al. observed a decrease of IL10, playing a role on the anti-tumoral effect via DC [19]. IL10, immunomodulatory cytokine, promotes tumor growth.

- Apoptosis

Apoptosis is characterized by cell shrinkage, chromatin condensation, genomic fragmentation and caspase activation. Huang et al. observed a decrease of PCNA (proliferation cell nuclear antigen) with activation of DNA fragmentation. They demonstrated that the combined treatment, cryosurgery and rhTNF $\alpha$  have a synergic effect on glioma therapy by induction of apoptosis and inhibition of proliferation. Liu et al. found an activation of intrinsic apoptosis (rapid-onset apoptosis via activation of caspase-9) caused by freezing and activation of delayed apoptosis (extrinsic apoptosis via activation of caspase-8) induced by the released cellular contents. Glioma cells surviving under sublethal temperature undergo intrinsic or extrinsic apoptosis, increasing the induction of apoptosis. In vitro, cryoablation inhibits effects on cell proliferation and migration [24][20].

The necrotic tumor tissue, as a result of cryosurgery, promotes the release of soluble antigens stimulating the production of specific antitumor antibodies.

b) Series of patients

The characteristics of human studies were summarized in Table 3. The two articles demonstrated the feasibility of brain cryotherapy without demonstration of positive effect on overall survival.

Li et al. described their experience about MR imaging-guided cryoablation of cystic metastatic brain tumors in six patients[27]. The localizations were: left temporal lobe, cerebellum, parietal and basal ganglia area. The procedure was realized under local anesthesia. Cryoablation was performed with argon-based system, MRI compatible. A drill hole was made at the entry point and when the dura was opened, the patient moved into the MRI device. Tumor cyst aspiration

was performed before cryoablation. The cryoablation was performed using two freeze-thaw cycles (with lowest temperature measured at  $-185^{\circ}\text{C}$ ). The iceball was monitored using MR imaging. One patient died of a secondary complications 12 days after cryoablation. All patients tolerated the procedure without neurological deficits. The follow-up ranged from 12 days to 12 months. On follow-up at 3 and 7 days after the procedure, the lesions showed typical appearance of cryocoagulation necrosis (hypointense on T1W1, hyperintense on T2W). At 6 weeks, lesions had decreased in size.

The second study was published by Martynov et al. [28]. They analyzed 88 patients with supratentorial gliomas, not suitable for microsurgical resection, treated by stereotactic cryodestruction[28]. The localizations were cerebral lobes, insula, thalamus, internal capsules and corpus callosum. The mean volume of lesions was  $44.2\text{ cm}^3$ . The histology of lesions was oligodendroglioma, diffuse astrocytomas, anaplastic astrocytomas and glioblastomas (according to the WHO classification of Tumors of the Central Nervous System, 2016[29]). The stereotactic cryotherapy was performed with a commercially non-available prototype device. Solid carbon dioxide ( $-78^{\circ}\text{C}$ ) was used for cooling the acetone within the cryoprobe. Stereotactic trajectories were planned, and surgery was done under awake condition for adults and general anesthesia was used for children. A burr hole was made, and biopsy realized. After this step, a cryoprobe was inserted into the target and cryodestruction was done (at least two cycles). After cryotherapy, 83% received fractioned radiotherapy and 38% chemotherapy. Surgical complications were identified in 11.4% of cases (hematoma, brain oedema, infection) with 1.1% postoperative mortality. Three patients underwent a craniotomy after cryodestruction to evacuate blood clot or necrotic tissue. Neurological deficit was observed in 42 % of cases including 8% permanent deterioration neurological function.

The median survival of patients with of astrocytomas and glioblastomas were 46.9 months and 12.4 months respectively.

## DISCUSSION

The cryotherapy increases the cellular immunity through the activation of dendritic cell and the antigen-presenting function. One of the consequences of cryosurgery is the necrotic tissue promotes the release of soluble antigens stimulating the production of specific antitumor antibodies and increasing the activation of the immune system.

Cryoablation uses Argon/Helium gases to generate extreme cold temperatures, destroying tumors via direct cellular injury, induction of apoptosis, and micro-circulatory occlusion. A cryo-immunologic effect has also been proposed, where cryo-preserved tumoral antigens may provoke a host anti-tumoral response[10]. In fact, cryotherapy release tumor antigens and enhances migration of DCs from the tumor to the draining lymph nodes. The animals' studies demonstrate the DC maturation and activation with the enhancement of antigen-presenting function after cryotherapy. The enhanced host immunity after cryotherapy is probably secondary to the release of the soluble tumor antigens. These examples, in animals' models, suggesting the potential usefulness of the association of cryotherapy and immunomodulator in the management of gliomas. In our knowledge, the series studies were limited to some clinical observations with the demonstration of feasibility of tumor brain cryotherapy. **These two clinical series are not enough to issue indications of the cryotherapy. Patients will need to be well selected. The clinical attempts are scares secondary to the need for radiological expertise in the cryotherapy to realize MR-guided ablation. The potential complications of brain cryotherapy described for one study were hematoma, oedema and infections (11.4% of cases) with 1.1% of mortality and for the second study, no complication was described. Further study will be needed to quantify the exact rate of complications.**

MR-guidance enables precise lesion targeting and excellent ablation-zone (named “ice-ball”) visualization/monitoring, facilitating optimal treatment margins while avoiding collateral eloquent parenchymal damage. In combination therapy, MR-guided Cryoablation potentially offers anti-tumor immunity for recurrent glioblastoma and represents a future immune strategy. However, MR-guided cryoablation, an established treatment for extra-cranial tumors with both ablative and immunomodulatory effects, has not yet been applied to recurrent glioblastoma.

Recurrent Glioblastoma invariably follows primary tumor therapy and portends a poor prognosis. In the absence of standard treatment guidelines, repeat surgery, re-irradiation, and second-line chemotherapy typically achieve 20-30% 6-month progression-free survival rates[30][31]. Recently, novel therapeutic approaches including minimally-invasive laser ablation and immunotherapy have been reported [32][33][34]. The immunotherapy to treat glioblastoma represents a challenge secondary to the blood-brain barrier (BBB) associated with a suppressive tumor environment[4][35][36][37]. The BBB is a dynamic barrier and its integrity could be compromise by inflammation or brain pathologies[4]. One other mechanism is developed by Carpentier et al. with the Ultrasound-induced BBB opening to increase the penetration of a large drugs [38]. Cryotherapy on glioblastoma could increase the permeability of the BBB with infiltration of monocytes and lymphocytes from the periphery through the interaction between the extracranial and intracranial immune response.

Cells of the immune system assume a protective role for the cancer cells by masking cancer immunogenicity form circulating immune cells with the loss of microglia capacity to present antigens. To counter the inhibitory influences of cancer and intensify the immune potentiating effect of the cryoablation in glioblastomas, the immunomodulatory agents could be associate to the cryosurgery[39].

**Glioblastomas are characterized by a T cell dysfunction with a potent suppression of systemic immunity[40]. In this comprehensive review, the cryotherapy results in activation of DC with**

activation of T cell. The immunotherapy, such as the immune checkpoint inhibitors, on glioblastoma represents a therapeutic challenge secondary to the dysfunction of the T cell with the risk of treatment resistance. By activating DC and TC, cryotherapy could be associated to immune check point blockade and the immunotherapy could be effective.

## CONCLUSION

The use of cryosurgery is dependent on image-guided control of freezing the tissue. Adjunctive MR-guided cryoablation may potentially improve therapeutic efficacy for recurrent glioblastoma. A multimodal approach using surgery, radiotherapy, chemotherapy and immunotherapy in combination with cryotherapy represent a potent weapon against glioblastomas. The future immunomodulatory approaches might be combined with brain tumors cryoablation to increase the cryoimmune response. Further research is required to elucidate its potential role in cutting-edge neurosurgical management of this devastating tumor.

## REFERENCES

- [1] Stupp R, Mason WP, van den Bent MJ, Weller M, Fisher B, Taphoorn MJB, et al. Radiotherapy plus concomitant and adjuvant temozolomide for glioblastoma. *N Engl J Med* 2005;352:987–96. <https://doi.org/10.1056/NEJMoa043330>.
- [2] Sampson JH, Maus MV, June CH. Immunotherapy for Brain Tumors. *J Clin Oncol Off J Am Soc Clin Oncol* 2017;35:2450–6. <https://doi.org/10.1200/JCO.2017.72.8089>.
- [3] Hoang-Minh LB, Mitchell DA. Immunotherapy for Brain Tumors. *Curr Treat Options Oncol* 2018;19:60. <https://doi.org/10.1007/s11864-018-0576-3>.
- [4] Adhikaree J, Moreno-Vicente J, Kaur AP, Jackson AM, Patel PM. Resistance Mechanisms and Barriers to Successful Immunotherapy for Treating Glioblastoma. *Cells* 2020;9. <https://doi.org/10.3390/cells9020263>.
- [5] Larkin J, Chiarion-Sileni V, Gonzalez R, Grob J-J, Rutkowski P, Lao CD, et al. Five-Year Survival with Combined Nivolumab and Ipilimumab in Advanced Melanoma. *N Engl J Med* 2019;381:1535–46. <https://doi.org/10.1056/NEJMoa1910836>.
- [6] Robert C, Long GV, Brady B, Dutriaux C, Maio M, Mortier L, et al. Nivolumab in previously untreated melanoma without BRAF mutation. *N Engl J Med* 2015;372:320–30. <https://doi.org/10.1056/NEJMoa1412082>.

- [7] Reck M, Rodríguez-Abreu D, Robinson AG, Hui R, Csósz T, Fülöp A, et al. Pembrolizumab versus Chemotherapy for PD-L1-Positive Non-Small-Cell Lung Cancer. *N Engl J Med* 2016;375:1823–33. <https://doi.org/10.1056/NEJMoa1606774>.
- [8] Ansell SM, Lesokhin AM, Borrello I, Halwani A, Scott EC, Gutierrez M, et al. PD-1 blockade with nivolumab in relapsed or refractory Hodgkin's lymphoma. *N Engl J Med* 2015;372:311–9. <https://doi.org/10.1056/NEJMoa1411087>.
- [9] Motzer RJ, Escudier B, McDermott DF, George S, Hammers HJ, Srinivas S, et al. Nivolumab versus Everolimus in Advanced Renal-Cell Carcinoma. *N Engl J Med* 2015;373:1803–13. <https://doi.org/10.1056/NEJMoa1510665>.
- [10] Cazzato RL, Garnon J, Ramamurthy N, Koch G, Tsoumakidou G, Caudrelier J, et al. Percutaneous image-guided cryoablation: current applications and results in the oncologic field. *Med Oncol Northwood Lond Engl* 2016;33:140. <https://doi.org/10.1007/s12032-016-0848-3>.
- [11] Gonski A, Sackelariou R. Cryohypophysectomy for the relief of pain in malignant disease. *Med J Aust* 1984;140:140–2.
- [12] Moser RP, Abbott IR, Stephens CL, Lee YY. Computerized tomographic imaging of cryosurgical iceball formation in brain. *Cryobiology* 1987;24:368–75.
- [13] Copper IS. Cryogenic surgery: a new method of destruction or extirpation of benign or malignant tissues. *N Engl J Med* 1963;268:743–9. <https://doi.org/10.1056/NEJM196304042681401>.
- [14] Rand RW, Markham CH. CRYOTHALAMECTOMY FOR PARKINSON'S DISEASE. *Calif Med* 1964;101:248–52.
- [15] Stellar S, Cooper IS. Mortality and morbidity in cryothalamectomy for parkinsonism. A statistical study of 2868 consecutive operations. *J Neurosurg* 1968;28:459–67. <https://doi.org/10.3171/jns.1968.28.5.0459>.
- [16] Bisdas S, Roder C, Ernemann U, Tatagiba MS. Intraoperative MR Imaging in Neurosurgery. *Clin Neuroradiol* 2015;25 Suppl 2:237–44. <https://doi.org/10.1007/s00062-015-0443-6>.
- [17] Liberati A, Altman DG, Tetzlaff J, Mulrow C, Gøtzsche PC, Ioannidis JPA, et al. The PRISMA statement for reporting systematic reviews and meta-analyses of studies that evaluate health care interventions: explanation and elaboration. *J Clin Epidemiol* 2009;62:e1-34. <https://doi.org/10.1016/j.jclinepi.2009.06.006>.
- [18] Yin Z, Lu G, Xiao Z, Liu T, He X, Wang Q, et al. Antitumor efficacy of argon-helium cryoablation-generated dendritic cell vaccine in glioma. *Neuroreport* 2014;25:199–204. <https://doi.org/10.1097/WNR.0000000000000045>.
- [19] Zhang S-Z, He X-Z, Han S, Wang Q-F, Ye Y-Y, Zhu Z-Y, et al. Cryo-ablation improves anti-tumor immunity through recovering tumor educated dendritic cells in tumor-draining lymph nodes. *Drug Des Devel Ther* 2015:1449. <https://doi.org/10.2147/DDDT.S76592>.
- [20] Liu T, Wang X, Yin Z, Pan J, Guo H, Zhang S. Extracts from glioma tissues following cryoablation have proapoptosis, antiproliferation, and anti-invasion effects on glioma cells. *BioMed Res Int* 2014;2014:236939. <https://doi.org/10.1155/2014/236939>.
- [21] Lin C, Wang Q, Lu G, Yin Z, He X, Xu H, et al. In-situ administration of dendritic cells following argon-helium cryosurgery enhances specific antiglioma immunity in mice. *Neuroreport* 2014;25:900–8. <https://doi.org/10.1097/WNR.0000000000000196>.
- [22] Xu H, Wang Q, Lin C, Yin Z, He X, Pan J, et al. Synergism between cryoablation and GM-CSF: enhanced immune function of splenic dendritic cells in mice with glioma. *NeuroReport* 2015;26:346–53. <https://doi.org/10.1097/WNR.0000000000000351>.
- [23] Li M, Zhang S, Zhou Y, Guo Y, Jiang X, Miao L. Argon-helium cryosurgery for treatment of C6 gliomas in rats and its effect on cellular immunity. *Technol Cancer Res Treat*

- 2010;9:87–94. <https://doi.org/10.1177/153303461000900110>.
- [24] Huang K-M, Peng M, Feng Y-Q, Huang H, Tu H-J, Luo J, et al. Cryosurgery and rhTNF- $\alpha$  play synergistic effects on a rat cortex C6 glioma model. *Cryobiology* 2012;64:43–9. <https://doi.org/10.1016/j.cryobiol.2011.09.137>.
- [25] Li M, Cui Y, Li X, Guo Y, Wang B, Zhang J, et al. Functional Changes of Dendritic Cells in C6 Glioma-Bearing Rats That Underwent Combined Argon-Helium Cryotherapy and IL-12 Treatment. *Technol Cancer Res Treat* 2016;15:618–24. <https://doi.org/10.1177/1533034615606322>.
- [26] Li M, Cui Y, Li X, Guo Y, Wang B, Zhang J, et al. Functional Changes of Dendritic Cells in C6 Glioma-Bearing Rats That Underwent Combined Argon-Helium Cryotherapy and IL-12 Treatment. *Technol Cancer Res Treat* 2016;15:618–24. <https://doi.org/10.1177/1533034615606322>.
- [27] Li C, Wu L, Song J, Liu M, Lv Y, Sequeiros RB. MR imaging-guided cryoablation of metastatic brain tumours: initial experience in six patients. *Eur Radiol* 2010;20:404–9. <https://doi.org/10.1007/s00330-009-1554-8>.
- [28] Martynov BV, Kholyavin AI, Nizkovolos VB, Parfenov VE, Trufanov GE, Svistov DV. Stereotactic Cryodestruction of Gliomas. *Prog Neurol Surg* 2018;32:27–38. <https://doi.org/10.1159/000469677>.
- [29] Louis DN, Perry A, Reifenberger G, von Deimling A, Figarella-Branger D, Cavenee WK, et al. The 2016 World Health Organization Classification of Tumors of the Central Nervous System: a summary. *Acta Neuropathol (Berl)* 2016;131:803–20. <https://doi.org/10.1007/s00401-016-1545-1>.
- [30] Weller M, Cloughesy T, Perry JR, Wick W. Standards of care for treatment of recurrent glioblastoma--are we there yet? *Neuro-Oncol* 2013;15:4–27. <https://doi.org/10.1093/neuonc/nos273>.
- [31] Morisse MC, Etienne-Selloum N, Bello-Roufai D, Blonski M, Taillandier L, Lorgis V, et al. Long-term survival in patients with recurrent glioblastoma treated with bevacizumab: a multicentric retrospective study. *J Neurooncol* 2019;144:419–26. <https://doi.org/10.1007/s11060-019-03245-5>.
- [32] Kamath AA, Friedman DD, Hacker CD, Smyth MD, Limbrick DD, Kim AH, et al. MRI-Guided Interstitial Laser Ablation for Intracranial Lesions: A Large Single-Institution Experience of 133 Cases. *Stereotact Funct Neurosurg* 2017;95:417–28. <https://doi.org/10.1159/000485387>.
- [33] Seystahl K, Wick W, Weller M. Therapeutic options in recurrent glioblastoma--An update. *Crit Rev Oncol Hematol* 2016;99:389–408. <https://doi.org/10.1016/j.critrevonc.2016.01.018>.
- [34] Bozinov O, Yang Y, Oertel MF, Neidert MC, Nakaji P. Laser interstitial thermal therapy in gliomas. *Cancer Lett* 2020;474:151–7. <https://doi.org/10.1016/j.canlet.2020.01.024>.
- [35] Cloughesy TF, Mochizuki AY, Orpilla JR, Hugo W, Lee AH, Davidson TB, et al. Neoadjuvant anti-PD-1 immunotherapy promotes a survival benefit with intratumoral and systemic immune responses in recurrent glioblastoma. *Nat Med* 2019;25:477–86. <https://doi.org/10.1038/s41591-018-0337-7>.
- [36] Schalper KA, Rodriguez-Ruiz ME, Diez-Valle R, López-Janeiro A, Porciuncula A, Idoate MA, et al. Neoadjuvant nivolumab modifies the tumor immune microenvironment in resectable glioblastoma. *Nat Med* 2019;25:470–6. <https://doi.org/10.1038/s41591-018-0339-5>.
- [37] Wick W, Gorlia T, Bendszus M, Taphoorn M, Sahm F, Harting I, et al. Lomustine and Bevacizumab in Progressive Glioblastoma. *N Engl J Med* 2017;377:1954–63. <https://doi.org/10.1056/NEJMoa1707358>.



[38] Dréan A, Lemaire N, Bouchoux G, Goldwirt L, Canney M, Goli L, et al. Temporary blood-brain barrier disruption by low intensity pulsed ultrasound increases carboplatin delivery and efficacy in preclinical models of glioblastoma. *J Neurooncol* 2019;144:33–41. <https://doi.org/10.1007/s11060-019-03204-0>.

[39] Sabel MS. Cryo-immunology: a review of the literature and proposed mechanisms for stimulatory versus suppressive immune responses. *Cryobiology* 2009;58:1–11. <https://doi.org/10.1016/j.cryobiol.2008.10.126>.

[40] Sampson JH, Gunn MD, Fecci PE, Ashley DM. Brain immunology and immunotherapy in brain tumours. *Nat Rev Cancer* 2020;20:12–25. <https://doi.org/10.1038/s41568-019-0224-7>.

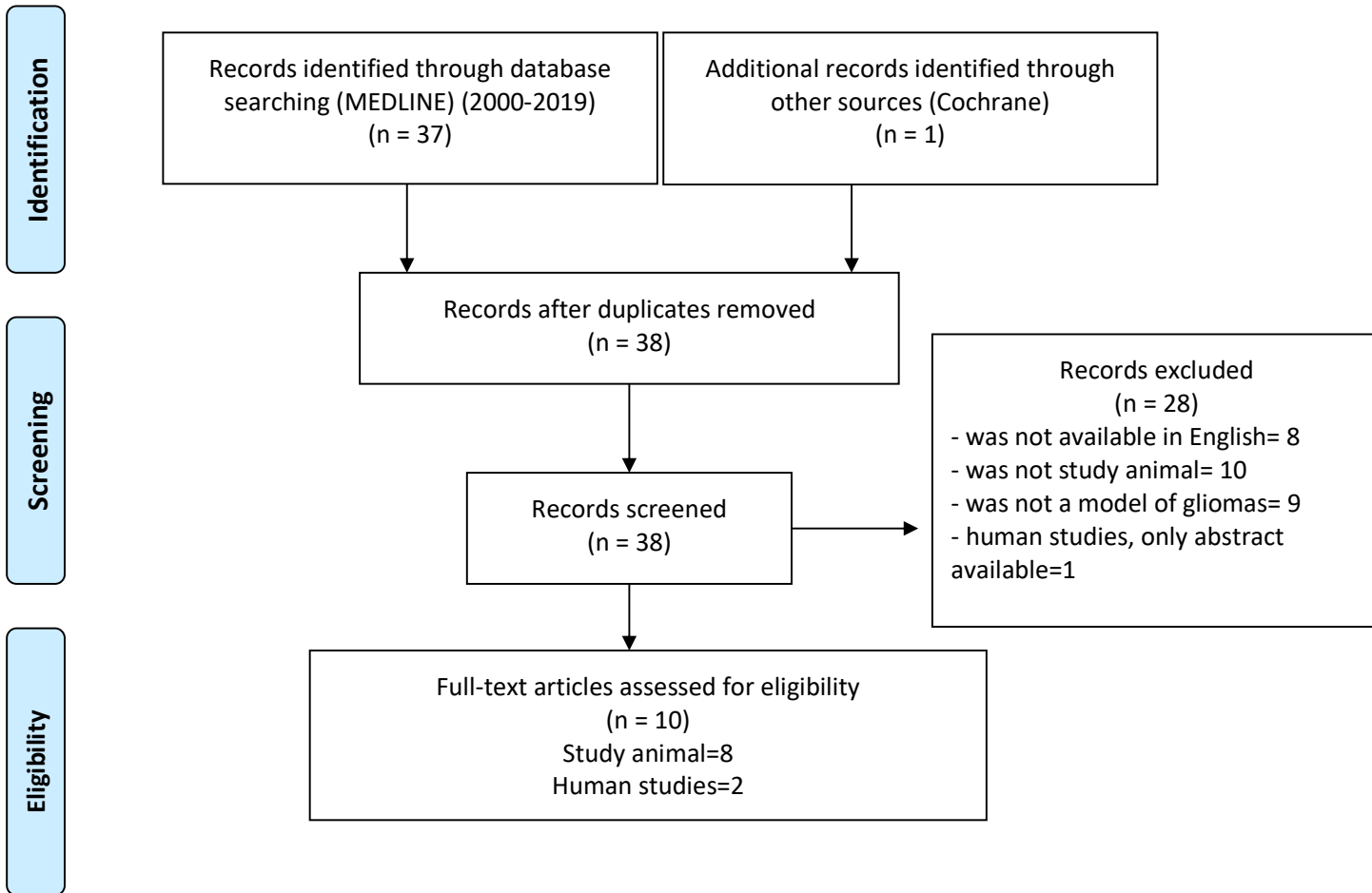
## LEGENDES

Table 1: Flow Diagram using PRISMA method

Table 2 : Summary of Experimental studies

Table 3: Summary of Series of Patients

Table 1: Flow Diagram using PRISMA method



Articles	Groupe	Localization	Models Cell line	Cryotherapy	Analyze	Effect	Commentary
Yin et al. [18]	NA	/	C57BL/6 and BALB/c mice GL261 glioma	3 cycles (-140°C) 3mm	DC80: DC86 IL6, IL1β, IL12	Increase Increase	DC maturation
Li et al. [23]	4	Subcutaneous	Wistar rat C6 glioma	1 cycle (-140°C) 2mm	DC3 DC4 DC4/DC8	Increase Increase	Enhanced cellular immunity
Zhang et al. [19]	4	Subcutaneous	C57BL/6 mice BALB/c mice GL261 glioma	3 cycles -140°C 2mm	Il10	Decrease	Improve anti- tumor effect via DC activation
Huang et al. [24]	4 Combined with rhTNFα	Brain Cortex	Wistar rat C6 glioma	2 cycles Nitrogène -196°C 2mm	PCNA	Decrease	Enhancing the inhibition of proliferation Induction of apoptosis
Liu et al. [20]	2	Subcutaneous	C57 mice GL261 glioma	3 cycles 3mm	Caspase 9  Caspase 8	Activation of intrinsic pathway Activation of extrinsic pathway	Induction of apoptosis
Li et al. [25]	4 Combined with IL12	Subcutaneous	Wistar rats C6 Glioma	2 cycles -140°C	DC11+ DC86+ IFNλ DC marker	Increase Increase Increase	Boosted immune function via DC activation. Activation Th1- type immunity
Lin et al. [21]	4 Combined with DC	Subcutaneous	C57BL/6 mice GL261 glioma	2 cycles -140°C 2 mm	DC3, DC3/DC4 IL12 DC2DC4/DC3 DC8	Increase Increase Increase	Enhance systemic antitumor immunity
Xu et al. [22]	4 combined with GM- CSF	Subcutaneous	C57BL/6 mice GL261 glioma	-140°C 2mm	Interferonλ DC8+	Increase Increase	Enhance activation of DCs

Table 2 : Summary of Experimental studies

DC: Dendritic cell

IL: Interleukin

PCNA: proliferation cell nuclear antigen

GM-CSF: granulocyte macrophage colony-stimulating factor

TNFα: cytokine tumor necrosis factor-alpha

NA: Non Available

Authors	Patients	Histology	Cryotherapy	Treatment	MRI follow-up	Complications	Survival
Li et al. [27]	6	Cystic metastatics	-185°C, AL, 2 cycles (10-5-10) Stereotactic	Mannitol Corticosteroid	J3/J7	No neurological deficit	5 patients survived at 3 months
Martynov et al. [28]	88	Supratentorial gliomas	-78°C (cooling with acetone) 1.5-6mm AL, 2 cycles, Stereotactic	NA	2-6 months	1,1% of mortality 11,4% of complications (8% permanent)	GBM: 12,4 months Anaplastic astrocytoma: 46,9 months

Table 3: Summary of Series of Patients

GBM: Glioblastoma

MRI: Magnetic resonance imaging

AL: Local anesthesia

NA: Non Available