



**HAL**  
open science

## Minimally invasive anterior plate osteosynthesis of the distal radius: A 710 case-series

Paul Vernet, Stéphanie Gouzou, Juan José Hidalgo Diaz, Sybille Facca,  
Philippe Liverneaux

### ► To cite this version:

Paul Vernet, Stéphanie Gouzou, Juan José Hidalgo Diaz, Sybille Facca, Philippe Liverneaux. Minimally invasive anterior plate osteosynthesis of the distal radius: A 710 case-series. *Orthopaedics & Traumatology: Surgery & Research*, 2020, 106, pp.1619 - 1625. 10.1016/j.otsr.2020.04.024 . hal-03492926

**HAL Id: hal-03492926**

**<https://hal.science/hal-03492926>**

Submitted on 15 Dec 2022

**HAL** is a multi-disciplinary open access archive for the deposit and dissemination of scientific research documents, whether they are published or not. The documents may come from teaching and research institutions in France or abroad, or from public or private research centers.

L'archive ouverte pluridisciplinaire **HAL**, est destinée au dépôt et à la diffusion de documents scientifiques de niveau recherche, publiés ou non, émanant des établissements d'enseignement et de recherche français ou étrangers, des laboratoires publics ou privés.



Distributed under a Creative Commons Attribution - NonCommercial 4.0 International License

## Original article

### Minimally invasive anterior plate osteosynthesis of the distal radius: a 710 case series

Paul **Vernet**<sup>1</sup>, Stéphanie **Gouzou**<sup>1</sup>, Juan José **Hidalgo Diaz**<sup>1</sup>, Sybille **Facca**<sup>1</sup>, Philippe **Liverneaux**<sup>1</sup>

<sup>1</sup> Department of Hand Surgery, SOS Hand, University Hospital of Strasbourg, FMTS, University of Strasbourg, Icube CNRS 7357, 1 Avenue Molière, 67000 Strasbourg, France

**Corresponding Author:** Liverneaux Philippe

Hand Surgery Department, Strasbourg University Hospitals, 1 Avenue Molière, F-67000 Strasbourg, France

Tel. + 33 6 88 89 47 79

Philippe.liverneaux@chru-strasbourg.fr

## **Abstract**

### **Introduction**

Since the 2000s, internal fixation of distal radius fracture by volar locking plate on an extended flexor carpi radialis (FCR) approach has become the gold-standard.

### **Objective**

The present study aimed to assess medium-term results of minimally invasive plate osteosynthesis (MIPO) in distal radius fracture.

### **Material and methods**

The series comprised 710 cases (512 female; mean age, 58 years). The 15 mm approach was on the lateral edge of the FCR. The plate was slipped under the pronator quadratus. Closure used intradermal running suture without drain or orthosis.

### **Results**

At a mean 7 months' follow-up, mean scar length was 17 mm (range, 10-40 mm), pain 1.13/10 (0-8), Quick-DASH 13.28 (0-86.36), and patient-rated wrist evaluation (PRWE) 11.48 (0-91). Compared to contralateral values, mean flexion was 87.23%, extension 88.52%, pronation 96.17%, supination 93.41%, and grip strength 79.68%. Hardware was removed in 45.92% of cases. There were 16 cases of secondary displacement, with 4 revision procedures, 1 of sepsis at 6 months, 10 of complex regional pain syndrome, and 14 of median nerve paresthesia, with 4 carpal tunnel release procedures.

### **Discussion**

The minimally invasive FCR approach can be used for volar plate fixation of distal radial fracture. It has the advantage of conserving ligamentotaxis, facilitating reduction and improving scar esthetics. The incision can be extended if need be.

**Level of evidence:** III; single-center retrospective study

**Keywords:** anterior plate, distal radius fracture, MIPO, minimally invasive

## Introduction

Since 2000, distal radius fracture fixation by volar locking plate has become the gold-standard [1,2]. Three approaches have been described: traditional, extended [3], and minimally invasive [4].

The traditional flexor carpi radialis (FCR) approach (Fig. 1A), described for anterior displacement [5], is the distal part of Henry's approach [6]. It spares the extensor system more effectively than dorsal approaches [7] and facilitates ligamentotaxis for posterior displacement fracture [8].

The extended FCR approach (Fig. 1B), described for posterior displacement, is 8-10 cm long [3]. To avoid flexor system impingement, the plate should not go beyond the watershed line at the distal edge of the pronator quadratus (PQ). The PQ is raised, exposing the fracture, without [3] or with [9] risk of necrosis. Unlike the traditional approach, this allows the proximal fragment to be mobilized in pronation, passing through the fracture for wide exposure [8]. Ligamentotaxis cannot be used here.

Minimally invasive plate osteosynthesis (MIPO) was developed for the hip [10], knee [11, 12], ankle [13], shoulder [14, 15] and elbow [16]. It conserves bone vascularization [17], increases consolidation [18], reduces infection, simplifies reduction by ligamentotaxis [19], and improves esthetics [10]. It was applied to the wrist in 2000 [20], promoting consolidation [21] as, unlike in traditional fixation, the PQ, periosteum and vascularization are conserved [6, 22]. The esthetic advantage is incontestable [23]. The technique uses a locking plate [4, 24]. Until 2013, 2 approaches were used [23, 25, 26], and just 1 since [27-30], 2 approaches being reserved for metadiaphyseal fracture [31, 32]. Lengths range from 15 mm [30] to 50 mm [26]. Single approaches are longitudinal [27-30]; in double approaches, the proximal one is longitudinal and the distal one either longitudinal [25, 26] or transverse [23, 31, 33-35]. Transverse incisions can mimic phlebotomy [21]. Smaller incisions ( $\leq 15$  mm) require special instrumentation [28-30]. The plate is slipped under the PQ, simplifying reduction [29].

MIPO requires no drainage [36] or orthosis [37], and allows immediate weight-bearing; Physiotherapy is prescribed only in case of stiffness [28, 29].

The aim of the present study was to assess medium-term results of MIPO for distal radial fracture in a series of 710 patients.

## **Materials and method**

### **Patients**

Our local review board approved this retrospective study. The 1,430 files for patients operated on between 2014 and 2018 for distal radius fracture MIPO were analyzed. 720 were excluded for incomplete data, follow-up <6 months, simultaneous bilateral fracture or associated osteoligamentous lesions of the wrist. The included cases comprised adult patients with fresh fracture (<2 weeks), without associated lesions, and with follow-up >6 months.

The series thus comprised 710 patients, with a mean age of 58 years (range, 18-95 years), including 512 women, divided into 2 groups: group 1, AO fracture types A and B; group 2, type C.

### **Surgery**

Surgery was ambulatory whenever possible, under locoregional anesthesia, with pneumatic tourniquet, in deferred emergency except in case of complications (skin opening, acute median nerve compression). A 15 mm segment was traced laterally to the FCR, 20 mm proximal to the radial styloid apophysis (Fig. 2A). The skin was separated from the underlying fascia for 50 mm proximally and 20 mm distally. The FCR sheath was incised over an equivalent length (Figs. 2B and 2C). The neurovascular and muscle structures, except for the radial artery, were inclined toward the ulna. The distal PQ was incised

transversally and released by elevator, conserving the ulnar and radial insertions (Fig. 2D). The plate, fixed to a guide, was introduced beneath the PQ (Fig. 2E), checking absence of noble structures below (notably flexor pollicis longus (FPL)), and kept temporarily in place by two 1.8 mm K-wires, under fluoroscopic control (Fig. 2F). The epiphyseal (Fig. 2G) then diaphyseal screws were introduced Fig. 2H). The skin was closed without drainage by intradermal running suture. Gentle active mobilization was encouraged on recovery from anesthesia [37].

As appropriate, hardware removal used the same approach [38].

### **Assessment**

Thirteen quantitative and 5 qualitative variables were assessed at last follow-up (> 6 months).

Quantitative variables comprised incision length (mm), pain (on visual analogue scale from 0 = no pain to 10 = worst possible pain), and upper limb function (on QuickDASH [39], and on patient-rated wrist evaluation (PRWE) [40] from 0 = normal to 100 = no function). Grip strength in pronation-supination on dynamometry in position 2 (Sammons Preston Rolyan™, Bolingbrook, IL, USA) and range of motion (flexion, extension, ulnar and radial inclination, pronation-supination) were assessed as percentage of contralateral values.

Qualitative variables comprised AO fracture grade, intra- and post-operative complications, secondary displacement, infection and type 1 complex regional pain syndrome (CRPS-1).

### **Statistics**

Statistical analysis was descriptive and comparative.

For descriptive analysis, normality of distribution was checked on Shapiro-Wilk test.

For quantitative variables, descriptive analysis comprised position (mean, median, range and 1<sup>st</sup> and 3<sup>rd</sup> quartiles) and scatter (variance, standard deviation, range, interquartile range).

For qualitative variables, descriptive analysis comprised number and percentage.

Comparative analysis assessed intergroup differences in QuickDASH and PRWE on non-parametric Mann-Whitney-Wilcoxon test (non-normal distribution).

## Results

Mean incision length was 17 mm (range, 10-40 mm) (Fig. 3A). Mean tourniquet time was 41 min (range, 11-120 min) (Fig. 3B).

At last follow-up, mean pain rating was 1.13 (range, 0-8) (Fig. 3C), QuickDASH 13.28 (0- 86.36) (Fig. 3D), and PRWE 11.48 (0- 91) (Fig. 3E). Mean grip strength was 79.68% (18.18-360%) (Fig. 3F), flexion 87.23% (0-133.33%) (Fig. 3G), extension 88.52% (25-133.33%) (Fig. 3H), ulnar inclination 91.97% (25-150%), radial inclination 92.97% (0-166.67%), pronation 96.17% (40-133,33%) (Fig. 3I) and supination 93.41% (12.5-130.77%) (Fig. 3J).

There were 16 cases of secondary displacement, 3 of which underwent revision surgery, 1 of sepsis at 6 months in a context of septicemia, 10 of CRPS-1, and 14 of median nerve paresthesia, 4 of which were treated by carpal tunnel nerve release.

The intergroup differences in QuickDASH ( $p=0.37$ ) and PRWE ( $p=0.44$ ) were not significant.

## Discussion

Minimally invasive techniques are becoming widespread for esthetic, technical and physiological reasons.

Technically, a limited surgical approach conserves the muscle and ligament attachments of the wrist and facilitates reduction by ligamentotaxis [20, 41, 42]. This contrasts with the extended FCR approach, which involves “undressing” the distal radius [3].

Physiologically, a limited surgical approach limits the bone ischemia inducing necrosis or non-union between small fragments sometimes found in extensive approaches with deperiostealization [43]. It also conserves the fracture hematoma, accelerating consolidation [44].

Indications for MIPO in distal radius fracture are increasing, with 500 published cases (Table I). Some authors reserve it for extra-articular [21] and diaphyseal-metaphyseal fracture [33]. When plate fixation is not possible, arthroscopy can be useful [45]. In case of metadiaphyseal fracture, a double proximal and distal approach is needed [32].

Surgery can be deferred and performed on an outpatient basis in the absence of signs of severity: open fracture, neurovascular injury, significant displacement [21, 28]. Osteotomy for malunion can be performed as MIPO [46, 47]. Posterior plates require 2 approaches and 2 bicolunar plates [48].

There have been no reported randomized comparative trials. A continuous prospective study comparing the traditional approach versus MIPO [21] found no difference in pain, range of motion, grip strength, DASH score or radiographs. The traditional technique was easier to perform. Esthetic satisfaction was not assessed. Studies without control group reported no differences with respect to the traditional technique (Table I).

In extra-articular fracture, results for a longitudinal or a transverse approach did not differ, but the longitudinal scar was shorter [49].

In the 477 reported cases of MIPO (Table I), there were 42 complications, a rate (8.8%) comparable to other techniques. Pain is the most frequent complication: 14 cases of CRPS and 2 of ulnar pain without anatomic substrate. There were 9 cases of flexor tenosynovitis and 2 FPL tears; prevention involves checking flexor system freedom [21, 28]. One author reported an FPL blocked under the hardware [50]. Osteoarticular complications comprised 3 intra-articular screws, 2 cases of stiffness, 1 migrated screw and 6 secondary displacements. Absence of intra-articular and notably distal radioulnar screws needs checking



under fluoroscopy on skyline view [51]. There were 2 cases of delayed healing [33], and 1 lesion of the palmar cutaneous branch of the median nerve [31].

All MIPO techniques involve a learning curve [52]. It is best to begin with simple extra-articular fractures on a traditional approach, progressively reducing incision length down to 15 mm or 10 mm [53]. In case of difficulty, the approach can be enlarged, which is not possible with the extended FCR approach.

The minimally invasive FCR approach can be used for volar plate osteosynthesis in distal ulnar fracture. The advantages comprise conserving ligamentotaxis, thereby facilitating reduction, and better scar esthetics. In case of difficulty, the approach can be enlarged.

#### **Acknowledgments**

Pr François Severac, Marie Mielcarek, Pôle de Santé Publique, Secteur Méthodologie et Biostatistiques, Hôpitaux Universitaires de Strasbourg, France

**Disclosure of interest:** Philippe Liverneaux has interests in Argomedical and Newclip Technics. The other authors have no conflicts of interest to disclose.

**Funding:** none

#### **Author contributions:**

Paul Vernet: data collection

Stéphanie Gouzou: surgery

Sybille Facca: surgery

Philippe Liverneaux: article writing

## References

1. Orbay JL. The treatment of unstable distal radius fractures with volar fixation. *Hand Surg.* 2000;5:103-112
2. Orbay JL, Fernandez DL. Volar fixation for dorsally displaced fractures of the distal radius: a preliminary report. *J Hand Surg Am.* 2002;27:205-215
3. Wijffels MM, Orbay JL, Indriago I, Ring D. The extended FCR approach for partially healed malaligned fractures of the distal radius. *Injury.* 2012;43:1204-1208
4. Liverneaux P, Ichihara S, Facca S, Hidalgo Diaz JJ. Outcomes of minimally invasive plate osteosynthesis (MIPO) with volar locking plates in distal radius fractures: A review. *Hand Surg Rehabil.* 2016;35S:S80-S85
5. Smith RS, Crick JC, Alonso J, Horowitz M. Open reduction and internal fixation of volar lip fractures of the distal radius. *J Orthop Trauma.* 1988;2:181-187
6. Henry AK. Complete exposure of the radius. *Exposures of long bones and other surgical methods*, John Wright & Sons Ltd, Bristol (1927),pp.9-12
7. Mares O, Coulomb R, Lazerges C, Bosch C, Kouyoumdjian P. Surgical exposures for distal radius fractures. *Hand Surg Rehabil.* 2016;35S: S39-S43
8. Orbay JL, Infante A, Khouri RK, Fernandez DL. The Extended FCR Approach: A New Perspective for the Distal Radius Fracture. *Tech Hand Up Extrem Surg.* 2001;5:204-211
9. Placzek JD, Sobol GV, Arnoczky SP, Quinn M, Magnell T. The effect of an extended FCR approach on blood flow to the distal radius: a cadaveric study. *Orthopedics.* 2005;28:1364-1367
10. Krettek C, Schandelmaier P, Miclau T, Tscherne H. Minimally invasive percutaneous plate osteosynthesis (MIPPO) using the DCS in proximal and distal femoral fractures. *Injury.* 1997;28:20-30
11. Kim JJ, Oh HK, Bae JY, Kim JW. Radiological assessment of the safe zone for medial minimally invasive plate osteosynthesis in the distal femur with computed tomography angiography. *Injury.* 2014;45:1964-1969
12. Bhat R, Wani MM, Rashid S, Akhter N. Minimally invasive percutaneous plate osteosynthesis for closed

distal tibial fractures: a consecutive study based on 25 patients. *Eur J Orthop Surg Traumatol*. 2015;25:563-568

13. Pires RE, Mauffrey C, de Andrade MA, Figueiredo LB, Giordano V, Belloti JC, dos Reis FB. Minimally invasive percutaneous plate osteosynthesis for ankle fractures: a prospective observational cohort study. *Eur J Orthop Surg Traumatol*. 2014;24:1297-1303
14. Gao YB, Tong SL, Yu JH, Lu WJ. Case control study on open reduction internal fixation (ORIF) and minimally invasive percutaneous plate osteosynthesis (MIPPO) for the treatment of proximal humerus fractures in aged. *Zhongguo Gu Shang*. 2015;28:335-339
15. Zhang Y, Xu J, Zhang C, Sun Y. Minimally invasive plate osteosynthesis for midshaft clavicular fractures using superior anatomic plating. *J Shoulder Elbow Surg*. 2016;25:7-12
16. Zogbi DR, Terrivel AM, Mouraria GG, Mongon ML, Kikuta FK, Filho AZ. Fracture of distal humerus: MIPO technique with visualization of the radial nerve. *Acta Ortop Bras*. 2014;22:300-303
17. Helfet DL, Shonnard PY, Levine D, Borrelli J Jr. Minimally invasive plate osteosynthesis of distal fractures of the tibia. *Injury*. 1997;28:42-48
18. Wagner M. General principles for the clinical use of the LCP. *Injury*. 2003;34:31-42
19. Agee JM. Distal radius fractures. Multiplanar ligamentotaxis. *Hand Clin*. 1993;9:577-585
20. Geissler WB, Fernandes D. Percutaneous and limited open reduction of intra-articular distal radial fractures. *Hand Surg*. 2000;5:85-92
21. Zenke Y, Sakai A, Oshige T, Moritani S, Fuse Y, Maehara T, Nakamura T. Clinical results of volar locking plate for distal radius fractures: conventional versus minimally invasive plate osteosynthesis. *J Orthop Trauma*. 2011;25:425-431
22. Heim U, Pfeiffer KM. *Internal Fixation of Small Fractures*, 3rd ed. Springer Verlag, Berlin (1987)
23. Yoshikawa Y, Saito T, Matsui H. A new cosmetic approach for volar fixed-angle plate fixation to treat distal radius fractures. *J Jpn Soc Surg Hand*. 2008;24:889-893
24. Duncan SF, Weiland AJ. Minimally invasive reduction and osteosynthesis of articular fractures of the distal radius. *Injury*. 2001;32:14-24
25. Imatani J, Noda T, Morito Y, Sato T, Hashizume H, Inoue H. Minimally invasive plate osteosynthesis for

- comminuted fractures of the metaphysis of the radius. *J Hand Surg Br.* 2005;30:220-225
26. Sen MK, Strauss N, Harvey EJ. Minimally invasive plate osteosynthesis of distal radius fractures using a pronator sparing approach. *Tech Hand Up Extrem Surg.* 2008;12:2-6
  27. Abe Y, Yoshida K, Tominaga Y. Less invasive surgery with wrist arthroscopy for distal radius fracture. *J Orthop Sci.* 2013;18:398-404
  28. Zemirline A, Naito K, Lebailly F, Facca S, Liverneaux P. Distal radius fixation through a mini-invasive approach of 15 mm. Part 1: feasibility study. *Eur J Orthop Surg Traumatol.* 2014;24:1031-1037
  29. Rey PB, Rochet S, Loisel F, Obert L. Technical note: How to spare the PQ during MIPO of distal radius fractures by using a mini-volar plate. *Chir Main.* 2014;33:95-99
  30. Lebailly F, Zemirline A, Facca S, Gouzou S, Liverneaux P. Distal radius fixation through a mini-invasive approach of 15 mm. Part 1: a series of 144 cases. *Eur J Orthop Surg Traumatol.* 2014;24:877-890
  31. Wei XM, Sun ZZ, Rui YJ, Song XJ. Minimally invasive plate osteosynthesis for distal radius fractures. *Indian J Orthop.* 2014;48:20-24
  32. Pire E, Hidalgo Diaz JJ, Salazar Botero S, Facca S, Liverneaux PA. Long Volar Plating for Metadiaphyseal Fractures of Distal Radius: Study Comparing Minimally Invasive Plate Osteosynthesis versus Conventional Approach. *J Wrist Surg.* 2017;6:227-234
  33. Wei XM, Sun ZZ, Rui YJ, Song XJ, WM Jiang. Minimally invasive percutaneous plate osteosynthesis for distal radius fractures with long-segment metadiaphyseal comminution. *Orthop Traumatol Surg Res.* 2016;102:333-338
  34. Chmielnicki M, Prokop A. New minimally invasive approach for palmar plating in distal radius fractures. *Z Orthop Unfall.* 2015;153:25-28
  35. Chen CY, Lin KC, Yang SW, Renn JH, Tarng YW. Clinical results of using minimally invasive long plate osteosynthesis versus conventional approach for extensive comminuted metadiaphyseal fractures of the radius. *Arch Orthop Trauma Surg.* 2015;135:361-367
  36. Prunières G, Hidalgo Diaz JJ, Vernet P, Salazar Botero S, Facca S, Liverneaux PA. Is there a relevance of suction drainage in non-septic wrist surgery? *Orthop Traumatol Surg Res.* 2017;103:453-455
  37. Duprat A, Hidalgo Diaz JJ, Vernet P, Gouzou S, Facca S, Igeta Y, Liverneaux P. Volar Locking Plate

- Fixation of Distal Radius Fractures: Splint versus Immediate Mobilization. *J Wrist Surg.* 2018;7:237-242
38. Medda PL, Matheron AS, Hidalgo Diaz JJ, Maire N, Vernet P, Facca S, Liverneaux P. Minimally invasive hardware removal after minimally invasive distal radius plate osteosynthesis (MIPO): Feasibility study in a 388-case series. *Orthop Traumatol Surg Res.* 2017;103:85-87
39. Gummesson C, Ward MM, Atroshi I. The shortened disabilities of the arm, shoulder and hand questionnaire (Quick DASH): validity and reliability based on responses within the full-length DASH. *BMC Musculoskelet Disord.* 2006;18:7-44
40. MacDermid JC, Turgeon T, Richards RS, Beadle M, Roth JH. Patient rating of wrist pain and disability: a reliable and valid measurement tool. *J Orthop Trauma.* 1998;12:577-586
41. Bindra RR. Biomechanics and biology of external fixation of distal radius fractures. *Hand Clin.* 2005;21:363-373
42. Kapandji A. Biomechanics of the carpus and the wrist. *Ann Chir Main.* 1987;6:147-169
43. Segalman KA, Clark GL. Un-united fractures of the distal radius: a report of 12 cases. *J Hand Surg Am.* 1998;23:914-919
44. Kolar P, Schmidt-Bleek K, Schell H, Gaber T, Toben D, Schmidmaier G, Perka C, Buttgereit F, Duda GN. The early fracture hematoma and its potential role in fracture healing. *Tissue Eng Part B Rev.* 2010;16:427-434
45. Zemirline A, Taleb C, Facca S, Liverneaux P. Minimally invasive surgery of distal radius fractures: a series of 20 cases using a 15mm anterior approach and arthroscopy. *Chir Main.* 2014;33:263-271
46. Taleb C, Zemirline A, Lebailly F, Bodin F, Facca S, Gouzou S, Liverneaux P. Minimally invasive osteotomy for distal radius malunion: a preliminary series of 9 cases. *Orthop Traumatol Surg Res.* 2015;101:861-865
47. Viegas SF. A minimally invasive distal radial osteotomy for treatment of distal radius fracture malunion. *Tech Hand Up Extrem Surg.* 1997;1:70-76
48. Chen AC, Chou YC, Cheng CY. Distal radius fractures: Minimally invasive plate osteosynthesis with dorsal bicolumnar locking plates fixation. *Indian J Orthop.* 2017;51:93-98
49. Galmiche C, Rodríguez GG, Xavier F, Igeta Y, Hidalgo Diaz JJ, Liverneaux P. Minimally Invasive Plate

Osteosynthesis for Extra-articular Distal Radius Fracture in Postmenopausal Women: Longitudinal versus Transverse Incision. *J Wrist Surg.* 2019;8:18-23

50. Chiu YC, Kao FC, Tu YK. Flexor pollicis longus tendon entrapment after performing minimally invasive plate osteosynthesis of a distal radius fracture: a case report. *Hand Surg.* 2013;18:403-406
51. Vaiss L, Ichihara S, Hendriks S, Taleb C, Liverneaux P, Facca S. The utility of the fluoroscopic skyline view during volar locking plate fixation of distal radius fractures. *J Wrist Surg.* 2014;3:245-249
52. Thornhill TS. The mini-incision hip: proceed with caution. *Orthopedics.* 2004;27:193-194
53. Naito K, Zemirline A, Sugiyama Y, Obata H, Liverneaux P, Kaneko K. Possibility of fixation of a distal radius fracture with a volar locking plate through a 10 mm approach. *Tech Hand Up Extrem Surg.* 2016;20:71-76

## Figure legends

### Figure 1 Anterior approaches to the distal radius

- A. Traditional FCR approach.
- B. Extended FCR approach.

### Figure 2 Volar MIPO in distal radius fracture

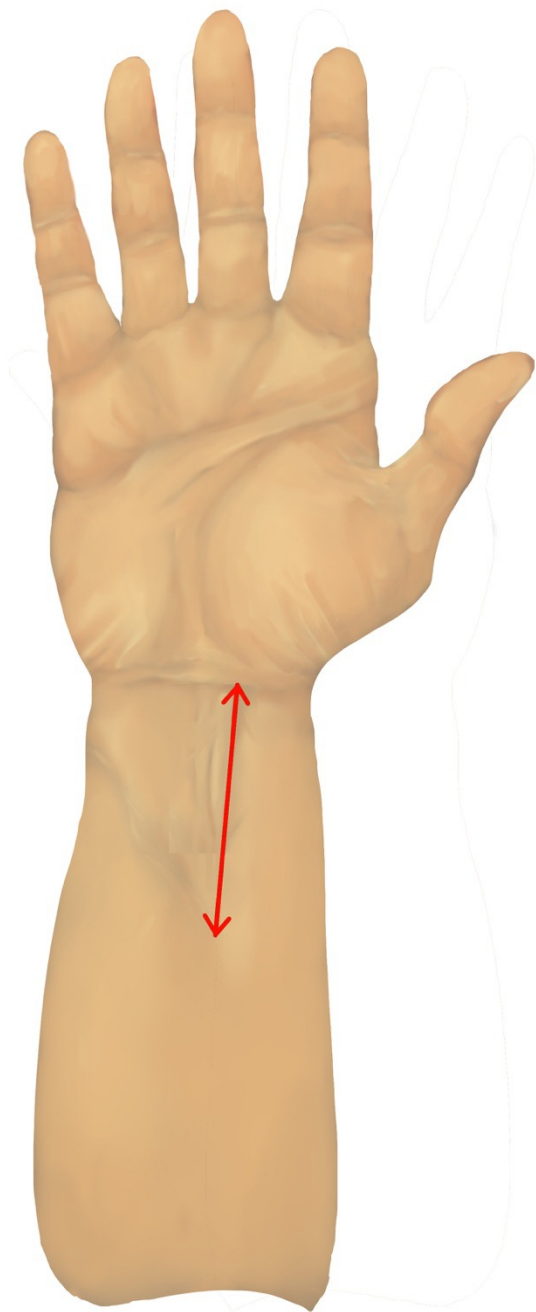
- A. Skin incision outside FCR.
- B. Longitudinal incision outside FCR.
- C. FCR inclined toward the ulna. Deep longitudinal incision of FCR sheath.
- D. PQ incised transversally at the distal edge then released by elevator, conserving radial and ulnar insertions.
- E. Plate introduced under PQ.
- F. Plate positioned upstream of the watershed line and temporarily fixed to the epiphysis by 2 K-wires.
- G. Central distal epiphyseal screws positioned. Temporary K-wires withdrawn and replaced by screws.
- H. Proximal end of plate exposed in maximal flexion to take advantage of skin elasticity; then, introduction of metaphyseal-diaphyseal screws.

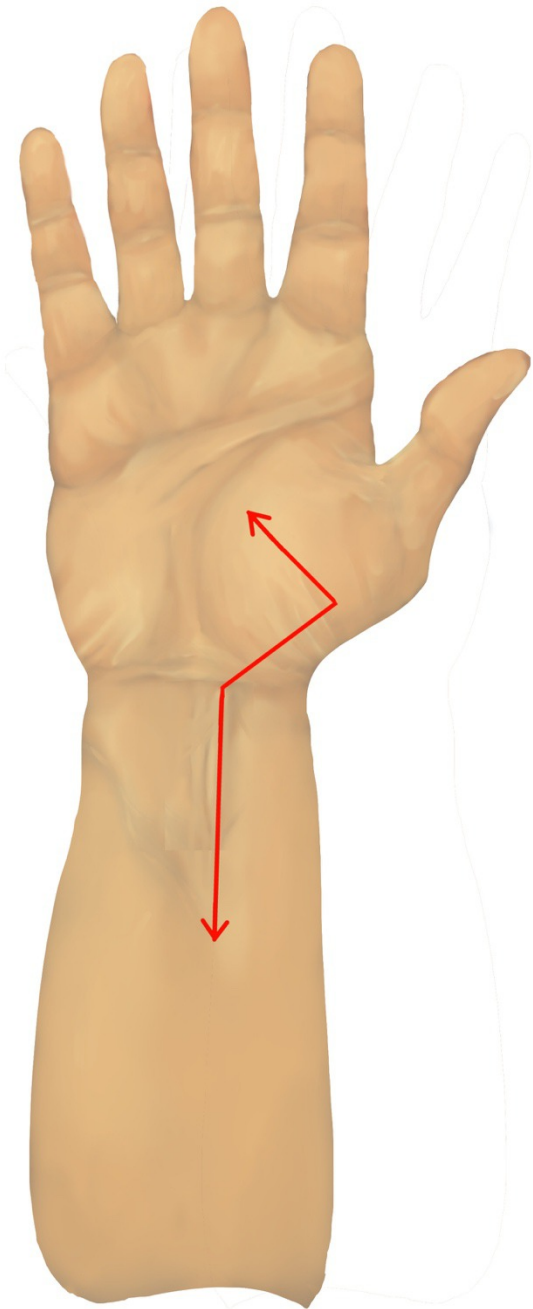
### Figure 3 Results of MIPO in 710 distal radius fractures

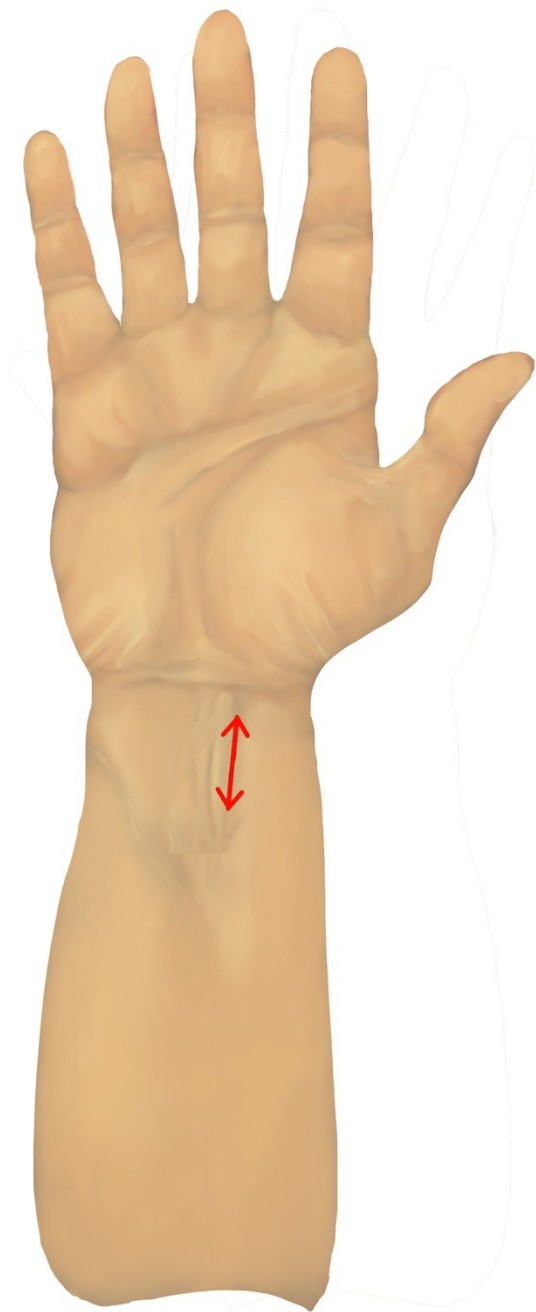
- A. Incision length
- B. Tourniquet time
- C. Pain
- D. QuickDASH
- E. PRWE
- F. Grip strength

- G. Flexion
- H. Extension
- I. Pronation
- J. Supination

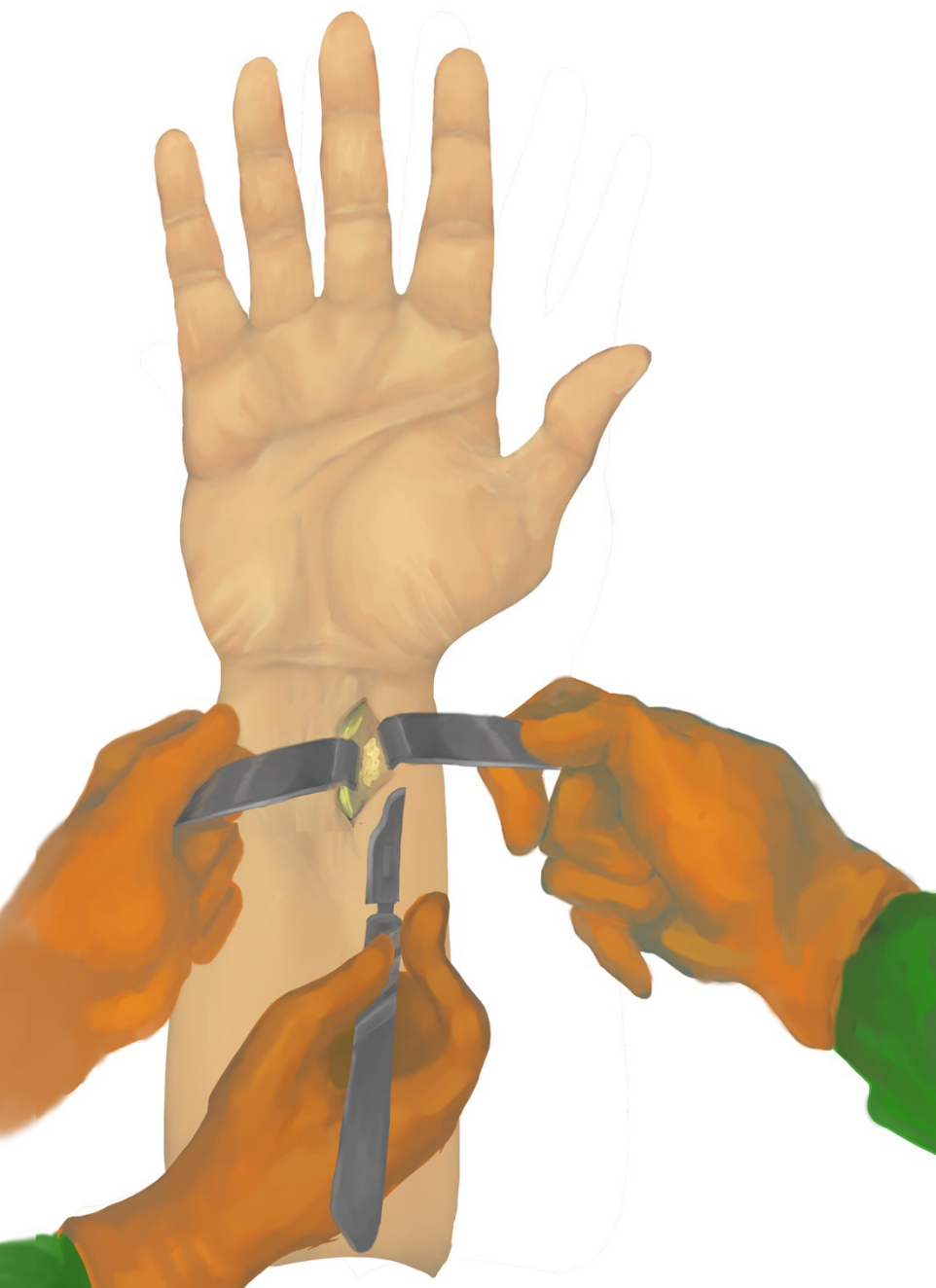

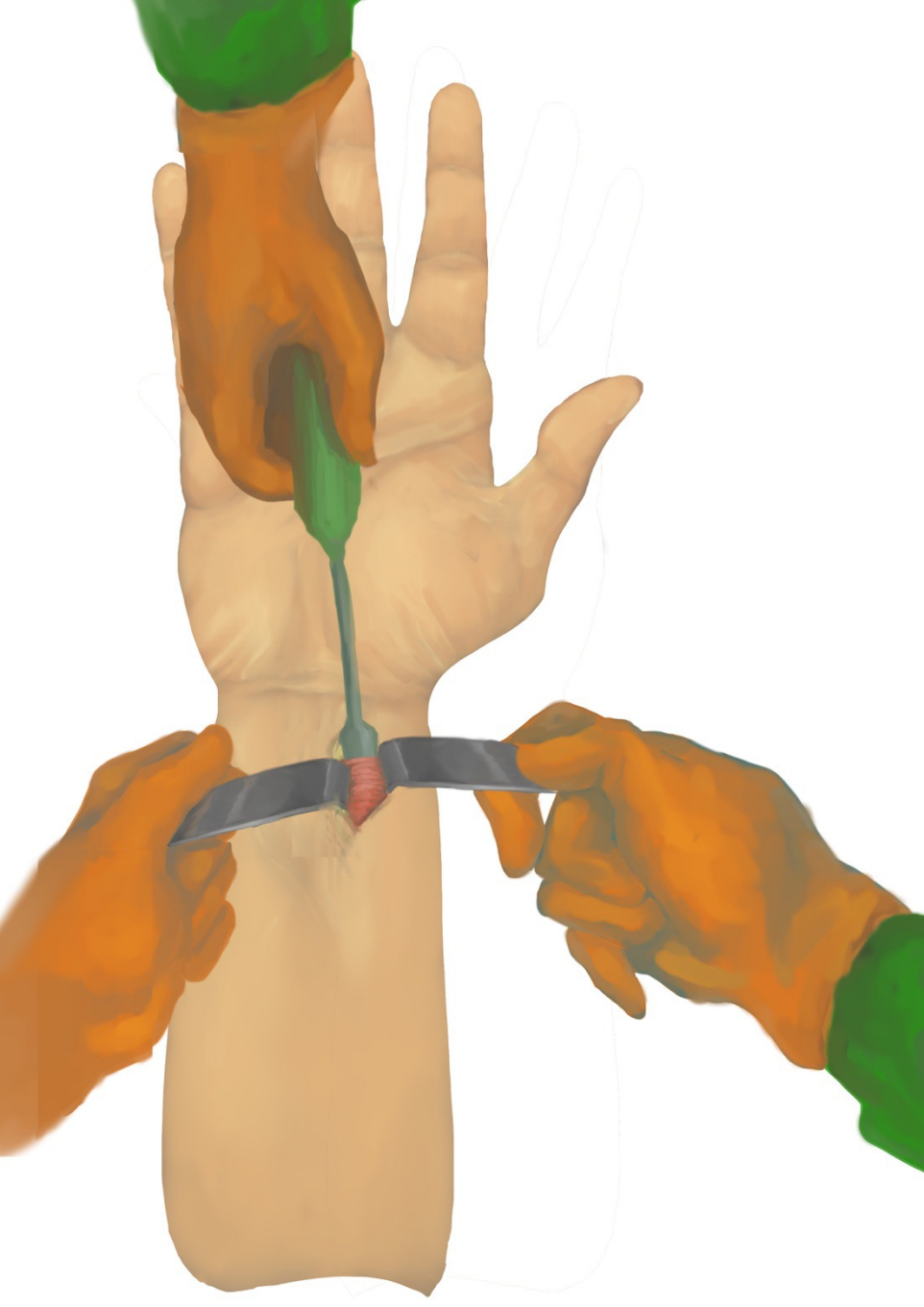


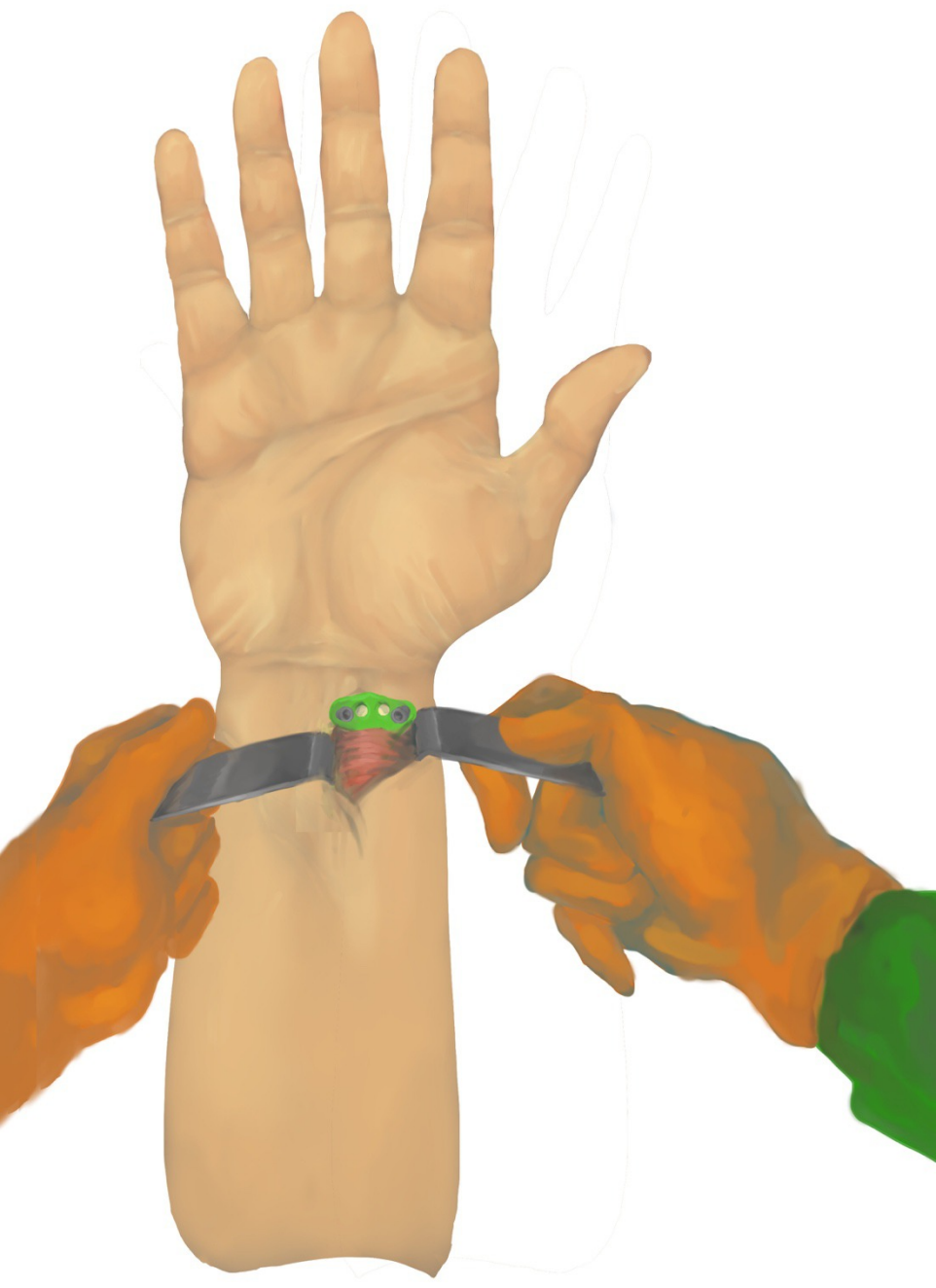


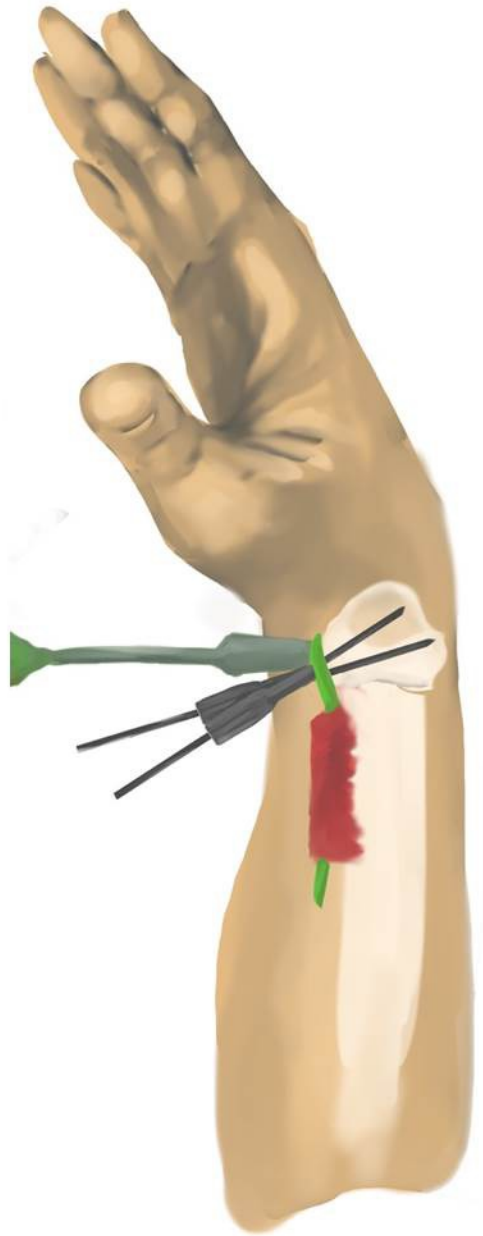
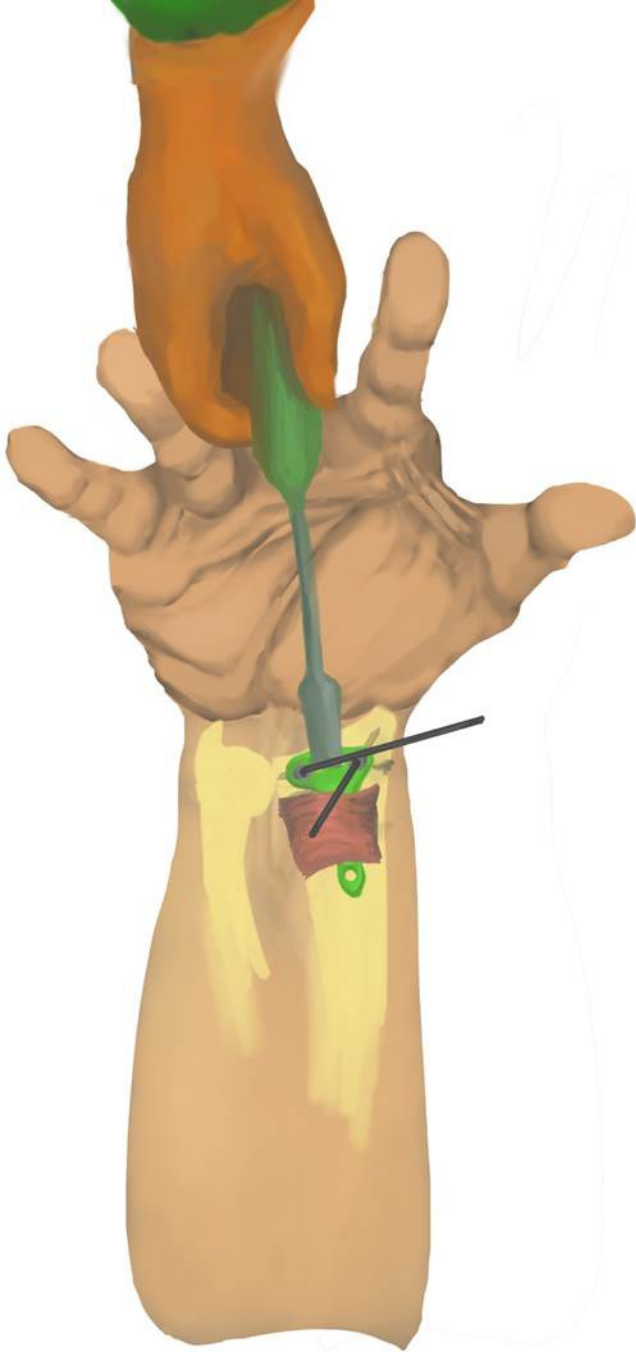





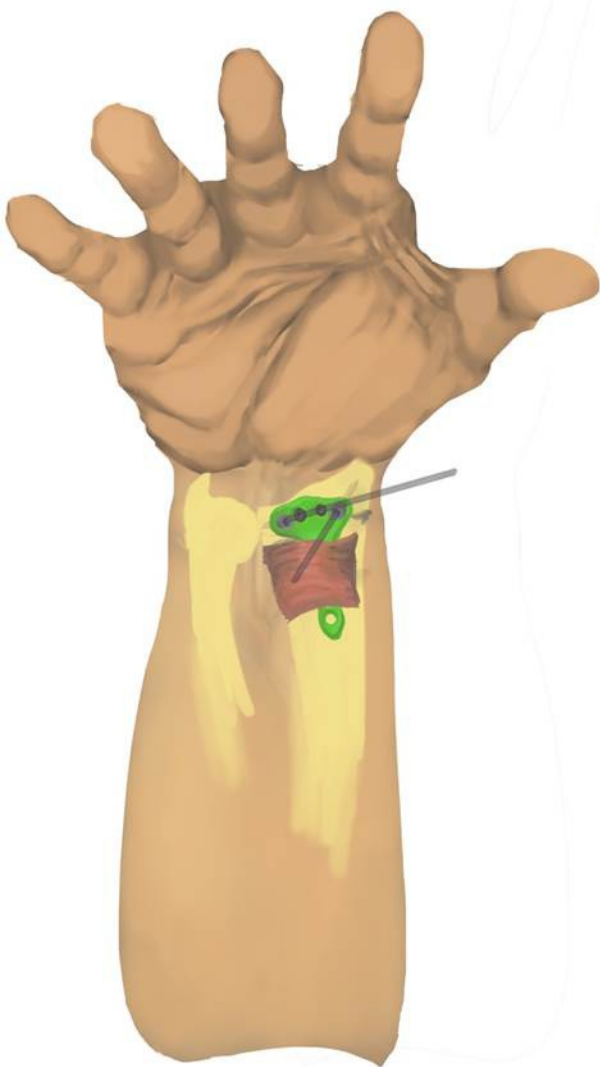


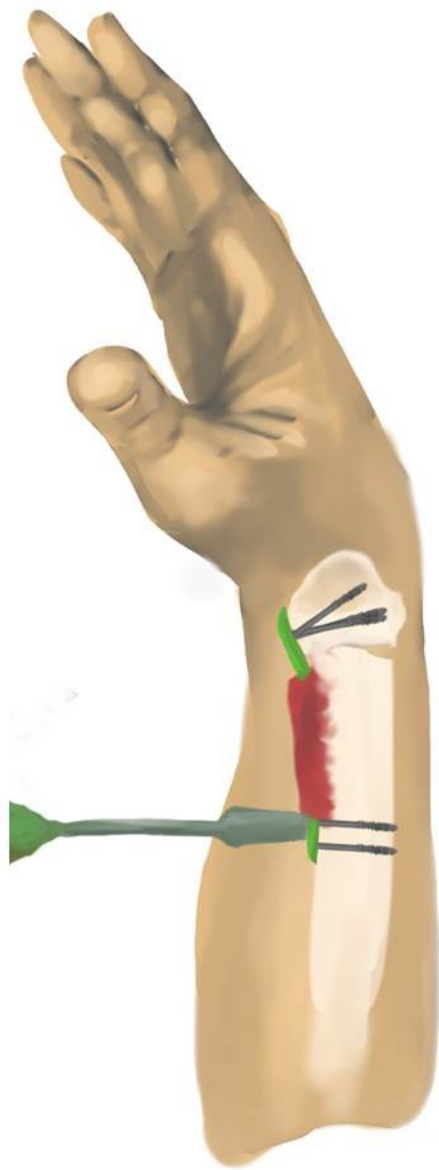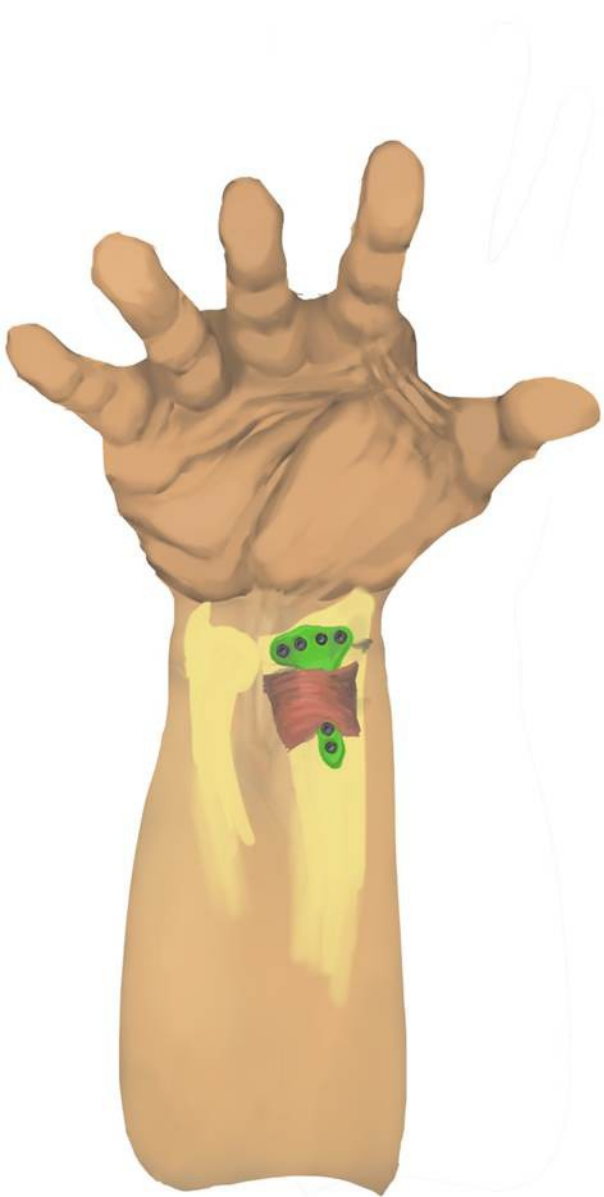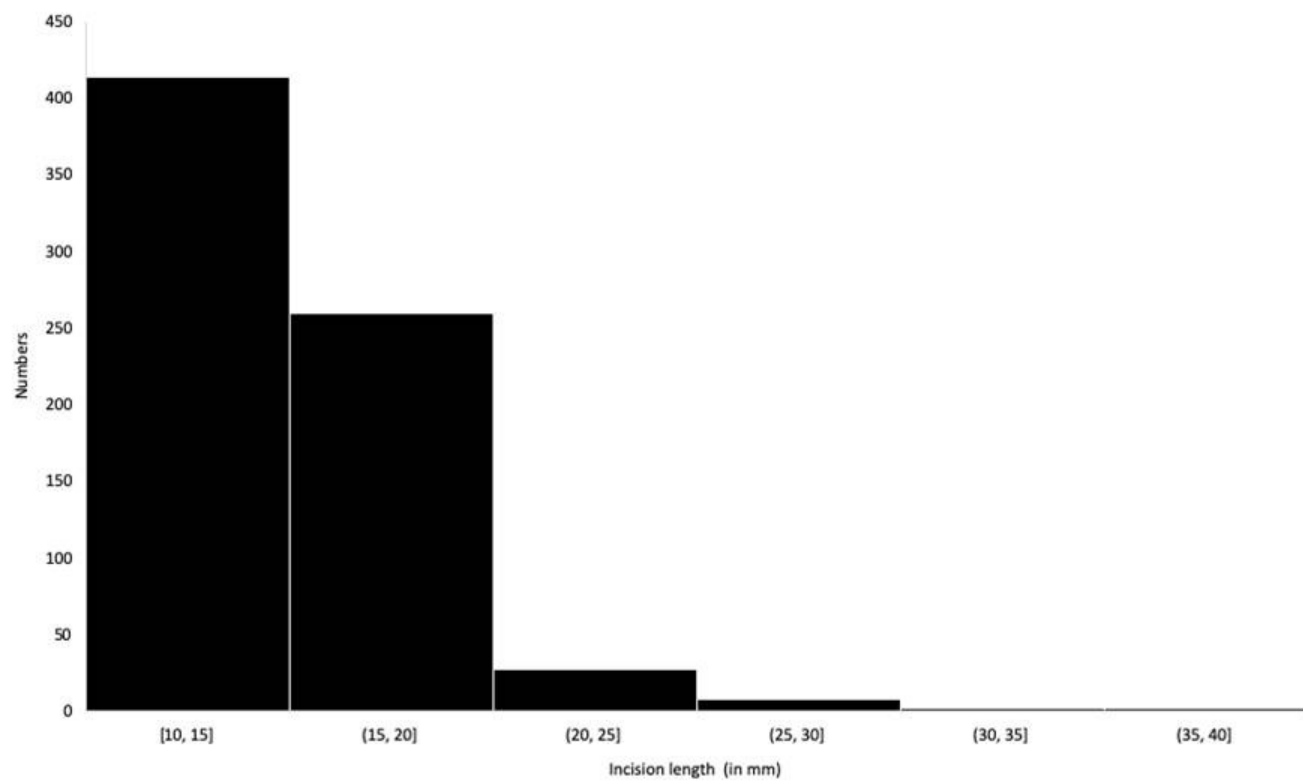


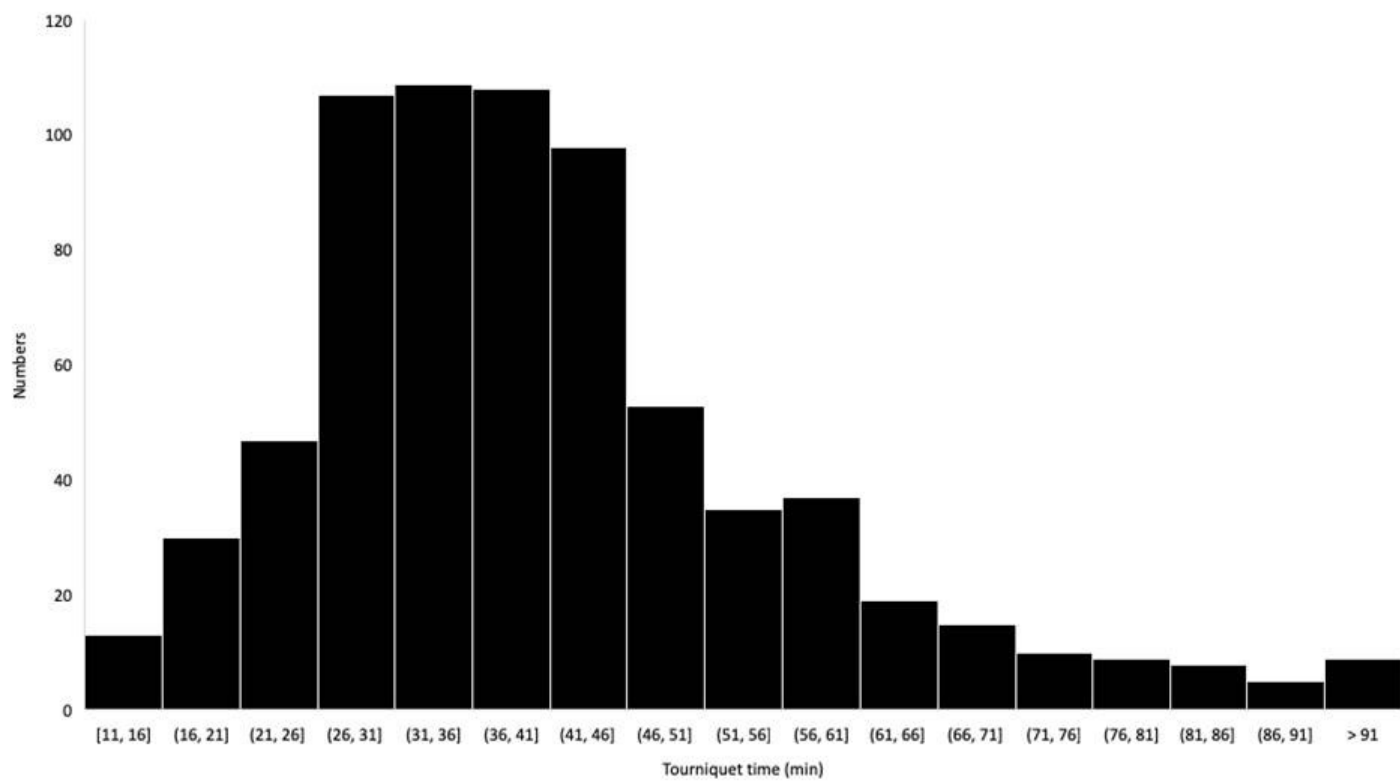


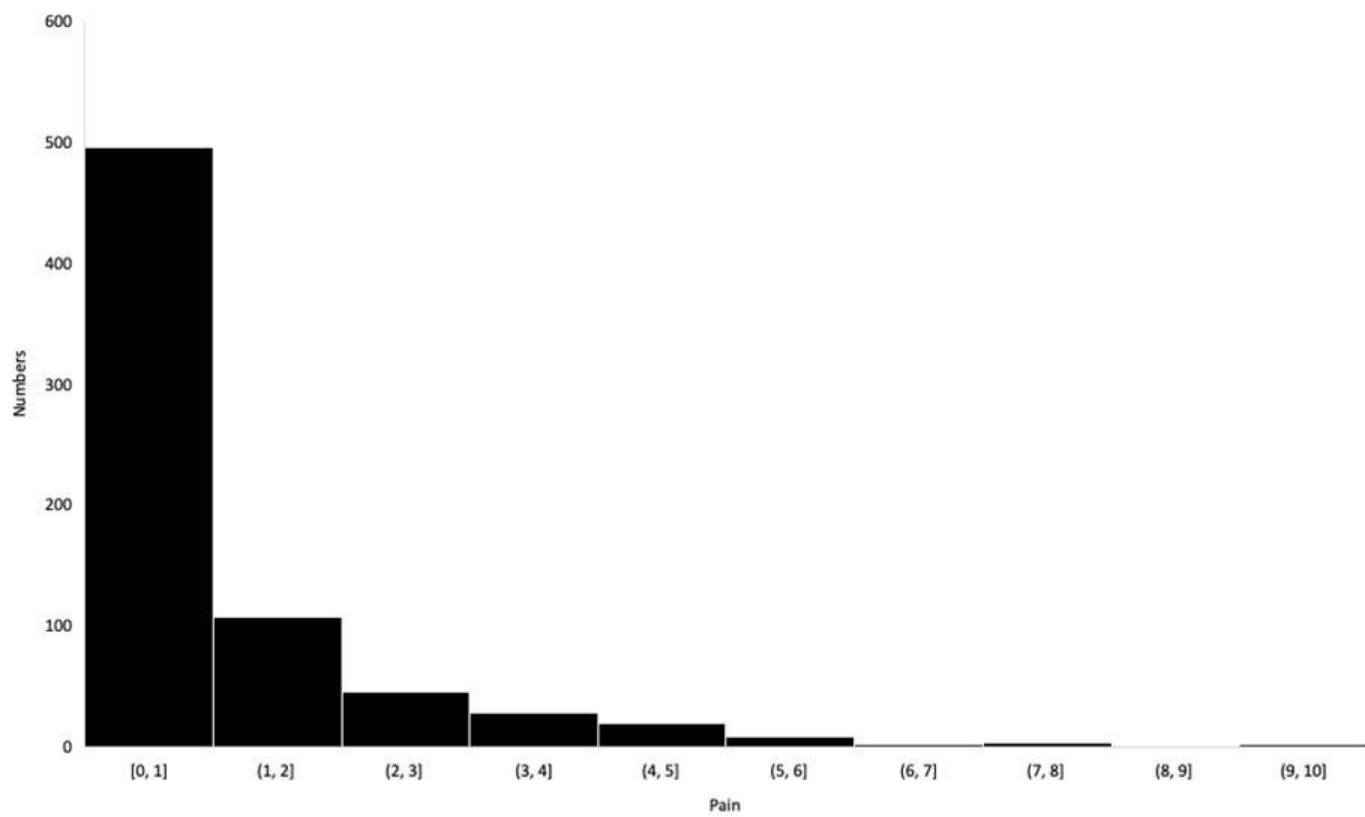


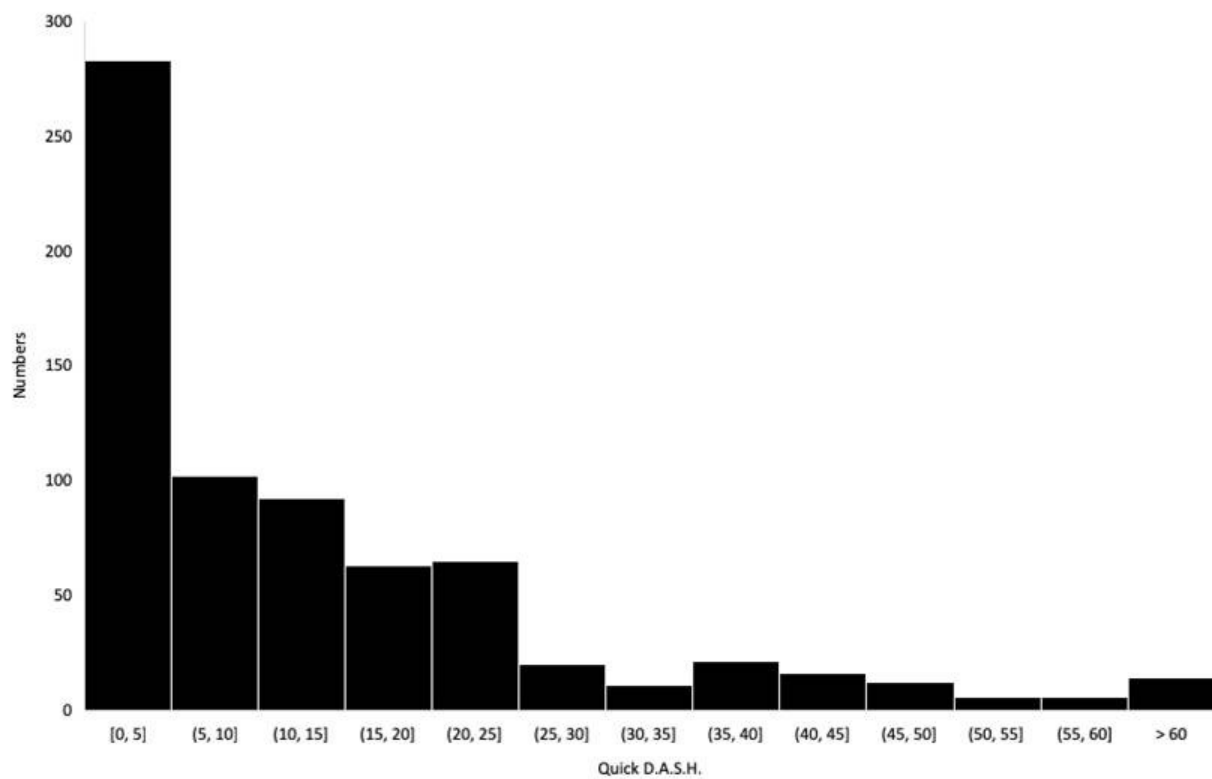


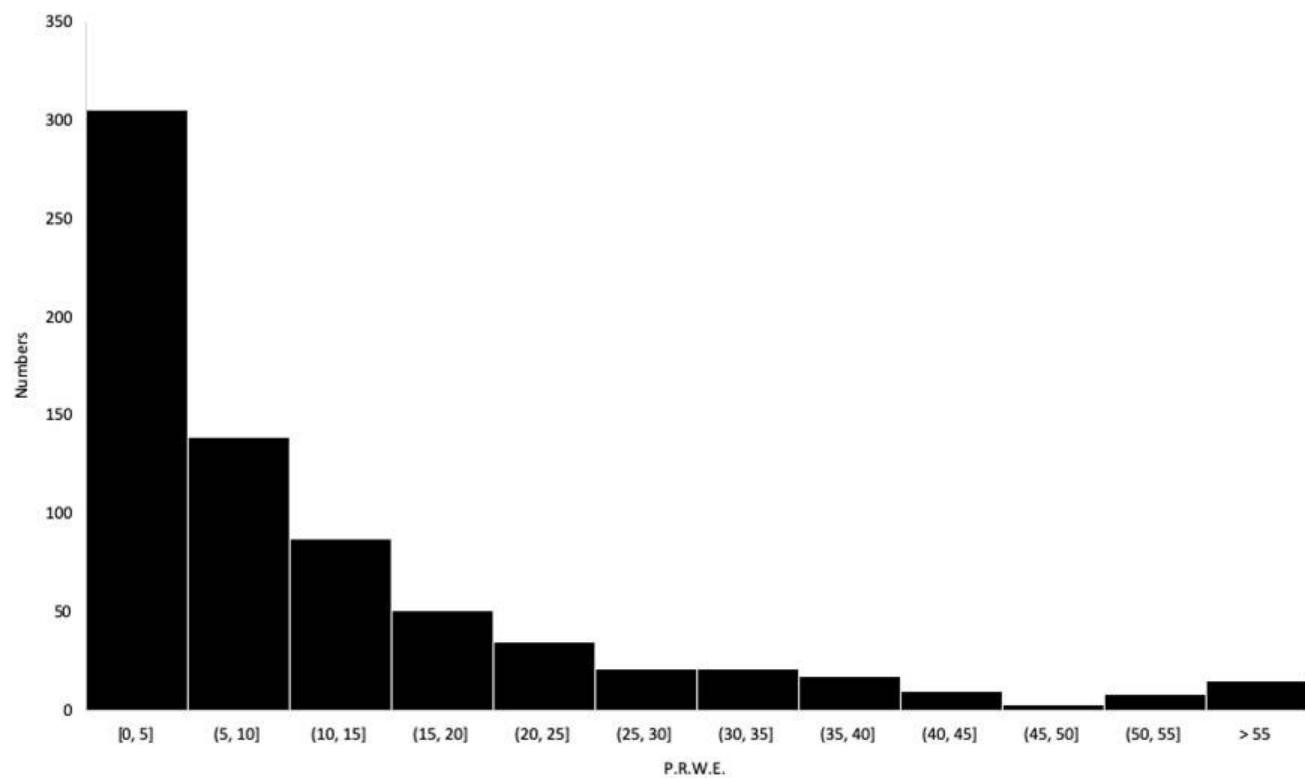


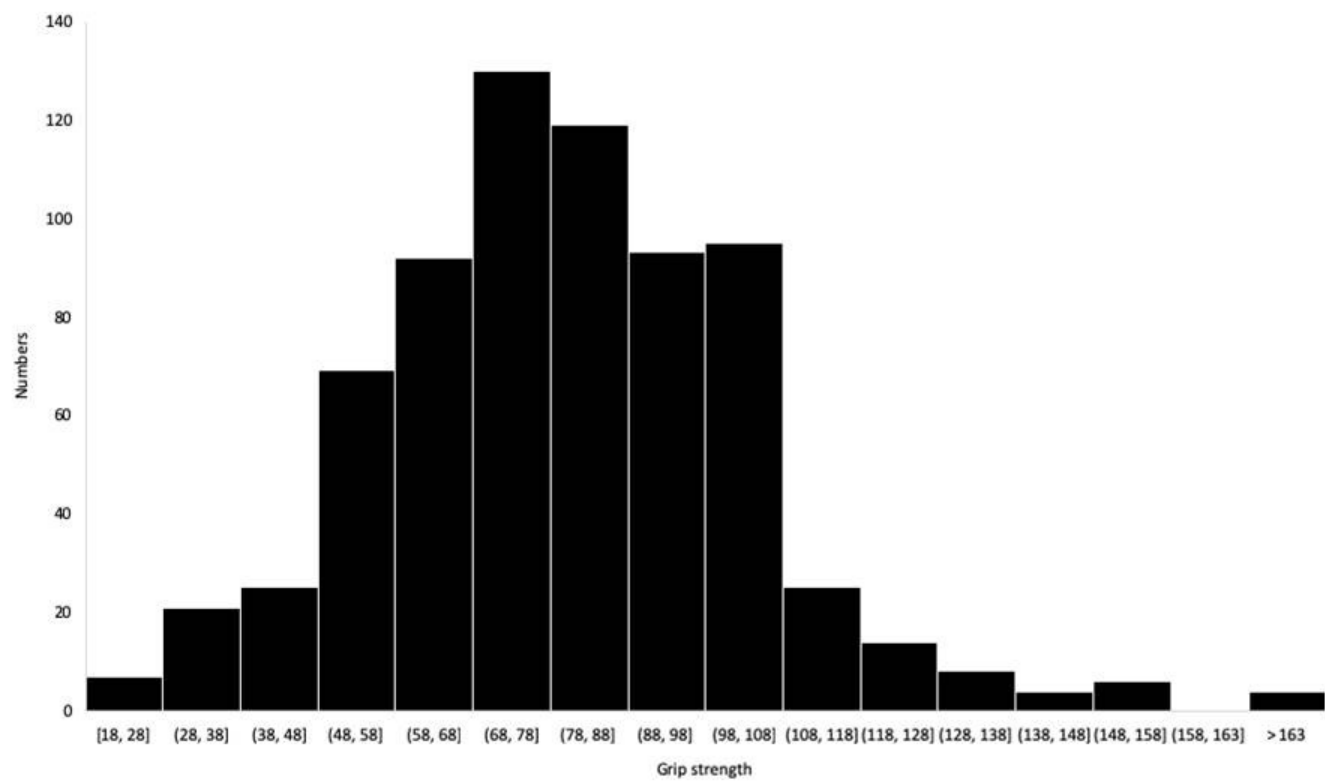




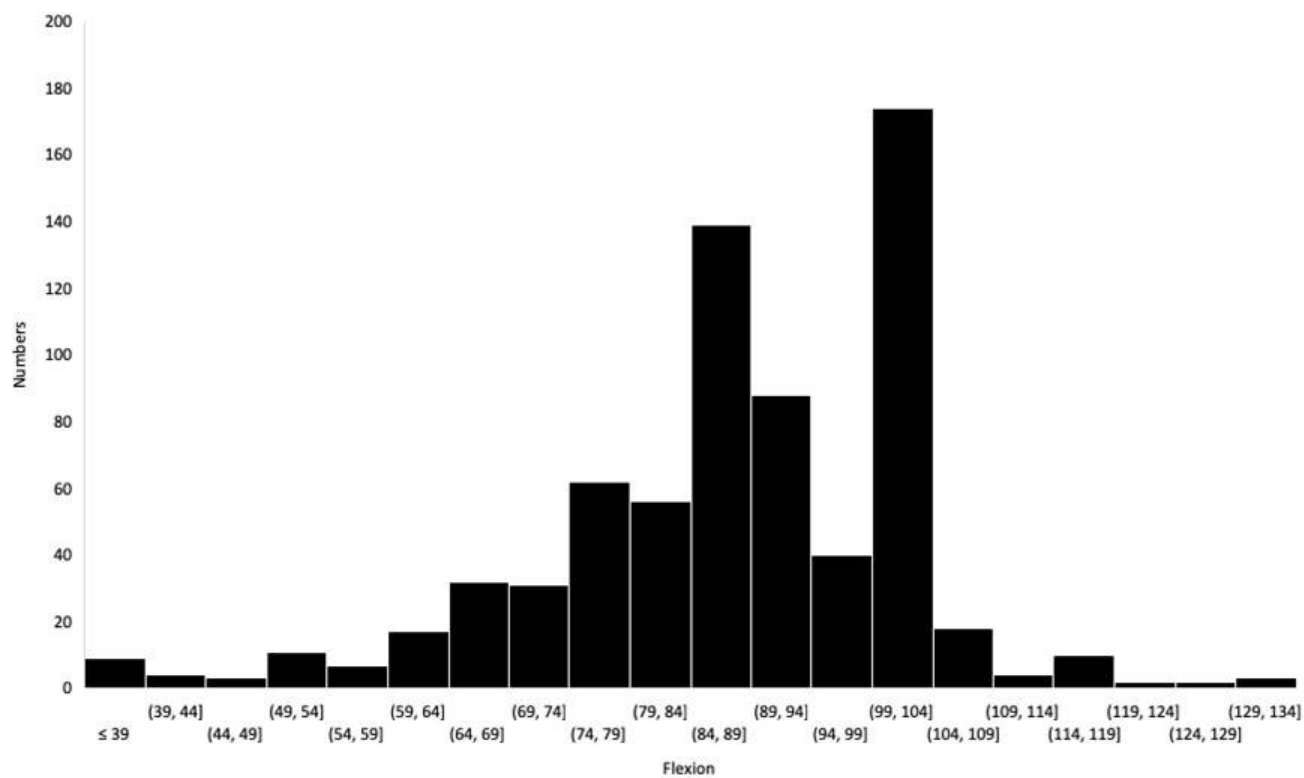


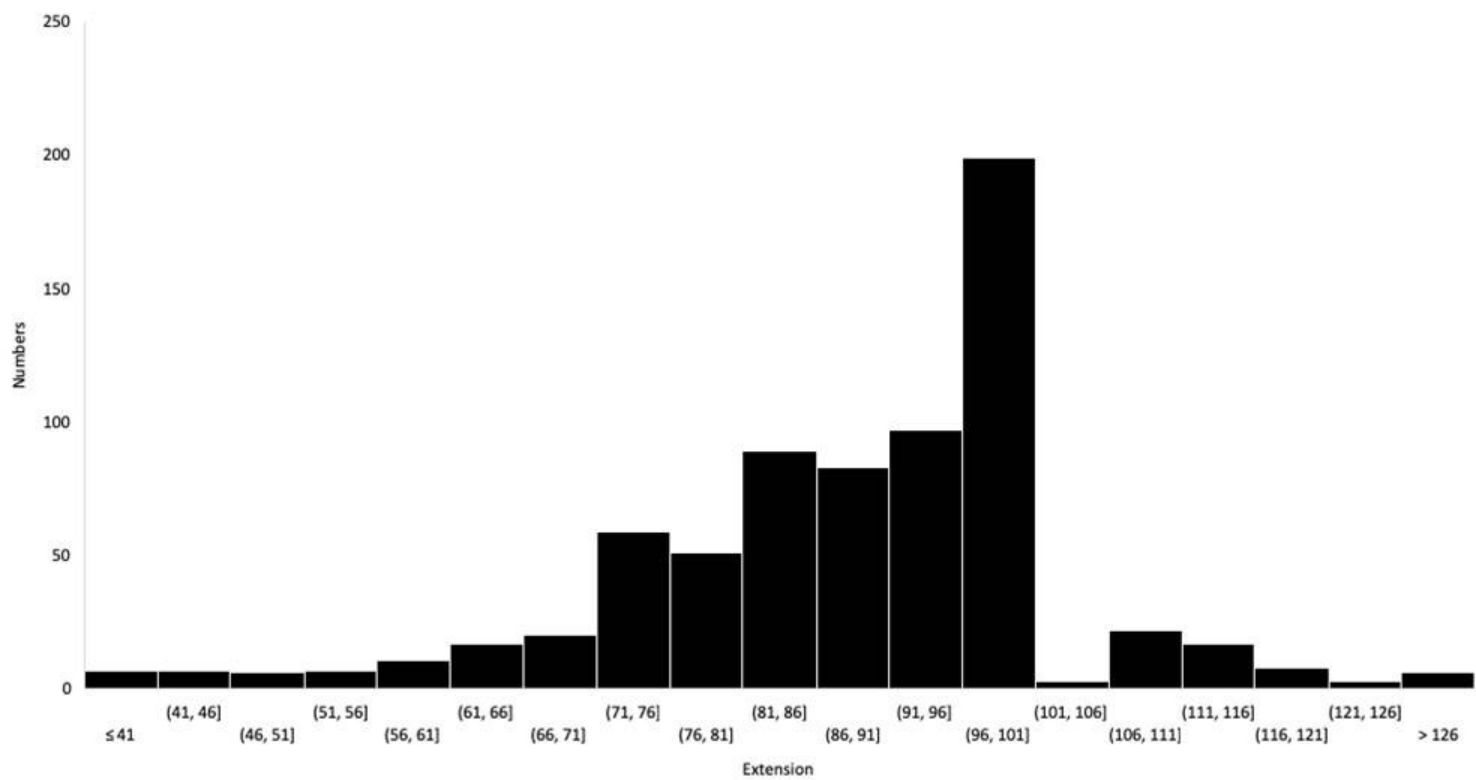


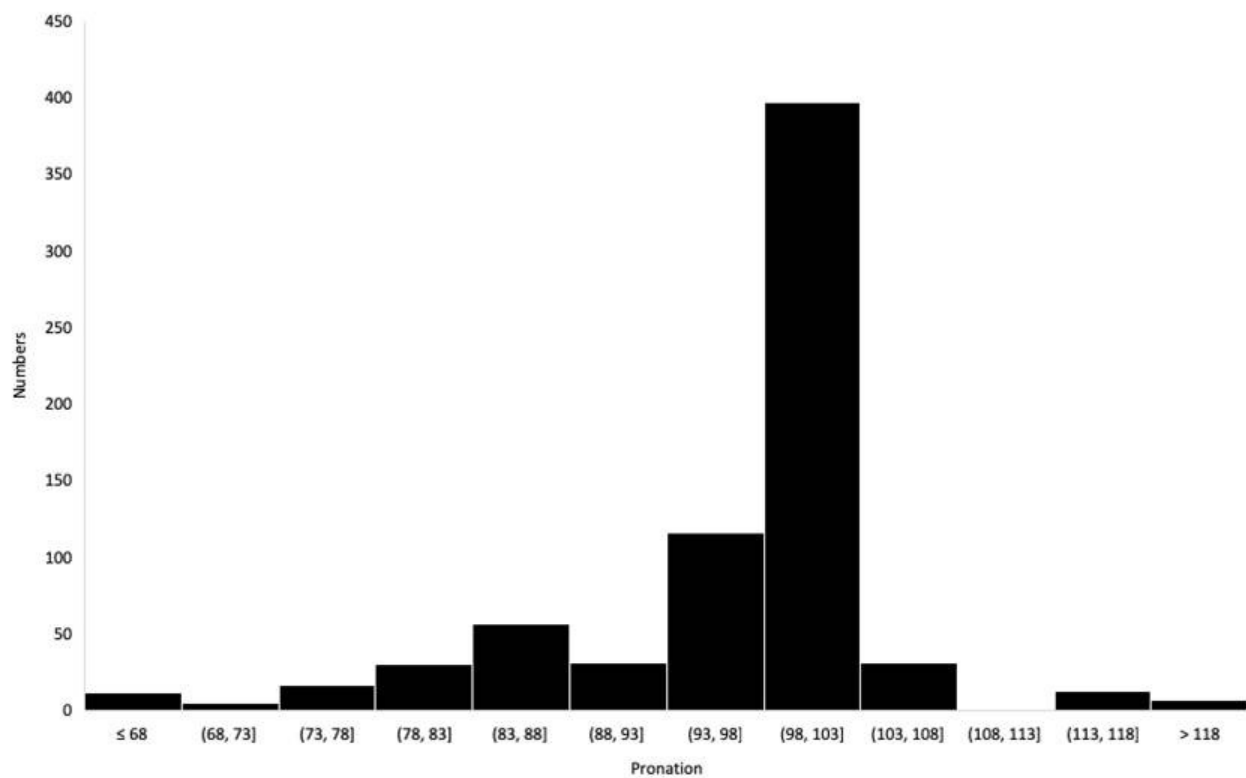


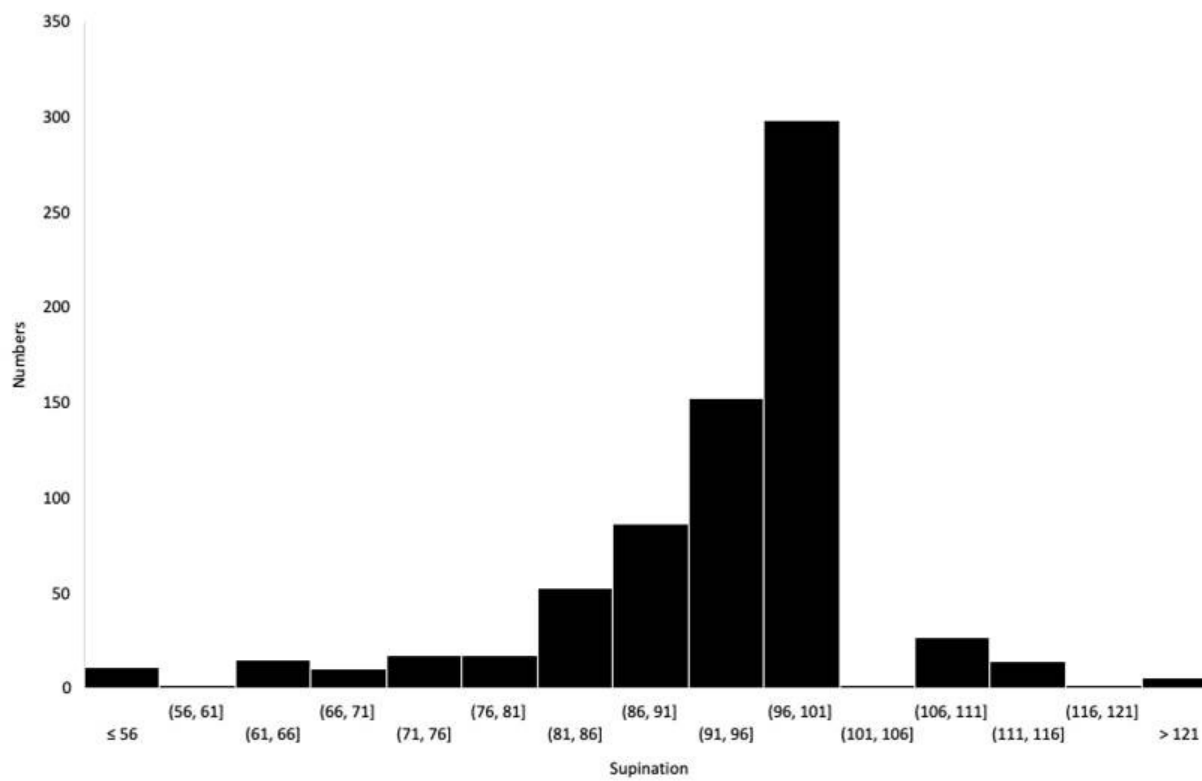












**Table 1. Main case or series reports of anterior plate osteosynthesis and minimally invasive plate osteosynthesis (MIPO) in distal radius fracture**

Authors	Date	Incision				PQ spared (Y/N)	Patients Number (N)	Result		
		Number (N)	Length (mm)	Orientation (T/L)	Arthroscopy (Y/N)			Clinical	Complications	Radiological
Geissler and Fernandes	2000	2	?	L (Pl) L (DI)	N	N	?	?	?	
Imatani et al.	2005	2	50 (20+30)	L (Ds) L (Pr)	N	Y	5	F59° E55° P85° S82° GS 88%	N	Anterior tilt 13° Radial inclination 24° Ulnar variance 0.6mm
Yoshikawa et al.	2008	2	40 (25+15)	T (Ds) L (Pr)	N	Y	13	Cooney score 92.7 F+E=122° P+S=157° GS 86%	N	Anterior tilt 8.6° Radial inclination 22.5° Ulnar variance 0.4mm
Sen et al.	2008	2	50 (20+30)	L (Ds) L (Pr)	N	Y	?	?	?	?
Zenke et al.	2011	2	40 (30+10)	T (Ds) L (Pr)	N	Y	30	F86° E67° P89° S89° GS 94%	Intra-articular screw (1)	Anterior tilt 9.4° Radial inclination 24° Ulnar variance 1.1mm
Abe et al.	2013	1	30 (25-30)	L	Y	Y	153	Mayo score good 89.5% DASH 4.1 F60° E63° P83° S86° GS 88%	Secondary displacement (3) EPL tear (2) CRPS type I (1)	Anterior tilt 5.6° Radial inclination 26.1° Ulnar variance 0.1mm
Zemirline et al.	2014	1	15	L	Y	Y	20	Pain 1.9/10 DASH 24.6 F71° E72° P86° S86° GS 67%	CRPS type I (3)	Anterior tilt 8.8° Radial inclination 20.7° Ulnar variance -1mm
Rey et al.	2014	1	26	L	N	Y	31	DASH 10 GS 80%	Secondary displacement (1)	Anterior tilt 4.8° Ulnar variance 0.3mm
Lebailly et al.	2014	1	15	L	Y	Y	144	DASH 25 F86° E86° P96° S91° GS 67%	CRPS type I (9) Secondary displacement (2) Tenosynovitis (9) Intra-articular screw (2) Distal screw cut-out (1)	Anterior tilt 8.3° Radial inclination 22° Ulnar variance 0.4mm
Wei et al.	2014	2	40 (20+20)	T (Ds) L (Pr)	N	Y	22	?	Thenar eminence anesthesia (1) Delayed skin healing (1) Ulnar-side pain (2) Limited function (2)	?
Chmielnicki and Prokop	2015	2	30 (25+5)	T (Ds) L (Ps)	N	Y	11	F45° E45° P85° S85° GS 96%	?	?
Chen et al.	2015	2	30 (20+10)	T (Ds) L (Ps)	N	Y	21	Mayo wrist score 95.0	N	Anterior tilt 9.86° Radial inclination 22.43° Ulnar variance 0.29mm
Naito et al.	2016	1	10	L	N	Y	18	F67° F67° P88° S88° DASH 0.7 Mayo wrist score 8.5	CRPS type I (1)	Complete union
Wei et al.	2016	2	40 (20+20)	T (Ds) L (Ps)	N	N	9	DASH 5.8 F76° E77° P79° S81° GS 89%	Delayed skin healing (1)	Anterior tilt 10.7° Radial inclination 18.2° Ulnar variance 2.3mm

T transverse. L longitudinal. PQ pronator quadratus. Pl palmaire. DI dorsal. Ds distal. Pr proximal. F flexion. E extension. S supination. P pronation. GS grip strength (% contralateral value). Y yes. N no. EPL extensor pollicis longus. FPL flexor pollicis longus. CRPS complex regional pain syndrome