



**HAL**  
open science

## Gunshot suicides caused by cane-gun and alarm garden gun cannon: Two cases report.”

Lh Rossi, O. Dubourg, S. Malbranque, N. Jousset

### ► To cite this version:

Lh Rossi, O. Dubourg, S. Malbranque, N. Jousset. Gunshot suicides caused by cane-gun and alarm garden gun cannon: Two cases report.”. *Journal of Forensic and Legal Medicine*, 2021, 77, pp.102090 -. 10.1016/j.jflm.2020.102090 . hal-03492900

**HAL Id: hal-03492900**

**<https://hal.science/hal-03492900v1>**

Submitted on 15 Dec 2022

**HAL** is a multi-disciplinary open access archive for the deposit and dissemination of scientific research documents, whether they are published or not. The documents may come from teaching and research institutions in France or abroad, or from public or private research centers.

L'archive ouverte pluridisciplinaire **HAL**, est destinée au dépôt et à la diffusion de documents scientifiques de niveau recherche, publiés ou non, émanant des établissements d'enseignement et de recherche français ou étrangers, des laboratoires publics ou privés.



Distributed under a Creative Commons Attribution - NonCommercial 4.0 International License

**GUNSHOT SUICIDES CAUSED BY CANE-GUN AND ALARM GARDEN GUN CANNON: TWO CASES  
REPORT.”**

**ROSSI LH<sup>1</sup>, DUBOURG O<sup>1</sup>, MALBRANQUE S<sup>1</sup>, JOUSSET N<sup>1,2</sup>**

- 1- Service de Médecine Légale, CHU Angers, Angers, France
- 2- Université d'Angers

**Corresponding author**

Lea-Hélène ROSSI

Service de Médecine Légale

CHU Angers

4 rue Larrey

49100 Angers

LeaHelena.Rossi@chu-angers.fr

Running title: gunshot suicides caused by atypical firearms

Keywords: forensic sciences - forensic pathology - suicide – atypical firearms – gunshot –  
cane-gun – alarm garden gun cannon

## **Introduction**

Suicide is a frequent type of unnatural death seen frequently by forensic scientists. There were, on average, 10,700 deaths per year accounted for in France, ranking it the 12th highest rate of suicide in the European Union [1]. Among them, gunshot wounds are one of the most frequent causes of death [2-4]. The most common method of suicide is hanging (54%), followed by firearm injuries (15%) [5]. In each case, one of the forensic pathologist's main missions is to attempt to distinguish death by suicide from other forms of violent death such as accidents or homicides. In gunshot suicide cases, the majority of cases show injuries related to a touching shot or a shooting from a very short distance (print on the barrel of the weapon, for example), with the weapon still present near the victim. These lesions are generally located on the upper part of the body, generally opposite the right temple area [6-10]. However, the use of unusual firearms might create a complicated and unsettling situation for the forensic pathologist who does not often come across antique, concealed, or handmade firearms. Unusual or atypical firearm injuries must be able to be recognized as such by the forensic medical experts. The present paper shows two uncommon suicides by "unusual" guns. The first case presents the use of a cane-gun, a walking stick which conceals a firearm, that was used by a 57-year-old man. The second case involves the use of an alarm garden gun cannon, which is a small Cannon, which fires blanks to scare away garden animals. It was remodeled by an 86-year old man. This article is based on reports of forensic autopsies, and therefore do not require the consent of the families of the deceased.

## **Case reports and results**

### ***Case 1***

An unidentified man was found dead by a municipal police officer in a park. After the initial police investigation, the forensic pathologist was called in to make the preliminary

observations and to preserve evidence. The body was found on its back, next to a tree surrounded by in the middle of high weeds (Fig.1). The practitioner noted many signs of advanced decomposition. The body had outer garments open in the front without any suspicious lesions and showed an oval-shaped wound on the left side of the chest surrounded by a black area. A metal element initially described as a “rod” was discovered close to the body (Figs.2-3-4). The police officers incidentally reported that the components of the metal « rod » suggested that it was a cane-gun type firearm. They also found a struck and two unused cartridges near the body. Suicide notes were found at man’s home.

First, a post mortem computed tomography was performed and highlighted a wound between the 5th and the 6th left ribs, a fracture of the mean part of the 8th left rib and some fractures of the posterior part of the 9th, 10th and 11th left ribs. In addition, some metal fragments were found. They were assumed to be pellets, due to the fact that the body had been found next to some cartridges. These fragments were in a state of degradation and were found only in the subcutaneous area of the left posterior chest. Secondly, an autopsy was conducted and confirmed the scannographical observations. The canal wound was 115 cm from the left heel and 10 cm from the midline on the left. The anterior left thoracic entrance wound measured 2 x 1.5 cm and was surrounded by a black area measuring 11 x 6 cm (Figs.5-6). No exit wound was found. No major organs or vessels wounds were found. However, the gunshot wound channel was likely to have involved a hemorrhagic syndrome leading to a fatal outcome apart from any rapid surgical management. However, it is not possible to establish a duration of agony given the state of degradation of the body, the lack of knowledge of the medicine taken (anticoagulant in particular) and the absence of any major vascular axis lesions. The direction of the gunshot wound channel was the following: from front-to-back, slightly inwards (from left to right) and downwards. Toxicological and histological analyses were not required by the authorities. The identification of the body, a 57-year-old man, was secondarily confirmed by

DNA analysis. To conclude, the death was a result of a ballistic thoracic and abdominal trauma. Based on the circumstances surrounding the death, the police investigation and the findings at the autopsy, the case was classified as a gunshot suicide caused by a cane-gun.

### *Case 2*

An 86-year-old man, a retired mechanic, was discovered dead by his wife in the basement of their home. He was lying on his back, in a pool of blood (Fig.7). The initial findings by the forensic pathologist objectified an oval wound at the base of the left thorax from which some viscera emerged. Next to the corpse, there was a firearm type alarm garden gun cannon fixed to a vice, itself fixed to a workbench (Fig.8). This weapon had a fired hunting cartridge into the cannon (12/67 caliber) (Fig.9). The victim's body was in the gunshot cannon's path. He had been suffering from terminal lung cancer and had started treated for depression three weeks earlier. On the previous day, he had met with a notary to complete his will.

The autopsy was conducted and confirmed the existence of a left anterior thoracic basilar lesion set, including at the upper pole : a reddish arciform ecchymotic impression zone, 22 mm internal diameter and 25 mm external diameter, a recent, hemorrhagic, oval, puncture wound, with irregular banks (of the "rat bite" type), scalloped, without peri-lesional tattoo, of 06, 5 cm wide by 04 cm high, located 120 cm from the plane of the heels, 15 cm from the anterior midline and 08 cm from the right nipple, a cleavage line, 02 cm long, in the inferior-internal quadrant of this wound, a pinkish ecchymosis, peri-lesional, 14 cm wide by 12 cm high (Fig.10). The internal examination revealed some very serious intracorporeal lesions. We highlighted a left thoracic traumatism including many costal fractures, a haemothorax and a haemopericardium linked to an irregular fracture of the heart apex. Moreover, we noticed an abdominal traumatism showing a major haemoperitoneum with a dilaceration of the stomach

and the spleen, some irregular edge breaks of the abdominal aorta and many lumbar fractures. No exit wound was noted. The direction of the wound channel was the following: from front-to-back, from left to right and horizontally. Toxicological findings showed no trace of legal or illegal drugs. Histological analyses were not required by the authorities. Based on these findings and the police investigations and the findings at the autopsy, the case was classified as a gunshot suicide caused by an alarm garden gun cannon.

## **Discussion**

In the US, concealed carry is the ability for an American citizen to own a firearm by carrying it discreetly on himself or having it nearby. However, there does not seem to be any distinction regarding “camouflaged” firearm possession such as cane-gun or alarm garden gun cannon [11,12]. In France and throughout Europe, the law authorizes people to own firearms that date back to before 1900 [13,14]. Despite their old age, the best-preserved weapons are still usable and present a real danger for anyone who is a novice at using firearms. On some specialized websites, it is currently possible to legally buy old firearms. Given this information, it is clear that access to conventional firearms is difficult (outside the United States). Because it is difficult to access firearms, suicidal people sometimes transform antique weapons, or other objects capable of firing a charge, into a firearm that is capable of causing their death.

Here is a little background about cane-guns. wealthy men in the 19th century used walking stick as a fashion accessory. With advances in metallurgy, these canes have become ingenious hiding places to conceal weapons. As far as alarm garden gun cannons are concerned, originally in the 19th and 20th centuries, this gun was used to scare animals or burglars found in private properties by firing blank bullets. These weapons are classified, in French legislation [13], in the category of “alarm guns” or “signalization or starter”. It is completely

legal to have them and to use them, but only if the weapon is loaded with blanks. According to French law, if the firearm is charged with a real cartridge [15,16] and hurts or kills someone, the owner and the one who modified it are guilty, even if the shooter was using it in self-defense.

Knowledge of the mechanism can provide useful clues to the forensic pathologist and guide his analysis (Fig.10), especially because he might, indeed face some situations in which this kind of firearm has been used. Beyond the historical point of view, these firearms are still in use and may continue to cause injury. Blank shot pistols, such as pistols used to kill moles are easy to get and can be adjusted to fire real bullets [15]. The two firearms have very similar bolt shot devices and typically have a metal case in which a single-blow bolt is located. There is no firing cell. We were unable to analyze powder deposits [17] because for the first case, the body was too damaged and for the second case, analysis was not relevant because the pellets were too widely dispersed.

The two cases presented above support the idea that some suicidal people might transform may divert historic weapons or mechanisms firing various charges to make them into real firearms. Nevertheless, it is up to the forensic pathologist to note certain subtleties.

The two most important differences between both of these guns are the design and the security. Nowadays, a lot of cane-guns are broken or partially damaged. They can be stuck may even explode because they are too old to be functional. This might explain the appearance of the injury because, as Hagemeyer and al. reported [17], even if the findings had been severely restricted due to the decomposition of the body in our first case. Alarm garden gun cannon are not intended to shoot real cartridges. Using this kind of object to shoot something or someone could fail or cause an explosion because the cannon is not designed to support real explosive charges. The mechanism and the use are similar to that which is found



in common guns, but the hammer cocking arrangement is a break-open system (Fig.11). Its trigger is linked to a string of variable length and the shot is fired when an unsuspecting person walks on it. The model in this case has an internal percussion mechanism. The hammer, equipped with a ring, protrudes from the rear of the barrel. To cock this firearm, the hammer must be pulled back and the trigger pressed down to block the hammer. The shot is fired when the trigger is pulled up. The canon is fixed on a stationary plane. As far as the ammunition is concerned, most of the time classical cartridges are used (12/67 caliber). These cartridges are similar to conventional firearm cartridges except that they are only filled with explosive charge (capsule), without a bullet or pellets inside (blank cartridges).

In addition to the technical point of view, it seems to be important for the forensic pathologist to keep in mind the existence of such “camouflaged” firearms and their operation in order to guide the forensic investigations towards such or such manner of death from the at-the-scene examination. When the forensic pathologist is investigating a gunshot injury, it is important to notice some of the parameters [17-19]. Injury dimensions, particularly when the projectile is not found, are among the things to be measured. Wiping collar and barrel burn make it possible to estimate the gun shot distance. However, with historical, antique, damaged or “hand-camouflaging” guns, these factors can be skewed. Its cannon can be corrupted, and the gun shot can be less powerful. A suicide can be camouflaged as a homicide in this way, and it can mislead investigators. The forensic pathologists should keep in mind that an at-the-scene-examination must be analyzed by starting with an enlarged perimeter and then by focusing on the body. Gradually, they reduce the area to complete by the body examination. As described above, in the first case, with the cane-gun), the forensic pathologist found a metal rod, had it set aside, and detected that it was in fact a concealed firearm. Without this piece, it would not have been possible to explain the bullet wound and to classify the suicide. Thus, the

importance of doing an at-the-scene examination [21], because a body examination at the Forensic Institute could not have provided this information. In the second case, the firearm is not concealed by its design but by disorder at the death scene. The forensic pathologist must keep in mind that a messy crime scene can often mislead the investigator. However, the alarm garden gun cannon was a modified version of the gun. The owner had replaced the blank cartridge with a real gun cartridge. He had hijacked the process so that the string was pulled by himself. The forensic pathologist work is complementary or even as important as that of the investigators. As we can see in this example, in order to understand how the weapon could kill, it is necessary to define many measures such as the distance between the string and the hand to check the consistency with the body position. Again, this would not be possible to do during a body examination at the Forensic Institute.

## **Conclusion**

The interest of these two original case reports is to highlight the firearm's appearance or misappropriation. The forensic pathologist needs to keep in mind that the death might be cause by an antique gun, which might be seen as a commonplace object. Or it might be cause by a rare and obsolete little cannon used to frighten animals or intruders [20], such as an alarm garden gun cannon. These cases illustrate the added value of a thorough investigation of the scene. Detailed documentation of the death scene is necessary to support the autopsy's results and to ascertain the cause and the circumstances of death. This article encourages the medical examiner to consider the entire scene of a firearm death, especially if it is not typical.

## **References**

- [1] Centre d'épidémiologie sur les causes médicales de décès. <http://www.cepidevesinetinserm.fr/> (accessed June, 2020).
- [2] Balci, Y., Canogullari, G., Ulupinar, E., 2007. Characterization of the gunshot suicides. *J Forensic Leg Med* 14, 203–208. <https://doi.org/10.1016/j.jcfm.2006.06.025>

- [3] Byard, R.W., Austin, A., 2011. The role of forensic pathology in suicide. *Forensic Sci Med Pathol* 7, 1–2. <https://doi.org/10.1007/s12024-010-9186-5>
- [4] Austin, A.E., Guddat, S.S., Tsokos, M., Gilbert, J.D., Byard, R.W., 2013. Multiple injuries in suicide simulating homicide: report of three cases. *J Forensic Leg Med* 20, 601–604. <https://doi.org/10.1016/j.jflm.2013.02.005>
- [5] DREES. Suicide: connaître pour prévenir. Dimensions nationales, locales et associatives [Suicide : know to prevent. Dimensions national, local and associative], 2016 ; [http://drees.solidarites-sante.gouv.fr/IMG/pdf/ons2016\\_mel\\_220216.pdf](http://drees.solidarites-sante.gouv.fr/IMG/pdf/ons2016_mel_220216.pdf) (accessed March 28, 2018).
- [6] Stone, I.C., 1992. Characteristics of firearms and gunshot wounds as markers of suicide. *Am J Forensic Med Pathol* 13, 275–280. <https://doi.org/10.1097/00000433-199212000-00001>
- [7] Karlsson, T., 1999. Multivariate analysis ('forensiometrics')--a new tool in forensic medicine. Differentiation between firearm-related homicides and suicides. *Forensic Sci. Int.* 101, 131–140. [https://doi.org/10.1016/s0379-0738\(99\)00017-1](https://doi.org/10.1016/s0379-0738(99)00017-1)
- [8] Karger, B., Billeb, E., Koops, E., Brinkmann, B., 2002. Autopsy features relevant for discrimination between suicidal and homicidal gunshot injuries. *Int. J. Legal Med.* 116, 273–278. <https://doi.org/10.1007/s00414-002-0325-8>
- [9] Solarino, B., Nicoletti, E.M., Di Vella, G., 2007. Fatal firearm wounds: a retrospective study in Bari (Italy) between 1988 and 2003. *Forensic Sci. Int.* 168, 95–101. <https://doi.org/10.1016/j.forsciint.2007.01.023>
- [10] Verzeletti, A., Astorri, P., De Ferrari, F., 2009. Firearm-related deaths in Brescia (Northern Italy) between 1994 and 2006: a retrospective study. *J Forensic Leg Med* 16, 325–331. <https://doi.org/10.1016/j.jflm.2009.01.006>
- [11] Rowhani-Rahbar, A., Azrael, D., Lyons, V.H., Simonetti, J.A., Miller, M., 2017. Loaded Handgun Carrying Among US Adults, 2015. *Am J Public Health* 107, 1930–1936. <https://doi.org/10.2105/AJPH.2017.304072>
- [12] Siegel, M., Xuan, Z., Ross, C.S., Galea, S., Kalesan, B., Flegler, E., Goss, K.A., 2017. Easiness of Legal Access to Concealed Firearm Permits and Homicide Rates in the United States. *Am J Public Health* 107, 1923–1929. <https://doi.org/10.2105/AJPH.2017.304057>
- [13] Bouvet, R., Baert, A., Le Gueut, M., 2015. Certificats médicaux et nouvelle réglementation des armes à feu en France. *La Presse Médicale* 44, 298–304.
- [14] Directive 91/477/CEE du Conseil, du 18 juin 1991, relative au contrôle de l'acquisition et de la détention d'armes, 1991. , 256.
- [15] Vadysinghe, A., Dassanayake, P., Wickramasinghe, M., 2017. Unusual Case of Suicide With a Modified Trap Gun. *Am J Forensic Med Pathol* 38, 97–99. <https://doi.org/10.1097/PAF.0000000000000302>
- [16] Cunliffe, C.H., Denton, J.S., 2008. An atypical gunshot wound from a home-made zip gun--the value of a thorough scene investigation. *J. Forensic Sci.* 53, 216–218. <https://doi.org/10.1111/j.1556-4029.2007.00621.x>
- [17] Hagemeyer, L., Schyma, C., Madea, B., 2009. Extended suicide using an atypical stud gun. *Forensic Sci. Int.* 189, e9-12. <https://doi.org/10.1016/j.forsciint.2009.03.028>
- [18] Grellner, W., Wilske, J., 2001. [Suicide with a walking cane gun: weapon, injury picture and psychopathology]. *Arch Kriminol* 207, 97–103.

- [19] Kolopp, M., Blum, A., Leupold, M.-A., Martrille, L., 2019. Atypical Suicide by Submachine Gun. *J. Forensic Sci.* 64, 629–633. <https://doi.org/10.1111/1556-4029.13897>
- [20] Kodikara, S., Kudagama, M., 2014. Trap gun: an unusual firearm, aimed at wild animals but causing a silent epidemic of human fatalities. *Am J Forensic Med Pathol* 35, 1–3. <https://doi.org/10.1097/PAF.0000000000000045>
- [21] Knight B, Thompson IM. The teaching of legal medicine in British medical schools. *Medical Education.* 1986;20(3):246–58.

### **Figure captions:**

Figure.1: Victim's body lying on its back, outer garments open in front.

Figure.2: The metal rod found near the body.

Figure.3: Metal "rod" tip.

Figure.4: The corpse discovered in the basement of the house.

Figure.5: Anterior left thoracic entrance wound (exterior view).

Figure.6: Anterior left thoracic entrance wound (interior view).

Figure.7: The corpse discovered in the basement of the house.

Figure.8: Alarm garden gun cannon covered in blood.

Figure.9: Fired cartridge into the alarm garden gun cannon.

Figure.10: Oval wound at the base of the left thorax and external lesions (1 – arcuate abrasion; 2 – bruise; OE – entrance hole).

Figure.11: Typical mechanism of a cane-gun. Images inspired by the Belgian patent of the "warning gun" published in 1920.

Figure.12: Typical mechanism of an alarm garden gun cannon. The circuit system is completed when the hook is pulled, and the blocker becomes free (red arrows). These images were found in the journal, *Manufrance*, and were slightly enhanced to make details clearer.

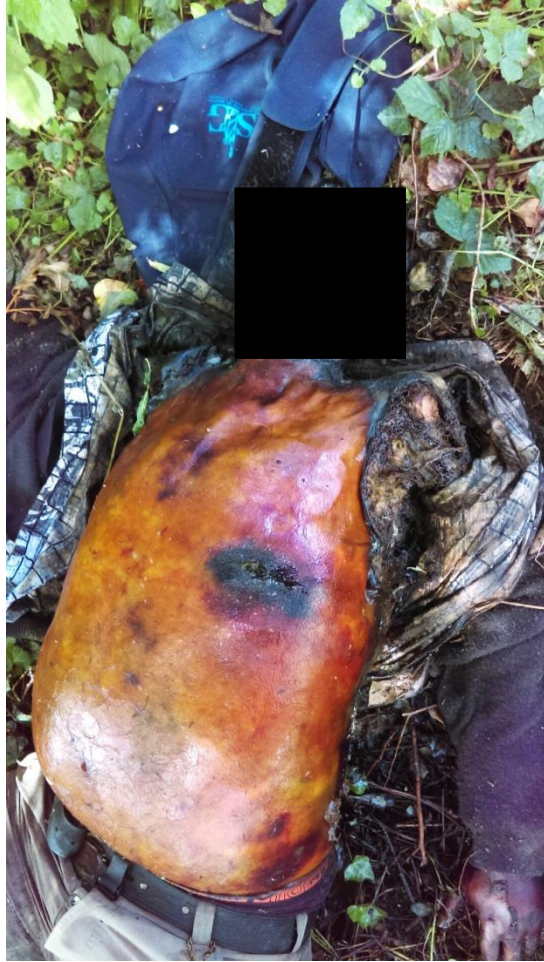

Fig.1. Victim's body lying on its back, outer garments open in front



Fig.2. The metal rod found near the body



Fig.3. Metal "rod" tip



Fig.4. Disassembly of the gun



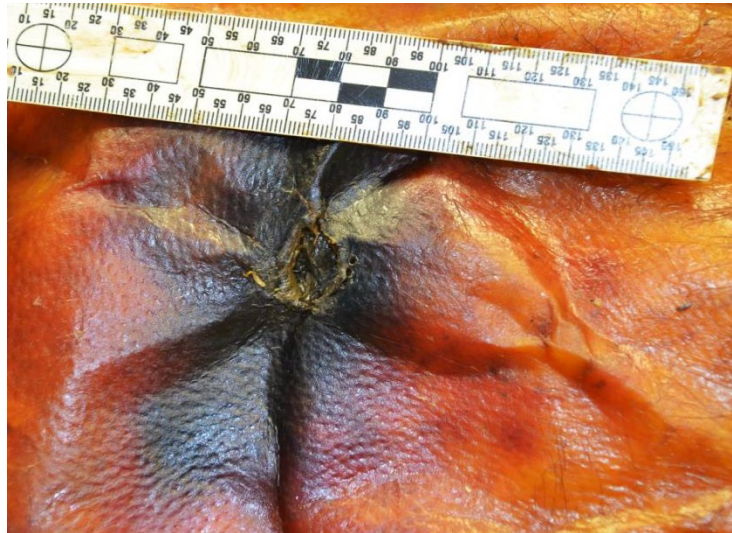


Fig.5. Anterior left thoracic entrance wound (exterior view)

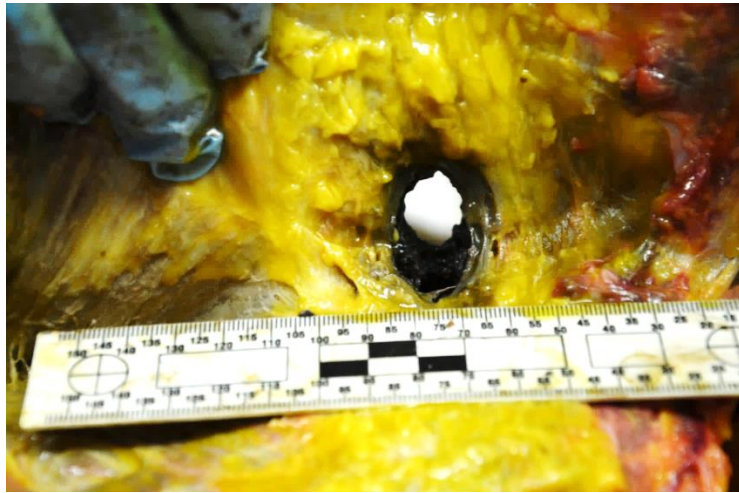


Fig.6. Anterior left thoracic entrance wound (interior view)



Fig.7. The corpse discovered in the basement of the house




Fig.8. Alarm garden gun cannon covered in blood



Fig.9. Fired cartridge into the alarm garden gun cannon

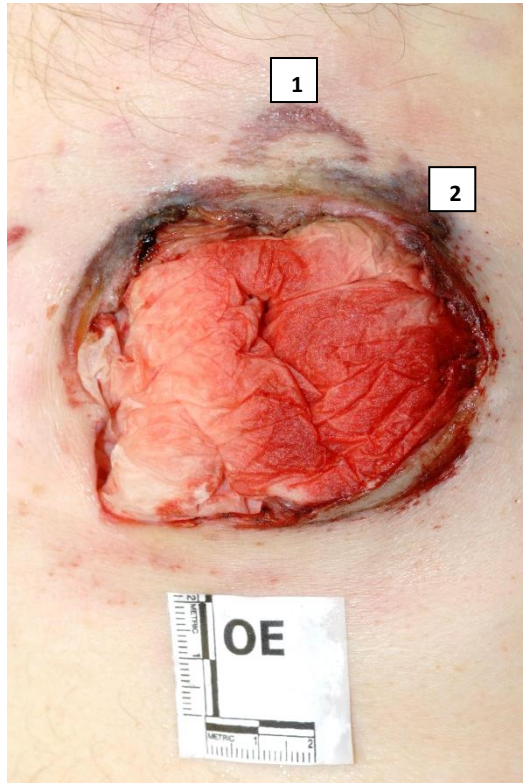


Fig.10. Oval wound at the base of the left thorax and external lesions  
(1 – arcuate abrasion; 2 – bruise; OE – entrance hole)

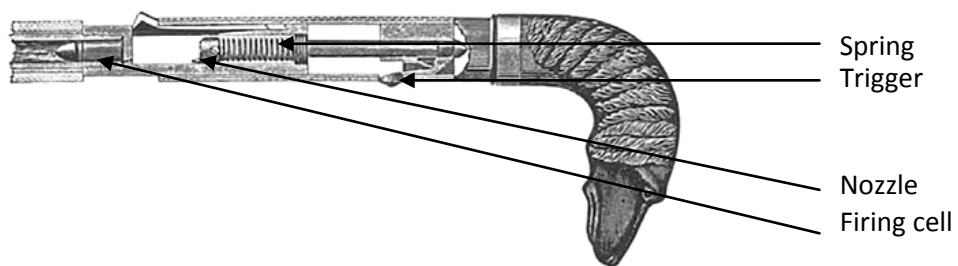


Fig.11. Typical mechanism of a cane-gun. Images inspired by the Belgian patent of the "warning gun" published in 1920.

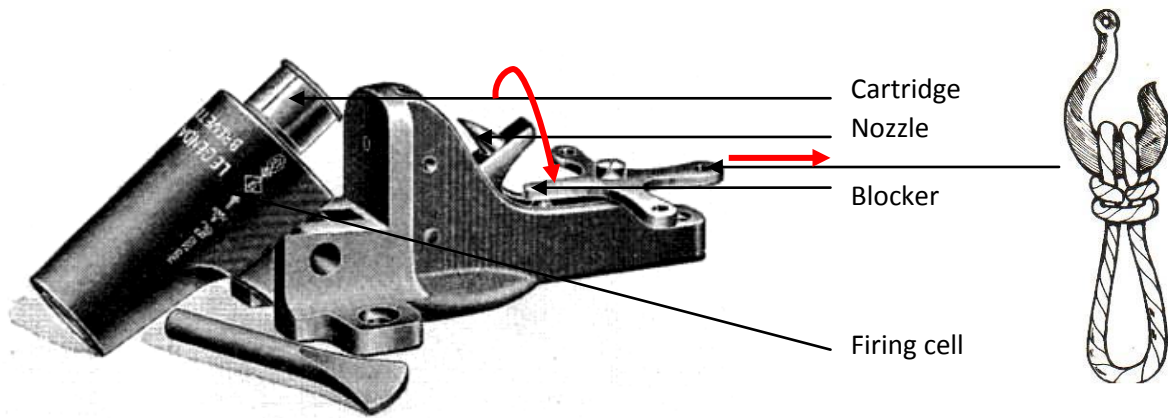


Fig.12. Typical mechanism of an alarm garden gun cannon. The circuit system is completed when the hook is pulled, and the blocker becomes free (red arrows). These images were found in the journal, *Manufrance*, and were slightly enhanced to make details clearer.