



HAL
open science

Flexor tendon complications in distal radius fractures treated with volar rim locking plates

A. Fardellas, P. Vernet, S. Facca, P. Liverneaux

► To cite this version:

A. Fardellas, P. Vernet, S. Facca, P. Liverneaux. Flexor tendon complications in distal radius fractures treated with volar rim locking plates. *Hand Surgery and Rehabilitation*, 2020, 39, pp.511 - 515. 10.1016/j.hansur.2020.06.003 . hal-03492869

HAL Id: hal-03492869

<https://hal.science/hal-03492869v1>

Submitted on 7 Nov 2022

HAL is a multi-disciplinary open access archive for the deposit and dissemination of scientific research documents, whether they are published or not. The documents may come from teaching and research institutions in France or abroad, or from public or private research centers.

L'archive ouverte pluridisciplinaire **HAL**, est destinée au dépôt et à la diffusion de documents scientifiques de niveau recherche, publiés ou non, émanant des établissements d'enseignement et de recherche français ou étrangers, des laboratoires publics ou privés.



Distributed under a Creative Commons Attribution - NonCommercial 4.0 International License

Flexor tendon complications in distal radius fractures treated with volar rim locking plates

Complications touchant les tendons fléchisseurs au cours du traitement des fractures de l'extrémité distale du radius par plaque antérieure extradistale

A. Fardellas, P. Vernet, S. Facca, P. Liverneaux

Department of Hand Surgery, SOS hand, University Hospital of Strasbourg, FMTS,
University of Strasbourg, Icube CNRS 7357, 1, avenue Molière, 67000 Strasbourg, France

Corresponding author:

Philippe Liverneaux

Department of Hand Surgery, SOS hand, University Hospital of Strasbourg, FMTS,
University of Strasbourg, Icube CNRS 7357, 1, avenue Molière, 67000 Strasbourg, France
philippe.liverneaux@chru-strasbourg.fr

Other authors:

Fardellas Alexandros

Vernet Paul

Facca Sybille

Liverneaux Philippe

Conflicts of interest:

Philippe Liverneaux has conflicts of interest with Newclip technis and Argomédical.

None of the other authors have conflicts of interest.

Acknowledgment: Juan Jose Hidalgo Diaz, for drawing the figures

Flexor tendon complications in distal radius fractures treated with volar rim locking plates

Complications touchant les tendons fléchisseurs au cours du traitement des fractures de l'extrémité distale du radius par plaque antérieure extradistale

Abstract

Volar locking plates used for treating distal radius fractures can damage the flexor tendon. Fractures distal to the watershed line can be fixed using volar rim locking plates. The aim of our study was to report the incidence of flexor tendon lesions when using these plates. Our case series included 15 patients (7 women, 8 men), aged 59 years on average (23-88) who underwent distal radius fixation using a volar rim plate (Extradistale®, Newclip Technics™, Haute Goulaine, France). Eight patients had complications: seven cases of synovitis treated by synovectomy with a satisfactory final outcome, ten cases of partial tendon ruptures treated by synovectomy and tendon repair in two cases, and five cases of complete rupture that were not repaired at the patient's requests. Our working hypothesis was not verified as we found flexor tendon complications in half our patients. When the fracture is distal to the watershed line, we recommend removing the plate after bone healing, never after the 3rd month postoperative.

Résumé

Les plaques antérieures verrouillées dans le traitement chirurgical des fractures de l'extrémité distale du radius peuvent entraîner des complications tendineuses de l'appareil fléchisseur. Les fractures au-delà de la ligne de partage des eaux (watershed line) peuvent être ostéosynthésées avec des plaques extradistales, c'est-à-dire qui descendent au-delà de la ligne de partage des eaux. Le but de notre étude était de rapporter l'incidence des lésions des tendons fléchisseurs dans une série de cas cliniques. Notre série comprenait 15 patients dont 7 femmes d'âge moyen 59 ans (23-88) opérés par plaque Extradistale® (Newclip

Technics™, Haute Goulaine, France). Huit patients présentaient des complications dont 7 synovites traitées par synovectomie avec un bon résultat final, 10 ruptures partielles traitées par synovectomie dont 2 avec suture tendineuse et 5 totales non réparées à la demande des patients. L'hypothèse de ce travail n'était pas vérifiée puisque nos résultats ont montré des complications intéressant l'appareil fléchisseur. En conclusion, en présence d'une fracture de l'extrémité distale du radius au-delà de la watershed line, nous recommandons l'ablation du matériel le plus vite possible après la consolidation osseuse, jamais après le troisième mois postopératoire.

Keywords: Watershed line; Distal radius fractures; Volar rim locking plates; Tendon complications

Mots-clés : Watershed line ; Fractures de l'extrémité distale du radius ; Plaque extradistale ; Complications tendineuses

1. Introduction

Volar locking plates have dramatically improved the results of the surgical treatment of displaced distal radius fractures (DRF) [1]. However, tendon damage has been reported when using volar locking plates [2-3]. The fixation of DRFs is not possible with regular plates [4-5]. Some authors have developed fragment-specific plates [6] and reported no tendon damage [7-9]. The downside of fragment-specific plates is that they are not sufficient to fix the fracture on their own and require an added mean of fixation [10]. Some authors have designed volar rim locking plates to enable fracture fixation including the distal fragment using only one device [11-12]. Volar rim plates are not associated with any specific complications according to some authors [11] while other authors report many complications [12,13].

The aim of our study was to report the incidence of flexor tendon lesions in a series of 15 patients with a DRF distal to the watershed line treated surgically with a volar rim distal plate. The working hypothesis was that plate removal recommended to be done 12 months after the initial fixation does not influence the incidence of flexor tendon lesions.

2. Materials and methods

Institutional review board approval was obtained for this study. The medical records of patients operated for a DRF distal to the watershed line between May 2018 and May 2019 were reviewed retrospectively. Patients aged less than 18 years, pregnant women, patients with a history of rheumatism or trauma in the affected limb were excluded. The preoperative, immediate postoperative as well as final radiographs were checked for alignment and intra-articular step-off. The fractures were classified according to the Arbeitsgemeinschaft für Osteosynthesefragen (AO) classification [14]. The Soong classification does not apply to this type of plate because the plate is specifically designed to have a low profile and be placed distal to the watershed line.

All the procedures were conducted by experienced hand surgeons. The procedures as well as the patient follow-up took place in our certified FESSH center. Our series included 15 patients (7 women, 8 men) aged 59 years on average (23-88) (Table 1).

The surgical technique consisted in DRF fixation distal to the watershed line using a volar rim locking plate (Extradistale®, Newclip Technics™, Haute Goulaine, France) under regional anesthesia using a minimally invasive approach and a dedicated drill guide [15]. The site was prepared with four aiming guides or a specific drill guide in its distal portion. The proximal end of the plate was inserted under the pronator quadratus. The distal part was inserted radially first and then ulnarly, making sure that no tendons were caught, particularly the flexor pollicis longus (FPL) between the plate and the radius.

The plate was positioned just distal to the watershed line and secured temporarily to the distal fragment using two 1.8 mm Kirchner (K) wires: one through the most ulnar aiming guide and the other through the most radial one (Fig. 1). The plate's position was checked with fluoroscopy. This step can be repeated as necessary until optimal positioning is obtained. The two central distal fragment screws were inserted and the two temporary K-wires were removed and replaced by screws. The proximal part of the plate was exposed by placing the wrist in maximum flexion to take advantage of skin elasticity, and the two proximal screws were placed (Fig. 2). The skin was closed by an intradermal continuous absorbable 3-0 suture. The surgeons reported no complications or difficulties when positioning the plates. Hand therapy was prescribed for every patient; no splint or immobilization cast was used postoperatively.

The outcomes were the number and types of complications in the flexor tendons (synovitis, partial rupture, total rupture) as well as their treatment. In addition, patient satisfaction at the end of the hand therapy was evaluated by the DASH and PWRE scores.

3. Results

The results are summarized in Table 1. Of the 22 tendons affected, only two had no clinical presentation during the follow-up in the outpatient clinic; the rest were identified and

documented during the clinical examination of each flexor tendon separately by surgeons. Clinical signs were pain during active flexion, loss of strength or total loss of active motion for the complete ruptures. No ultrasound imaging was used to identify the lesions. Seven patients had no signs of tendon irritation during the follow-up; nevertheless, they wanted to undergo another procedure for hardware removal as recommended.

Overall, eight patients had complications on the flexor tendons: seven cases of synovitis, ten cases of partial ruptures and five cases of total ruptures (Fig. 3). The plate was removed in all patients who had complications related to the flexor tendons. Seven cases of synovitis in four patients were treated by synovectomy with a satisfactory outcome. Ten partial tendon ruptures in six patients were treated by synovectomy with additional tendon repair in two cases; the remaining eight had less than 50% rupture, thus did not require repair. None of the five total tendon ruptures in three patients were repaired since those patients (aged 57, 72 and 88 years) refused the surgical revision after being provided with information on the surgical procedure and expected rehabilitation.

The earliest sign of tendon irritation was documented at the follow-up visit 2 months after the initial operation, with a mean of 2.2 months. Mean DASH and PWRE scores at the end of the hand therapy were 33.61 and 38.47, respectively.

4. Discussion

Understanding the biomechanics of different fracture types and recognizing the key fragments is crucial to developing a treatment-oriented classification and to selecting the best fixation device [16]. To optimize fixation, volar locking plates used for treating DRF should be placed as distally as possible [17]. However, they should not be placed distal to the watershed line due to the risk of complications on the flexor tendons [3,18-20]. Most flexor tendon lesions are caused by incorrectly positioned plates [2]. Some authors have developed a clinical test to detect synovitis and/or partial flexor tendon ruptures by looking for crackling during thumb mobilization [21,22]. Other authors recommend that all plates be removed before 1 year postoperative to avoid those complications [23].

Two articles describe the use of a volar rim locking plate (Depuy Synthes™, Saint-Priest, France) for DRF distal to the watershed line in 44 patients. It is surprising that one study reported only one flexor tendon complication while the other reported 15 cases of synovitis, six cases of partial rupture of the FPL, three cases of partial rupture of the flexor digitorum profundus (FDP) of the index, none of which required a surgical revision [12]. In the same study, 24 plates from a different manufacturer (Aculoc 2™, Cesson-Sevigne, France) did not cause flexor tendon complications [11]. One article describes the use of a specifically designed plate distal to the watershed line with an indentation for the FPL tendon, the Aptus® FPL plate (Medartis™, Basel, Switzerland); no flexor tendon complications were reported in the 15 patients treated with this plate. Of the 366 patients treated with the Medartis™ Aptus® plate, one patient had irritation of the FDP tendon of the index finger and the other of the FPL tendon; along with the other plates used, the overall rate of flexor tendon irritation was 0.5% with no complete tendon ruptures [13]. Through an ultrasound and radiological examination of the wrist during physiological movements in 12 patients treated with the same plate, the Aptus® FPL plate's indentation was found to reduce the tendon-plate contact and even prevent it completely [9]. Plates from a fourth manufacturer (Newclip Technics™) were used in our study. In our 15 patients, flexor tendon complications were common, and the tendon ruptures occurred after 3 months. We repaired the tendons in two cases of partial rupture in our series. Some authors contend that tendon repair is not necessary when less than 60% of the flexor tendon is damaged [24].

Our working hypothesis was not verified since we found flexor tendon complications in 8 of 15 patients with DRF distal to the watershed line, including 3 cases of complete tendon rupture.

5. Conclusion

When the DRF is distal to the watershed line, we recommend removing the plate as soon as possible after bone healing and never after 3 months postoperative.

Conflicts of interest:

Philippe Liverneaux has conflicts of interest with Newclip Technics and Argomédical.

None of the other authors have conflicts of interest.

Acknowledgment: Juan Jose Hidalgo Diaz for drawing the figures.

References

1. Loisel F, Kielwasser H, Faivre G, Rondot T, Rochet S, et al. Treatment of distal radius fractures with locking plates: an update. *Eur J Orthop Surg Traumatol* 2018;28:1537-42.
2. Cognet JM, Dujardin C, Popescu A, Gouzou S, Simon P. [Rupture of the flexor tendons on an anterior plate for distal radial fracture: four cases and a review of the literature]. *Rev Chir Orthop Reparatrice Appar Mot* 2005;91:476-81.
3. Monaco NA, Dwyer CL, Ferikes AJ, Lubahn JD. Hand surgeon reporting of tendon rupture following distal radius volar plating. *Hand (N Y)* 2016;11:278-86.
4. Obata H, Baba T, Futamura K, Obayashi O, Mogami A, et al. Difficulty in fixation of the volar lunate facet fragment in distal radius fracture. *Case Rep Orthop* 2017;2017:6269081.
5. Beck JD, Harness NG, Spencer HT. Volar plate fixation failure for volar shearing distal radius fractures with small lunate facet fragments. *J Hand Surg Am* 2014;39:670-8.
6. Hozack BA, Tosti RJ. Fragment-specific fixation in distal radius fractures. *Curr Rev Musculoskelet Med* 2019;12:190-7.
7. Bakker AJ, Shin AY. Fragment-specific volar hook plate for volar marginal rim fractures. *Tech Hand Up Extrem Surg* 2014;18:56-60.
8. Quadlbauer S, Pezzei C, Jurkowitsch J, Rosenauer R, Pichler A, et al. Early complications and radiological outcome after distal radius fractures stabilized by volar angular stable locking plate. *Arch Orthop Trauma Surg* 2018;138:1773-82.
9. Schlickum L, Quadlbauer S, Pezzei C, Stöphasius E, Hausner T, Leixnering M. Three-dimensional kinematics of the flexor pollicis longus tendon in relation to the position of the FPL plate and distal radius width. *Arch Orthop Trauma Surg* 2019;139:269-79.
10. O'Shaughnessy MA, Shin AY, Kakar S. Volar marginal rim fracture fixation with volar fragment-specific hook plate fixation. *J Hand Surg Am* 2015;40:1563-70

11. Naito K, Sugiyama Y, Kinoshita M, Obata H, Goto K, et al. Functional outcomes in volar-displaced distal radius fractures patients with marginal rim fragment treated by volar distal locking plates. *J Hand Microsurg* 2019;11:100-5.
12. Kara A, Celik H, Oc Y, Uzun M, Erdil M, Tetik C. Flexor tendon complications in comminuted distal radius fractures treated with anatomic volar rim locking plates. *Acta Orthop Traumatol Turc* 2016;50:665-9.
13. Quadlbauer S, Pezzei C, Jurkowitsch J, Rosenauer R, Pichler A, et al. Functional and radiological outcome of distal radius fractures stabilized by volar-locking plate with a minimum follow-up of 1 year. *Arch Orthop Trauma Surg* 2020;140:843-52.
14. Müller ME, Nazarian S, Koch P, Schatzker J. Tibia/Fibula = 4. In: *The comprehensive classification of fractures of long bones*. Berlin, Heidelberg, Springer, 1990; pp. 148-191.
15. Liverneaux PA. The minimally invasive approach for distal radius fractures and malunions. *J Hand Surg Eur* 2018;43:121-30.
16. Hintringer W, Rosenauer R, Pezzei C, Quadlbauer S, Jurkowitsch J, et al. Biomechanical considerations on a CT-based treatment-oriented classification in radius fractures. *Arch Orthop Trauma Surg* 2020;140:595-609.
17. Harness NG, Jupiter JB, Orbay JL, Raskin KB, Fernandez DL. Loss of fixation of the volar lunate facet fragment in fractures of the distal part of the radius. *J Bone Joint Surg Am* 2004;86:1900-8.
18. Soong M, Earp BE, Bishop G, Leung A, Blazar P. Volar locking plate implant prominence and flexor tendon rupture. *J Bone Joint Surg Am* 2011;93:328-35.
19. Asadollahi S, Keith PP. Flexor tendon injuries following plate fixation of distal radius fractures: a systematic review of the literature. *J Orthop Traumatol* 2013;14:227-34.
20. Casaletto JA, Machin D, Leung R, Brown DJ. Flexor pollicis longus tendon ruptures after palmar plate fixation of fractures of the distal radius. *J Hand Surg Eur* 2009;34:471-4.
21. Suganuma S, Tada K, Tsuchiya H. Reducing the risk of flexor pollicis longus tendon rupture after volar plate fixation for distal radius fractures: validation of the tendon irritation test. *Eur J Orthop Surg Traumatol* 2014;24:1425-9.

22. Tada K, Ikeda K, Shigemoto K, Suganuma S, Tsuchiya H. Prevention of flexor pollicis longus tendon rupture after volar plate fixation of distal radius fractures. *Hand Surg* 2011;16:271-5.
23. Medda LP, Matheron AS, Hidalgo Diaz JJ, Maire N, Vernet P, et al. Minimally invasive hardware removal after minimally invasive distal radius plate osteosynthesis (MIPO): Feasibility study in a 388 case series. *Orthop Traumatol Surg Res* 2017;103:85-7.
24. McGeorge DD, Stilwell JH. Partial flexor tendon injuries: to repair or not. *J Hand Surg Br* 1992;17:176-7.

Figure captions

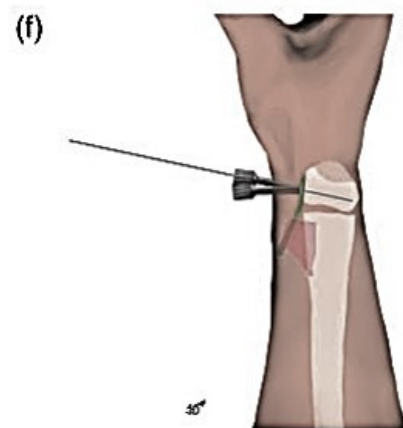
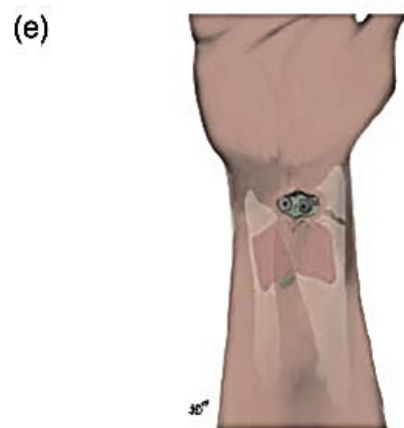
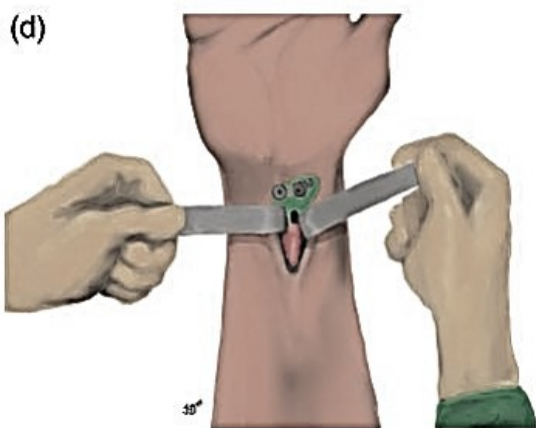
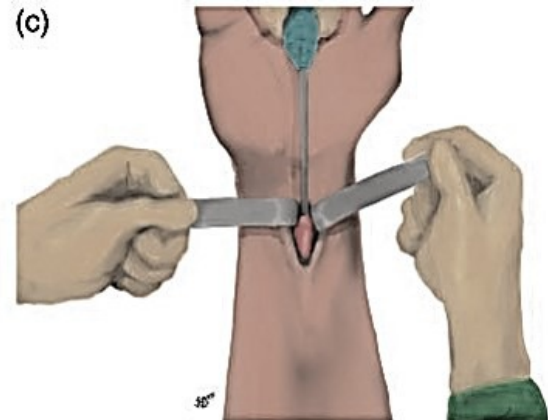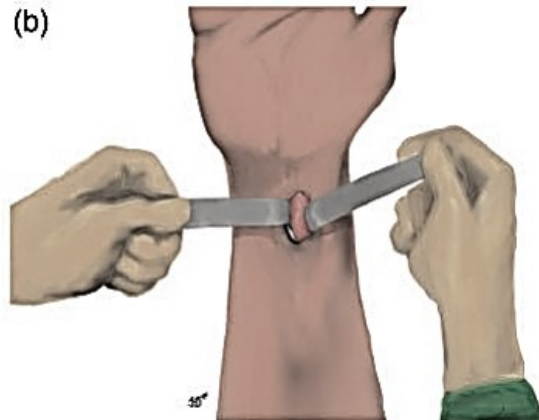
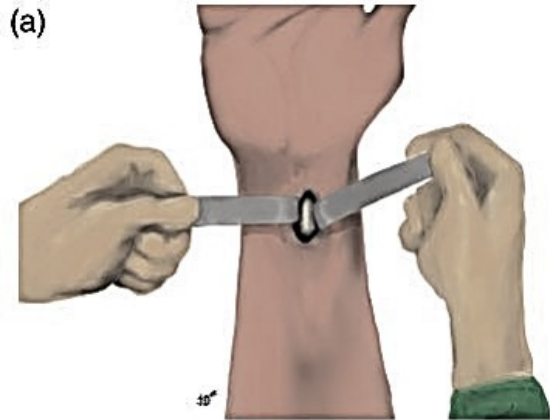
Fig. 1. First step of surgical technique. The FCR tendon is between the two retractors (a). The pronator quadratus is exposed when the FCR, flexor pollicis longus (FPL) and other tendons are retracted to the ulnar side of the skin incision (b). The pronator quadratus is elevated at its distal end using a periosteal elevator (c). A volar locking plate, prepared with two aiming guides at its distal end, is inserted by placing its proximal end under the pronator quadratus (d). Next, the entire plate is inserted underneath the pronator quadratus (e). The plate is positioned just proximal to the watershed line and secured temporarily to the radial epiphysis using a 1.8 mm K-wire through the most ulnar aiming guide. The plate's position is checked with fluoroscopy and is modified if necessary, until the K-wire is in the subchondral bone (f).

Fig. 2. Second step of surgical technique. A second 1.8 mm K-wire is inserted through the most radial aiming guide. The plate's position is checked with fluoroscopy and is modified if necessary, until the K-wire is in subchondral bone (see inset). The other screws are inserted in the same manner (a). Reduction of fracture onto the plate. The wrist is flexed to shift the incision proximally. The plate is positioned on the anterior cortex of the metaphysis by applying pressure with a bone impactor, thereby reducing its dorsal tilt (see inset) (b).

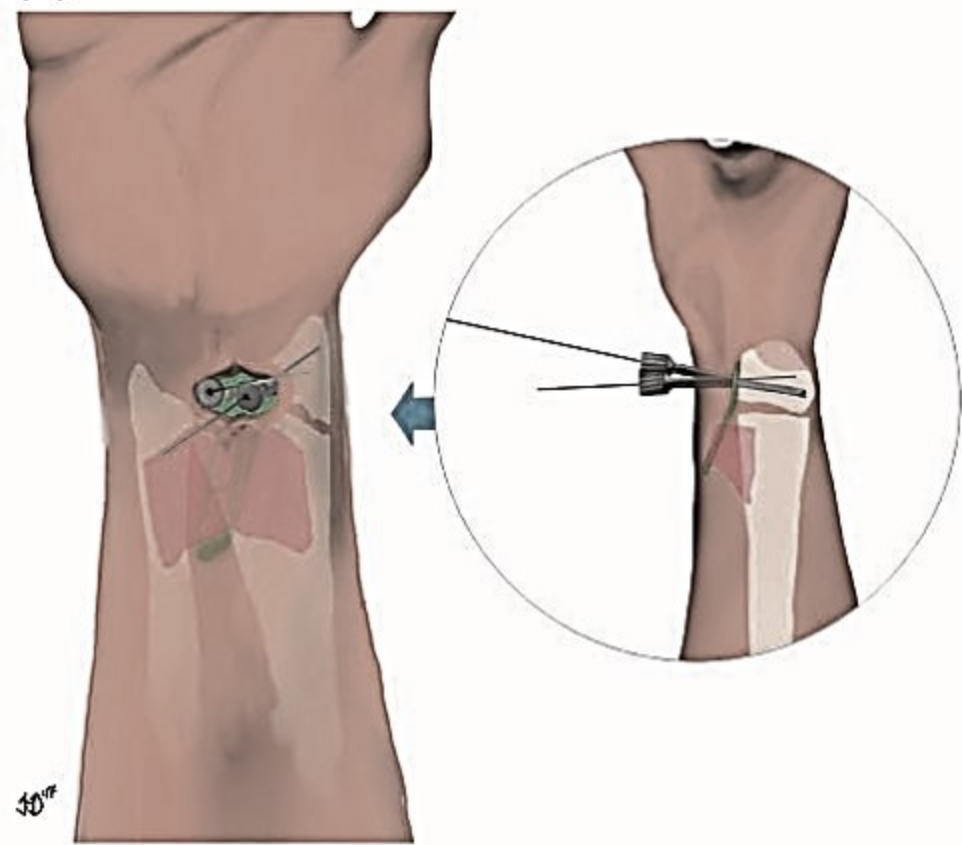
Fig. 3. Example of tendon damage with a volar rim locking plate (patient No.4). Preoperative x-ray AP view (*left*) and lateral view (*right*) (A). Postoperative x-ray AP view (*left*) and lateral view (*right*) (B). X-ray after plate removal AP view (*left*) and lateral view (*right*) (C). Intraoperative view during plate removal (*left*). Synovectomy of flexor pollicis longus (*right*) (D).

Table title

Table 1. Features and results of a case series of 15 patients with distal radius fractures treated by volar rim locking plate

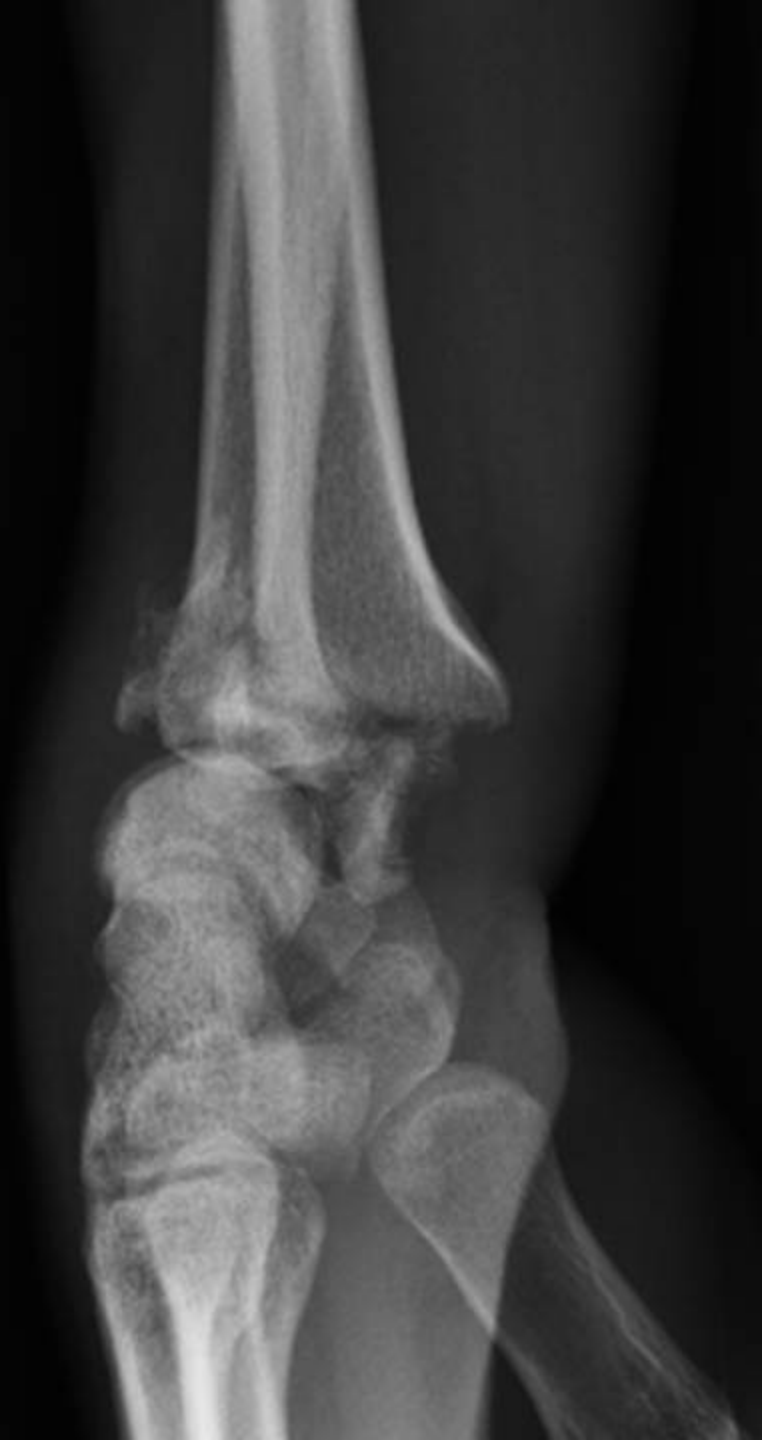
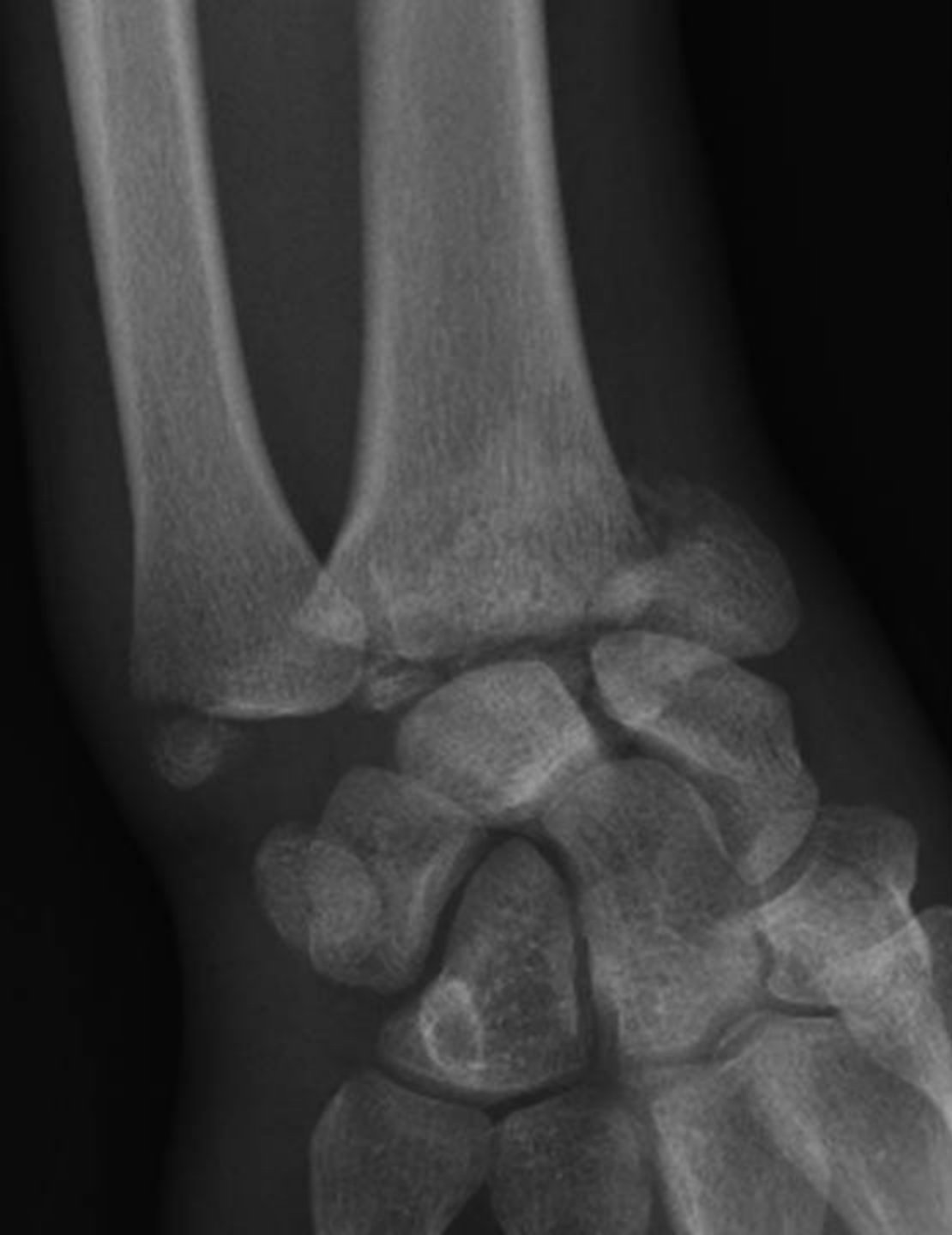
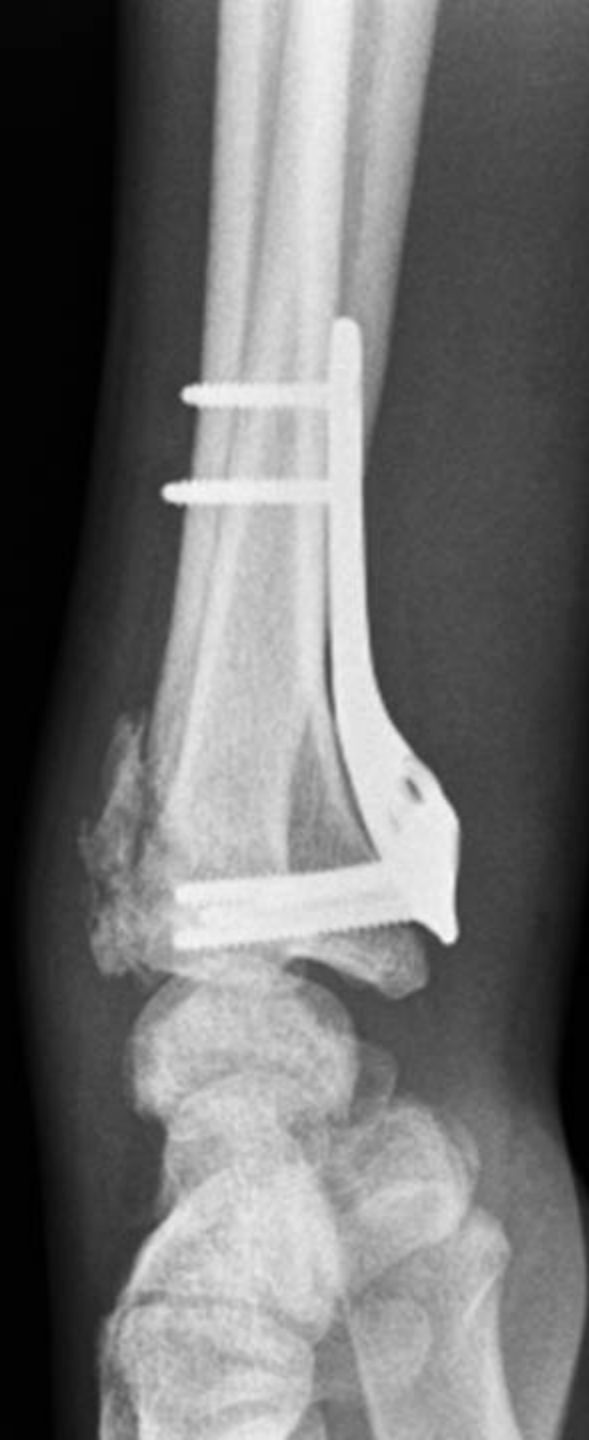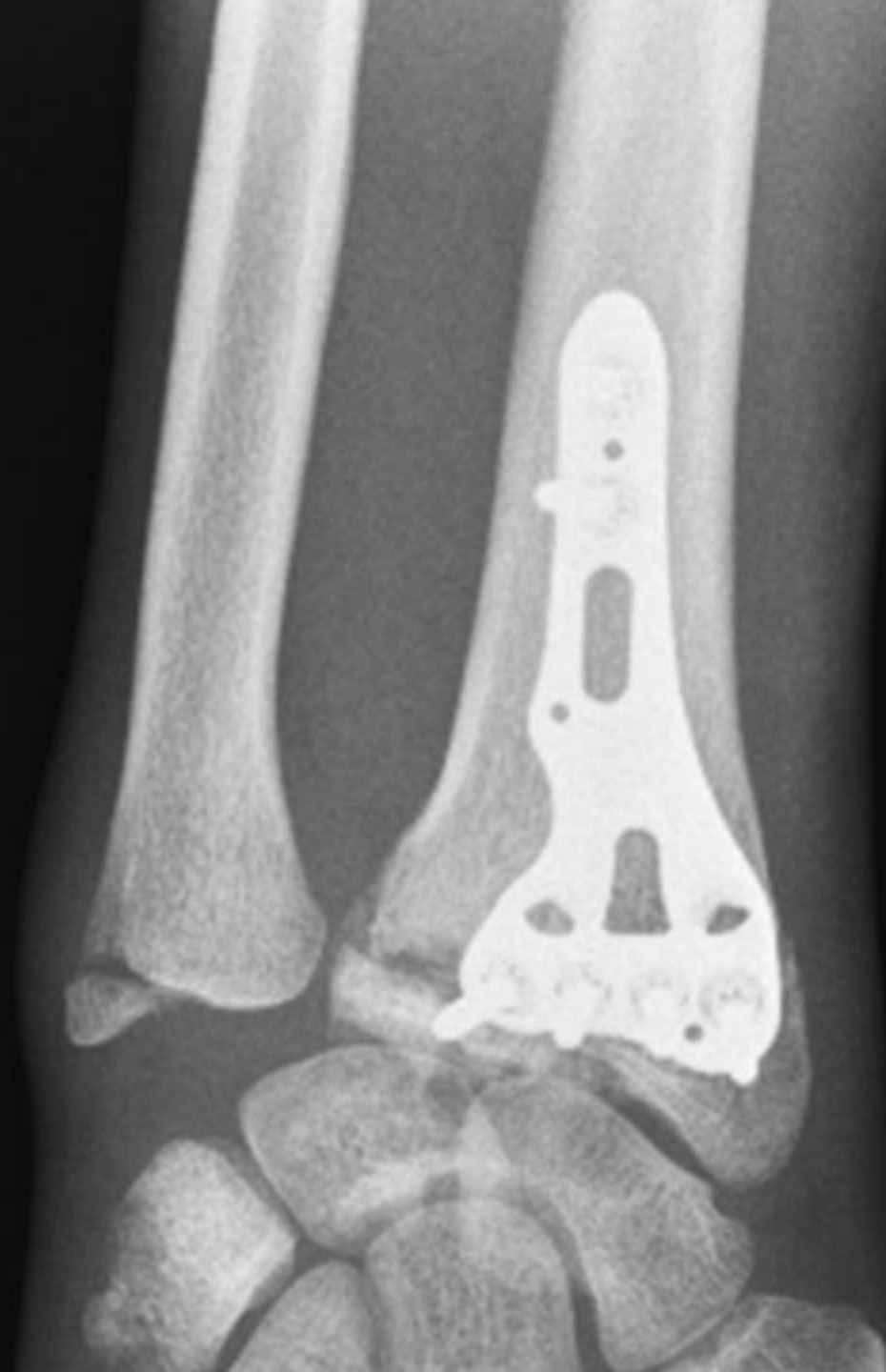(a)

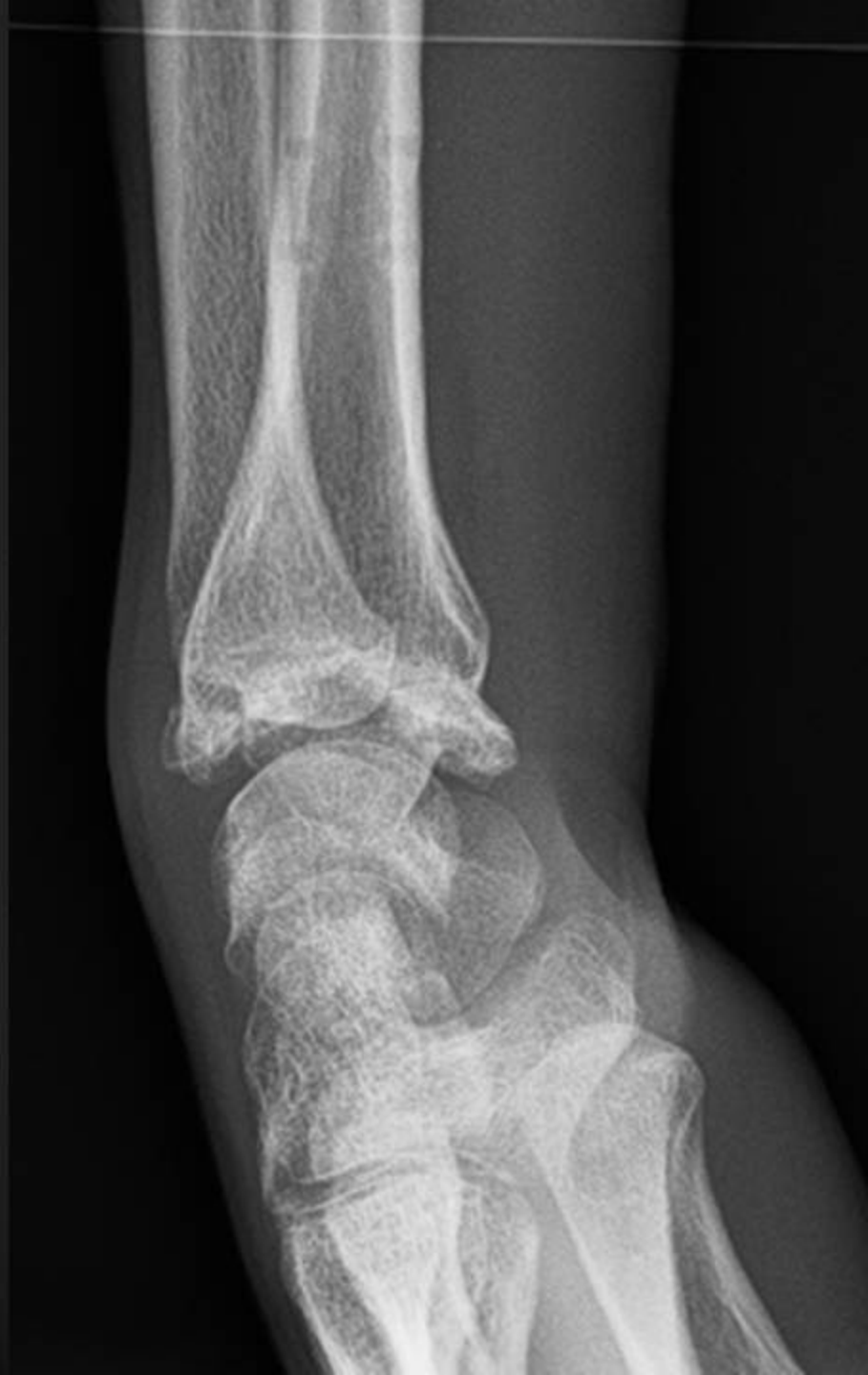
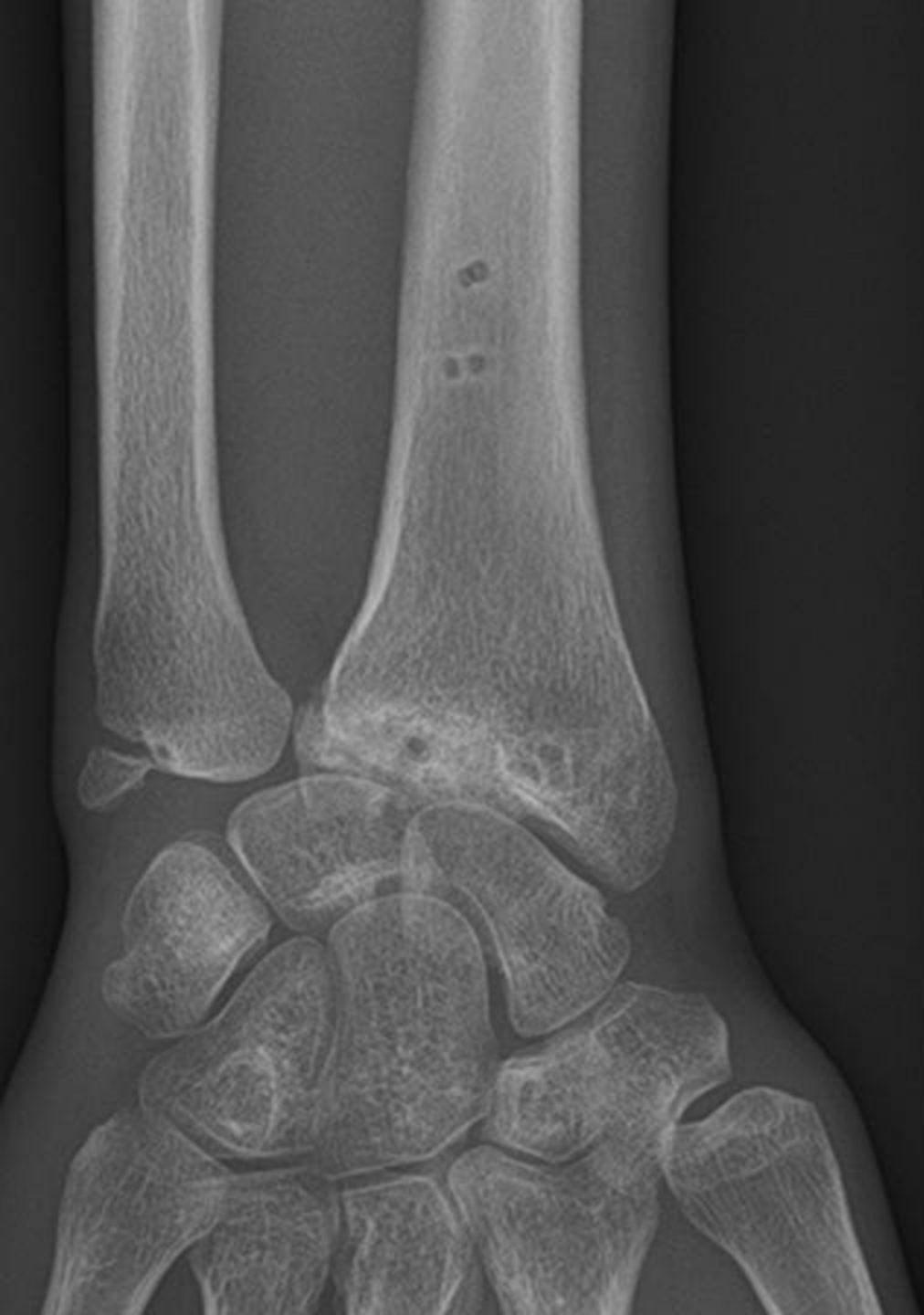
(b)

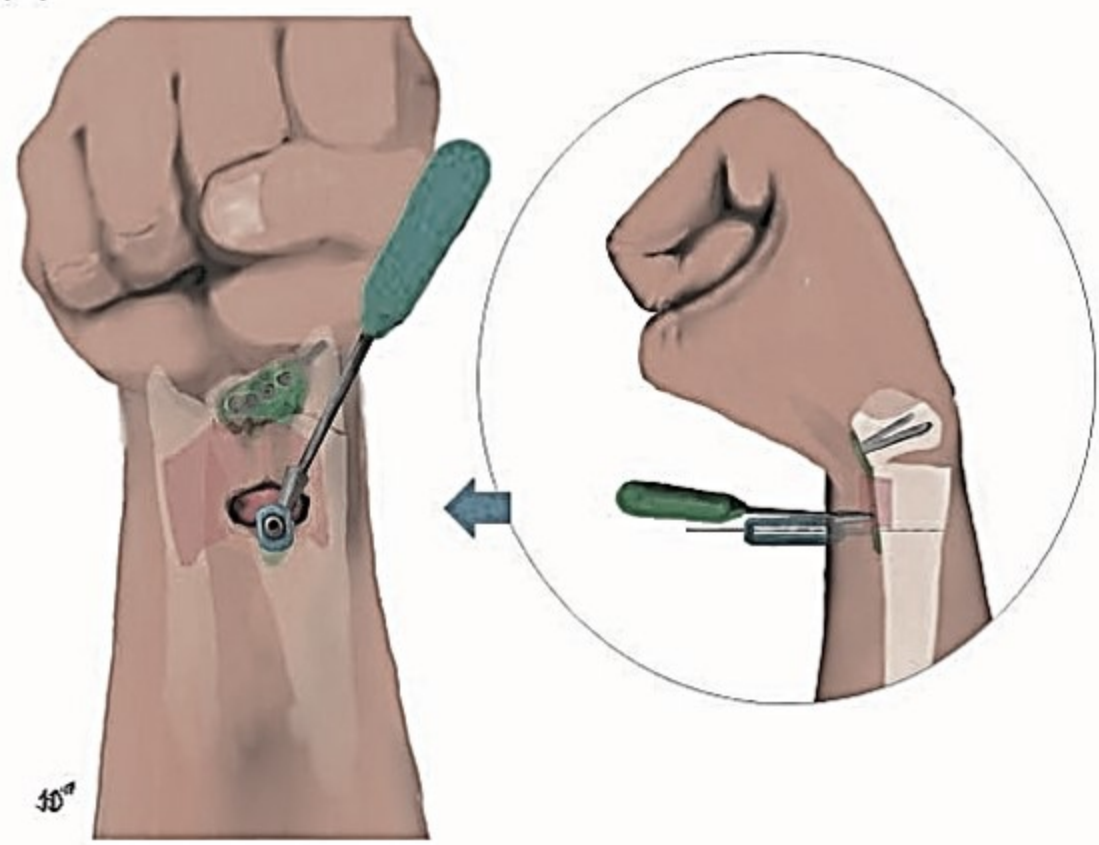







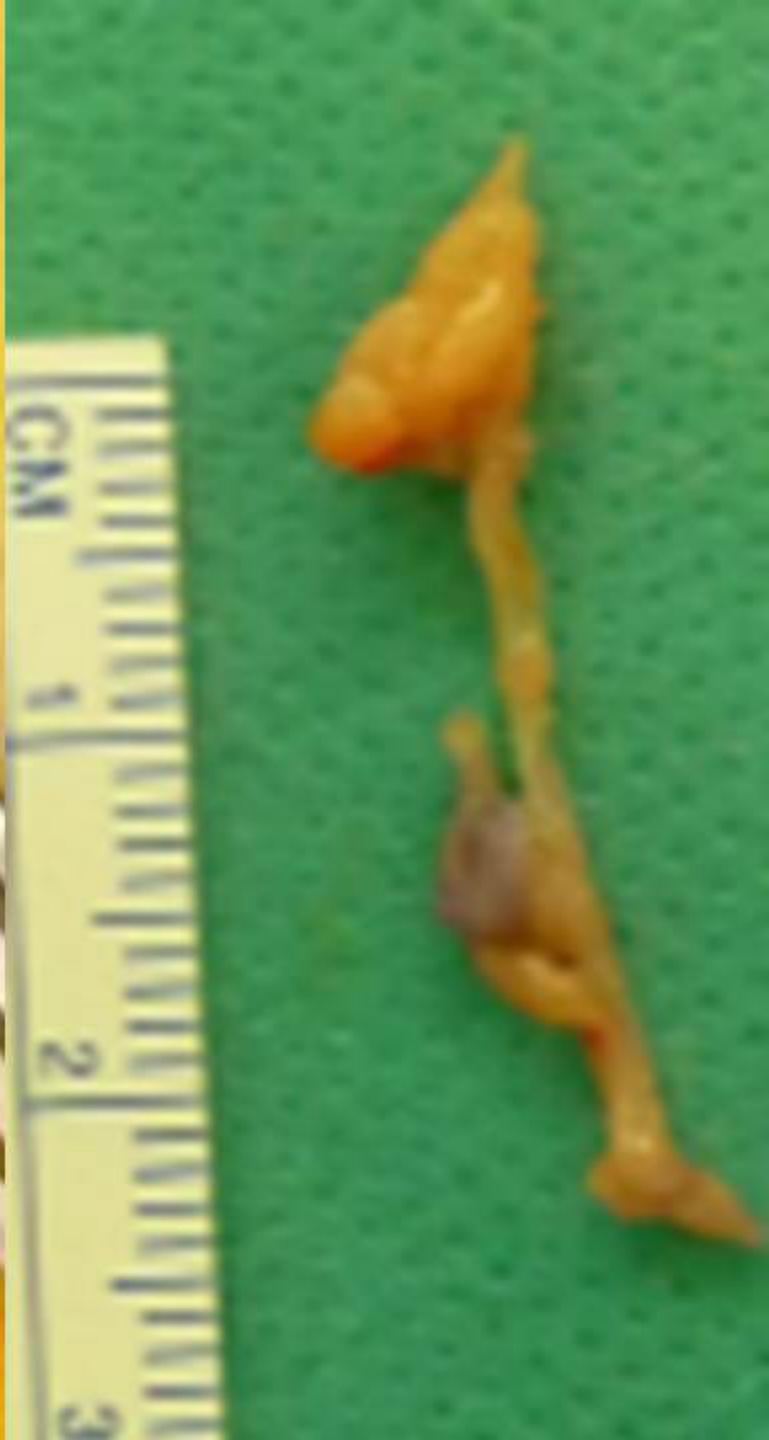
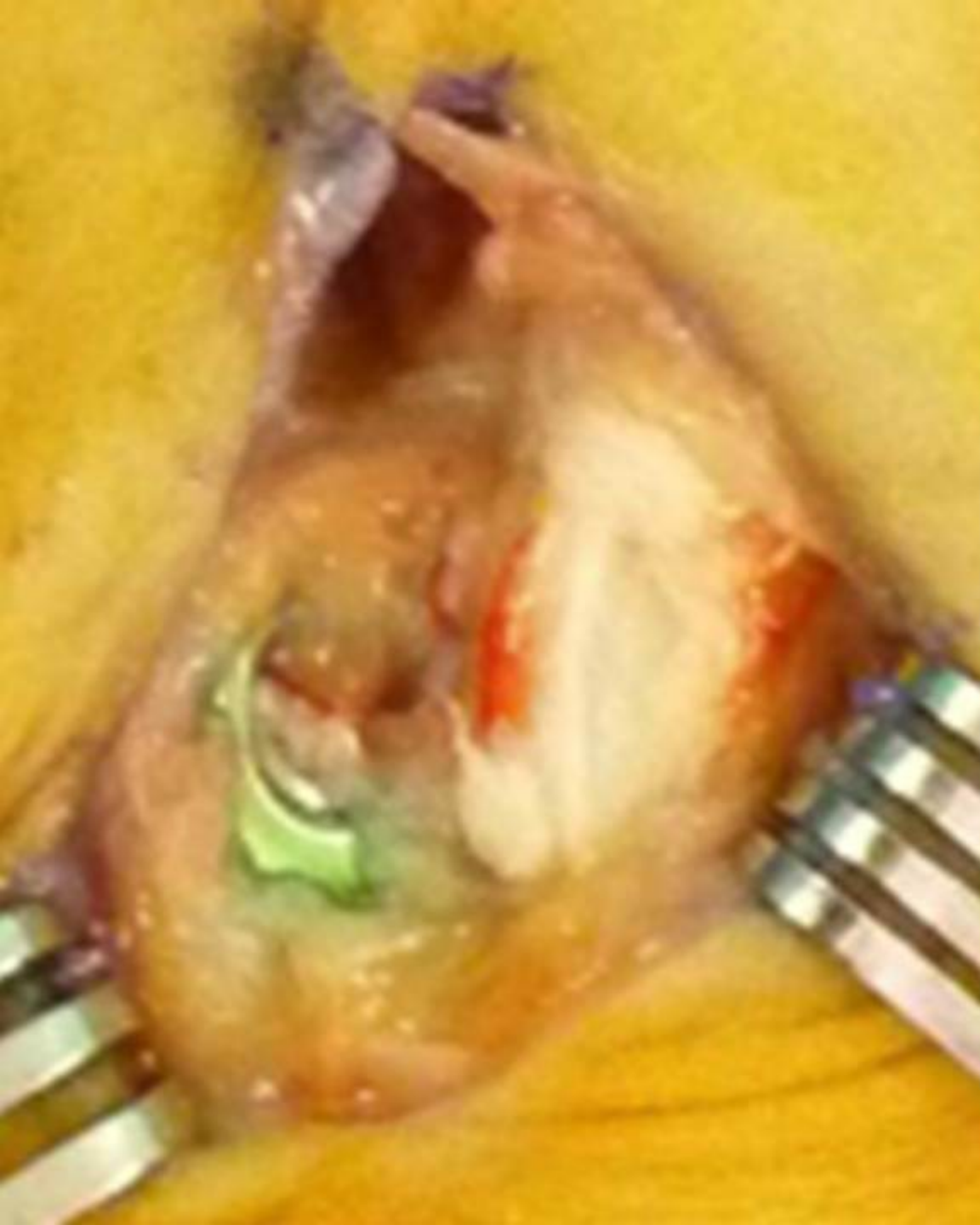

Table 1. Features and results of a case series of 15 patients with distal radius fractures treated by volar rim locking plate

Patient (N)	Gender (M/F)	Age (years)	AO (A/B/C)	D (R/L)	I (R/L)	TTL (M)	HR (Y/N)	Flexion tendon lesions						
								S		PR		TR		
1	M	65	C.3.2	R	R	NA	Y	-	-	-	-	-	-	-
2	F	72	C.3.2	R	R	8	Y	-	-	FDS2***	-	-	FPL*	-
3	M	56	C.3.1	R	R	5	Y	FPL**	-	-	-	-	-	-
4	M	23	A.2.1	R	R	5	Y	FPL**	-	-	FCR**	-	-	-
5	F	57	C.1.2	R	R	3	Y	-	-	FDS2** FDS3**	-	-	FPL*	-
6	F	88	C.1.2	R	L	3	Y	FDP4** FDS4** FDP5** FDS5**	FDP3** FDS3**	FPL** FDS2***	FPL* FDP2* FDS2*	-	-	-
7	M	49	C.2.1	R	L	4	Y	-	-	-	-	-	-	-
8	F	76	C.1.3	R	L	NA	N	-	-	-	-	-	-	-
9	M	26	B.3.1	R	L	NA	Y	-	-	-	-	-	-	-
10	F	52	C.1.2	R	L	2	Y	FPL**	-	-	-	-	-	-
11	M	70	B.3.2	R	L	NA	Y	-	-	-	-	-	-	-
12	F	60	C.2.1	R	L	4	Y	-	-	FDS2** FDS3**	-	-	-	-
13	M	45	C.3.1	R	L	NA	Y	-	-	-	-	-	-	-
14	F	72	A.2.2	L	L	NA	Y	-	-	-	-	-	-	-
15	M	68	C.2.2	L	L	NA	Y	-	-	-	-	-	-	-

M: male; F: female; D: dominant side; I: injured side; R: right; L: left; TTL: time to lesion occurrence; M: months; HR: hardware removal; Y: yes; N: no; S: synovitis; PR: partial rupture; TR: total rupture; 1,2,3,4,5: thumb, index, middle, ring, little finger; FCR: flexor carpi radialis; FPL: flexor pollicis longus; FDS: flexor digitorum superficialis; FDP: flexor digitorum profundus; NA: not applicable; *: no repair; **: synovectomy; ***: suture repair; ****; graft; *****: tendon transfer