



HAL
open science

Minimally invasive posterolateral hip approach with SPARTAQUUS (Spare the Piriformis And Respect The Active QUadratus femoris and gluteus mediUS) technique

Romain Gérard, Joël Savéan, Christian Lefèvre

► To cite this version:

Romain Gérard, Joël Savéan, Christian Lefèvre. Minimally invasive posterolateral hip approach with SPARTAQUUS (Spare the Piriformis And Respect The Active QUadratus femoris and gluteus mediUS) technique. *Orthopaedics & Traumatology: Surgery & Research*, 2020, 106, pp.1523 - 1526. 10.1016/j.otsr.2020.07.010 . hal-03492691

HAL Id: hal-03492691

<https://hal.science/hal-03492691>

Submitted on 15 Dec 2022

HAL is a multi-disciplinary open access archive for the deposit and dissemination of scientific research documents, whether they are published or not. The documents may come from teaching and research institutions in France or abroad, or from public or private research centers.

L'archive ouverte pluridisciplinaire **HAL**, est destinée au dépôt et à la diffusion de documents scientifiques de niveau recherche, publiés ou non, émanant des établissements d'enseignement et de recherche français ou étrangers, des laboratoires publics ou privés.



Distributed under a Creative Commons Attribution - NonCommercial 4.0 International License

Technical Note

Minimally invasive posterolateral hip approach with SPARTAQUUS (Spare the Piriformis And Respect The Active QUadratus femoris and gluteus mediUS) technique

Romain **Gérard**^{a,b,*}, Joël **Savéan**^{b,d}, Christian **Lefèvre**^{b,c,d}

a Service de Chirurgie Orthopédique et Traumatologique, Centre Hospitalier Privé Brestois, Clinique Pasteur-Lanroze, 29200 Brest, France

b LaTIM, Inserm, UMR 1101, SFR IBSAM, UFR médecine, 22, avenue Camille-Desmoulins, CS 93837, 29238 Brest cedex 3, France

c Service de Chirurgie Orthopédique et Traumatologique, Centre Hospitalier Régional Universitaire, 29200 Brest, France

d Université de Bretagne Occidentale, UBO, 3, rue des Archives, CS 93837, 29238 Brest, France.

* **Corresponding author:** Romain Gérard,

Department of Orthopedics and Traumatology

Clinique Pasteur-Lanroze, 29200 Brest, France

Email = dr.romaingerard@gmail.com

Abstract

Interest in the different surgical approaches to total hip arthroplasty remains high, but without any real consensus on which approach is the most beneficial. Several recent technical

innovations have made it possible to reduce the risk of dislocation and therefore improving the efficacy of the posterolateral approach. Since 2003, we have been using a modified minimally invasive posterolateral approach called SPARTAQUUS (Spare the Piriformis And Respect The Active QUadratus femoris and gluteus mediUS) which spares the piriformis tendon, the quadratus femoris muscle and the gluteus medius muscle, and involves direct capsular repair. The “active posterosuperior hammock” effect of the piriformis tendon is therefore coupled with the “passive posterosuperior hammock” effect of the capsular repair, thus limiting the risks of posterior dislocation of the prosthetic hip joint.

Key words: posterior approach, total hip arthroplasty, dislocation

1. Introduction

Interest in the different surgical approaches to total hip arthroplasty remains high, but without any real consensus on which approach is the most beneficial [1,2]. However, two approaches stand out in terms of efficacy, rapid postoperative recovery, preservation of the abductor apparatus and low dislocation rate. The anterior approach has a steep learning curve, often requires a specialized table and ancillary equipment, and has a significantly higher incidence of intraoperative fractures and injury to the lateral femoral cutaneous nerve [3,4]. The posterior approach, historically purported to have a higher dislocation rate [5,6], has had the same excellent functional outcomes as the anterior approach [3,4], and remains the most commonly used technique worldwide [7-9]. Several recent technical innovations have greatly reduced the risk of dislocation [9-11] and therefore improving the efficacy of the posterolateral approach [12-16], originally described by Moore in the 1950s [17]. Since 2003 [18], we have been using a modified minimally invasive posterolateral approach called

SPARTAQUUS (Spare the Piriformis And Respect The Active QUadratus femoris and gluteus mediUS) which spares the piriformis tendon, the quadratus femoris muscle and the gluteus medius muscle, and involves direct capsular repair without reinsertion of the remaining lateral rotator group of muscles. This modified posterolateral SPARTAQUUS approach is presented below.

2. **Technique**

The patient was placed in the lateral decubitus position (video SPARTAQUUS.wmv). The curvilinear incision was centered over the greater trochanter (2/3 proximally and 1/3 distally) and measured approximately 10 +/- 2 cm. The aponeurosis of the gluteus maximus muscle and the tensor fasciae latae were exposed and opened in an arciform manner. The gluteus maximus muscle was split in line with its fibers without detaching it. The gluteus medius and gluteus minimus muscles were retracted and therefore completely preserved. The short lateral rotators were exposed when retracting the layer of fat. The sciatic nerve is sometimes visualized, but never dissected. The interval between the gluteus medius and piriformis muscles was identified. The piriformis tendon, appearing as a dense pearly white strip running obliquely downward and outward (Fig. 1) (video of opening), contrasted with the red fibers of the adjacent muscles. An L-shaped incision in the lateral rotator group of muscles was performed distally to the inferior border of the piriformis tendon and ending at the anterior border of the quadratus femoris muscle (Fig. 1). The remaining lateral rotator group of muscles (superior and inferior gemelli, obturator internus and obturator externus) were released close to the intertrochanteric line using an electric scalpel and will not be reinserted. The resulting muscle flap was detached from the capsular plane and reflected backwards to protect the sciatic nerve. A capsular incision was made along the inferior border of the

piriformis tendon, that was carried down along the intertrochanteric line and ended next to the base of the femoral neck, under the deep surface of the quadratus femoris. It was then possible to release the zona orbicularis and free the neck from its capsular attachments. The arciform incision in the capsular plane produced a flap with a clearly distinct free border that was thick, and solid, especially in the proximal area (Fig. 2), that was easily sutured with number 2 absorbable thread once the prosthesis was implanted (Fig. 3) (video of closure).

3. Results

We reported in Table 1 the results from a single-center, single-operator (RG) study of 296 scheduled total hip arthroplasties that were performed in 2018 using the posterior “SPARTAQUUS” approach and a surgical navigation system (Orthokey™, Florence, Italy). There were no dislocations or periprosthetic fractures in this continuous study (Table 1).

4. Discussion

The lateral rotator group of muscles (piriformis, superior gemellus, obturator internus, inferior gemellus, obturator externus, and quadratus femoris) are considered the “rotator cuff” of the hip [21]. Anatomically speaking, the piriformis exhibits continuity and thick dense tendons, and plays a significant role in the active stabilization of the acetabulofemoral joint (“posterior stabilizer of the hip” [22]), as well as hip abduction and external rotation [23]. The quadratus femoris, a large and powerful muscle [24], also plays an important role in external rotation, adduction and active stabilization of the hip. However, the combination of superior gemellus-obturator internus-inferior gemellus, called the triceps coxae [24], and the obturator externus forms a thin and weaker musculotendinous unit that is not very involved in the external rotation of the hip [25]. Given these anatomical and functional reasons, we now use the

minimally invasive window between the piriformis tendon and the quadratus femoris for all posterior total hip arthroplasties. The piriformis tendon is completely spared, which by its active role in hip stabilization and joint coaptation [22,24], reinforces the posterosuperior corner of the acetabulofemoral joint, and thus significantly reduces the risk of posterior dislocation. Furthermore, it can act as an indicator of muscle and soft tissue tensions after the final prosthetic components are implanted. Repairing the capsule is essential [10,26-28]. The relative risk of dislocation is six to eight times higher if the capsule is not repaired [10,28]. Preservation of the entire piriformis is essential and useful [29]. Indeed, suturing of the piriformis tendon after dissection is not reliable [30], because of fatty degeneration and marked atrophy. Preservation of the quadratus femoris is important because it acts as an active external rotator and hip stabilizer. Its sectioning away from the posterior border of the greater trochanter to preserve the blood supply from the medial circumflex femoral artery is not indicated, because the risk of injuring the sciatic nerve is then greater [31]. Its repair is unreliable and greatly decreases the active coaptation capacities of the acetabulofemoral joint [24] because its thick musculature makes it impossible to perform a solid direct suture and scarring is not uniform. Lastly, this technique makes it possible to preserve in most cases, the medial circumflex femoral artery and perfusion of the greater trochanter (via the insertion of the quadratus femoris muscle), to reduce the risk of demineralization of the proximal femur [31,32] and proximal loosening of uncemented femoral stems [33]. Although the transosseous repair of the short external rotators (inferior and superior gemelli, obturator internus and obturator externus) has been recommended to increase internal rotational stability of the hip [12,13,16], we believe it to be ineffective as it is not very functional [34-36], given that the frailty of the muscle tissue makes a strong stitch anchorage impossible [34,37]. In our experience, the cases of coxa profunda, diffuse coxarthrosis, hip dysplasia with a well-

centered femoral head and the use of dual-mobility prostheses are not limiting factors in the use of this approach.

5. Conclusion

The positioning of the implants, especially acetabular cups [28,38,39], the diameter of the prosthetic femoral head [40] and the anatomical restoration of femoral offset [41] limit the risk of dislocation of THA performed via the posterior approach [42]. However, insufficient or no repair of the posterior capsular plane combined with the dissection of two powerful muscles of the lateral rotator group (quadratus femoris and piriformis), remains just as damaging [28], and contributes to perpetuating the poor reputation regarding dislocation of Moore's posterolateral approach. The main appeal of the SPARTAQUUS technique is that it combines a capsular flap that can be properly sutured with sparing of the piriformis muscle, thus producing a hammock that is both passive and active, in the posterosuperior aspect of the hip joint; the real area of weakness in the posterior dislocation of a THA.

Disclosure of interest: The authors declare to have no conflicts of interest related to this article. Unrelated to this work, RG is a consultant for Ceraver Osteal, Protheos Ouest and Newclip Technics. CL is a consultant for Ceraver Osteal, Stryker and Newclip Technics.

Funding: This research has received no specific grant from any funding agency in the public, commercial, or not-for-profit sectors.

Author Contributions: RG conceived the study and was responsible for the procedures and their assessment, as well as the acquisition and analysis of data. CL conceived the study,

designed the technique, and participated in the drafting and final revision of the manuscript. JS directed and edited the surgical video.

References

- [1] Higgins BT, Barlow DR, Heagerty NE, Lin TJ. Anterior vs. posterior approach for total hip arthroplasty, a systematic review and meta-analysis. *J Arthroplasty* 2015;30:419-34.
- [2] Daas den A, Reitsma EA, Knobben BAS, Have Ten BLEF, Somford MP. Patient satisfaction in different approaches for total hip arthroplasty. *Orthop Traumatol Surg Res* 2019;105:1277-82.
- [3] Jia F, Guo B, Xu F, Hou Y, Tang X, Huang L. A comparison of clinical, radiographic and surgical outcomes of total hip arthroplasty between direct anterior and posterior approaches: a systematic review and meta-analysis. *Hip Int* 2019;29(6):584-96.
- [4] Bon G, Kacem EB, Lepretre PM, Weissland T, Mertl P, Dehl M, et al. Does the direct anterior approach allow earlier recovery of walking following total hip arthroplasty? A randomized prospective trial using accelerometry. *Orthop Traumatol Surg Res* 2019;105:445-52.
- [5] Woo RY, Morrey BF. Dislocations after total hip arthroplasty. *J Bone Joint Surg Am* 1982;64:1295-306.
- [6] Masonis JL, Bourne RB. Surgical approach, abductor function, and total hip arthroplasty dislocation. *Clin Orthop Relat Res* 2002:46-53.
- [7] Waddell J, Johnson K, Hein W, Raabe J, FitzGerald G, Turibio F. Orthopaedic practice in total hip arthroplasty and total knee arthroplasty: results from the Global Orthopaedic Registry (GLORY). *Am J Orthop* 2010;39:5-13.
- [8] Barrett WP, Turner SE, Murphy JA, Flener JL, Alton TB. Prospective, Randomized Study of Direct Anterior Approach vs Posterolateral Approach Total Hip Arthroplasty: A Concise 5-Year Follow-Up Evaluation. *J Arthroplasty* 2019; 34(6):1139-1142.
- [9] Chechik O, Khashan M, Lador R, Salai M, Amar E. Surgical approach and prosthesis fixation in hip arthroplasty world wide. *Arch Orthop Trauma Surg* 2013;133:1595-600.
- [10] Kwon MS, Kuskowski M, Mulhall KJ, Macaulay W, Brown TE, Saleh KJ. Does

- surgical approach affect total hip arthroplasty dislocation rates? *Clin Orthop Relat Res* 2006;447:34-8.
- [11] Weeden SH, Paprosky WG, Bowling JW. The early dislocation rate in primary total hip arthroplasty following the posterior approach with posterior soft-tissue repair. *J Arthroplasty* 2003;18:709-13.
- [12] Sioen W, Simon JP, Labey L, Van Audekercke R. Posterior transosseous capsulotendinous repair in total hip arthroplasty : a cadaver study. *J Bone Joint Surg Am* 2002;84-A:1793-8.
- [13] Mihalko WM, Whiteside LA. Hip mechanics after posterior structure repair in total hip arthroplasty. *Clin Orthop Relat Res* 2004:194-8.
- [14] Sioen W, Meermans G, Lenaert A. Surgical technique description : Transosseous “over the top” reconstruction of capsule and tendons in primary total hip arthroplasty using a posterior approach. *Acta Orthop Belg* 2017;83:87-92.
- [15] Fink B, Mittelstaedt A, Schulz MS, Sebena P, Singer J. Comparison of a minimally invasive posterior approach and the standard posterior approach for total hip arthroplasty A prospective and comparative study. *J Orthop Surg Res* 2010;5:46.
- [16] Khan RJK, Fick D, Khoo P, Yao F, Nivbrant B, Wood D. Less invasive total hip arthroplasty: description of a new technique. *J Arthroplasty* 2006;21:1038-46.
- [17] Moore AT. The self-locking metal hip prosthesis. *J Bone Joint Surg Am* 1957;39-A:811-27.
- [18] Gérard R, Lefèvre C, Stindel E, et al. Une "autre façon" d'aborder l'articulation coxo-fémorale par voie postéro-latérale. In: Dubrana F, Lefèvre C, Le Nen D, editors. *Trucs et astuces en chirurgie orthopédique et traumatologie. Tome 3 Montpellier: Éd. Sauramps Médical; 2004. p 361-366.*
- [19] Delaunay C, Epinette J-A, Dawson J, Murray D, Jolles B-M. Cross-cultural adaptations of the Oxford-12 HIP score to the French speaking population. *Orthop Traumatol Surg Res* 2009;95:89-99.
- [20] Merle D'Aubigné R. [Numerical classification of the function of the hip. 1970]. *Rev Chir Orthop Reparatrice Appar Mot.* 1990;76(6):371-4.
- [21] Pine J, Binns M, Wright P, Soames R. Piriformis and obturator internus morphology: a cadaveric study. *Clin Anat* 2011;24:70-6.
- [22] Roche JJW, Jones CDS, Khan RJK, Yates PJ. The surgical anatomy of the piriformis tendon, with particular reference to total hip replacement: a cadaver study. *Bone Joint J* 2013;95-B:764-9.

- [23] Giphart JE, Stull JD, Laprade RF, Wahoff MS, Philippon MJ. Recruitment and activity of the pectineus and piriformis muscles during hip rehabilitation exercises: an electromyography study. *Am J Sports Med* 2012;40:1654-63.
- [24] Yoo S, Dedova I, Pather N. An appraisal of the short lateral rotators of the hip joint. *Clin Anat* 2015;28:800-12.
- [25] Lumley JSP, Craven JL, Aitken JT. *Essential anatomy and some clinical applications*. 4th ed. Edinburgh, New-York: Churchill Livingstone; 1987.
- [26] Chiu FY, Chen CM, Chung TY, Lo WH, Chen TH. The effect of posterior capsulorrhaphy in primary total hip arthroplasty: a prospective randomized study. *J Arthroplasty* 2000;15:194-9.
- [27] van Stralen GMJ, Struben PJ, van Loon CJM. The incidence of dislocation after primary total hip arthroplasty using posterior approach with posterior soft-tissue repair. *Arch Orthop Trauma Surg* 2003;123:219-22.
- [28] Fessy M-H, Putman S, Viste A, Isida R, Ramdane N, Ferreira A, et al. What are the risk factors for dislocation in primary total hip arthroplasty? A multicenter case-control study of 128 unstable and 438 stable hips. *Orthop Traumatol Surg Res* 2017;103:663-8.
- [29] Tan BKL, Khan RJK, Haebich SJ, Maor D, Blake EL, Bredahl WH. Piriformis-Sparing Minimally Invasive Versus the Standard Posterior Approach for Total Hip Arthroplasty: A 10-Year Follow-Up of a Randomized Control Trial. *J Arthroplasty* 2019;34:319-26.
- [30] Kao JT, Woolson ST. Piriformis tendon repair failure after total hip replacement. *Orthop Rev* 1992;21:171-4.
- [31] Sculco PK, Lazaro LE, Su EP, Klinger CE, Dyke JP, Helfet DL, et al. A Vessel-Preserving Surgical Hip Dislocation Through a Modified Posterior Approach: Assessment of Femoral Head Vascularity Using Gadolinium-Enhanced MRI. *J Bone Joint Surg Am* 2016;98:475-83.
- [32] ElMaraghy AW, Schemitsch EH, Waddell JP. Greater trochanteric blood flow during total hip arthroplasty using a posterior approach. *Clin Orthop Relat Res* 1999:151-7.
- [33] Hartog C, Metzler C, Meier C, Kalberer F, Wahl P. Anatomy of the lateral circumflex femoral artery: Does the direct anterior approach to the hip jeopardize vascularization of the proximal femur? *Orthop Traumatol Surg Res* 2019;105:1257-64.
- [34] Stähelin T, Drittenbass L, Hersche O, Miehle W, Munzinger U. Failure of capsular enhanced short external rotator repair after total hip replacement. *Clin Orthop Relat*

Res 2004;199-204.

- [35] Stähelin T, Vienne P, Hersche O. Failure of reinserted short external rotator muscles after total hip arthroplasty. *J Arthroplasty* 2002;17:604-7.
- [36] Su EP, Mahoney CR, Adler RS, Padgett DE, Pellicci PM. Integrity of Repaired Posterior Structures after THA. *Clin Orthop Relat Res* 2006;447:43-7.
- [37] Pellicci PM, Potter HG, Foo LF, Boettner F. MRI Shows Biologic Restoration of Posterior Soft Tissue Repairs after THA. *Clin Orthop Relat Res* 2008;467:940-5.
- [38] Reina N, Putman S, Desmarchelier R, Sari Ali E, Chiron P, Ollivier M, et al. Can a target zone safer than Lewinnek's safe zone be defined to prevent instability of total hip arthroplasties? Case-control study of 56 dislocated THA and 93 matched controls. *Orthop Traumatol Surg Res* 2017;103:657-61.
- [39] Danoff JR, Bobman JT, Cunn G, Murtaugh T, Gorroochurn P, Geller JA, et al. Redefining the Acetabular Component Safe Zone for Posterior Approach Total Hip Arthroplasty. *The Journal of Arthroplasty* 2016;31:506-11.
- [40] Allen CL, Hooper GJ, Frampton CMA. Do larger femoral heads improve the functional outcome in total hip arthroplasty ? *J Arthroplasty* 2014;29:401-4.
- [41] Lecerf G, Fessy M-H, Philippot R, Massin P, Giraud F, Flecher X, et al. Femoral offset: anatomical concept, definition, assessment, implications for preoperative templating and hip arthroplasty. *Orthop Traumatol Surg Res* 2009;95:210-9.
- [42] Yamaguchi T, Naito M, Asayama I, Ishiko T. Total hip arthroplasty: the relationship between posterolateral reconstruction, abductor muscle strength, and femoral offset. *J Orthop Surg (Hong Kong)* 2004;12:164-7.

Table 1: Results of a single-center, single-operator study (RG) of 296 total hip arthroplasties (THA), except in the case of trauma, performed using the SPARTAQUUS posterior approach with a surgical navigation system (Orthokey™, Florence, Italy), over a one-year period (2018).

Cases	296	
Age (years)	66 (36-85)	
Sex (F/M)	151/145	
Indication	Primary coxarthrosis	266
	Osteonecrosis	17
	Dysplasia	13
THA	Uncemented, CoC (heads Ø 28 mm/32 mm)	207 (39/168)
	Uncemented, dual-mobility, head Ø 28 mm	89
BMI	28.6 (22-40)	
OHS-12 (0-48) [19]	20.8 (13-27) preop	39.1 (32-46) 2M postop
PMA (0-18) [20]	11.7 (5-14) preop	16.2 (12-18) 2M postop
DVT	0	
Dislocation	0	
Postoperative LLI**	0 +/-1 mm (navigation)	
Acute infection	3	

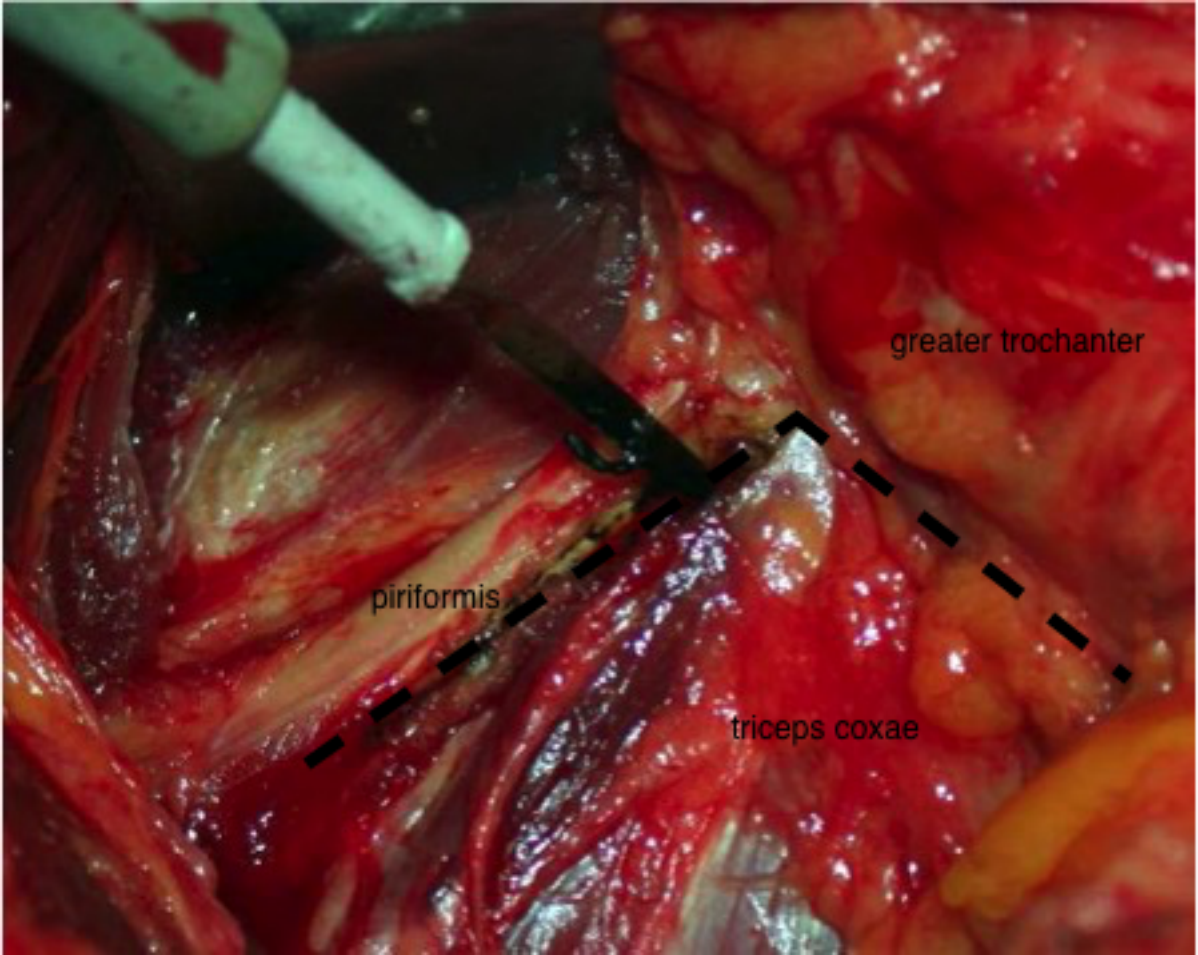
F: female; M: male; LLI: Leg length inequality; PMA: Postel Merle d'Aubigné score; DVT: deep vein thrombosis; IMC: body mass index; OHS-12: Oxford 12 Hip Score; CoC: ceramic-on-ceramic; 2M: 2nd month.

** We do not have all the millimeter data for the preoperative LLI. We only know that the correction target in terms of length and overall offset, if necessary, was restored in all cases (+/- 1 mm) thanks to the computer-assisted surgery we use for all our primary total hip arthroplasties.

Figure Legends

Figure 1: Operative view of the L-shaped incision of the lateral rotator group of muscles, sparing proximally the piriformis tendon and distally the quadratus femoris muscle. The capsulotomy will follow the same course.

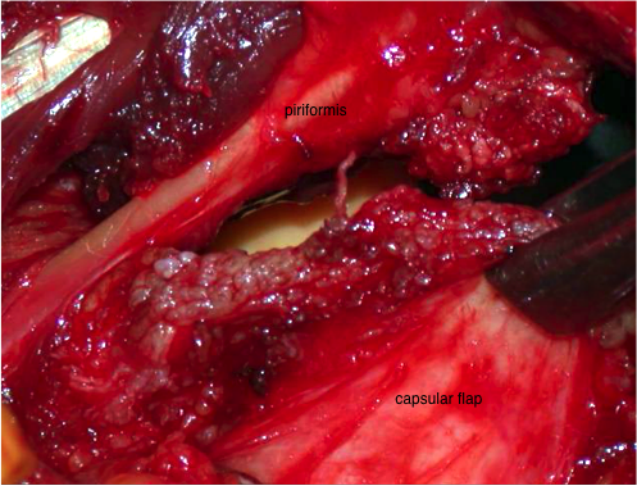
Figures 2 and 3: Operative view of the implanted total hip prosthesis and the posterosuperior corner of the SPARTAQUUS posterior approach involving the piriformis tendon and the posterior capsular flap before suturing.



greater trochanter

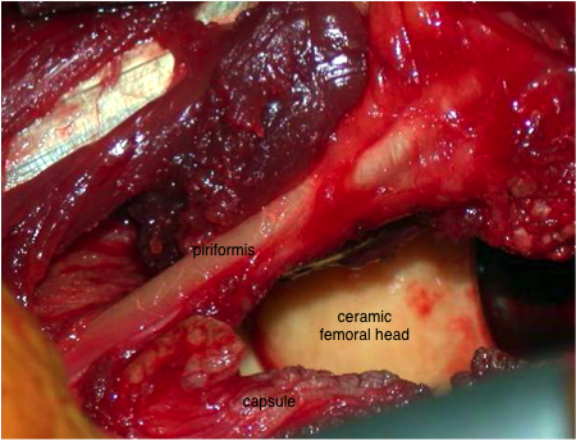
piriformis

triceps coxae



piriformis

capsular flap



piriformis

ceramic
femoral head

capsule