



# One-stage circumferential limb ring constriction release and direct circular skin closure in amniotic band syndrome: a 14-case series

Benjamin Dufournier, Stéphane Guero, Marine de Tienda, Caroline Dana, Nicolas Garcelon, Christophe Glorion, Arielle Salon, Stéphanie Pannier

## ► To cite this version:

Benjamin Dufournier, Stéphane Guero, Marine de Tienda, Caroline Dana, Nicolas Garcelon, et al.. One-stage circumferential limb ring constriction release and direct circular skin closure in amniotic band syndrome: a 14-case series. *Orthopaedics & Traumatology: Surgery & Research*, 2020, 106, pp.1353 - 1359. 10.1016/j.otsr.2020.06.009 . hal-03492677

**HAL Id: hal-03492677**

**<https://hal.science/hal-03492677>**

Submitted on 21 Nov 2022

**HAL** is a multi-disciplinary open access archive for the deposit and dissemination of scientific research documents, whether they are published or not. The documents may come from teaching and research institutions in France or abroad, or from public or private research centers.

L'archive ouverte pluridisciplinaire **HAL**, est destinée au dépôt et à la diffusion de documents scientifiques de niveau recherche, publiés ou non, émanant des établissements d'enseignement et de recherche français ou étrangers, des laboratoires publics ou privés.



Distributed under a Creative Commons Attribution - NonCommercial 4.0 International License

## TECHNICAL NOTE

### **One-stage circumferential limb ring constriction release and direct circular skin closure in amniotic band syndrome: a 14-case series.**

Benjamin **Dufournier**<sup>1</sup>, Stéphane **Guero**<sup>1,2</sup>, Marine **de Tienda**<sup>1</sup>, Caroline **Dana**<sup>1,3</sup>, Nicolas **Garcelon**<sup>4</sup>, Christophe **Glorion**<sup>1</sup>, Arielle **Salon**<sup>1,3</sup>, Stéphanie **Pannier**<sup>1</sup>

<sup>1</sup> Service de Chirurgie Orthopédique Pédiatrique, Université de Paris, Hôpital Necker- Enfants Malades, APHP, Paris, France.

<sup>2</sup> Clinique Marcel Sembat, Boulogne, France

<sup>3</sup> Clinique Saint Jean de Dieu, Paris, France

<sup>4</sup> Institut Imagine, INSERM, UMR 1138 Equipe 22, Université de Paris, France

#### **Corresponding author:**

Benjamin Dufournier

[benjamindufournier@gmail.com](mailto:benjamindufournier@gmail.com)

## **ABSTRACT**

### **Introduction**

The aim of the present study was to report results of direct circular suture after 1-stage circumferential resection of limb ring constriction in amniotic band syndrome.

### **Methods**

A multicenter retrospective study included 14 patients with amniotic band syndrome (mean age, 13.3 months) operated on between 2004 and 2019 by circumferential release of  $\geq 1$  ring constriction. Assessment was based on limb function and clinical scar aspect on the POSAS and Vancouver scales.

### **Results:**

Mean follow-up was 3.9 years. There were no scar-related, vascular or neurologic complications, postoperatively or at last follow-up. POSAS and Vancouver scores were satisfactory.

### **Conclusion**

One-stage circumferential release with direct closure is a simple technique that provides satisfactory functional and esthetic results.

**Keywords:** Amniotic Band Syndrome, Constriction ring, Z-plasty

## **Introduction**

Amniotic band syndrome involves constriction rings mainly developing in the limbs (Figure 1), with amputations and acrosyndactyly [1].

Treatment is surgical, usually by 1- or 2-stage resection by Z or WY plasty [2-3]. Two-stage strategies were the rule [4] to avoid jeopardizing distal segment vascularization and prevent necrosis around the scar. During growth, the saw-tooth scar tends to become an esthetic blemish (Figure 2).

The aim of the present study was to report esthetic and functional results of 1-stage circumferential release with direct skin closure.

## **Material and methods**

The inclusion criteria in this multicenter retrospective study comprised 1-stage direct circumferential release of  $\geq 1$  ring constriction in the limbs performed between 2004 and 2019. Semicircumferential resection and finger or toe locations were excluded, for homogeneity.

Fourteen patients were included: 7 girls, 7 boys; mean age at surgery, 13.3 months (range, 0-32.8 months). Seventeen constriction rings were resected: 2 upper and 15 lower limb (Table 1).

## **Surgical technique**

Except in case of severe lymphedema requiring emergency treatment, circumferential rerelease was scheduled after 6 months of age, to limit anesthesia-related risk.

Skin marking was performed to avoid soft-tissue rotational disorder. Resection was at least 0.5 cm from the constriction ring, and circumferential (Figure 3). It was systematically complete, including deep scar tissue with fascia superficialis, respecting neurovascular and musculotendinous structures. Excess skin was conserved for possible grafting in case of associated acrosyndactyly release. Deep release of the edges between fat tissue and fascia facilitated mobilization. Closure was performed without tension, with a few approximating sutures in the hypodermis following the skin marking and two intradermal hemi-sutures (Figure 4). Silicone interface dressing and compresses were applied, and changed on postoperative day 7. Postoperative care at home included massaging the scar to make it more supple and prevent adherence.

## **Postoperative assessment**

Assessment was based on limb function according to psychomotor development, scar aspect and complications. Scar quality and overall satisfaction were assessed on the Patient and Observer Scar Assessment Scale (POSAS) [5] (Figure 5) and Vancouver scale [6].

## **Ethical considerations**

The study adhered to the Declaration of Helsinki. Parents and patients received detailed information.

## Results

Ten of the 14 patients were contacted or followed up in consultation (Figures 6-8). Mean follow-up was 3.9 years {range, 0.5-15 years}. Any preoperative lymphedema was systematically removed. All 3 patients with neurologic deficit recovered if the corresponding muscles were present. No other scar-related, vascular or neurologic complications occurred. There were no cases of upper or lower limb growth disorder. One patient was operated on for ipsilateral club-foot some time after ring constriction release. Two patients showed limp at 2 years' follow-up, due to absence of the triceps in 1 case and to congenital tibial curvature in the other (Table 1).

POSAS and Vancouver scores were satisfactory (Table 2).

## Discussion

Ring constriction treatment is surgical in case of functional impact or severe lymphedema. Two-stage Z or WY plasties were widely used, to conserve distal segment vascularization and avoid lymphatic problems [4].

One-stage release is made possible by distal segment skin vascularization, mainly by musculocutaneous arteries, protecting against secondary necrosis [7,8]. It has the advantage of avoiding repeat anesthesia and painful postoperative care. It also has the economic advantage of a lower hospital admission rate.

The present study had several limitations: selection based on historic computer-file data, lack of any reproducible functional assessment scale for children, and loss to follow-up.

## Conclusion

The present technique is esthetically and functionally very promising for children with amniotic band syndrome. One-stage release improves comfort for patient and family, without vascular risk.

## Communication

The study was presented as a free communication at the 2019 Congress of the French Society of Orthopedic Surgery and Traumatology (SoFCOT) and 2019 Hand Study Group (GEM) Congress.

## Disclosure of interest

The authors have no conflicts of interest to disclose.

## Funding

The present study received no specific funding from any public-sector, private-sector or non-profit body.

## Author contributions

Data collection and analysis: Benjamin Dufournier and Stéphanie Pannier

Study design: Stéphanie Pannier and Christophe Glorion

Article writing: Benjamin Dufournier, Marine de Tienda, Stéphane Guero, Arielle Salon, Caroline Dana, Nicolas Garcelon, Christophe Glorion and Stéphanie Pannier

## References

1. Patterson T.J.S. Congenital ring-constrictions. *Br J Plast Surg.* 1961;14:1–31.
2. Greene WB. One-stage release of congenital circumferential constriction bands. *J Bone Joint Surg Am.* 1993;75:650–5.
3. Upton J, Tan C. Correction of constriction rings. *J Hand Surg Am.* 1991;16:947–53.
4. Stevenson TW. Release of circular constricting scar by Z flaps. *Plast Reconstr Surg.* 1946;1:39–42
5. Van de Kar AL, Corion LU, Smeulders MJ, Draaijers LJ, van der Horst CM, van Zuijlen PP. Reliable and feasible evaluation of linear scars by the Patient and Observer Scar Assessment Scale. *Plast Reconstr Surg.* 2005;116(2):514-22
6. Draaijers LJ, Tempelman FR, Botman YA, Tuinebreijer WE, Middelkoop E, Kreis RW, et al. The patient and observer scar assessment scale: a reliable and feasible tool for scar evaluation. *Plast Reconstr Surg.* 2004;113:1960-5
7. Prasetyono TO, Sitorus AS. A Review on the Safety of One-Stage Circumferential Ring Constriction Release. *Int Surg.* 2015;100:341–9.
8. Habenicht R, Hülsemann W, Lohmeyer JA, Mann M. Ten-year experience with one-step correction of constriction rings by complete circular resection and linear circumferential skin closure. *J Plast Reconstr Aesthet Surg.* 2013;66:1117–22

Case	Gender	Age at surgery (months)	Follow-up (years)	Location	Involvement			Complications	Progression
					lymphedema	neurologic	particularities		
1	F	30.4	7.3	arm	-	-		-	
2	F	18.3	3.3	thigh	-	-		-	
				lower leg	-	-		-	
3	M	32.8	4.1	lower leg	-	-		-	
				lower leg	-	-		-	
4	M	3.7	1.4	lower leg	+	-		-	
5	F	22	3.1	lower leg	-	2/5 extension, foot and ankle	absence of triceps	-	4/5 extension, foot and ankle
6	M	12.9	3	lower leg	-	-	club-foot	-	
7	M	12.1	1	lower leg	-	2/5 extension, foot and ankle	congenital tibial curvature	-	5/5 extension, foot and ankle
8	M	5.6	3.7	lower leg	+	-		-	
9	F	5.3	1	lower leg	-	-		-	
10	M	0	4	lower leg	+	-		-	
11	F	23.2	15	lower leg	-	-		-	
				lower leg	-	-		-	
12	F	3.76	1	lower leg	-	-		-	
13	M	2.1	0.5	arm	+	0/5 flexion, elbow		-	5/5 flexion, elbow
14	F	12.3	1.6	lower leg	-	-		-	

Table 1: Series data

POSAS		
	Mean / 60	General opinion /10
Observer	13.9	2.7
Patient	14.9	3.3
VANCOUVER		
	Mean /13	
Observer	3.6	

Table 2: Vancouver scale and POSAS results.



## Figures

Figure 1: Three-month-old girl (Case 12) with ring constriction of lower third of the lower leg (A-B).

Figure 2: Z-scar aspect at 2 years (A-B) (Collection S. GUERO).

Figure 3: Circumferential resection after skin landmarking (A-B) in the patient shown in Figure 1. Ring aspect after release (C-D).

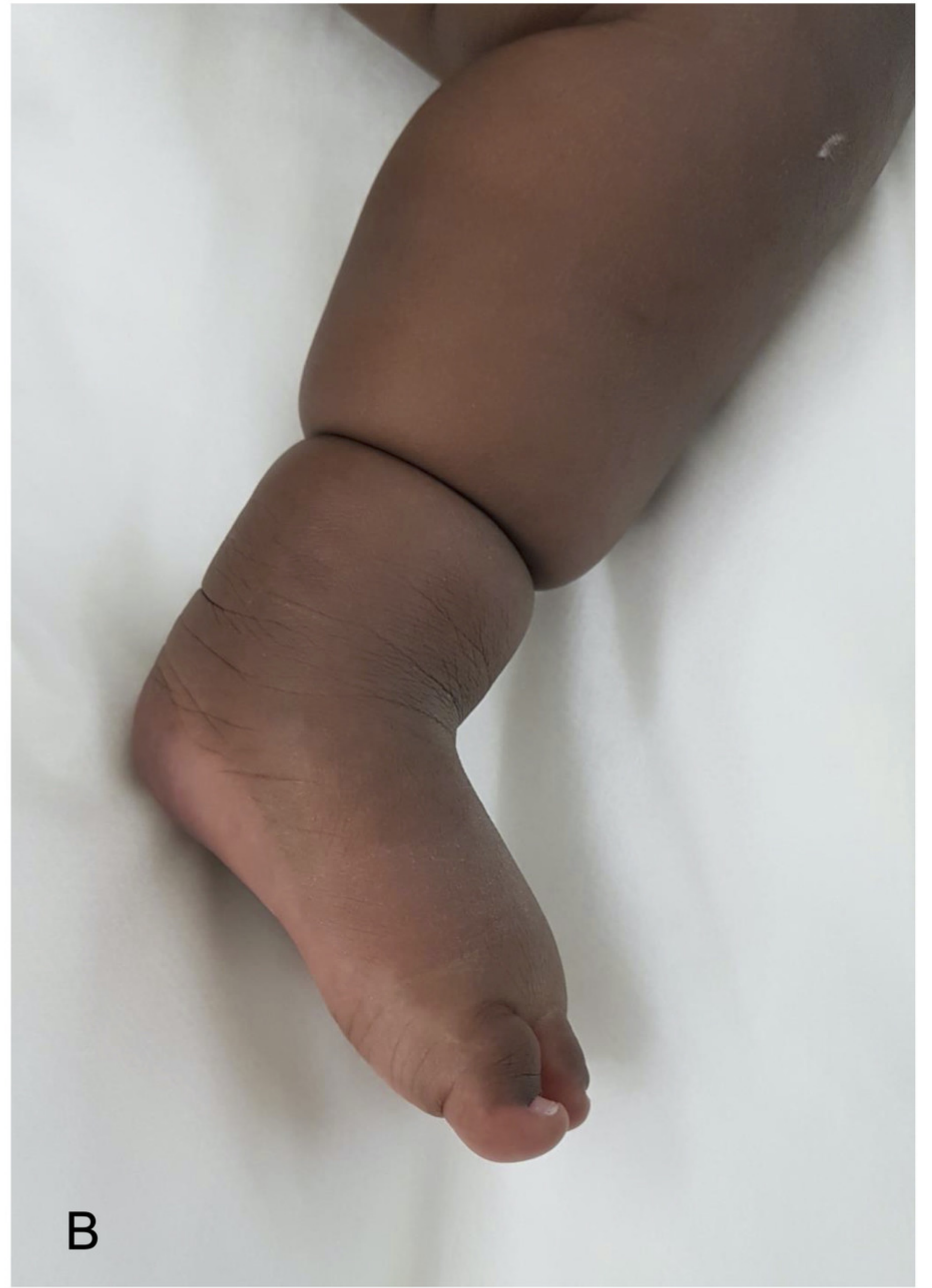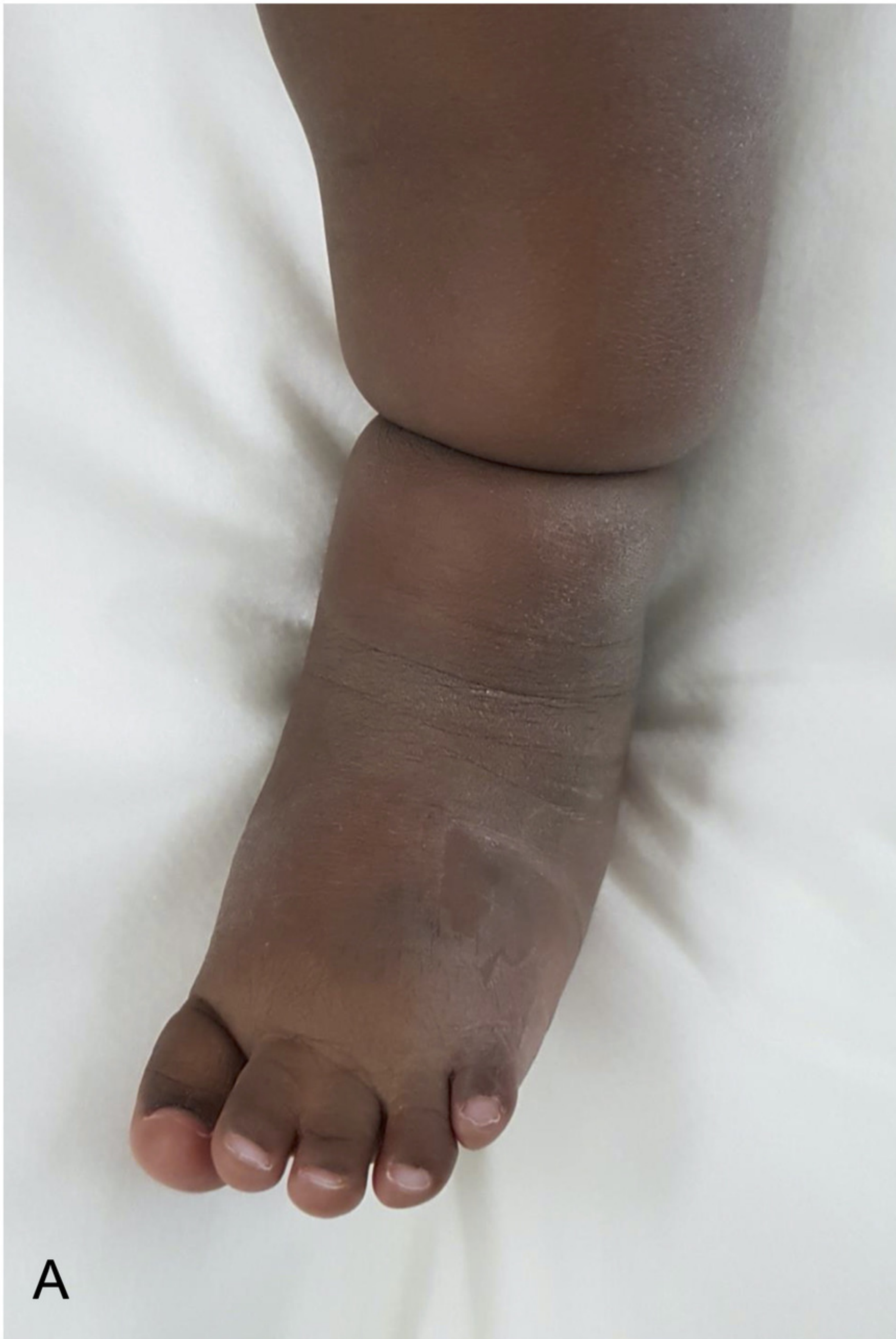Figure 4: Day-8 postoperative aspect in the patient shown in Figures 1 and 3 (A-B).

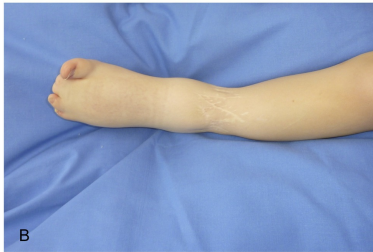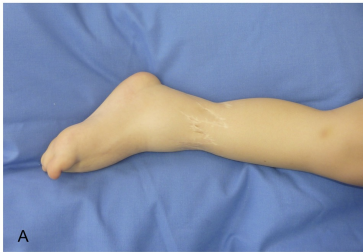Figure 5: POSAS forms for observer (A) and child and parents (B). *Copyright © Prof. Dr. Paul van Zuijlen. All rights reserved*

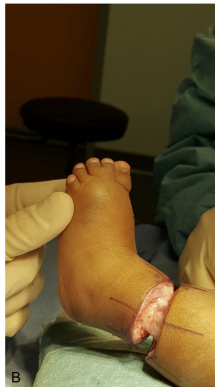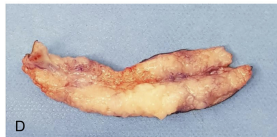
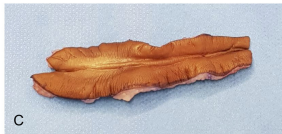
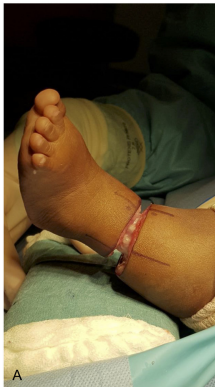Figure 6: Two-year old (Case 11) with ring constriction of left lower leg (A); circumferential resection with direct suture (B-C); clinical aspect at 4 years (D), 6 years (E) and 15 years (F). (Collection S. GUERO).

Figure 7: Seven-year aspect of right constriction ring of the upper arm operated on at the age of 2 years (Case 1) (A-B).

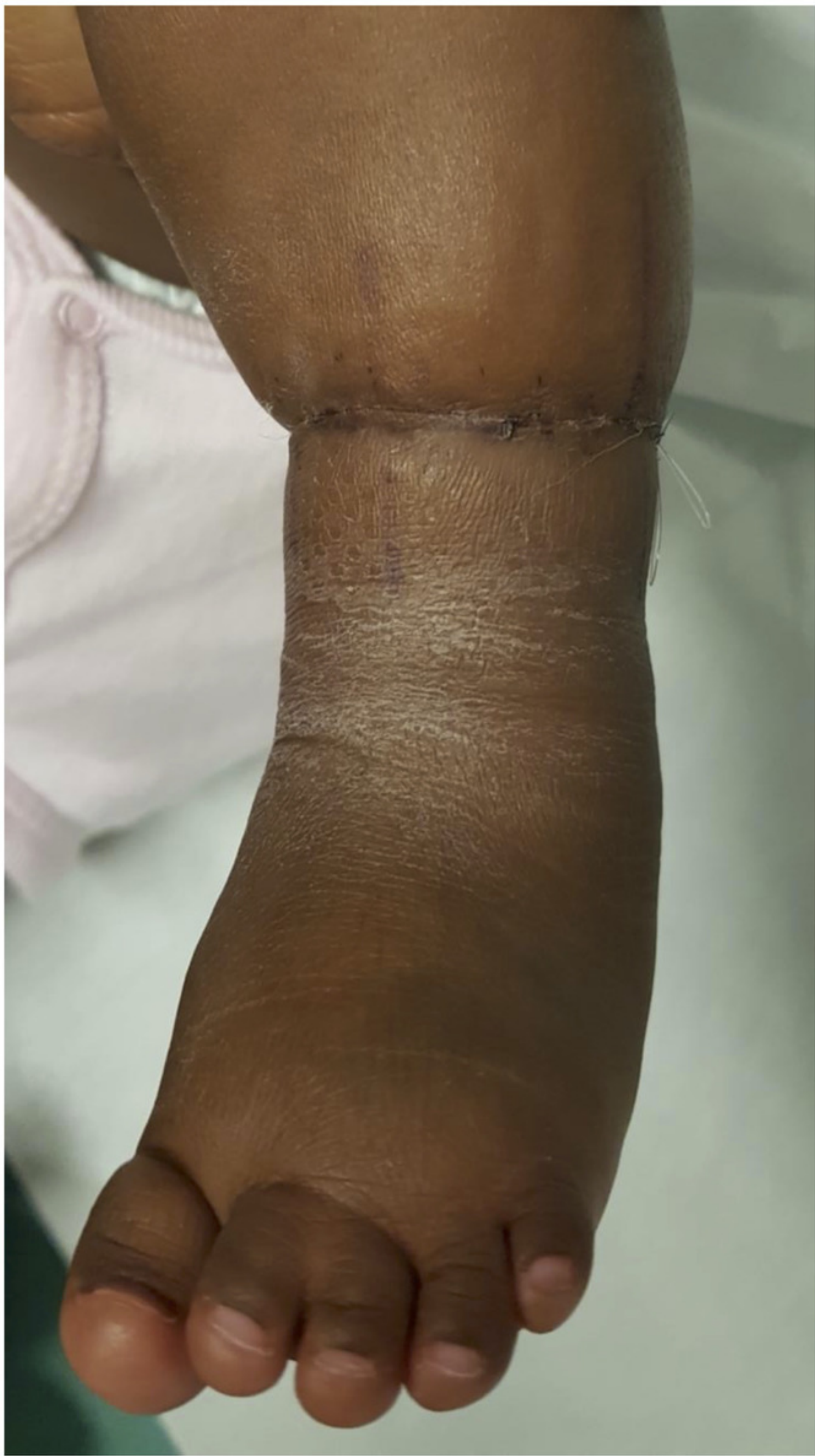Figure 8: Two-year old (Case 5) with ring constriction of lower third of the right lower leg with absence of triceps and initial 2/5 foot levator deficit (A-B). Clinical aspect at 3 years (C-D).



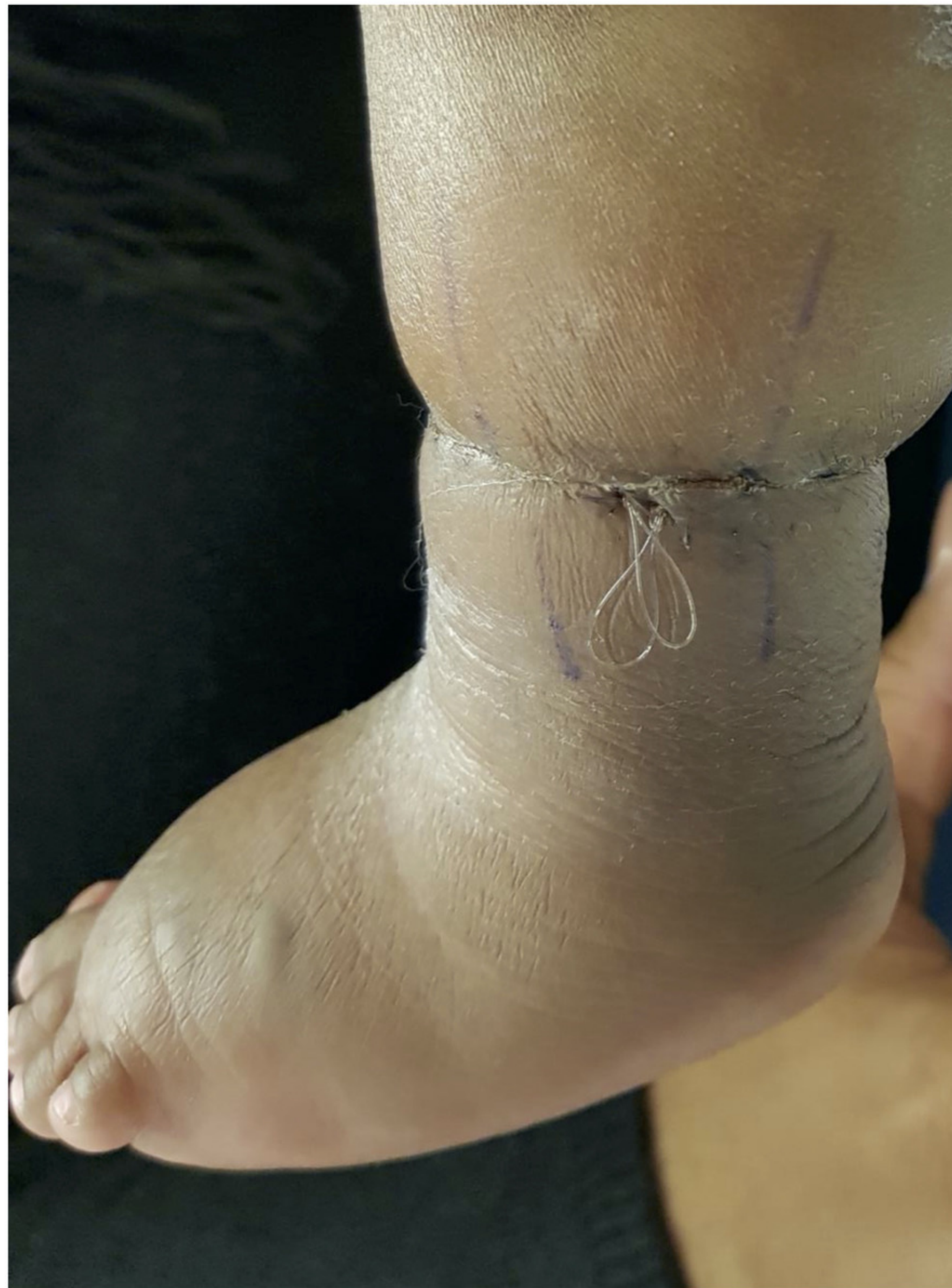







A



B



# POSAS Observer scale

The Patient and Observer Scar Assessment Scale v2.0 / EN

Date of examination:

Observer:

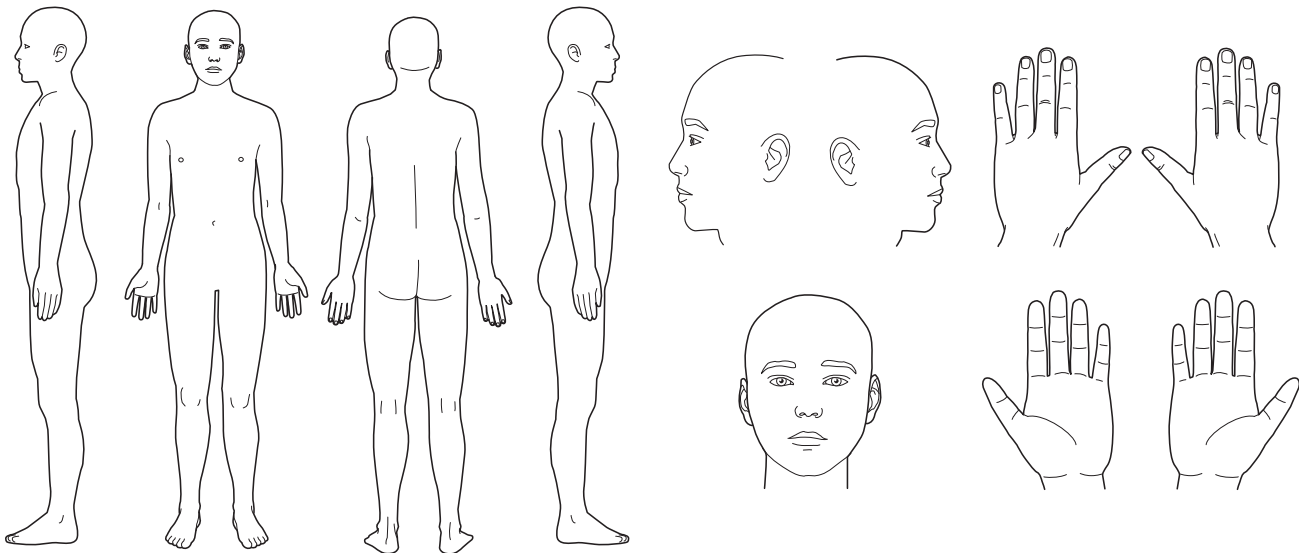
Location:

Research / study:

Name of patient:

Date of birth:

Identification number:



1 = normal skin      worst scar imaginable = 10

PARAMETER	1	2	3	4	5	6	7	8	9	10	CATEGORY
VASCULARITY	<input type="radio"/>	<input type="radio"/>	<input type="radio"/>	<input type="radio"/>	<input type="radio"/>	<input type="radio"/>	<input type="radio"/>	<input type="radio"/>	<input type="radio"/>	<input type="radio"/>	PALE   PINK   RED   PURPLE   MIX
PIGMENTATION	<input type="radio"/>	<input type="radio"/>	<input type="radio"/>	<input type="radio"/>	<input type="radio"/>	<input type="radio"/>	<input type="radio"/>	<input type="radio"/>	<input type="radio"/>	<input type="radio"/>	HYPO   HYPER   MIX
THICKNESS	<input type="radio"/>	<input type="radio"/>	<input type="radio"/>	<input type="radio"/>	<input type="radio"/>	<input type="radio"/>	<input type="radio"/>	<input type="radio"/>	<input type="radio"/>	<input type="radio"/>	THICKER   THINNER
RELIEF	<input type="radio"/>	<input type="radio"/>	<input type="radio"/>	<input type="radio"/>	<input type="radio"/>	<input type="radio"/>	<input type="radio"/>	<input type="radio"/>	<input type="radio"/>	<input type="radio"/>	MORE   LESS   MIX
PLIABILITY	<input type="radio"/>	<input type="radio"/>	<input type="radio"/>	<input type="radio"/>	<input type="radio"/>	<input type="radio"/>	<input type="radio"/>	<input type="radio"/>	<input type="radio"/>	<input type="radio"/>	SUPPLE   STIFF   MIX
SURFACE AREA	<input type="radio"/>	<input type="radio"/>	<input type="radio"/>	<input type="radio"/>	<input type="radio"/>	<input type="radio"/>	<input type="radio"/>	<input type="radio"/>	<input type="radio"/>	<input type="radio"/>	EXPANSION   CONTRACTION   MIX
OVERALL OPINION	<input type="radio"/>	<input type="radio"/>	<input type="radio"/>	<input type="radio"/>	<input type="radio"/>	<input type="radio"/>	<input type="radio"/>	<input type="radio"/>	<input type="radio"/>	<input type="radio"/>	

### Explanation

The observer scale of the POSAS consists of six items (vascularity, pigmentation, thickness, relief, pliability and surface area). All items are scored on a scale ranging from 1 ('like normal skin') to 10 ('worst scar imaginable'). The sum of the six items results in a total score of the POSAS observer scale. Categories boxes are added for each item. Furthermore, an overall opinion is scored on a scale ranging from 1 to 10. All parameters should preferably be compared to normal skin on a comparable anatomic location.

### Explanatory notes on the items:

- VASCULARITY** Presence of vessels in scar tissue assessed by the amount of redness, tested by the amount of blood return after blanching with a piece of Plexiglas
- PIGMENTATION** Brownish coloration of the scar by pigment (melanin); apply Plexiglas to the skin with moderate pressure to eliminate the effect of vascularity
- THICKNESS** Average distance between the subcutical-dermal border and the epidermal surface of the scar
- RELIEF** The extent to which surface irregularities are present (preferably compared with adjacent normal skin)
- PLIABILITY** Suppleness of the scar tested by wrinkling the scar between the thumb and index finger
- SURFACE AREA** Surface area of the scar in relation to the original wound area

# POSAS Patient scale

The Patient and Observer Scar Assessment Scale v2.0 / EN

Date of examination:

Observer:

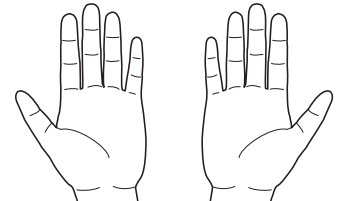
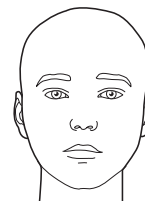
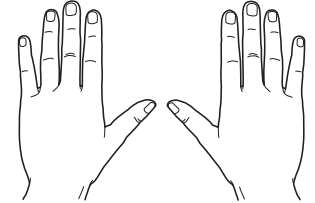

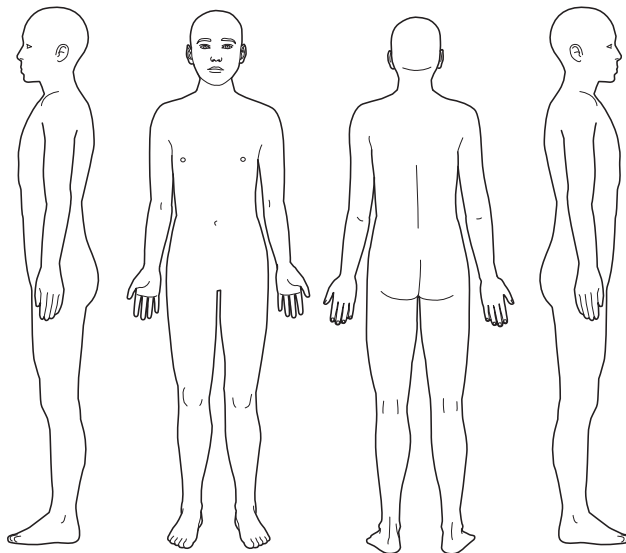
Location:

Research / study:

Name of patient:

Date of birth:

Identification number:



1 = no, not at all

yes, very much = 10

1 2 3 4 5 6 7 8 9 10

HAS THE SCAR BEEN PAINFUL THE PAST FEW WEEKS?

☐☐☐☐☐☐☐☐☐☐

HAS THE SCAR BEEN ITCHING THE PAST FEW WEEKS?

☐☐☐☐☐☐☐☐☐☐

1 = no, as normal skin

yes, very different = 10

1 2 3 4 5 6 7 8 9 10

IS THE SCAR COLOR DIFFERENT FROM THE COLOR OF YOUR NORMAL SKIN AT PRESENT?

☐☐☐☐☐☐☐☐☐☐

IS THE STIFFNESS OF THE SCAR DIFFERENT FROM YOUR NORMAL SKIN AT PRESENT?

☐☐☐☐☐☐☐☐☐☐

IS THE THICKNESS OF THE SCAR DIFFERENT FROM YOUR NORMAL SKIN AT PRESENT?

☐☐☐☐☐☐☐☐☐☐

IS THE SCAR MORE IRREGULAR THAN YOUR NORMAL SKIN AT PRESENT?

☐☐☐☐☐☐☐☐☐☐

1 = as normal skin

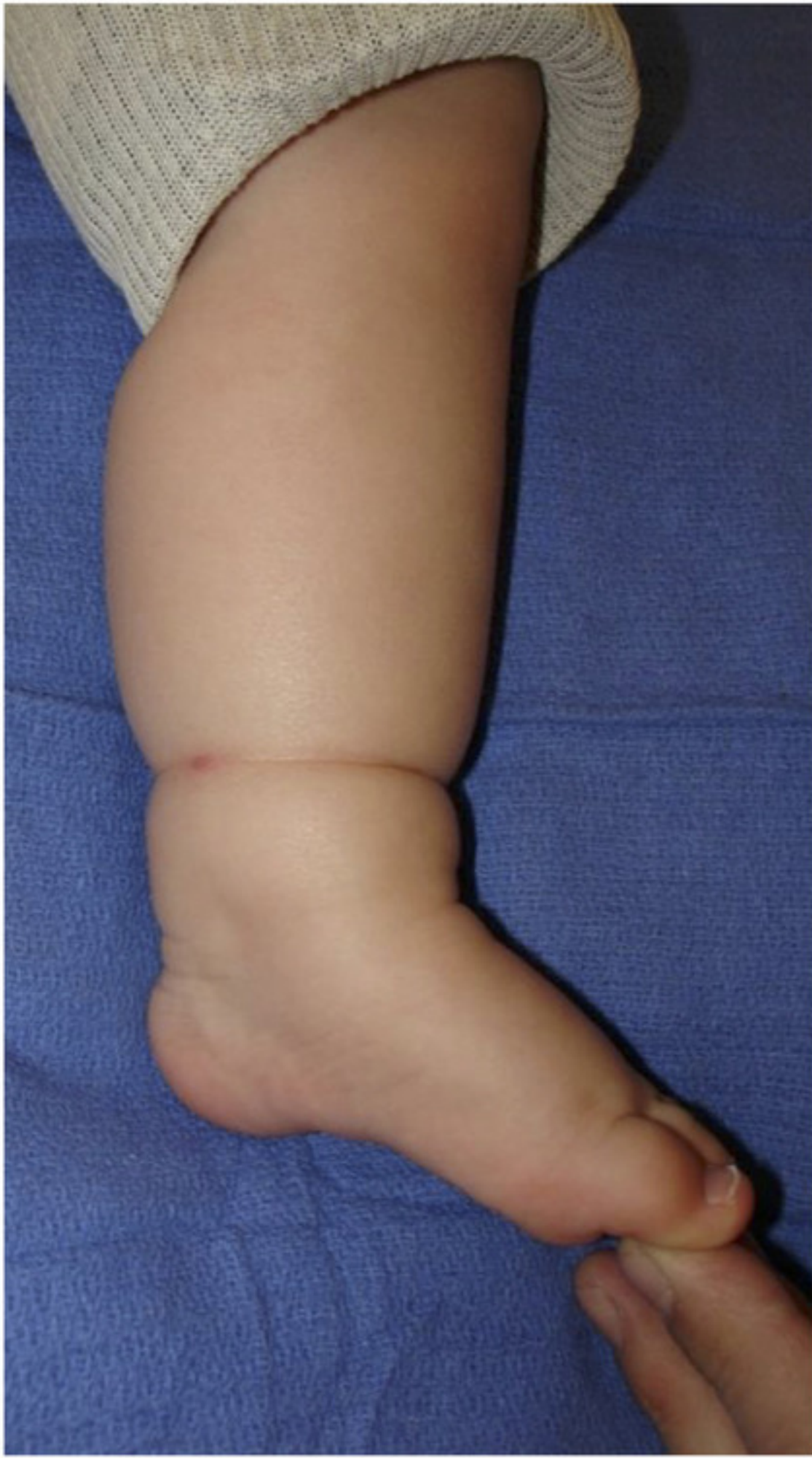very different = 10

1 2 3 4 5 6 7 8 9 10

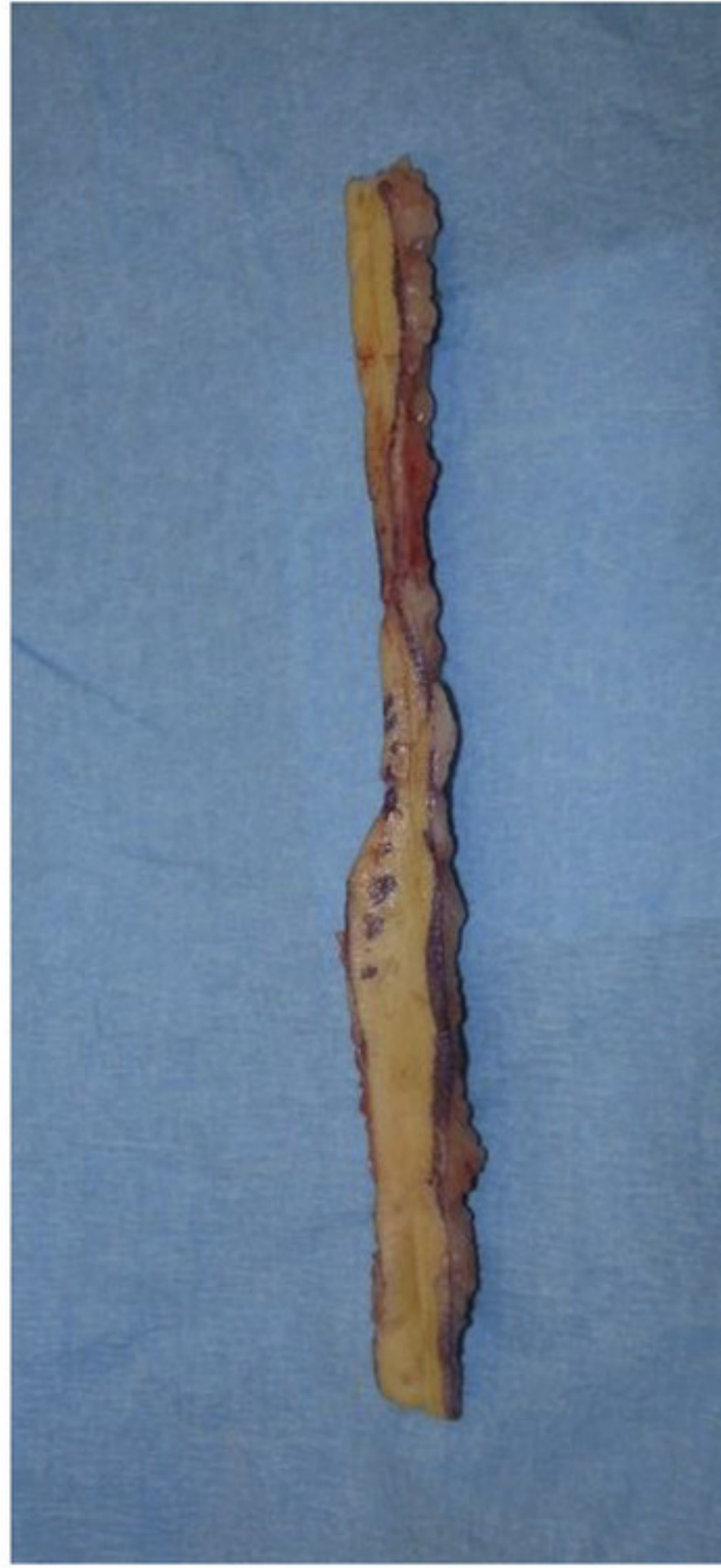WHAT IS YOUR OVERALL OPINION OF THE SCAR COMPARED TO NORMAL SKIN?

☐☐☐☐☐☐☐☐☐☐

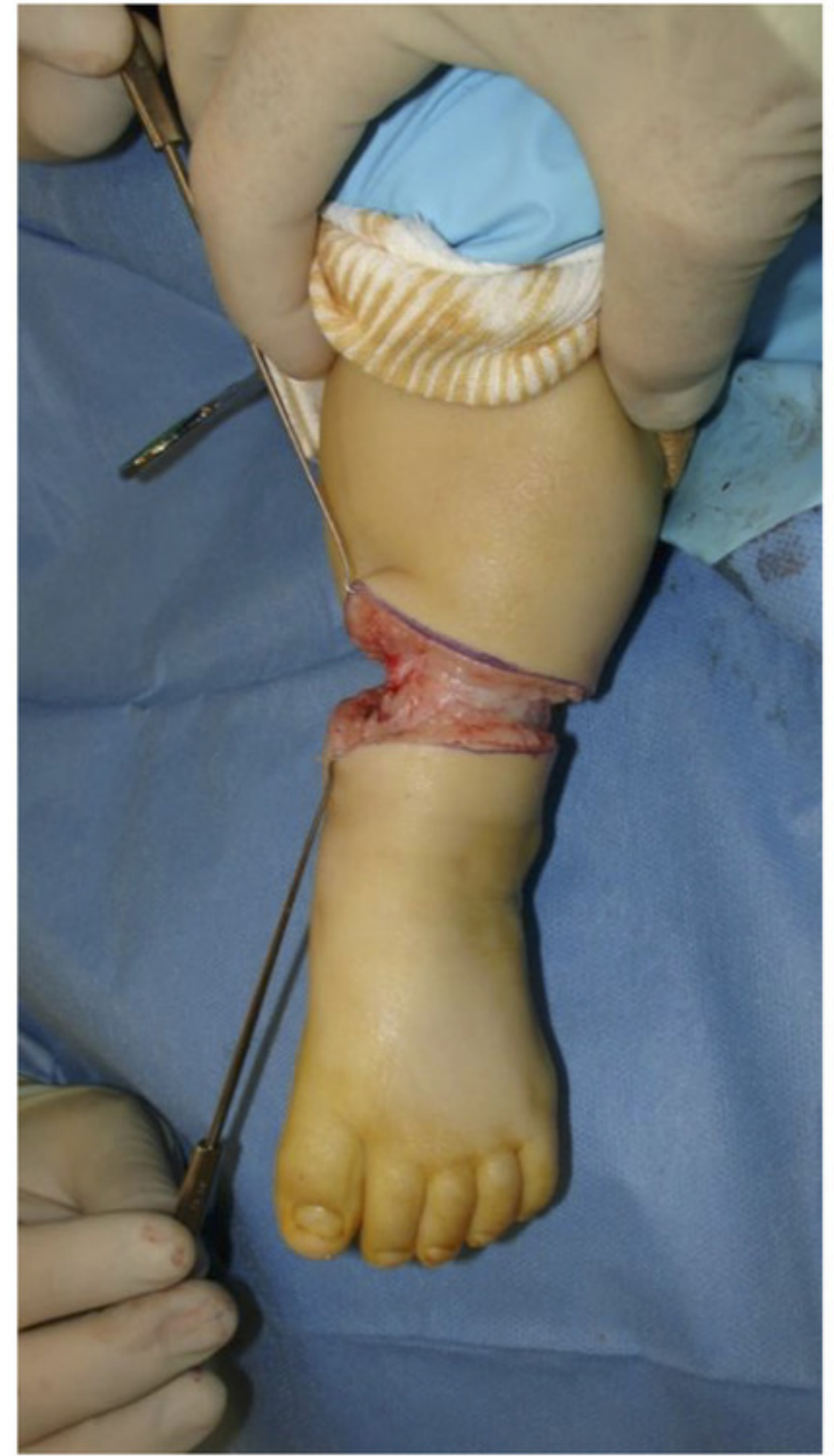



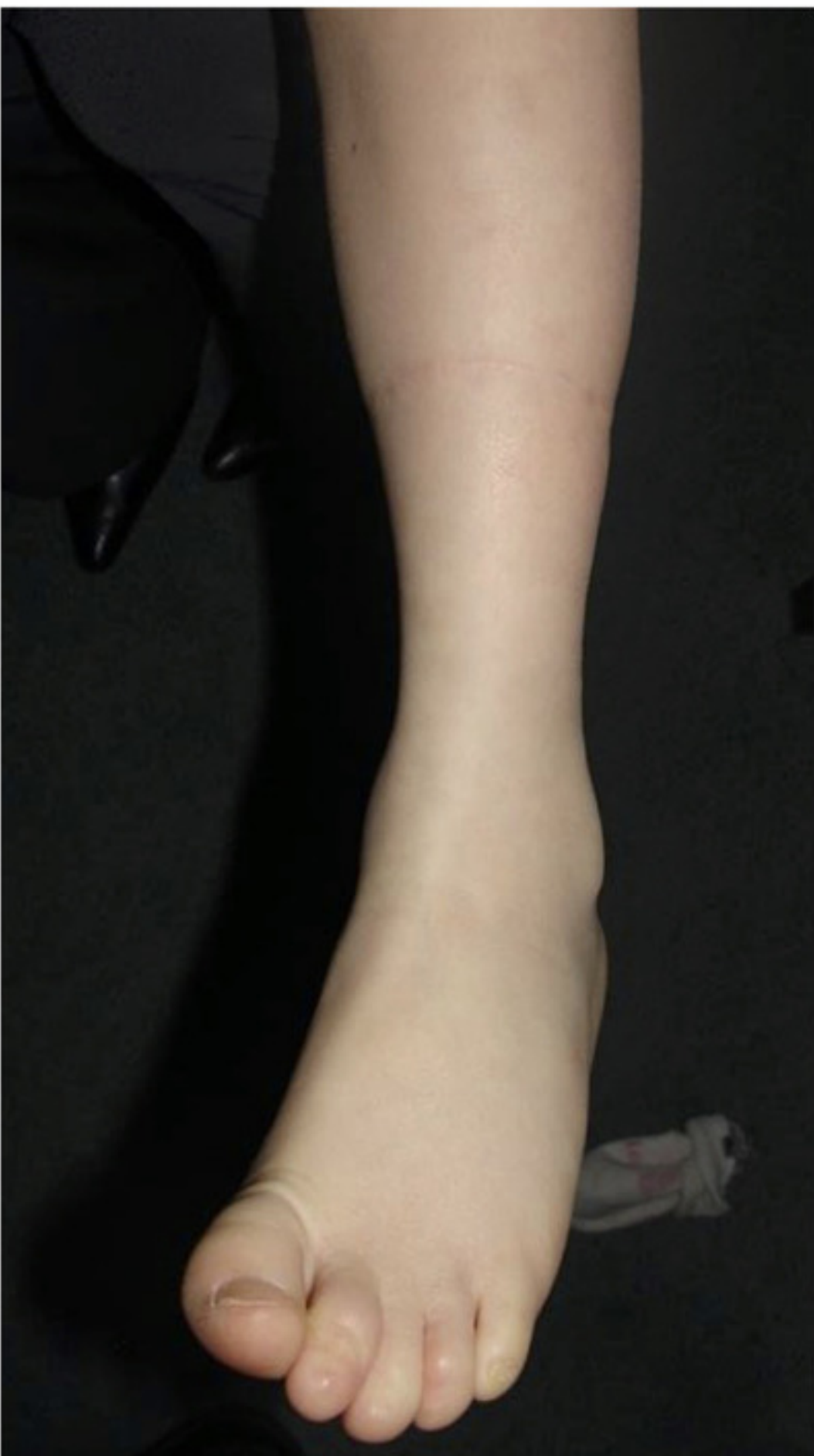A



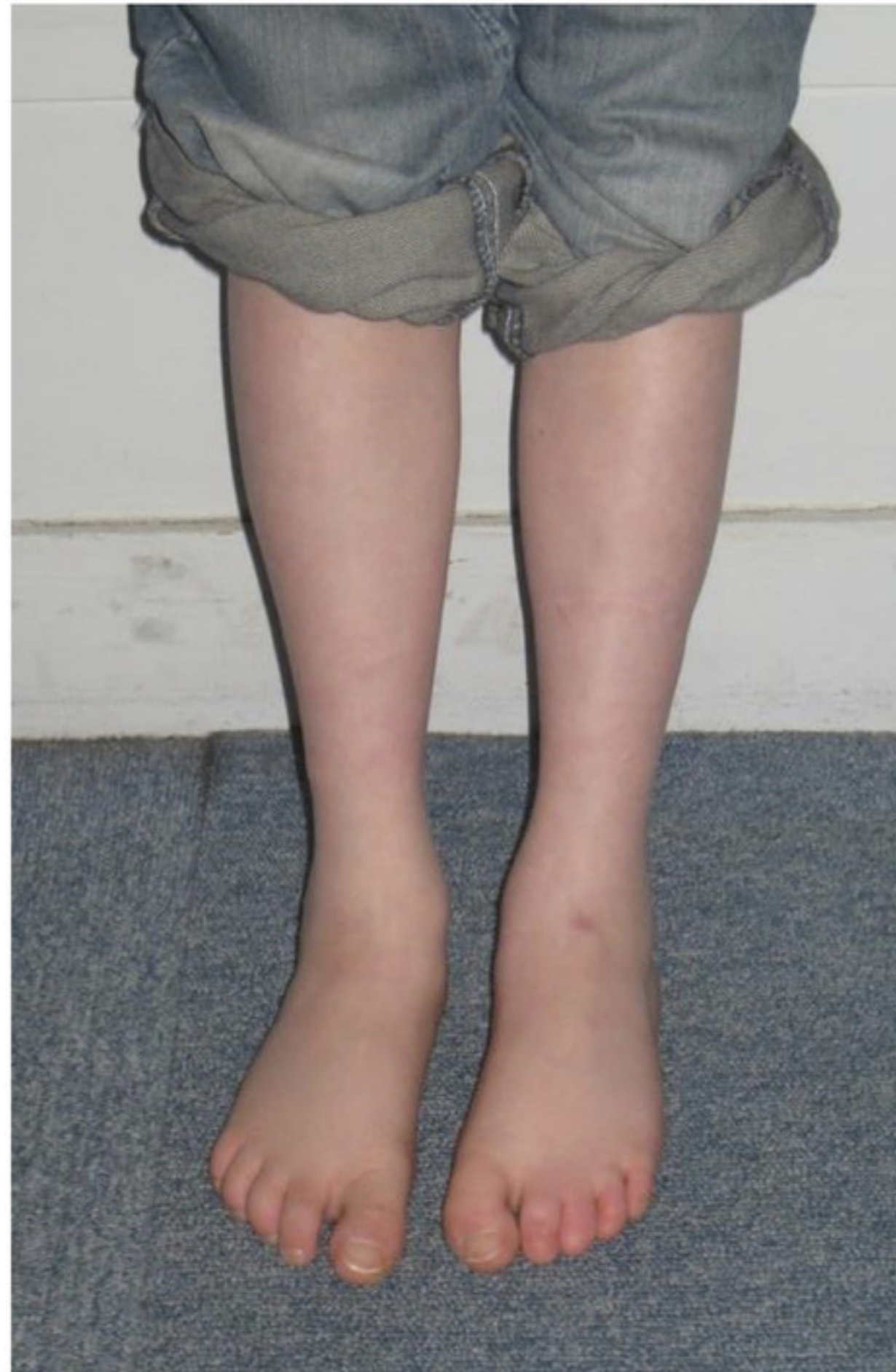B



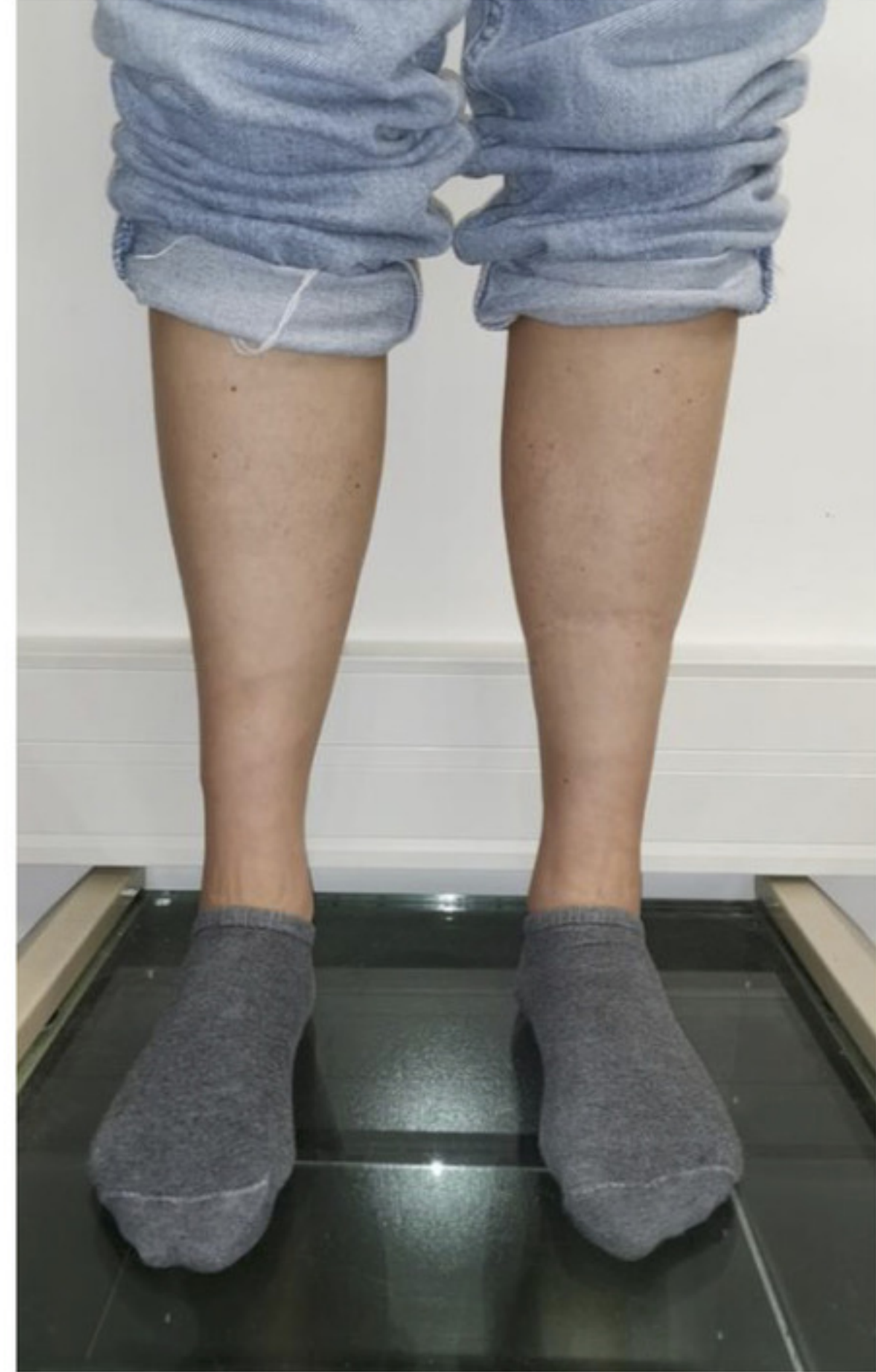C



D

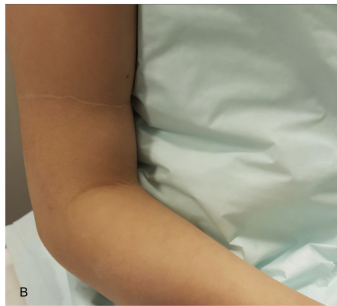
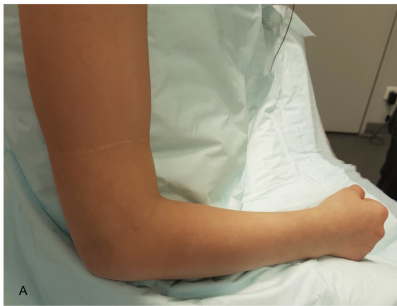

E

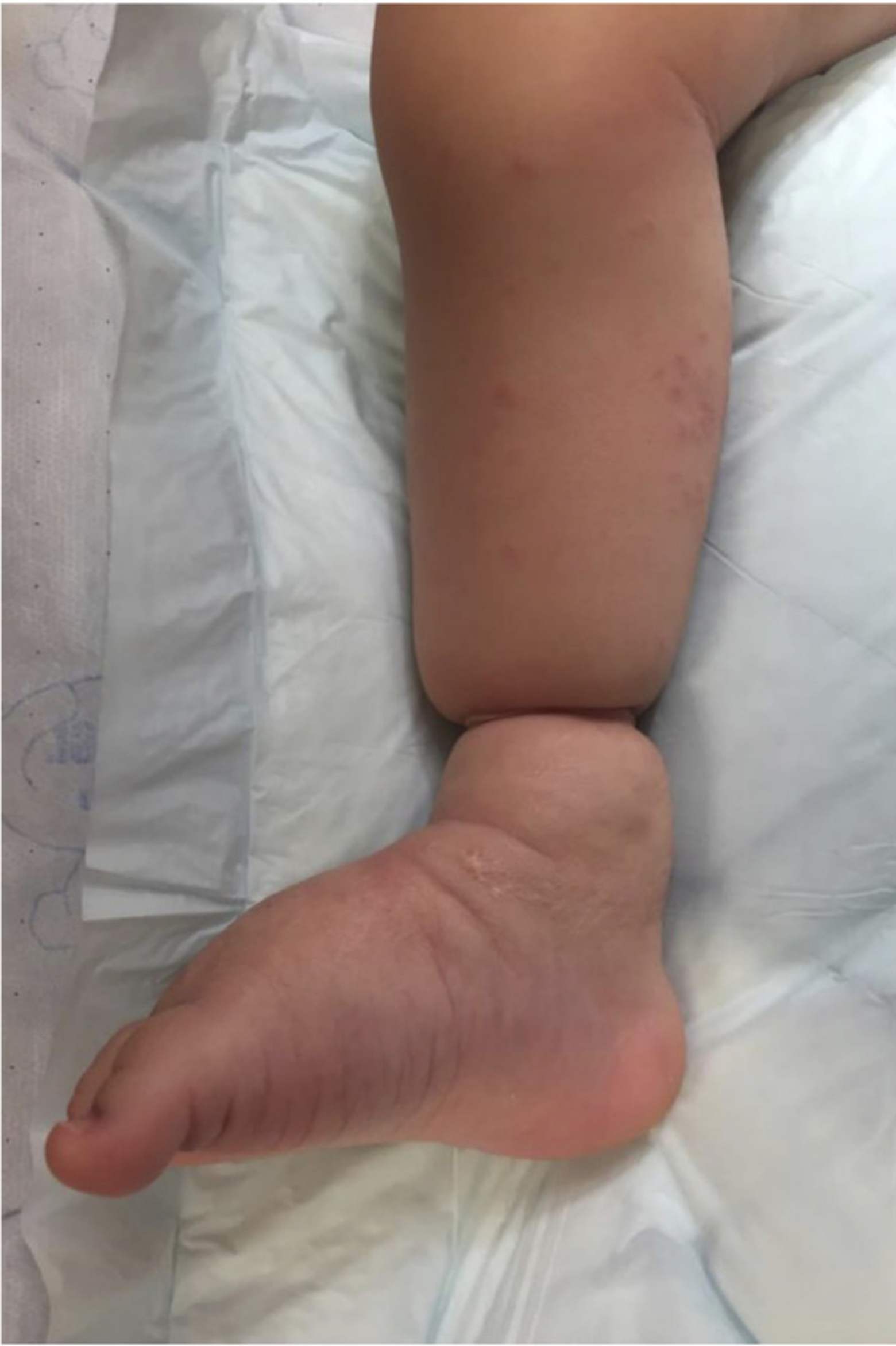

F

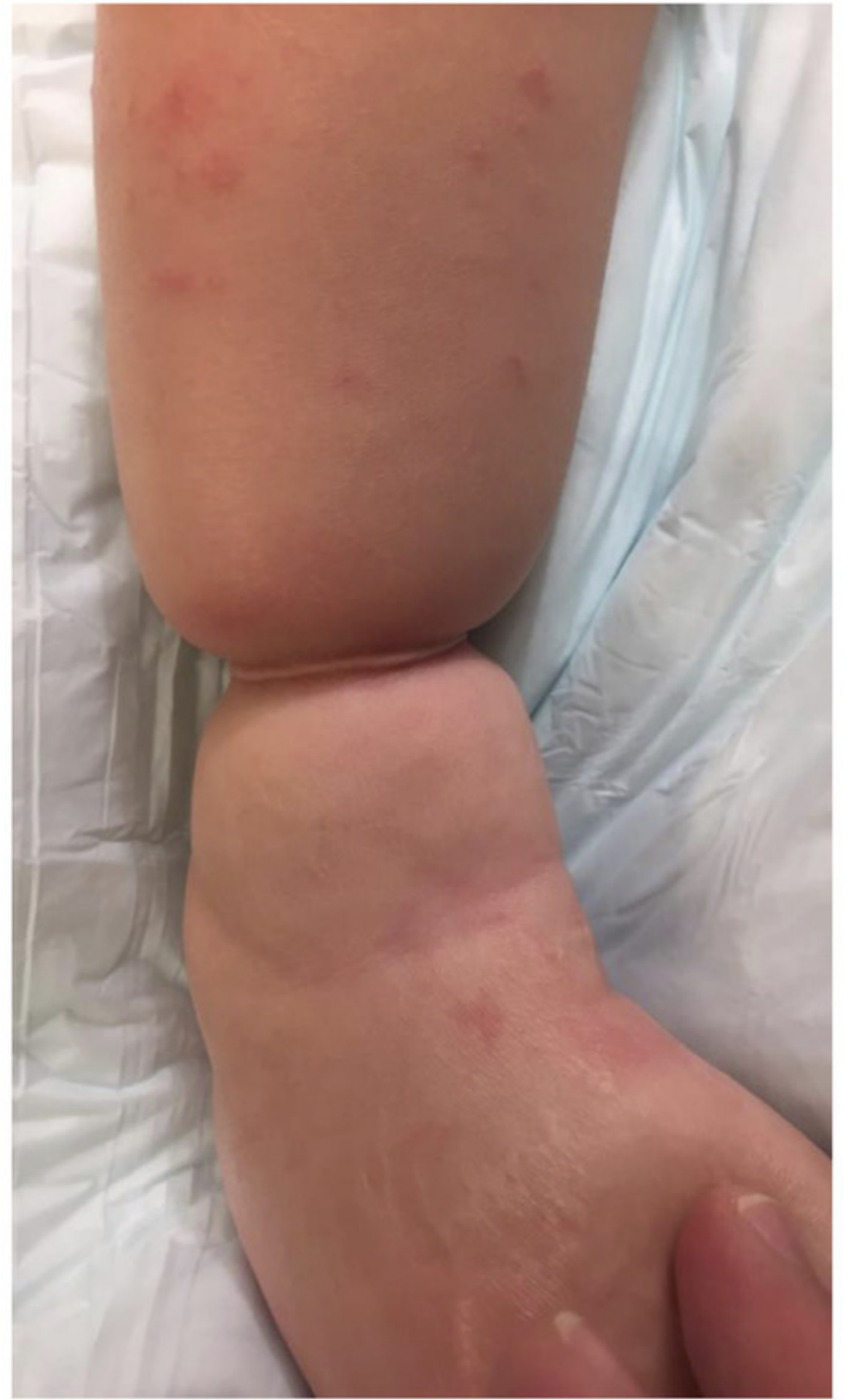




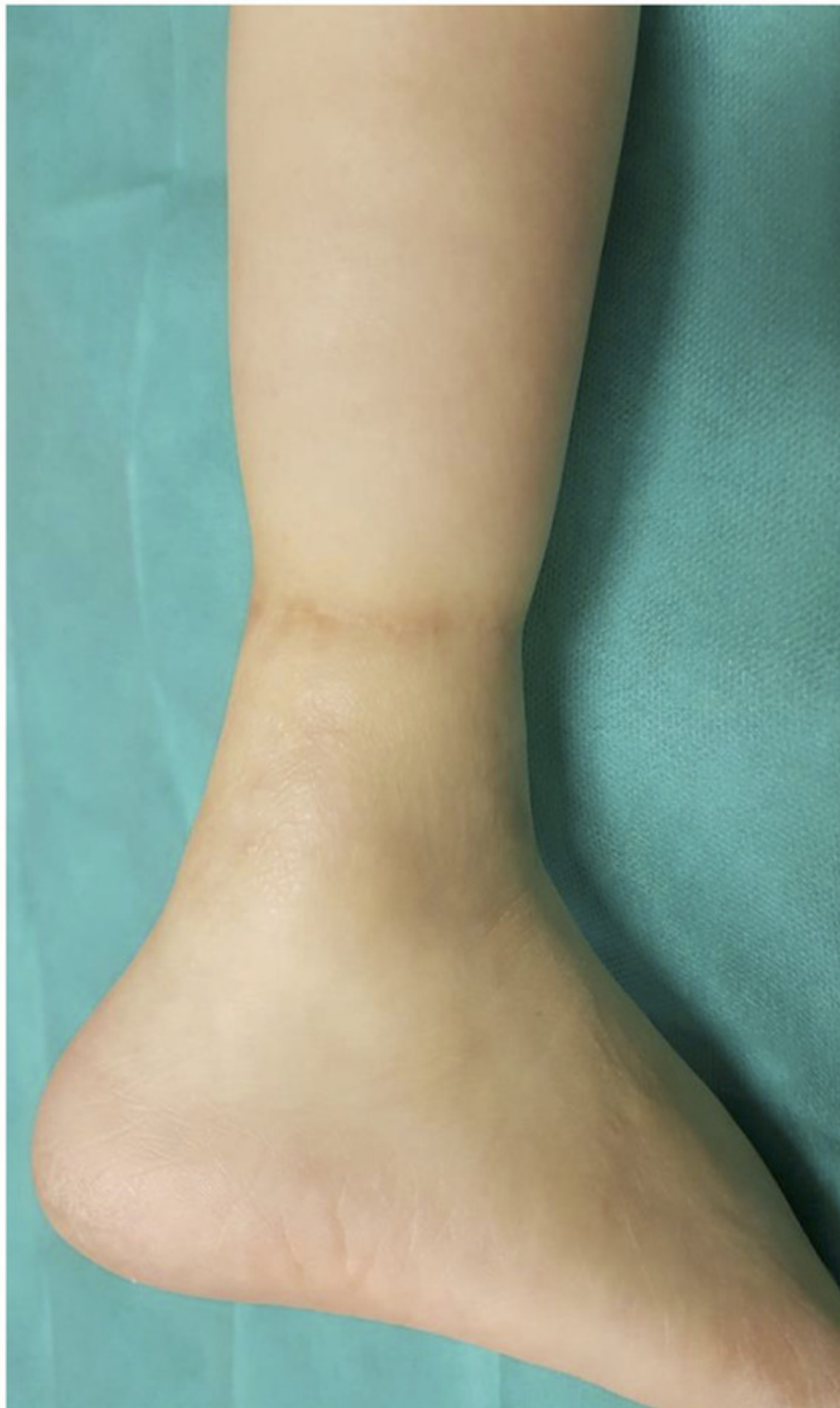


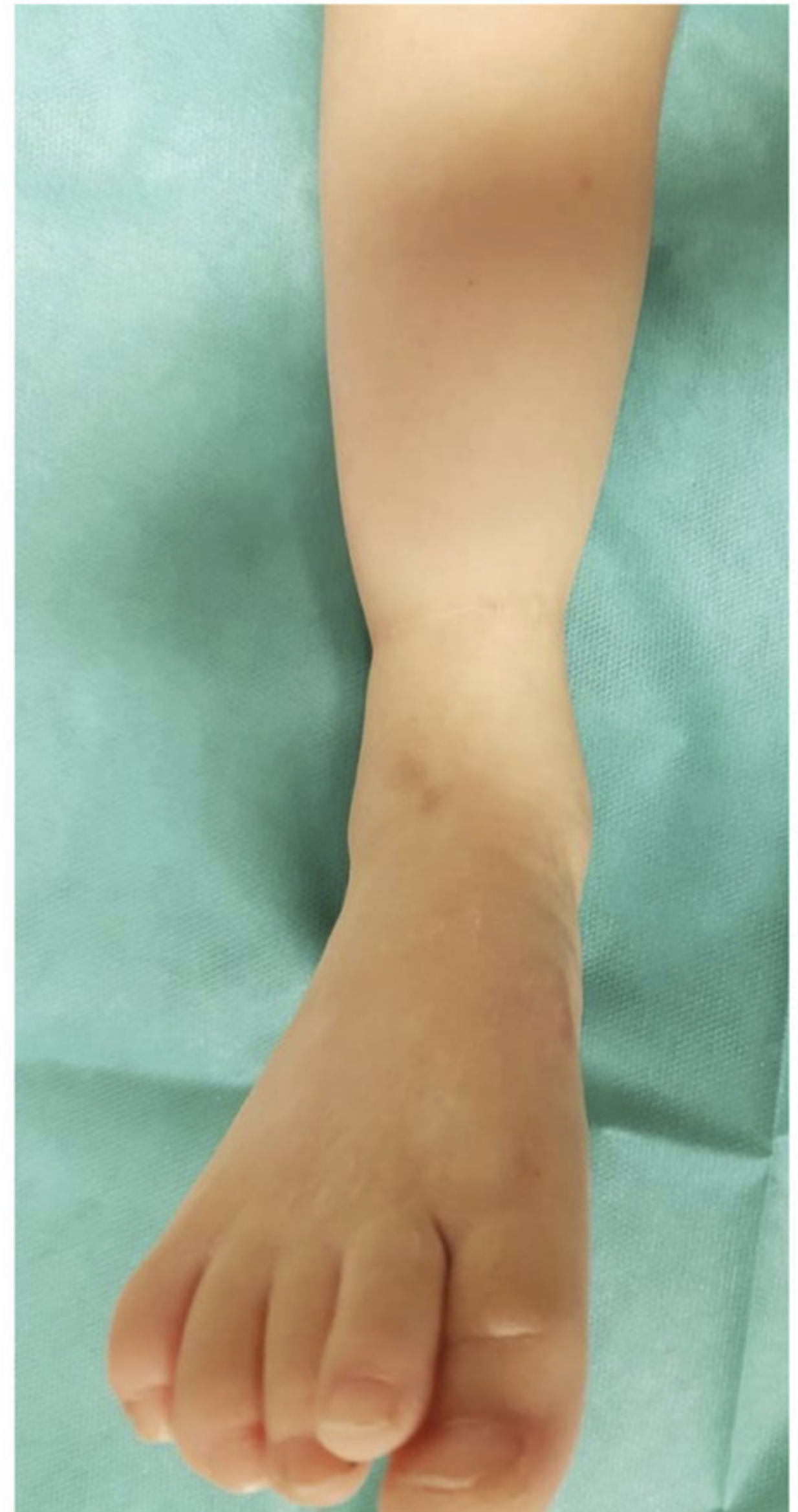A



B



C



D