



HAL
open science

Combined Single Lung and Liver Transplantation in a Cystic Fibrosis Patient With Previous Contralateral Pneumonectomy: A Case Report

Gaetane Roquet, Jean Michel Maury, Jean Yves Mabrut, Claire Flamens, Agathe Senechal, Jean François Mornex, François Tronc

► **To cite this version:**

Gaetane Roquet, Jean Michel Maury, Jean Yves Mabrut, Claire Flamens, Agathe Senechal, et al.. Combined Single Lung and Liver Transplantation in a Cystic Fibrosis Patient With Previous Contralateral Pneumonectomy: A Case Report. *Transplantation Proceedings*, 2020, 52, pp.2820 - 2823. 10.1016/j.transproceed.2020.08.036 . hal-03492671

HAL Id: hal-03492671

<https://hal.science/hal-03492671>

Submitted on 7 Nov 2022

HAL is a multi-disciplinary open access archive for the deposit and dissemination of scientific research documents, whether they are published or not. The documents may come from teaching and research institutions in France or abroad, or from public or private research centers.

L'archive ouverte pluridisciplinaire **HAL**, est destinée au dépôt et à la diffusion de documents scientifiques de niveau recherche, publiés ou non, émanant des établissements d'enseignement et de recherche français ou étrangers, des laboratoires publics ou privés.



Distributed under a Creative Commons Attribution - NonCommercial 4.0 International License

Combined single-lung and liver transplantation in a cystic fibrosis patient with previous contralateral pneumonectomy: A Case Report

Gaetane Roquet MD¹, Jean Michel Maury MD, PhD¹, Jean Yves Mabrut MD, PhD², Claire Flamens MD³, Agathe Senechal MD⁴, Jean François Mornex MD, PhD⁴, François Tronc MD, PhD¹

¹ Department of Thoracic Surgery and Lung Transplantation, Louis Pradel Hospital, Hospices Civils de Lyon, F-69677, Lyon, France

² Department of General Surgery and Liver Transplantation, Hospices Civils de Lyon, Croix Rousse University Hospital, Claude-Bernard Lyon 1 University, Lyon, France

³ Department of Anesthesiology and Critical Care, Louis Pradel Hospital, Hospices Civils de Lyon, F-69677, Lyon, France

⁴ Department of Pneumology, Louis Pradel Hospital, Hospices Civils de Lyon, F-69677, Lyon, France

Corresponding author:

François Tronc

Service de Chirurgie Thoracique

Hôpital Louis Pradel

F-69500 Bron Cedex, France

Phone: +33 0 (0) 472357464 Fax: +33 0 (0) 472357323

francois.tronc@chu-lyon.fr

ABSTRACT

Combined lung-liver transplantation is a rare life-saving procedure to treat concomitant lung and liver end stage failure. In this report, we describe the first published case of single lung-liver transplantation in a cystic fibrosis patient who had previously a pneumonectomy for the treatment of an infected and destroyed right lung. We detail the lung first sequential transplant procedure and surgical difficulties due to mediastinal shift. Emergent intra operative renal replacement therapy was decided before liver transplantation to overcome pulmonary oedema in the transplanted lung. After fluid balance equilibration, liver transplantation was performed in good conditions. The patient is currently alive with no signs of rejection 8 years after the procedure.

Keywords: Cystic fibrosis, Pneumonectomy, Combined lung-liver transplantation, dialysis.

INTRODUCTION

Cystic fibrosis is the most common life threatening autosomal recessive disorder among Caucasians. This multisystemic disease is due to mutations in the CFTR gene, causing disorder of electrolyte transport in epithelial cells. Mortality is most commonly due to pulmonary complications, but nowadays prolonged survival shows that advanced liver disease is becoming more prevalent and is now considered to be the third cause of death, accounting for 2.5% of overall mortality among cystic fibrosis patients [1]. Patients who develop respiratory failure should be offered the option of lung transplantation when they are on a trajectory of declining lung function. Similarly, patients suffering cirrhosis or portal hypertension should be considered for liver transplantation [1]. Combined lung-liver transplantation is proposed for those patients with end-stage lung disease complicated by concomitant liver disease in whom survival is not expected with single organ transplantation alone. Here we report the case of a combined single-lung and liver transplantation after a right pneumonectomy.

CASE REPORT

The patient was a 24-year-old woman suffering from cystic fibrosis diagnosed at birth after meconium ileus. Genetic analysis revealed homozygous DeltaF508 mutations. Her pulmonary history was as usual as it can be in cystic fibrosis, with repeated pulmonary infections, longstanding *Pseudomonas Aeruginosa* colonization, and episode of pneumothorax resolute with a chest drain. Since the age of 8 years, she developed a liver disease leading to biliary cirrhosis associated with portal hypertension at 14 years old. Two years later, she suffered from two episodes of variceal bleeding and esophageal veins were ligated. At the age of twenty, pulmonary symptoms progressed towards an end-stage respiratory failure with increasingly frequent exacerbations requiring intravenous antibiotics. Lung function test showed severe obstructive airway disease (functional vital capacity 1.7L, 43% of predicted values, forced expiratory volume in one second (FEV1) 1L, 30 %). She had a body mass index of 17.3 (weight: 47kg, height: 165 cm). At that point, notwithstanding an end-stage liver disease, with Child-Pugh class A liver cirrhosis and a model of end-stage liver disease (MELD) score at 7, she was planned for combined lung and liver transplantation. Approval for dual listing was made by a multidisciplinary board review. While she was on the waiting list, her condition degraded again with extensive bronchiectasis resulting in a destroyed and infected right lung with a retracted right pleural space (Figure 1). The FEV1 declined to 21% and the forced vital capacity to 31%. Despite antibiotics, intensive physiotherapy and non invasive ventilatory support, she maintained an irreversible atelectasis and sepsis. After thorough multidisciplinary assessment a right pneumonectomy was performed for resection of the pulmonary abscess. Pre-operatively, she benefited from a transjugular intrahepatic portosystemic shunt to decrease portal hypertension. The surgery was realized through a posterolateral thoracotomy in the fifth intercostal space. The pleural adhesion was complete, requiring an extensive pneumolysis. Unfortunately early postoperative period was marked with extubation failure with major hypercapnia (pCO₂ : 11,10 kPa) without empyema. Faced with this abrupt worsening of her respiratory function,

the patient was listed in the “high emergency waiting list”, a new allocation system created by French organ transplantation authorities in 2007 to reduce mortality in the regular waiting list [2].

The surgical intervention was performed eight days after listing, by distal procurement from a 61-year-old donor. Lungs were protected with antegrade and retrograde Celsior solution, explanted in a slightly inflated status and transported in a cooler (temperature 8°C to 10°C). Femoral vessels were cannulated for normothermic cardiopulmonary bypass. Left posterolateral thoracotomy was performed through the fifth intercostal space. After left pneumonectomy, pulmonary hilum anastomoses were executed conventionally. The cardiopulmonary bypass time was 210 minutes. After reperfusion, the weaning from cardiopulmonary bypass was accompanied with pulmonary oedema, elevated central venous blood pressure and anuria. Cardiopulmonary bypass withdrawal was coupled with noradrenaline requirement up to 1 mcg/kg/min and use of inhaled nitrogen monoxide. Arterial blood gas measurements evidenced severe acidosis refractory to intravenous bicarbonates with corresponding instability and resistance to vasopressors (pH 7.07, PCO₂ 12kPa, PO₂ 12kPa under 100% oxygen, lactate level at 6.9mmol/L, base deficit at -3.6 mmol/L, potassium 6.4mmol/l). In close cooperation between surgeons and anesthesiologists, it was decided to wait before liver transplantation, and to perform an emergent hemodialysis in the operative room through continuous veno-venous hemofiltration with minimal heparin to improve electrolyte management, acid-base status and to restore fluid balance. The liver transplantation was performed secondarily, after hemodynamic equilibration and heparinisation reversal. Following a Rio-Branco incision, and a temporary end-to-side portacaval shunt, liver explantation then transplantation were performed without difficulties. The total ischemic time was 257 minutes for the lung (cold ischemia: 203 minutes, warm ischemia: 54 minutes) and 583 minutes for the liver (cold and warm ischemia: 550 minutes and 33 minutes respectively). Immunosuppression regimen was based on basiliximab administered on day 0 and day 4 with methylprednisolone. Maintenance immuno-

suppression consisted of steroid, mycophenolate mofetil and a calcineurin inhibitor (tacrolimus) initiated in day one. Extubation was possible on postoperative day (POD) 5, as well as cessation of renal replacement therapy. Discharge from Intensive Care Unit occurred on POD 15 and discharge from hospital on POD 43. The last follow-up visit take place 96 months after transplantation (Figure 2). The patient has good functional results and quality of life and was free of rejection episodes. The FEV1 was 51%. No abnormality was detected in hepatic function tests.

DISCUSSION

Combined liver-single lung transplantation in a patient applies two technically challenging surgery in a patient with severe two organ failure and mediastinal changes due to previous pneumonectomy. Lung transplantation alone is the most common transplant performed in cystic fibrosis patients, followed by liver transplantation alone, and finally combined lung-liver transplantation. This last procedure is proposed to patients with advanced lung and liver disease who could not be expected to survive transplantation of either organ alone [3]. It is a rare procedure with a cumulated experience of slightly more than one hundred cases in United States [4]. Our patient was at end-stage lung disease and suffered from cirrhosis and portal hypertension but have not decompensated liver disease with hepatic synthetic dysfunction and consequently a lower mean MELD score than would be expected for isolated liver transplantation. It was decided to perform a combined liver and lung transplantation to preclude the risk of hepatic decompensation leading secondarily to the necessity of emergent liver transplantation. It appeared preferable to perform a combined double transplantation rather than potential staged procedures including immunologically even if combined lung-liver transplantation remains a challenging surgery with opposite anesthetic goals regarding optimal volume resuscitation. However, recent reports [3,5,6] showed that midterm survival after combined Lung-Liver transplantation compare similarly with isolated lung transplantation with a three year survival of more than 70%. In the other hand, Nash et al studies [7] found that in their institution, carefully selected cystic fibrosis patients with end-stage lung disease and cirrhosis undergoing lung transplantation had similar perioperative outcomes and survival. There was no evidence of hepatic decompensation in their six patients in the perioperative period. Previously, Klima et al [8] didn't see complications in cystic fibrosis patients with cystic fibrosis-associated liver disease and portal hypertension after double lung transplantation. This controversy highlights the need for close cooperation between lung and liver transplantation teams to define the best surgical strategy.

Datas are lacking in the literature about single-lung transplantation after previous pneumonectomy. Short case series or isolated observations are reported and our first case has been published elsewhere [9,10]. In a nationwide retrospective study, Le Pimpec-Barthes et al [10] reported a series of 14 patients from France and Belgium who benefited of a single-lung transplantation after pneumonectomy. The interval between pneumonectomy and single lung transplantation ranged from 11 months to 30 years. Obviously, anatomical changes that occur with pneumonectomy due to mediastinal shift and rotation increase the technical difficulty of the subsequent transplantation with an inhospital mortality up to 29%. Another important consideration is the obligatory need for Cardiopulmonary Bypass with increased risk of hemorrhage and difficulties of fluid balance equilibration. Effectively, in this series, all patients had moderate to severe pulmonary oedema in the early post-operative period. Authors emphasise the need for careful analysis of pre-operative CT scan to anticipate perioperative difficulties particularly in cannulation access [10]. The CT-scan also is helpful for evaluation of the ideal donor lung volume for an oversized recipient's pleural cavity. Souilamas et al [11] reported three cases of single-lung transplantation and metachronous pneumonectomy in patients with cystic fibrosis. In two patients the pneumonectomy was performed after the single-lung transplantation. They both died of infectious complications. They advise to perform the pneumonectomy before the lung-transplantation if possible or otherwise simultaneously. Ganapathi et al [12] founded, using the United Network for Organ Sharing (UNOS) database, that lung transplantation after previous major lung resection was associated with increased 90-day mortality and dialysis. In this series, 22 patients were transplanted after a previous pneumonectomy, the largest cohort published to date. Interestingly, 10 of these patients (45%) had bilateral lung transplantation despite prior pneumonectomy. Delay between procedures is not indicated. Retrospectively, considering the short time delay between pneumonectomy and transplantation, bilateral lung transplantation could have been proposed to our patient but we have concerns about post pneumonectomy pleural cavity size after major mediastinal shift

favoured by chronic lung atelectasis and increased bleeding risk due to redo hilum dissection. Finally, in the paper of Grannas et al [13], one patient undergoing a combined single lung-liver transplantation after previous pneumonectomy is mentioned. The underlying disease was not cystic fibrosis and postoperative course was not described.

Acute renal failure defined as a 50% decrease in glomerular filtration rate, is common after lung transplantation, reaching 39% to 56% in different studies [14,15]. Jacques et al [14] identified the use of aprotinin and bipulmonary transplantation as predictive factors for developing acute renal failure. Other predictive factors such as effective volume contraction, ventricular dysfunction, acute tubular necrosis, sepsis, hypotension or ECMO before lung transplantation are found in the literature [16,17]. However, data on intraoperative renal replacement therapy during lung or combined lung-liver transplantation are not specifically reported but as been studied for liver transplantation. Lamattina et al [18] retrospectively reviewed cases of intraoperative renal replacement therapy in liver transplant recipients with new-onset renal failure. The use of intraoperative renal replacement therapy (IORRT) permitted patients with increasing severity of illness to achieve outcomes comparable with less ill patients. Agopian et al [19] proposed a practical risk score that can be used to accurately identify the subset of liver recipients receiving pre-transplant renal replacement therapy that are likely to require intraoperative renal replacement therapy. The selective and planned use of IORRT at the start of liver transplant may lead to reduced intraoperative complications and improved post-transplant outcomes compared to the emergent IORRT group in whom reasons for initiation of hemodialysis were severe acidosis and hemodynamic instability. In our case, we decided to perform the intraoperative renal replacement therapy just before liver transplantation, so as to correct the severe metabolic acidosis and to restore hemodynamic stability and biochemical balance.

Conclusion

Combined lung and liver transplantation is a rare but feasible and effective procedure for cystic fibrosis patients with end-stage lung and liver disease. Herein it's the first reported case of concomitant single lung-liver transplantation after previous controlateral pneumonectomy with smooth postoperative recoveries.

REFERENCES

1. T Flass, M R Narkewicz. Cirrhosis and other liver disease in cystic fibrosis. *J Cystic Fibros* 2013(12):116-124.
2. Orsini B, Sage E, Olland A, Cochet E, Tabutin M, Thumerel M et al. High-emergency waiting list for lung transplantation: early results of a nation-based study. *Eur J Cardiothorac Surg* 2014;46:e41-e47.
3. Barshes NR, DiBardino DJ, McKenzie ED, Lee TC, Stayer SA, Mallory GB et al. Combined lung and liver transplantation: the United States experience. *Transplantation*. 2005;80(9):1161-67.
4. Han JL, Beal EW, Mumtaz K, Washburn K, Black SM. Combined liver-lung transplantation: Indications, outcomes, current experience and ethical issues. *Transplantation Reviews*. 2019;33:99-106.
5. Arnon R, Annunziato RA, Miloh T, Padilla M, Sogawa H, Batemarco L et al. Liver and combined lung and liver transplantation for cystic fibrosis: analysis of the UNOS database. *Pediatr Transplantation* 2011;15: 254-64.
6. Freischlag KW, Messina J, Ezekian B, Mulvihill MS, Barbas A, Berg C et al. Single-center long-term analysis of combined liver-lung transplant outcomes. *Transplantation direct*. 2018;4:e341-e49.
7. Nash EF, Volling C, Gutierrez CA, Tullis E, Coonar A, McRae K et al. Outcomes of patients with cystic fibrosis undergoing lung transplantation with and without cystic fibrosis-associated liver cirrhosis. *Clin Transplant*. 2012;26(1):34-41.
8. Klima LD, Kowdley KV, Lewis SL, Wood DE, Aitken ML.. Successful lung transplantation in spite of cystic fibrosis-associated liver disease: a case series. *J Heart Lung Transplant*. 1997;16(9):934-938.

9. Vergnat M, Farhat F, Tronc F, Jegaden O. Metachronous single lung transplantation after contralateral pneumonectomy. *Minerva Chir* 2007;62:187-90.
10. Le Pimpec-Barthes F, Thomas PA, Bonnette P, Mussot S, DeFrancquen P, Hernigou A et al. Single-lung transplantation in patients with previous contralateral pneumonectomy: technical aspects and results. *Eur J Cardiothorac Surg*. 2009;36(5):927-32.
11. Souilamas R, Mostafa A, Guillemain R, Boussaud V, Amrein C, Chevalier P. Single-Lung Transplantation for Cystic Fibrosis and Metachronous Pneumonectomy: Case reports. *Transplant Proc*.2008; 40(10):3594-3595.
12. Ganapathi AM, Speicher PJ, Castleberry AW Englum BR, Osho AA, Davis RD et al. The effect of prior pneumonectomy or lobectomy on subsequent lung transplantation. *Ann Thorac Surg*. 2014;98(6):1922-28.
13. Grannas G, Neipp M, Hoepfer M, Gottlieb J, Lück R, Becker T et al. Indications for and outcomes after combined lung and liver transplantation: a single-center experience on 13 consecutive cases. *Transplantation*. 2008; 85(4):524-31.
14. Jacques F, El-Hamamsy I, Fortier A, Maltais S, Perrault LP, Liberman M et al. Acute renal failure following lung transplantation: risk factors, mortality, and long-term consequences. *Eur J Cardiothorac Surg*. 2012;41(1):193-99.
15. Rocha PN, Rocha AT, Palmer SM, Davis RD, Smith SR. Acute renal failure after lung transplantation: incidence, predictors and impact on perioperative morbidity and mortality. *Am J Transplant*. 2005;5(6):1469-76.
16. Bloom RD, Doyle AM. Kidney disease after heart and lung transplantation. *Am J Transplant*. 2006;6(4):671-79.
17. Grimm JC, Lui C, Kilic A, Valero V, Sciortino CM, Whitman GJ et al. A risk score to predict acute renal failure in adult patients after lung transplantation. *Ann Thorac Surg*. 2015;99(1):251-57.

18. LaMattina JC, Kelly PJ, Hanish SI, Ottmann SE, Powell JM, Hutson WR et al. Intraoperative Continuous Veno-Venous Hemofiltration Facilitates Surgery in Liver Transplant Patients With Acute Renal Failure. *Transplant Proc.* 2015;47(6):1901-04.

19. Agopian VG, Dhillon A, Baber J, Kaldas FM, Zarrinpar A, Farmer DG et al. Liver transplantation in recipients receiving renal replacement therapy: outcomes analysis and the role of intraoperative hemodialysis. *Am J Transplant.* 2014;14(7):1638-47.

DISCLOSURE

The authors have no conflicts of interest to disclose as described by *Transplantation Proceedings*

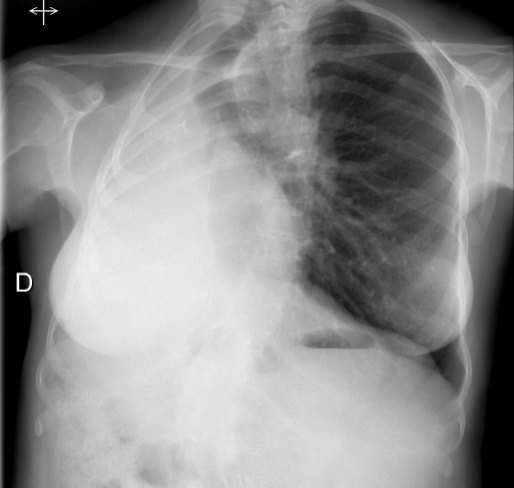
Acknowledgements

The authors thank Karine Debbasch for reviewing the English manuscript

Figure legends

Figure 1. Pre-operative chest radiograph and axial CT image demonstrating right lung collapse with cystic bronchiectasis involving the whole bronchial tree.

Figure 2. Chest radiograph 96 months after transplantation showing good transplanted left lung expansion and a shift of mediastinal structures towards the right hemithorax.



D

