HAL open science

Utility of Three-Dimensional Transesophageal Echocardiography for Mitral Annular Sizing in Transcatheter Mitral Valve Replacement Procedures: A Cardiac Computed Tomographic Comparative Study

Augustin Coisne, François Pontana, Samy Aghezzaf, Stéphanie Mouton, Hélène Ridon, Marjorie Richardson, Anne-Sophie Polge, Benjamin Longère, Valentina Silvestri, Julien Pagniez, et al.

To cite this version:

Augustin Coisne, François Pontana, Samy Aghezzaf, Stéphanie Mouton, Hélène Ridon, et al.. Utility of Three-Dimensional Transesophageal Echocardiography for Mitral Annular Sizing in Transcatheter Mitral Valve Replacement Procedures: A Cardiac Computed Tomographic Comparative Study. Journal of The American Society of Echocardiography, 2020, 33, pp.1245 - 1252.e2. 10.1016/j.echo.2020.04.030 . hal-03492548

HAL Id: hal-03492548

https://hal.science/hal-03492548v1

Submitted on 17 Oct 2022

HAL is a multi-disciplinary open access archive for the deposit and dissemination of scientific research documents, whether they are published or not. The documents may come from teaching and research institutions in France or abroad, or from public or private research centers.

L'archive ouverte pluridisciplinaire **HAL**, est destinée au dépôt et à la diffusion de documents scientifiques de niveau recherche, publiés ou non, émanant des établissements d'enseignement et de recherche français ou étrangers, des laboratoires publics ou privés.

Distributed under a Creative Commons Attribution - NonCommercial 4.0 International License

Version of Record: https://www.sciencedirect.com/science/article/pii/S0894731720303096
Manuscript_b6d5dd0fcb50d4c74cb01056644697e6

Utility of 3-Dimensional Transoesophageal Echocardiography for Mitral Annular Sizing in Transcatheter Mitral Valve Replacement Procedures: A Cardiac Computed Tomography Comparative Study

Augustin Coisne, MD, PhD [a,b,c,d,]; François Pontana, MD, PhD [b,c,d,e]; Samy Aghezzaf, MD [a]; Stéphanie Mouton, MD [a]; Hélène Ridon, MD [a]; Marjorie Richardson, MD [a]; Anne-Sophie Polge, MD [a]: Benjamin Longère, MD [e]; Valentina Silvestri, MD [e]; Julien Pagniez, MD [e]; Antoine Bical, MD [f]; Natacha Rousse, MD [f]; Pavel Overtchouk, MD [f]; Juan F. Granada, MD [h]; Rebecca T. Hahn, MD [i]; Thomas Modine, MD, PhD [f]; David Montaigne, MD, PhD [a,b,c,d,]

a. CHU Lille, Department of Clinical Physiology and Echocardiography – Heart Valve Center, France

b. Univ. Lille, U1011 - EGID, F-59000 Lille, France

c. Inserm, U1011, F-59000 Lille, France

d. Institut Pasteur de Lille, F-59000 Lille, France

e. CHU Lille, Department of Cardiovascular Radiology, France

f. CHU Lille, Department of Cardiovascular Surgery, France

g. Cardiovascular Research Foundation, Columbia University Medical Center, NY

h. Columbia University Medical Center/ NY Presbyterian Hospital, New York, NY

Address for correspondence: Dr. Augustin Coisne. Department of Clinical Physiology and Echocardiography, France – Heart Valve Clinic. Institut Coeur Poumon. CHU Lille F59000. France.

E-mail: augustin.coisne@chru-lille.fr

No disclosures to declare

All authors made a significant contribution to the study and manuscript by performing inclusions, reading and performing 3D-TEE and CT-scan, performing TMVR or drafting of the manuscript or revising it critically.

Total Word Count: 4896/5000

© 2020 published by Elsevier. This manuscript is made available under the CC BY NC user license
https://creativecommons.org/licenses/by-nc/4.0/

ABSTRACT

Background. 3-dimensional transoesophageal echocardiography (3D-TEE) is frequently used as an initial screening tool in the evaluation of patients who are candidates to Transcatheter Mitral Valve Replacement (TMVR). However, little is known about the imaging correlation with the gold-standard computed tomography (CT) imaging. We aimed at testing the quantitative differences between these two modalities and finding the best 3D-TEE parameters for TMVR screening.

Methods. We included 57 patients referred to our Heart Valve Clinic for TMVR with **prostheses** specifically designed for the mitral valve. Mitral annulus (MA) analyses were performed using commercially available software in 3D-TEE and CT.

Results. 3D-TEE was feasible in 52 patients (91%). Although 3D-TEE measurements were slightly lower than in CT, both measurements of projected MA area and perimeter showed excellent correlation with small differences between the two modalities (r=0.88 and r=0.92 respectively, p<0.0001). Correlations were significant but lower for MA diameters (r=0.68 to 0.72, p<0.0001) and mitro-aortic angle (r=0.53, p=0.0001). ROC curve analyses showed that 3D-TEE had a good ability to predict TMVR screening success defined by constructors based on CT measurements with a range of 12.9 to 15cm² for MA area (AUC=0.88-0.91, p<0.0001), 128 to 139mm for MA perimeter (AUC=0.85-0.91, p<0.0001), 35 to 39mm for anteroposterior diameter (AUC=0.79-0.84 p<0.0001) and 37 to 42mm for posteromedial-anterolateral diameter (AUC=0.81-0.89, p<0.0001).

Conclusion. 3D-TEE measurements of MA dimensions display strong correlation with CT measurements in patients undergoing TMVR screening process. 3D-TEE should be proposed as a reasonable alternative to CT in this vulnerable population.

Key-words: Transcatheter Mitral Valve Replacement; Mitral Annulus; 3-dimensions; Multimodality Imaging; Heart Team

ABBREVIATIONS LIST

3D: Three dimensional

AP: Antero-posterior

CT: Computed Tomography

LVOT: Left Ventricular Outflow Tract

MA: Mitral Annulus

MR: Mitral Regurgitation

PM-AL: Posteromedial-anterolateral

TMVR: Transcatheter Mitral Valve Replacement

TEE: Transoesophageal Echocardiography

INTRODUCTION

Recent early clinical reports suggest that Transcatheter Mitral Valve Replacement (TMVR) is a viable therapeutic solution for inoperable or high-risk patients with symptomatic severe mitral regurgitation (MR) (1–3). However, the advancement of TMVR solutions face several challenges including the careful selection of device size to match the individual dimensions and the geometry of the mitral annulus (MA). (4,5)

We have recently shown that despite the availability of several TMVR prosthesis with different dimensions a very high rejection rate still occurs due to anatomy and prosthesis mismatch in size or risk of neo-left ventricular outflow tract (LVOT) obstruction. (6)

Cardiac computed tomography (CT) is currently the imaging modality of choice for MA sizing for TMVR screening (7). Recent studies have suggested that 3-dimensional (3D) transoesophageal echocardiography (TEE) is a promising tool for assessing characteristics of MR and MA using dedicated software (8–10). Pitfalls of CT include radiation exposure, motion artifact (due to arrhythmias or patient factors) and the need for iodinated contrast. Candidates for TMVR often have renal insufficiency (11) and it is thus important to find alternative imaging methods to avoid contrast administration in this frail population. Mak et al. showed that 3D-TEE seems a promising complementary tool to CT for sizing the TMVR (12). However, the best 3D-TEE parameters to size the prosthesis are still unclear.

In the present study, we aimed to 1) compare MA sizing using a novel 3D-TEE method to CT measurements in candidates for TMVR with various prostheses and 2) find the best 3D-TEE parameters for TMVR screening.

METHODS

Study population and design

From November 2016 to May 2019, we prospectively studied all consecutive patients with severe MR referred to our Heart Valve Centre for percutaneous implantation because of high-risk for MR surgery. Inclusion criteria were: age > 18 years with severe (grade III-IV) and symptomatic (New York Heart Association functional class ≥ 2) chronic MR. Patients were excluded from TMVR screening if they had severe mitral annulus calcification, left atrial or LV thrombus, prior mitral valve surgery, indications for standard cardiac surgery or suitable anatomy for mitral valve repair using the MitraClip™ system (Abbott Structural, Santa Clara, California) according to our Heart Team decision. The local ethics committee approved the protocol and patients gave informed consent

Echocardiography

A comprehensive transthoracic (TTE) and transoesophageal echocardiography (TEE) using 2- and 3-D imaging was performed in our department according to current guidelines (13–15) using state-of-the-art echocardiographic ultrasound systems (Vivid 9 or Vivid 95, GE Healthcare, Horten, Norway) under local anaesthesia before the procedure. All measurements were obtained by TTE expect MA dimensions.

3D TEE reconstruction for measurement of the MA was performed off-line on a dedicated workstation using a commercially available software (4D Auto MVQ, GE Healthcare - Echopac, version 203, Horten, Norway) (Figure 1). Briefly, a 3D volume of the MA set was acquired guided by a multiplane 2D-TEE view. The mid diastolic frame was selected. An alignment step was performed to ensure standardized and expected views where vertical axis crosses through the center of the mitral valve while the horizontal axis is parallel to the mitral valve. Six landmarks were then placed: two mitral annulus points, two anterior/posterior

points, the coaptation plus the aorta point. A complete 3D reconstruction of the mitral annulus was automatically performed but which can be edited by the operator. Finally, a review stage was performed to check the 3D model in all slices (Biplane, Scallops and Commissures) and several MA dimensions and geometry were determined by the 4D Auto MVQ software.

Cardiac Computed Tomography

Contrast-enhanced cardiac CT images were also acquired for screening and procedure planning. CT examinations were performed using a multiphase retrospectively electrocardiogram-gated data acquisition. Briefly, mitral annular measurements were made at 60% of the cardiac cycle based on a saddle shape (or projected) orifice contour (16,17) (Figure 2) and mitral annular segmentation was performed using a dedicated software (3mensio, Pie Medical Imaging. Bilthoven, The Netherlands) as previously described (7,18). All CT measurements were performed by the same cardiovascular radiologist with 12 years of experience in cardiac CT and with 3 years' experience using this software. These measurements included MA area, 3D and projected perimeters, antero-posterior and posteromedial-anterolateral diameter and mitro-aortic angle.

Screening for TMVR

TMVR screening was performed for several dedicated prostheses (Intrepid™ [Medtronic, Minneapolis, Minnesota] (outer diameters 43-46-50mm), Tendyne™ [Abbott Structural, Santa Clara, California] (sizes ranging from 33 to 41) and HighLife™ [HighLife, Paris, France] (outer diameter 26.5mm). The final suitability decision was given by the manufacturer based on CT measurements of projected MA area, projected MA perimeter, antero-posterior (AP) and posteromedial-anterolateral (PM-AL) diameter, mitro-aortic angle and risk of neo-LVOT obstruction. This screening classified patients as being suitable for TMVR implantation, or not suitable because of too large or too small mitral annulus anatomy.

Statistical analysis

Continuous variables were tested for normality with Shapiro test, and were displayed as mean±SD. Continuous variables with no Gaussian distribution were displayed as median (IQR). Categorical variables were displayed as percentages of individuals. Linear regression was used to explore the correlation between 3D-TEE and CT measurements using Pearson correlation coefficient. Comparisons between 2 measurements were performed using a paired t-test. Agreement between these two methods was displayed with plots using Bland-Altman method. (19). All 3D-TEE measurements were performed by an observer (AC) blinded to patient information and CT analysis. Interobserver variability was quantified in 10 patients with a second observer (SA) blinded to all measurements with intraclass correlation coefficient with 95% confidence intervals. Receiver Operating Characteristics (ROC) curve analyses were used to determine the 3D-TTE cut-offs with the higher discriminating power to predict exclusion from TMVR due to too large or too small anatomy. Statistics were performed using MedCalc v16.4 (Olstead, Belgium).

RESULTS

Characteristics of patients referred to the Heart Team and eligible for TMVR screening

Among the 57 patients included, 2 patients had a truncated LV view with commissures out of the 3D data set and 3 patients had inadequate image quality due **to** severe pulmonary disease. Patients were elderly (77±9 years), with a sex ratio of nearly 1 and few diabetic patients (21%). Most of the patients (60%) were in NYHA 3 or 4. Almost a half presented with chronic kidney disease and 15% had previous cardiac surgery. These characteristics translates into high EuroScore II and STS predicted risk of mortality, 3.05 [2.00-6.08] and 5.75 [3.67-8.70], respectively. MR mechanism was mainly primary (60%) with a posterior mitral valve leaflet mostly involved (58%). LV function was normal (ejection fraction>60%) in 26 patients (50%) and moderately impaired (ejection fraction between 30% and 60%) in 26 patients (50%). No patient had severe LV dysfunction (ejection fraction <30%). 33 patients (63.5%) had previous and paroxysmal atrial fibrillation (AF). No patient was in AF at the time of the CT of TEE acquisition.

Comparison of 3D-TEE and CT measurements

Both projected MA area and perimeter measurements were the parameters with the best concordance with CT, showing excellent correlation (r=0.88, p<0.0001 and r=0.92, p<0.0001, respectively) with small differences between the two modalities (-0.05±0.72, p=0.68 and 1.09±3.39, p=0.54 respectively by paired t-test) (Table 1, Figures 3). Correlation was significant but lower for MA diameters (r=0.72, p<0.0001 for AP diameter and r=0.68, p<0.0001 for PM-AL diameter) and mitro-aortic angle (r=0.53, p=0.0001).

In Bland-Altman analysis, 3D-TEE measurements were slightly smaller than CT measurements for most measurements with the following differences: mean projected MA area difference = 0.1cm² (range, 3.6 to -3.4cm²), projected MA perimeter difference = -0.6mm

(range, 13.7 to -15mm), A-P diameter difference = -2mm (range, 6.8 to -10.7mm) and PM-AL diameter difference = -2.8mm (range, 6.7 to -12.4mm) (Figures 3).

Intraclass correlation coefficient for the 10 patients tested was 0.97 (0.79-0.99) for projected MA area, 0.87 (0.50-0.98) for projected MA perimeter, 0.94 (0.55-0.99) for A-P diameter, 0.93 (0.53-0.99) for PM-AL diameter and 0.60 (-1.88-0.94) for mitro-aortic angle. Mitral annulus dimensions by TEE and CT according to MR mechanism are given in Supplemental Table 1.

Receiver Operating Characteristic Curve Analyses for prediction too large or too small annulus with 3D-TEE

Among the 52 patients screened for TMVR, 34 patients (65%) were refused, 20 (38%) for a too large annulus and 14 (27%) for a too small annulus including 11 with risk of LVOT obstruction. Screening success rate was significantly higher in secondary than in primary MR, respectively 71.4% vs. 19.4%, p=0.0008.

ROC curve analyses showed that 3D-TEE had a good ability to predict too large anatomy as defined by constructors based on CT measurements with a cut-off of 15cm² for projected MA area (area under the curves (AUC) =0.91, p<0.0001), 139mm for projected MA perimeter (AUC=0.91, p<0.0001), 39mm for A-P diameter (AUC=0.84, p<0.0001) and 42mm for PM-AL diameter (AUC=0.89, p<0.0001) (Table 2). In addition, the discrimination ability of 3D-TEE to predict too small annulus defined on CT sizing was also good with a cut-off of 12.9cm² for projected MA area (AUC=0.88, p<0.0001), 128mm for projected MA perimeter (AUC=0.85, p<0.0001), 35mm for A-P diameter (AUC=0.79, p=0.003) and 37mm for PM-AL diameter (AUC=0.81, p<0.0001) (Table 3). Importantly, predictions for screening were always consistent between 3D-TEE and CT. ROC curves analyses for predicting too large or too small annulus with 3D-TEE are given in Supplemental Figures 2.

Implantation results

Among the 18 patients with screening success, 2 died before TMVR and 16 underwent TMVR. 14 patients (87.5%) had successful implantation without complication, 1 (6.25%) presented severe paravalvular leak, and 1 (6.25%) moderate intravalvular leak. 1 patient presented a significant LVOT obstruction (max aortic velocity = 3.4m/s) but without clinical signs. All the results of the implantations are given in Supplemental Table 2.

DISCUSSION

Exploring 52 eligible patients referred to our Heart Valve Clinic for a TMVR with a variety of dedicated prostheses, we found that 3D-TEE measurements of MA dimensions is 1) feasible in 90% of the cases (52/57), 2) displays good interobserver agreement and correlations with CT measurements and 3) poses very high accuracy to predict TMVR screening success as defined by manufacturer recommendations for CT measurements.

With commercially available software and improvement in 3D technology, 3D-TEE has the unique capacity of showing the MA and the mitral valve from an *en face* perspective with a high temporal and spatial resolution. It is thus probably one of the best methods for visualizing and exploring the anatomy and dynamism of the MA. (20,21)

Usefulness of MA evaluation using 3D-TEE has been reported in patients undergoing surgical (22,23) or percutaneous (24) mitral valve repair, and in ischemic MR (10) or in the presence of mitral annular disjunction (25). Only one prior study showed its usefulness in TMVR sizing for a dedicated prosthesis (12). In line with the latter study, we found an excellent correlation between 3D-TEE and CT for MA area and perimeter measurements (r=0.88 and r=0.92 respectively) and a good correlation for PM-AL diameter (r=0.68), despite different software for TEE MA sizing. The lower correlation for PM-AL diameter may be due to a suboptimal resolution in the lateral part of the coronal plane in 3D-TEE, reducing the ability to distinguish blood from tissue (26). We showed larger MA dimensions (MA area and perimeter=14.8cm² and 137.8mm respectively) than Mak et al. (11.4cm² and 123mm respectively) or other studies (27,28). This can be explained by the characteristics of our population, i.e. older patient, with a higher proportion of primary and severe MR. Indeed, in line with Mak et al. findings, we found that primary MR were associated with larger MA measurements (Supplemental Table 1). We also found lower screening success rates in

primary MR. These differences in TMVR screening between primary and secondary MR should be explored in further studies.

TEE-derived MA area between 12.9 and 15cm² and MA perimeter between 128 and 139mm can predict screening success with specificity satisfying accuracy (Figure 4). We did not included patients with AF at the time of the acquisition. The way to manage AF both for CT and 3D-TEE acquisition and analysis should be explored in further studies.

Almost a half of patients referred for TMVR presented with chronic kidney disease in our centre. Thus, using 3D-TEE measurements of MA as first-line imaging modality appears clinically relevant to avoid iodinated contrast injection mandatory with screening CTs. Even if the final decision will be taken with CT analysis, our study is the first to propose range of 3D-TEE measurements to predict TMVR screening success for the currently available TMVR sizes.

Limitations

The software uses a semi-automated segmentation algorithm to initiate a 3D model from where MA measurements are calculated, with an inherent risk of giving inaccurate 3D models. A review step is thus mandatory to confirm the accuracy of the model. Though this step may lead to discrepancies, the interobserver variability was at least good in our study. Moreover, current software allows MA analysis during one moment of the cardiac cycle. Since MA area is highly dynamic, with a 20-30% reduction during LV contraction (29), a dynamic evaluation with a multiphasic annular assessment would probably improve the annular sizing. Although the final suitability decision was given by the manufacturer, the criteria for suitability was the same for the 3 devices. However, this criterion must be confirmed in the future. Even if we present data from the most used prosthesis, as the companies produce different size devices, the cut-offs will change depending on the company

and must be confirmed in further studies. Poor image quality still an issue for 3D-TEE analysis in almost 10% of the screened population. Unfortunately, both TEE or CT did not give us any clues regarding postoperative issues. The high LVOT gradient and the significant MR observed in 3 patients were actually secondary to per-procedure issues and calcifications that are in our mind hardly predicted even a posteriori by pre-op screening. Finally, we report the current largest TVMR population with 3D-TEE, CT and screening for dedicated TMVR prosthesis. However, our results and ranges of 3D-TEE measurements should be tested in larger populations.

Clinical perspectives

3D-TEE is feasible and useful to measure MA dimensions in patients referred for TMVR, displaying good interobserver agreement and correlations with CT measurements and high accuracy to predict TMVR screening success. It might be proposed as a reasonable alternative to avoid unnecessary CTs in this vulnerable population

CONCLUSION

3D-TEE measurements of MA dimensions are feasible in daily practice to predict TMVR screening success with acceptable accuracy and interobserver agreement, and good correlations with CT measurements.

REFERENCES

1. Muller DWM, Farivar RS, Jansz P, Bae R, Walters D, Clarke A, et al. Transcatheter Mitral Valve Replacement for Patients With Symptomatic Mitral Regurgitation: A Global Feasibility Trial. J Am Coll Cardiol. 2017 Jan 31;69(4):381–91.

2. Bapat V, Rajagopal V, Meduri C, Farivar RS, Walton A, Duffy SJ, et al. Early Experience With New Transcatheter Mitral Valve Replacement. J Am Coll Cardiol. 2018 Jan 2;71(1):12–21.

3. Barbanti M, Piazza N, Mangiafico S, Buithieu J, Bleiziffer S, Ronsivalle G, et al. Transcatheter Mitral Valve Implantation Using the HighLife System. JACC Cardiovasc Interv. 2017 Aug 28;10(16):1662–70.

4. Blanke P, Naoum C, Dvir D, Bapat V, Ong K, Muller D, et al. Predicting LVOT Obstruction in Transcatheter Mitral Valve Implantation: Concept of the Neo-LVOT. JACC Cardiovasc Imaging. 2017 Apr;10(4):482–5.

5. Regueiro A, Granada JF, Dagenais F, Rodés-Cabau J. Transcatheter Mitral Valve Replacement: Insights From Early Clinical Experience and Future Challenges. J Am Coll Cardiol. 2017 May 2;69(17):2175–92.

6. Coisne A, Pontana F, Tchétché D, Richardson M, Longère B, Vahdat O, et al. Transcatheter Mitral Valve Replacement: Factors Associated with Screening Success and Failure. EuroIntervention. 2019 Aug 27;

7. Blanke P, Naoum C, Webb J, Dvir D, Hahn RT, Grayburn P, et al. Multimodality Imaging in the Context of Transcatheter Mitral Valve Replacement: Establishing Consensus Among Modalities and Disciplines. JACC Cardiovasc Imaging. 2015 Oct;8(10):1191–208.

8. van Wijngaarden SE, Kamperidis V, Regeer MV, Palmen M, Schalij MJ, Klautz RJ, et al. Three-dimensional assessment of mitral valve annulus dynamics and impact on quantification of mitral regurgitation. Eur Heart J Cardiovasc Imaging. 2018 01;19(2):176–84.

9. Jolley MA, Ghelani SJ, Adar A, Harrild DM. Three-Dimensional Mitral Valve Morphology and Age-Related Trends in Children and Young Adults with Structurally Normal Hearts Using Transthoracic Echocardiography. J Am Soc Echocardiogr. 2017 Jun;30(6):561–71.

10. Fattouch K, Castrovinci S, Murana G, Novo G, Caccamo G, Bertolino EC, et al. Multiplane two-dimensional versus real time three-dimensional transesophageal echocardiography in ischemic mitral regurgitation. Echocardiography. 2011 Nov;28(10):1125–32.

11. Schueler R, Nickenig G, May AE, Schillinger W, Bekeredjian R, Ouarrak T, et al. Predictors for short-term outcomes of patients undergoing transcatheter mitral valve interventions: analysis of 778 prospective patients from the German TRAMI registry focusing on baseline renal function. EuroIntervention. 2016 Jul 20;12(4):508–14.

12. Mak GJ, Blanke P, Ong K, Naoum C, Thompson CR, Webb JG, et al. Three-Dimensional Echocardiography Compared With Computed Tomography to Determine Mitral

Annulus Size Before Transcatheter Mitral Valve Implantation. Circ Cardiovasc Imaging. 2016 Jun;9(6).

13. Lang RM, Badano LP, Mor-Avi V, Afilalo J, Armstrong A, Ernande L, et al. Recommendations for cardiac chamber quantification by echocardiography in adults: an update from the American Society of Echocardiography and the European Association of Cardiovascular Imaging. J Am Soc Echocardiogr. 2015 Jan;28(1):1–39.e14.

14. Hahn RT, Abraham T, Adams MS, Bruce CJ, Glas KE, Lang RM, et al. Guidelines for performing a comprehensive transesophageal echocardiographic examination: recommendations from the American Society of Echocardiography and the Society of Cardiovascular Anesthesiologists. J Am Soc Echocardiogr. 2013 Sep;26(9):921–64.

15. Mitchell C, Rahko PS, Blauwet LA, Canaday B, Finstuen JA, Foster MC, et al. Guidelines for Performing a Comprehensive Transthoracic Echocardiographic Examination in Adults: Recommendations from the American Society of Echocardiography. J Am Soc Echocardiogr. 2019 Jan;32(1):1–64.

16. Thériault-Lauzier P, Mylotte D, Dorfmeister M, Spaziano M, Andalib A, Mamane S, et al. Quantitative multi-slice computed tomography assessment of the mitral valvular complex for transcatheter mitral valve interventions part 1: systematic measurement methodology and inter-observer variability. EuroIntervention. 2016 Oct 10;12(8):e1011–20.

17. Thériault-Lauzier P, Dorfmeister M, Mylotte D, Andalib A, Spaziano M, Blanke P, et al. Quantitative multi-slice computed tomography assessment of the mitral valvular complex for transcatheter mitral valve interventions part 2: geometrical measurements in patients with functional mitral regurgitation. EuroIntervention. 2016 Oct 10;12(8):e1021–30.

18. Blanke P, Dvir D, Cheung A, Ye J, Levine RA, Precious B, et al. A simplified D-shaped model of the mitral annulus to facilitate CT-based sizing before transcatheter mitral valve implantation. J Cardiovasc Comput Tomogr. 2014 Dec;8(6):459–67.

19. Bunting KV, Steeds RP, Slater LT, Rogers JK, Gkoutos GV, Kotecha D. A Practical Guide to Assess the Reproducibility of Echocardiographic Measurements. J Am Soc Echocardiogr. 2019 Dec;32(12):1505–15.

20. Grewal J, Suri R, Mankad S, Tanaka A, Mahoney DW, Schaff HV, et al. Mitral annular dynamics in myxomatous valve disease: new insights with real-time 3-dimensional echocardiography. Circulation. 2010 Mar 30;121(12):1423–31.

21. Faletra FF, Leo LA, Paiocchi VL, Caretta A, Viani GM, Schlossbauer SA, et al. Anatomy of mitral annulus insights from non-invasive imaging techniques. Eur Heart J Cardiovasc Imaging. 2019 Aug 1;20(8):843–57.

22. Chen T-E, Ong K, Suri RM, Enriquez-Sarano M, Michelena HI, Burkhart HM, et al. Three-Dimensional Echocardiographic Assessment of Mitral Annular Physiology in Patients With Degenerative Mitral Valve Regurgitation Undergoing Surgical Repair: Comparison between Early- and Late-Stage Severe Mitral Regurgitation. J Am Soc Echocardiogr. 2018 Nov;31(11):1178–89.

23. Sugeng L, Shernan SK, Weinert L, Shook D, Raman J, Jeevanandam V, et al. Real-time three-dimensional transesophageal echocardiography in valve disease: comparison with

surgical findings and evaluation of prosthetic valves. J Am Soc Echocardiogr. 2008 Dec;21(12):1347–54.

24. Mantegazza V, Pasquini A, Agati L, Fusini L, Muratori M, Gripari P, et al. Comprehensive Assessment of Mitral Valve Geometry and Cardiac Remodeling With 3-Dimensional Echocardiography After Percutaneous Mitral Valve Repair. Am J Cardiol. 2018 Oct 1;122(7):1195–203.

25. Lee AP-W, Jin C-N, Fan Y, Wong RHL, Underwood MJ, Wan S. Functional Implication of Mitral Annular Disjunction in Mitral Valve Prolapse: A Quantitative Dynamic 3D Echocardiographic Study. JACC Cardiovasc Imaging. 2017;10(12):1424–33.

26. Khalique OK, Kodali SK, Paradis J-M, Nazif TM, Williams MR, Einstein AJ, et al. Aortic annular sizing using a novel 3-dimensional echocardiographic method: use and comparison with cardiac computed tomography. Circ Cardiovasc Imaging. 2014 Jan;7(1):155–63.

27. Aruta P, Muraru D, Guta AC, Mihaila S, Ruozi N, Palermo C, et al. Comparison of mitral annulus geometry between patients with ischemic and non-ischemic functional mitral regurgitation: implications for transcatheter mitral valve implantation. Cardiovasc Ultrasound. 2018 Oct 12;16(1):27.

28. Veronesi F, Corsi C, Sugeng L, Caiani EG, Weinert L, Mor-Avi V, et al. Quantification of mitral apparatus dynamics in functional and ischemic mitral regurgitation using real-time 3-dimensional echocardiography. J Am Soc Echocardiogr. 2008 Apr;21(4):347–54.

29. Ormiston JA, Shah PM, Tei C, Wong M. Size and motion of the mitral valve annulus in man. I. A two-dimensional echocardiographic method and findings in normal subjects. Circulation. 1981 Jul;64(1):113–20.

FIGURE LEGENDS

Figure 1. Mitral annulus sizing using 3D-TEE MVQ software
A, A 3D volume of the mitral annulus set is acquired from a multiplane 2D-TEE view. **B**, Alignment step is mandatory to ensure standardized and expected views where vertical axis crosses through the center of the mitral valve while the horizontal axis is parallel to the mitral valve. **C**, 6 landmarks are then placed (two mitral annulus points, two anterior/posterior points, the coaptation plus the aorta point. **D**, A complete 3D reconstruction of the mitral annulus is finally performed. Once all lines have been checked, area (**E**), perimeter (**F**) or PM-AL diameter (yellow line, **G**) for example are determined by the 4D Auto MVQ software. 3D: Three dimensional; PM-AL: Posteromedial-anterolateral; TEE: Transoesophageal Echocardiography

Figure 2. CT mitral annulus measurements
A, Mitral annular segmentation is manually performed using a dedicated software (3mension, Pie Medical Imaging. Bilthoven, The Netherlands) by placing 16 points around the annulus. **B**, the software automatically generates the 3D reconstruction of the mitral annulus with its parameters on a short-axis view and **C**, the corresponding aorto-mitral angle on a 3-chamber view

Figures 3. Bland-Altman plots and correlations for comparison of 3D-TEE and CT mitral annulus measurements. Comparison of A) MA area, B) MA perimeter, C) A-P diameter and D) PM-AL diameter. P-value by linear regression 3D: Three dimensional; AP: Antero-posterior; MA: Mitral Annulus; PM-AL: Posteromedial-anterolateral; TEE: Transoesophageal Echocardiography

Figure 4. Ranges of 3D-TEE measurements for TMVR suitability
AP: Antero-posterior; PM-AL: Posteromedial-anterolateral

Supplemental Figures 1. ROC curves analyses for prediction too large (A) or too small (B) annulus with 3D-TEE

Table 1: Comparison between TEE and CT measurements

	3D-TEE	CT	Δ 3D-TEE – CT	Absolute % error	R	p-value
Projected MA area (cm²)	14.8 ± 3.7	14.8 ± 3.5	-0.05 ± 0.72	5.96 (3.64-9.83)	0.88	**<0.0001**
Projected MA perimeter (mm)	137.8 ± 17.8	138.8 ± 16.3	1.09 ± 3.39	2.25 (1.52-4.34)	0.92	**<0.0001**
A-P diameter (mm)	39.4 ± 5.8	41.4 ± 6.2	2.06 ± 1.18	8.28 (5.69-10.0)	0.72	**<0.0001**
PM-AL diameter (mm)	41.3 ± 6.2	44.2 ± 5.8	2.84 ± 1.19	9.09 (6.11-11.06)	0.68	**<0.0001**
Anterior leaflet length (mm)	28.2 ± 5.3	32.3 ± 6.4	4.12 ± 1.17	15.88 (9.75-22.07)	0.28	**0.05**
Mitro-aortic angle (°)	117.5 ± 15.5	115.5 ± 26.5	-2.07 ± 4.28	7.81 (6.08-11.24)	0.53	**0.0001**

AL: Anterolateral; A-P: AnteroPosterior; MA: Mitral Annulus; PM: Posteromedial.

Table 2: ROC analyses for prediction too large annulus with 3D-TEE

	AUC	p-value	Cut-off	Sensitivity	Specificity
3D-TEE					
MA area (cm²)	0.91	<0.0001	15	88.9	87.9
MA perimeter (mm)	0.91	<0.0001	139	83.3	87.9
A-P diameter (mm)	0.84	<0.0001	39	94.4	60.6
PM-AL diameter (mm)	0.89	<0.0001	42	83.3	84.9
Anterior leaflet length (mm)	0.67	0.03	26	88.9	39.4
Mitroaortic angle (°)	0.65	0.06	112	66.7	68.8

AL: Anterolateral; A-P: AnteroPosterior; MA: Mitral Annulus; PM: Posteromedial

Table 3: ROC analyses for prediction too small annulus with 3D-TEE

	AUC	p-value	Cut-off	Sensitivity	Specificity
3D-TEE					
MA area (cm²)	0.88	<0.0001	12.9	81.8	82.5
MA perimeter (mm)	0.85	<0.0001	128	72.7	85
A2-P2 diameter (mm)	0.79	0.003	35	72.7	90
PM-AL diameter (mm)	0.81	<0.0001	37	72.7	82.5
Anterior leaflet length (mm)	0.74	0.007	24	54.6	85
Mitroaortic angle (°)	0.52	0.79	120	90.9	30.8

AL: Anterolateral; A-P : AnteroPosterior; MA: Mitral Annulus; PM: Posteromedial

Figure 1. Mitral annulus sizing using 3D-TEE MVQ software

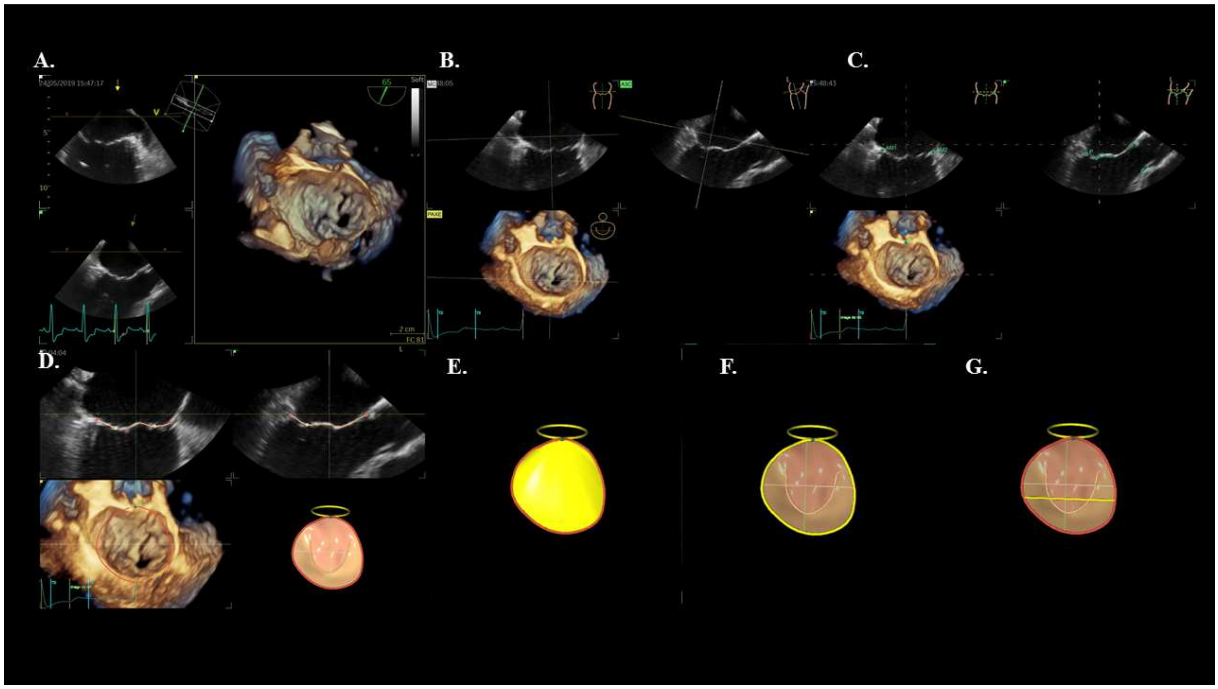

A, A 3D volume of the mitral annulus set is acquired from a multiplane 2D-TEE view. **B**, Alignment step is mandatory to ensure standardized and expected views where vertical axis crosses through the center of the mitral valve while the horizontal axis is parallel to the mitral valve. **C**, 6 landmarks are then placed (two mitral annulus points, two anterior/posterior points, the coaptation plus the aorta point. **D**, A complete 3D reconstruction of the mitral annulus is finally performed. Once all lines have been checked, area (**E**), perimeter (**F**) or PM-AL diameter (yellow line, **G**) for example are determined by the 4D Auto MVQ software

Figure 2. CT mitral annulus measurements

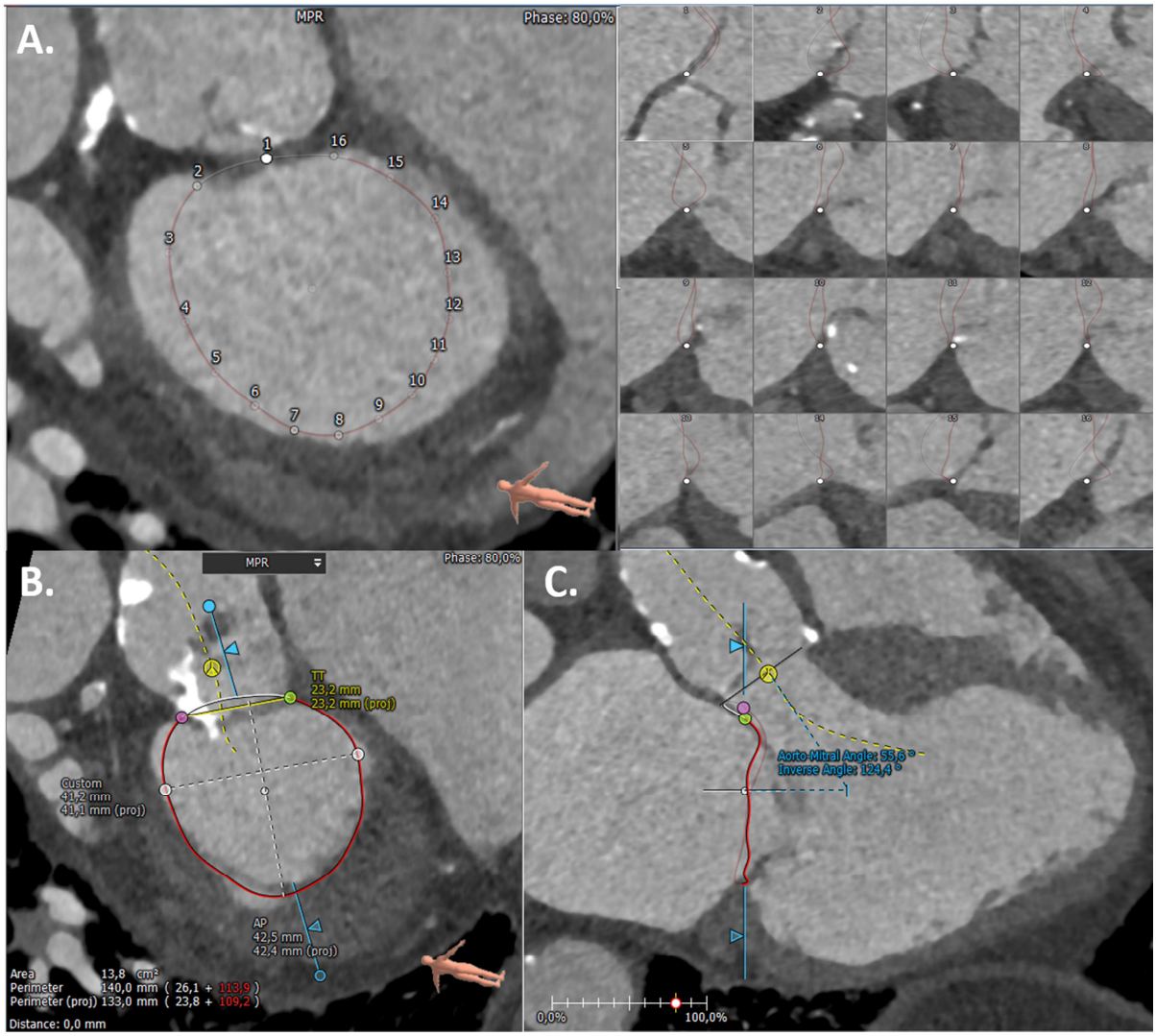

A, Mitral annular segmentation is manually performed using a dedicated software (3mension, Pie Medical Imaging. Bilthoven, The Netherlands) by placing 16 points around the annulus. **B**, the software automatically generates the 3D reconstruction of the mitral annulus with its parameters on a short-axis view and **C**, the corresponding aorto-mitral angle on a 3-chamber view

Figures 3. Bland-Altman plots and correlations for comparison of 3D-TEE and CT mitral annulus measurements. Comparison of A) MA area, B) MA perimeter, C) A-P diameter, D) PM-AL diameter and E) Mitro-aortic angle. P-value by linear regression

A.

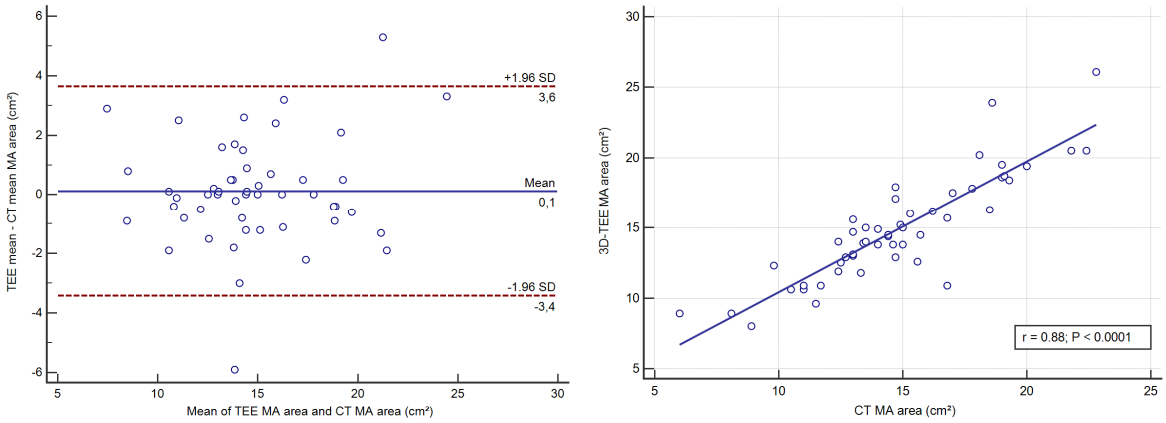

B.

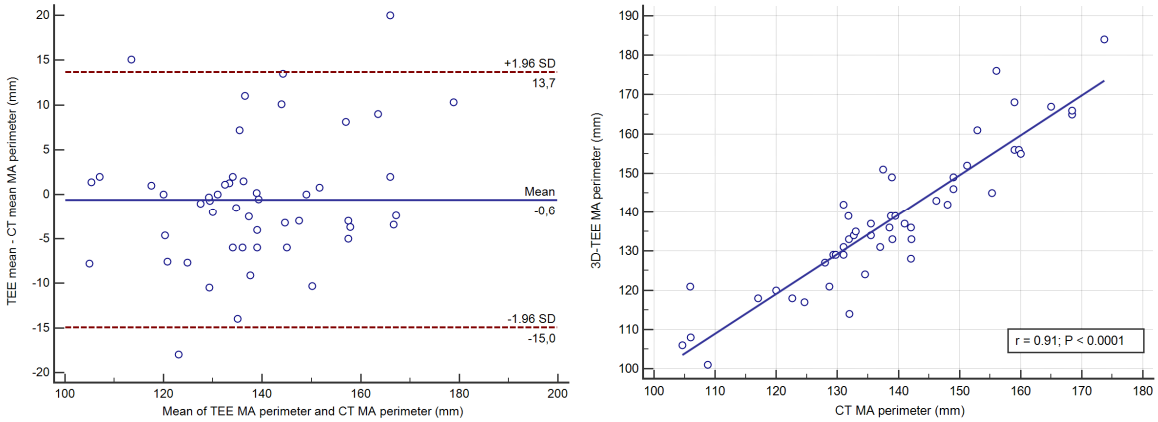

C.

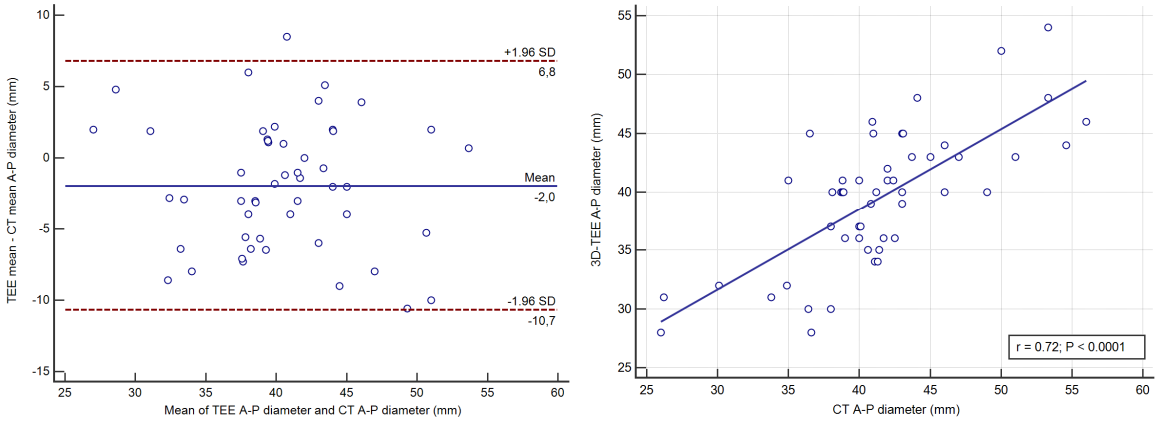

D.

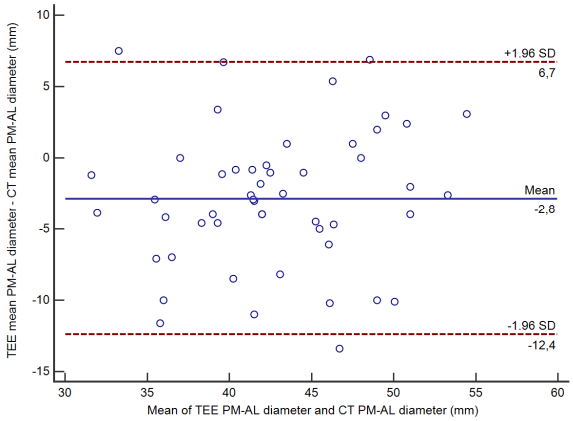
TEE mean PM-AL diameter - CT mean PM-AL diameter (mm)
Mean of TEE PM-AL diameter and CT PM-AL diameter (mm)
+1.96 SD
6,7
Mean
-2,8
-1.96 SD
-12,4

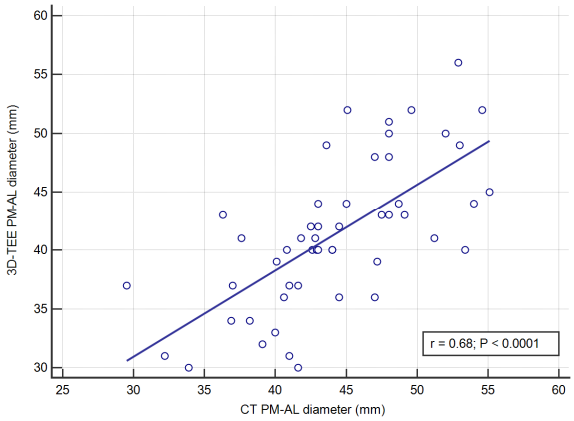
3D-TEE PM-AL diameter (mm)
CT PM-AL diameter (mm)
r = 0.68; P < 0.0001

E.

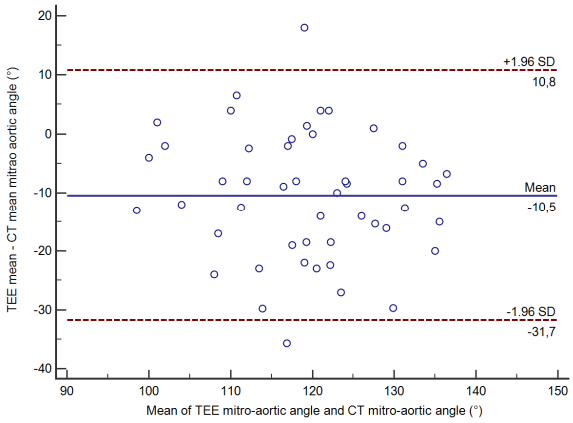
TEE mean - CT mean mitrao aortic angle (°)
Mean of TEE mitro-aortic angle and CT mitro-aortic angle (°)
+1.96 SD
10,8
Mean
-10,5
-1.96 SD
-31,7

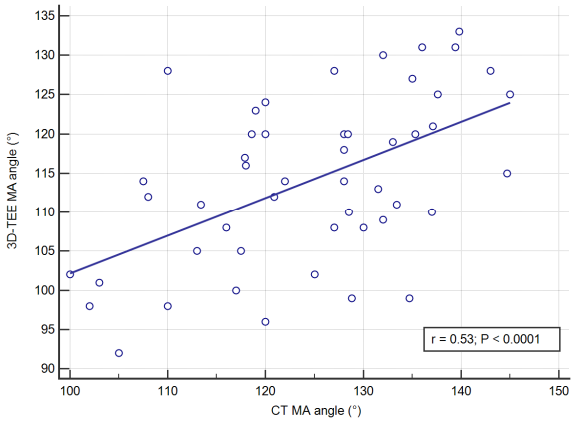
3D-TEE MA angle (°)
CT MA angle (°)
r = 0.53; P < 0.0001
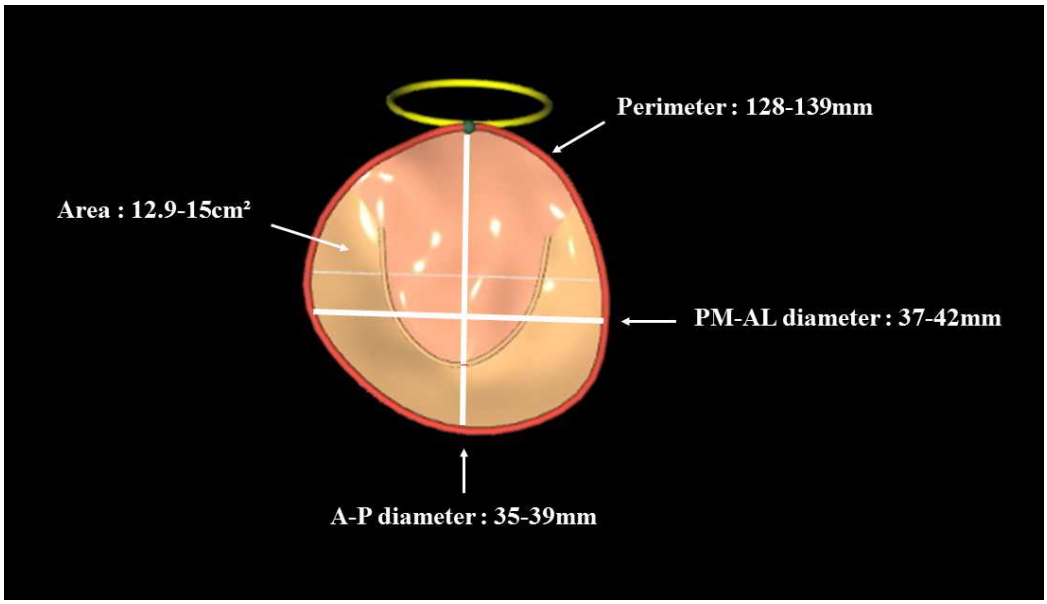
Figure 4. Ranges of 3D-TEE measurements to predict TMVR screening success