



HAL
open science

Deep cutaneous fungal infections in solid-organ transplant recipients

Agnès Galezowski, Julie Delyon, Laurence Le Cleach, Sarah Guégan, Emilie Ducroux, Alexandre Alanio, Diane Lastennet, Philippe Moguelet, Ali Dadban, Marie Thérèse Leccia, et al.

► To cite this version:

Agnès Galezowski, Julie Delyon, Laurence Le Cleach, Sarah Guégan, Emilie Ducroux, et al.. Deep cutaneous fungal infections in solid-organ transplant recipients. *Journal of The American Academy of Dermatology*, 2020, 83 (2), pp.455 - 462. 10.1016/j.jaad.2019.12.064 . hal-03492502

HAL Id: hal-03492502

<https://hal.science/hal-03492502>

Submitted on 18 Jul 2022

HAL is a multi-disciplinary open access archive for the deposit and dissemination of scientific research documents, whether they are published or not. The documents may come from teaching and research institutions in France or abroad, or from public or private research centers.

L'archive ouverte pluridisciplinaire **HAL**, est destinée au dépôt et à la diffusion de documents scientifiques de niveau recherche, publiés ou non, émanant des établissements d'enseignement et de recherche français ou étrangers, des laboratoires publics ou privés.



Distributed under a Creative Commons Attribution - NonCommercial 4.0 International License

1 **Deep cutaneous fungal infections in solid-organ transplant recipients**

2 Agnès Galezowski¹, MD; Julie Delyon², MD, PhD; Laurence Le Cleach³, MD; Sarah
3 Guégan⁴, MD, PhD; Emilie Ducroux⁵, MD; Alexandre Alanio⁶⁻⁷, MD, PhD; Diane Lastennet⁸,
4 MD, PhD; Philippe Moguelet⁹, MD; Ali Dadban¹⁰, MD; Marie Thérèse Leccia¹¹ MD, PhD;
5 François Le Pelletier¹², MD; Camille Francès¹³, MD; Céleste Lebbé², MD, PhD; Stéphane
6 Barete¹, MD, PhD on behalf of Skin and Organ Transplantation Group of the French Society
7 of Dermatology.

8

9 **Author affiliations**

10 ¹ Unit of Dermatology, Pitié-Salpêtrière Hospital, AP-HP, Sorbonne University, UPMC Paris-6, Paris,
11 France

12 ² Department of Dermatology, Saint-Louis Hospital, AP-HP, Paris; INSERM U976; University of
13 Paris Diderot, Sorbonne Paris Cité, France

14 ³ Department of Dermatology, Henri Mondor Hospital, AP-HP, Paris-Est Créteil Val de Marne - Paris
15 12 University, Créteil, France

16 ⁴ Department of Dermatology, Cochin Hospital, AP-HP, Paris Descartes University, Paris, France

17 ⁵ Department of Dermatology, Edouard Herriot Hospital, Lyon, France

18 ⁶ Department of Parasitology-Mycology, Saint-Louis Hospital, AP-HP, Paris Diderot University,
19 Sorbonne Paris Cité, France

20 ⁷ Unit of Molecular Mycology, CNRS UMR 2000, Institut Pasteur, Paris, France

21 ⁸ Unit of Public Health, Department of Biostatistics, Pitié-Salpêtrière Hospital, AP-HP, Sorbonne
22 University, UPMC Paris-6, Paris, France

23 ⁹ Department of Pathology, Tenon Hospital, AP-HP, Paris, France

24 ¹⁰ Department of Dermatology, Amiens University Hospital, Amiens, France

25 ¹¹ Department of Dermatology, Grenoble University Hospital, Grenoble, France

26 ¹² Department of Pathology, Pitié-Salpêtrière Hospital, AP-HP, Paris, France

27 ¹³ Department of Dermatology, Tenon Hospital, AP-HP, Paris, France.

28

29

30 **Corresponding author:**

31 Dr Stéphane BARETE

32 Unit of Dermatology, AP-HP, Hôpital Pitié-Salpêtrière, 47-83 bd de l'Hôpital F-75013 Paris,

33 Sorbonne University, UPMC Paris-6, Paris, France. Phone : + 33 1 42 17 82 43 ; Fax: + 33 1

34 42 17 82 46 ;

35 e-mail: stephane.barete@aphp.fr

36 **Funding sources:** This article has no funding source.

37

38 **Disclosure**

39 AG, SB, JD, LL, SG, PM, FL, DL, AD, MTL, ED, AA, CF, have no conflict of interest to

40 declare

41 CL received research grants or honoraria from Roche, BMS, MSD, GSK, Novartis, Amgen,

42 outside the submitted work.

43

44 **Word count**

45 Abstract: 148

46 Text: 2140

47 Capsule summary: 42

48 References: 17

49 Material: 2 tables; 2 figures; 2 supplementary e-tables; (DOI: 10.17632/mwyp7f6czm.1; DOI:

50 10.17632/6cc6rsk9n2.1)

51 **Author Contributions:**

52 AG, CL and SB conceived and designed the study.

53 AG, SB, JD, LL, SG, PM, FL, AD, MTL, ED, AA, CF, CL participated in data collection and
54 critically reviewed the manuscript.

55 AG, JD, SB participated in writing the paper and contributed to the analysis of study results;

56 DL performed statistics analyses

57 AG, JD, SB participated in revision of the article.

58 **Support:** This study was supported by Skin and Organ Transplantation Group (GPGO) of the
59 French Society of Dermatology.

60 **Acknowledgements:** We are indebted to all contributors of this study, organ transplant
61 specialists and solid-OTR patients and donors.

62 **Keywords:** deep cutaneous fungal infection, phaeohyphomycosis, solid organ transplant
63 recipients, antifungal treatment

64 **ABSTRACT**

65 **Background:** Deep cutaneous fungal infections (DCFIs) are varied in immunosuppressed
66 patients with few data for such infections in solid-organ transplant recipients (s-OTRs).

67 **Objective:** To determine DCFIs diagnostic characteristics and outcome with treatments in s-
68 OTRs.

69 **Methods:** A 20-year retrospective observational study in France was conducted in 8 primary
70 dermatological dedicated centers for s-OTRs diagnosed with DCFIs. Relevant clinical data on
71 transplantation, fungal species, treatments and outcome were analyzed.

72 **Results:** 46 s-OTRs developed DCFIs (median delay: 13 months after transplantation) with
73 predominant phaeohyphomycoses (46%). Distribution of nodular lesions on limbs and
74 granulomatous findings on histopathology were helpful diagnostic clues. Treatments received
75 were systemic antifungal therapies (48%), combined with surgery (28%), surgery alone (15%)
76 and modulation of immunosuppression (61%) leading to complete response in 63% of s-
77 OTRs.

78 **Limitation:** Limits due to observational study

79 **Conclusion:** Phaeohyphomycoses are the most common DCFIs in s-OTRs. Multidisciplinary
80 teams are helpful for optimal diagnosis and management.

81

82

83 Capsule Summary

- 84 • A variety of deep cutaneous fungal infections (DCFIs) occur in solid-organ transplant
85 recipients but phaeohyphomycoses are the most common.
- 86 • DCFIs should be managed by a multidisciplinary team and may require modulation of
87 immunosuppression, systemic antifungal treatment, and/or surgery to obtain complete
88 response.

89

90 INTRODUCTION

91 Deep cutaneous fungal infections (DCFIs) are varied and more frequent in
92 immunocompromised patients, particularly in adult solid-organ transplant recipients (s-
93 OTRs).^{1,2} Few series have reported DCFIs in adult s-OTR patients³⁻⁵. Epidemiological and
94 clinical data, fungal and transplantation parameters as well as therapeutic management are
95 poorly described. Due to the increasing population of s-OTR that are at risk for fungal
96 infections, it is important to better characterize these infections in order to reduce delays in
97 diagnosis and initiate treatment to limit potential fungal dissemination, that would be
98 associated with increased mortality.⁵ This retrospective observational multicenter study was
99 conducted in France to determine DCFIs diagnostic characteristics and outcome with
100 treatments in s-OTRs.

101

102

103 PATIENTS AND METHODS

104 Epidemiological, clinical, fungal and transplantation parameters were retrospectively
105 collected in solid-OTR diagnosed with DCFI in centers belonging to Skin and Organ
106 Transplantation Group of the French Society of Dermatology (GPGO for Groupe Peau et
107 Greffe d'Organe).

108 Solid-OTR adult cases were included if they had a proven diagnosis of invasive fungal
109 infection as defined by EORTC-Mycoses Study Group.⁶ DCFI was determined as a dermal
110 fungal infection, including systemic fungal infection with cutaneous involvement, in
111 opposition to superficial fungal infection, excluded from the series. DCFI was considered
112 primary, if any extracutaneous organ was involved at diagnosis. S-OTRs cases were selected
113 if they had cutaneous lesions available for samples investigations (pathological and/or fungal
114 analysis). Diagnosis was assessed by pathological criterion or direct cytopathological criteria

115 (molds or hyphae) associated with either tissue infiltration or filamentous molds in culture.
116 Patients gave their informed consent in accordance with Helsinki ethical statement.
117 We collected data including epidemiological (sex, date of diagnosis, geographic origin),
118 clinical (description of cutaneous lesions, number of lesions, trauma before DCFI, duration
119 between transplantation and onset of the DCFI) and transplantation characteristics (age at
120 transplantation, types of organ transplants, immunosuppressive (IS) drugs and their adverse
121 events including malignancies and infections). DCFI diagnosis was based on pathological
122 analysis (i.e. Hematoxylin Eosin Saffron (HES) and periodic acid–Schiff (PAS) and/or
123 Gomori-Grocott methenamine silver stains) and fungal identification (culture and/or PCR
124 methods). Cases with undetermined DCFI fungal identification were not included. Fungal
125 species were identified with standard microbiological methods in each participating center. A
126 minority of fungal species identification was assessed by PCR method (data not shown) as
127 many samples appeared in a period without this diagnosis method. S-OTRs patients with
128 DCFI were treated according to local practices depending on therapeutic options in each
129 center. Specific treatments for DCFIs were classified as medical treatment, including systemic
130 or local antifungal treatment, surgery, or combined treatments. Efficacy of treatments for
131 DCFI was evaluated at each visit by a global assessment of clinical, microbiologic and
132 radiographic responses (when available), and classified as complete (CR) or partial (PR)
133 response, progression under treatment (Pro), resistance (R) or death (D), as previously
134 published.⁷ CR was the resolution of all attributable signs, symptoms, and radiographic
135 abnormalities (if ever) present at baseline with fungal eradication; PR was their improvement
136 greater than 50% (reduction of number or size for unique lesion); Pro was defined as increase
137 of size or number of lesions. R was defined as the inefficacy of treatment to reduce cutaneous
138 lesion.

139 According to the current taxonomy, homogeneous fungal categories relevant for clinicians
140 and mycologists were defined.^{8,9} Six fungal opportunistic categories were *a posteriori* settled
141 with a centralized mycological analysis: phaeohyphomycoses (alternarioses, coelomycetes),
142 hyalohyphomycoses, scytalidium infections, cryptococcoses-histoplasmoses, mycetomas and
143 miscellaneous DCFIs.¹⁰⁻¹²

144

145 **STATISTICAL METHODS**

146 Categorical variables were summarized as counts and percentages and quantitative variables
147 as medians and interquartile ranges where appropriate.

148 Comparisons on qualitative variables (type of transplant, type and number of
149 immunosuppressive drugs, clinical distribution of lesions and treatment responses according
150 to fungal pathogens) were performed with Fisher's Exact test.

151

152

153 **RESULTS**

154 **Demographic and transplantation data**

155 Forty-six patients diagnosed from 1998 to 2016 from 8 centers were included in the study.

156 The median age at diagnosis was 56.5 years (16-72 years) with a male to female sex ratio of
157 2.54. Forty-eight percent of patients originated from Europe. Characteristics of solid-OTR
158 with DCFIs are reported in **Table 1**. Median and mean delays between transplantation and
159 diagnosis of DCFI were respectively 13.4 and 28 months (2-144 months). Patients were
160 transplanted at a mean age of 53.5 years (16-72 years). Most frequent transplanted organs
161 were renal (n=31, 67%) and heart (n=5, 11%). IS drug regimens at diagnosis of DCFI were
162 triple (n=30), double (n=13), quadruple (n=1), or single (n=1). IS drug regimens included
163 prednisone (n=43), calcineurin inhibitors (CNI) (n=41, including 7 patients with tacrolimus),
164 mycophenolate mofetil (MMF) (n=31), cyclosporine (CsA) (n=3), azathioprine (n=2), and
165 everolimus (n=1).

166

167 **Clinical characteristics**

168 Local trauma on exposed skin areas preceding infection occurred in 7 patients (15%).

169 DCFIs were primary and not spread from a systemic infection in 41 cases (89 %). The mean
170 delay between occurrence of cutaneous lesions and DCFI diagnosis was 4 months. Cutaneous
171 lesions predominated statistically on lower limbs (n=24, 52%) in most DCFI categories
172 (P=0.006). 54% of patients had one or two lesions (**Figure 1**). Lesions were polymorphic:
173 nodules and/or papules (n=26, 56%), abscess (n=7, 15%), cellulitis/ panniculitis or
174 inflammatory plaques (n=6, 13%), ulcerated or necrotic lesions (n=4, 9%), or other (blisters
175 (n=1), proliferative lesion (n=1), not specified (n=1)).

176

177

178 **Histopathology findings**

179 Pathological cutaneous analysis was available for 40 patients. Pathological features showed
180 multinucleated giant cells granulomas (n=20, 50%), suppurative granulomas (n=13, 32.5%) or
181 dermal fibrosis (n=4, 10%) (**Figure 2A**). The analysis was non-specific for 3 cases. Specific
182 histochemical staining with either Periodic acid-Schiff or Grocott methenamine silver was
183 positive in 24 cases (60%), and both were positive in 19 cases (47.5%). Fungal filaments were
184 detected in 18 cases (45%) and hyphae and yeast in 4 cases.

185

186 **Fungal species identification**

187

188 Following the recent taxonomic literature, six different DCFI categories related to fungal
189 species identifications were observed (**Table 2**). Phaeohyphomycoses (n=21, 46%) (**e-Table**
190 **1**) were the most frequently diagnosed DCFI including 16 cases of alternariosis (35%)
191 (**Figure 1B, 1C, 1D**). Hyalohyphomycoses were diagnosed in 8 cases (17%) including 4
192 patients with aspergillosis. Six patients had cryptococcosis, 2 had histoplasmosis.
193 Scytalidioses were diagnosed in 4 cases (9%) (**Figure 2E, 2F**). Only 2 cases of *Madurella spp*
194 mycetomas, one case of candidiasis and one case of *Pityrosporum spp* were observed. Further
195 analyses to investigate the proportion of DCFI categories according to the type of organ
196 transplanted, type of IS drug regimens (CNI versus MMF), and number of IS drugs (≤ 2 versus
197 ≥ 3) did not show significant differences between DCFI categories for these analyses (P=0.42,
198 P=0.86, P= 0.60, respectively).

199

200 **Therapeutic management**

201 Treatments included systemic antifungal drugs alone (n=22; 48%), surgery alone (n=7; 15%),
202 and surgery combined with systemic antifungal drugs (n=13; 28%). (**e-Table 2**). One patient
203 died within two days of diagnosis without specific treatment. Most patients (n= 35; 76%)

204 received systemic antifungal drugs as monotherapy: voriconazole (n=12; 26%), liposomal-
205 amphotericin B (n=7; 15%), itraconazole (n=1), posaconazole (n=3; 6.5%), flucytosine, (n=4;
206 9%), fluconazole (n=4; 9%), terbinafine hydrochloride (n=1), caspofungin (n=1). Median
207 duration of treatment was 2.5 months (0.5 to 33 months).

208 Immunosuppressive drug regimens were modified for 28 patients (61%) (**e-Table 2**). In 9
209 patients, one (n=7) or two IS drugs (n=2) were withdrawn including 8 cases for MMF drug. In
210 19 patients, tapering of one (n=12) or two (n=7) IS drugs was performed. Three patients
211 underwent switch of their IS drugs (2 switches from MMF to azathioprine, 1 switch from
212 azathioprine to MMF).

213

214 **Outcome and evolution**

215 During a median follow-up period of 45 months, 29 patients had complete remission, 7 had
216 progression, 3 were resistant to treatment, and 2 died before evaluation (7 and 11 days after
217 DCFI diagnosis). In addition, 5 patients were lost to follow-up (**e-Table 2**).

218 Among patients with complete remission (n=29), 6 had relapses and required additional
219 systemic antifungal treatments to reach complete remission.

220 Among patients with progression (n=7), 4 had subsequent complete remission after systemic
221 antifungal treatment initiation, 2 died of DCFI-unrelated causes at 1.5 and 3 months after the
222 diagnosis, and the DCFI was still present for 1 patient at the end of the study.

223 Among patients resistant to treatment (n=3), 1 required surgery and additional systemic
224 antifungal treatment to reach complete remission.

225 During follow-up, 14 patients (30%) died of DCFI-unrelated causes. Among 8 patients, two
226 had acute organ rejections (heart/ liver), two had pneumocystis pneumonia, one had bacterial
227 septic shock, one had pulmonary embolism, one had HTLV-1 lymphoma progression, and

228 another had advanced epidermoid carcinoma of the head. The remaining 6 patients died of
229 undetermined causes.

230

231

232 **DISCUSSION**

233 This multicenter observational study has highlighted a large diversity of DCFIs in solid-OTR
234 in France. Primary DCFI in s-OTRs occurred mostly in the first two years after
235 transplantation, which is in line with a previous series of 22 s-OTRs patients in Italy, the
236 single and last series reported in Europe.¹³ In this case-control multicentric cohort
237 retrospective study, risk factors reported for DCFI were the first 2 years period after
238 transplantation, being a renal transplant recipient, being transplanted after the age of 50 years.
239 In our observational study, without available s-OTRs controls, these risks were not
240 determined. However, DCFIs appeared also in a majority of renal transplant patients (above
241 70%), at a mean age of transplantation of 53.5 years. Phaeohyphomycoses in our series were
242 the most frequent DCFIs representing a prevalence of 46%. This high prevalence has been
243 previously reported in a series of 30 solid-OTR patients in USA.¹⁴ Among these
244 phaeohyphomycoses, a 76% rate of *Alternaria spp* was observed. This high proportion of this
245 pigmented fungus in DCFIs might be linked to its common detection in the soil environment
246 and its ability to penetrate skin by local trauma circumstance described in some
247 immunocompromised patients.^{3,4} Looking at proportions across the six categories of DCFI
248 identified, there was no statistical association with the type of organ transplanted, type of IS
249 drug regimens, number of IS drugs prescribed. The mean delay between onset of cutaneous
250 lesions and DCFI diagnosis was 4 months. This quite long delay may be explained by the
251 heterogeneous clinical presentations of DCFIs observed and the lack of expertise of general
252 practitioners for dermatological issues for S-OTRs patients. However, solitary or multiple
253 nodular lesions on limbs and particularly on lower limbs, on exposed body parts, associated
254 with granulomatous pathological pattern are very suggestive of DCFIs, especially if the fungal
255 specific staining is positive in skin sample after biopsy.¹⁵ Alternatively, DCFIs should be
256 suspected in cases of resistance of cutaneous lesions to initial antibiotics prescription, and

257 thus require multiple investigations for microbiological analyses including fungal culture
258 from skin biopsy. However, some cases might exhibit these suggestive elements for DCFIs
259 but lack despite investigations for a definite fungal identification. In these difficult cases, any
260 consensus is reported but one might repeat fungal investigations and be prone to initiate
261 treatment for DCFI after elimination of other non-infectious diagnosis.

262 One of the main goals of treatment of DCFIs in solid-OTR is preventing to prevent a life-
263 threatening fungal dissemination. In our study, no disseminated fungal infection after primary
264 DCFI diagnosis nor direct DCFI-related death occurred. If this mortality has been reported for
265 up to 4-10 % of patients⁵ for localized DCFIs, we believe that new high potency systemic
266 antifungal treatments have modified this outcome. Indeed, systemic antifungal treatment
267 alone or combined with surgery was used in 76% of patients and led to complete response in
268 57% of cases. Among 89% of patients with follow-up, 63% had complete response with
269 treatments with no significant differences according to DCFI categories. The reasons for
270 failure of initial treatment are multiple and difficult to assess regarding for example
271 insufficient tapering of IS drug regimen, inappropriate dose of specific systemic anti-fungal
272 therapy, bad compliance of the patient. Moreover, 30% of patients in our cohort had died in
273 the first 3 years after DCFI diagnosis. This may be explained in part by the high level of
274 immunosuppression that the occurrence of DCFIs reveal and by other associated infections,
275 organ transplant rejections and other vascular or cancer causes in these patients. Considering
276 immunological treatment, modulation of immunosuppression was associated to specific
277 antifungal treatment in 61% of patients. It was mostly based on IS drugs tapering or
278 withdrawing of mycophenolate mofetil in addition with the necessity to adapt systemic
279 antifungal interaction especially voriconazole and posaconazole with CNI as previously
280 reported in phaeohyphomycoses.¹⁶ This IS modulation when feasible is considered very
281 important for the DCFI outcome by analogy to management of systemic invasive fungal

282 infection.¹⁷ To both validate IS modulation and optimize individualized antifungal
283 treatments, a specific management in good collaboration with organ transplant specialists and
284 the multidisciplinary network was required.

285

286 **CONCLUSION**

287 This observational study has highlighted the large diversity of DCFIs observed in organ
288 transplant recipients with the highest prevalence of phaeohyphomycoses. Nodular lesions on
289 lower limbs and granulomatous findings on histopathology were helpful diagnostic clues. An
290 appropriate therapeutic management by a multidisciplinary team of dermatologists, transplant
291 specialists, pathologists and mycologists, based on specific mostly systemic antifungal
292 treatment, surgery and IS modulation, is required to obtain complete DCFI remission.

293 **ACKNOWLEDGMENT SECTION**

294 We are indebted to all contributors of this study, organ transplant specialists and solid-OTR

295 patients and donors.

296

297 **Abbreviation and acronym list:**

298 DCFI: deep cutaneous fungal infection; s-OTRs: solid organ transplant recipient; HES:

299 Hematoxylin Eosin Saffron; PAS: periodic acid–Schiff; IS: immunosuppressive drugs; CNI:

300 calcineurin inhibitor; MMF: mycophenolate mofetil; BCC: basal cell carcinoma; SCC:

301 squamous cell carcinoma

302

303 **REFERENCES**

- 304 1. Miele PS, Levy CS, Smith MA, Dugan EM, Cooke RH, Light JA et al. Primary cutaneous
305 fungal infections in solid organ transplantation: a case series. *Am J Transplant* 2002;2:678-83.
- 306 2. Patterson JE. Epidemiology of fungal infections in solid organ transplant patients. *Transpl*
307 *Infect Dis* 1999;1:229-36.
- 308 3. Boyce RD, Deziel PJ, Otley CC, Wilhelm MP, Eid AJ, Wengenack NL et al.
309 Phaeohyphomycosis due to *Alternaria* species in transplant recipients. *Transpl Infect Dis*
310 2010;12:242-50.
- 311 4. Diernaes JE, Hjuler KF, Kristensen L , Deleuran M. Subcutaneous Phaeohyphomycosis due
312 to *Alternaria dennisii* in an Immunocompromised Patient. *Acta Derm Venereol* 2016;96:701-
313 2.
- 314 5. Gonzalez Santiago TM, Pritt B, Gibson LE , Comfere NI. Diagnosis of deep cutaneous
315 fungal infections: correlation between skin tissue culture and histopathology. *J Am Acad*
316 *Dermatol* 2014;71:293-301.
- 317 6. De Pauw B, Walsh TJ, Donnelly JP, Stevens DA, Edwards JE, Calandra T et al. Revised
318 definitions of invasive fungal disease from the European Organization for Research and
319 Treatment of Cancer/Invasive Fungal Infections Cooperative Group and the National Institute
320 of Allergy and Infectious Diseases Mycoses Study Group (EORTC/MSG) Consensus Group.
321 *Clin Infect Dis* 2008;46:1813-21.
- 322 7. Segal BH, Herbrecht R, Stevens DA, Ostrosky-Zeichner L, Sobel J, Viscoli C et al.
323 Defining responses to therapy and study outcomes in clinical trials of invasive fungal
324 diseases: Mycoses Study Group and European Organization for Research and Treatment of
325 Cancer consensus criteria. *Clin Infect Dis* 2008;47:674-83.
- 326 8. Hibbett DS, Binder M, Bischoff JF, Blackwell M, Cannon PF, Eriksson OE et al. A higher-
327 level phylogenetic classification of the Fungi. *Mycological research* 2007;111:509-47.

- 328 9. Revankar SG , Sutton DA. Melanized fungi in human disease. *Clinical microbiology*
329 *reviews* 2010;23:884-928.
- 330 10. Gramaje D, Mostert L, Groenewald JZ , Crous PW. *Phaeoacremonium*: from esca disease
331 to phaeohyphomycosis. *Fungal biology* 2015;119:759-83.
- 332 11. Reblova M, Jaklitsch WM, Reblova K , Stepanek V. Phylogenetic Reconstruction of the
333 *Calosphaerales* and *Togniniales* Using Five Genes and Predicted RNA Secondary Structures
334 of ITS, and *Flabellascus tenuirostris* gen. et sp. nov. *PloS one* 2015;10:e0144616.
- 335 12. Valenzuela-Lopez N, Cano-Lira JF, Stchigel AM , Guarro J. DNA sequencing to clarify
336 the taxonomical conundrum of the clinical coelomycetes. *Mycoses* 2018;61:708-17.
- 337 13. Tessari G, Naldi L, Piaserico S, Boschiero L, Nacchia F, Forni A et al. Incidence and
338 clinical predictors of primary opportunistic deep cutaneous mycoses in solid organ transplant
339 recipients: a multicenter cohort study. *Clin Transplant* 2010;24:328-33.
- 340 14. McCarty TP, Baddley JW, Walsh TJ, Alexander BD, Kontoyiannis DP, Perl TM et al.
341 *Phaeohyphomycosis* in transplant recipients: Results from the Transplant Associated Infection
342 Surveillance Network (TRANSNET). *Med Mycol* 2015;53:440-6.
- 343 15. Schieffelin JS, Garcia-Diaz JB, Loss GE, Jr., Beckman EN, Keller RA, Staffeld-Coit C et
344 al. *Phaeohyphomycosis* fungal infections in solid organ transplant recipients: clinical
345 presentation, pathology, and treatment. *Transpl Infect Dis* 2014;16:270-8.
- 346 16. Ferrándiz-Pulido C, Martin-Gomez MT, Repiso T, Juárez-Dobjanschi C, Ferrer B, López-
347 Lerma I, et al. Cutaneous infections by dematiaceous opportunistic fungi: Diagnosis and
348 management in 11 solid organ transplant recipients. *Mycoses* 2019;62:121-127.
- 349 17 Welte T, Len O, Muñoz P, Romani L, Lewis R, Perrella A. Invasive mould infections in
350 solid organ transplant patients: modifiers and indicators of disease and treatment response.
351 *Infection*. 2019 Oct 1. doi: 10.1007/s15010-019-01360-z.
- 352

353 **Table 1: Characteristics of solid-OTR with DCFIs**

Characteristics of solid-OTR patients (N=46)	N (%)
Age at diagnosis median (range) years	56.5 (16 – 72)
Sex: male / female	33 (72) / 13 (28)
Geographic origins	-
Europe	22 (47.8)
Sub-Saharan Africa	8 (17.4)
North Africa	6 (13)
Overseas French territories	4 (8.7)
Asia	1 (2.2)
NA	5 (11)
Transplanted organs	-
Renal	31 (67.54)
Heart	5 (11)
Liver	3 (6.5)
Renal-liver	3 (6.5)
Lung	2 (4.3)
Heart-lung	2 (4.3)
History of local trauma	7 (15.2)
Number of cutaneous lesions	-
1	24 (52)
2	1 (2)
≥ 3	21 (45.6)
Extent of the infection at diagnosis	-
Primary cutaneous	41 (89.1)
Systemic	5 (10.9)
Localization of cutaneous lesions	-
Lower limbs	24 (52.1)
Upper limbs	14 (30.4)
Diffuse	7 (15.2)
Trunk	1 (2.2)
Types of lesions	-
Nodule and/or papule	26 (56.5)
Abscesses	7 (15.2)
Cellulitis/ panniculitis / inflammatory plaques	6 (13)
Ulcerated and/or necrotic lesions	4 (8.7)
Blisters	1 (2.1)
Proliferative lesion	1 (2.1)
NA	1 (2.1)

354 NA for not available; DCFIs for deep cutaneous fungal infections; Solid-OTR for organ transplant recipients

355

356 **Table 2: Fungal species identifications from DCFIs**
 357

Fungal species	N (%)
Phaeohyphomycoses	21
Alternarioses (<i>Alternaria sp</i> , <i>A. infectoria</i> , <i>A. alternata</i>)	(45.7)
<i>Exophiala spp</i> (<i>Exophiala janselmei</i> , <i>E. lecanii-corni</i>)	16
<i>Medicopsis romeroi</i>	(34.8)
<i>Pleurostoma richardsiae</i>	2 (4.3)
<i>Pheoacremonium parasiticum</i>	1 (2.2)
	1 (2.2)
	1 (2.2)
Hyalohyphomycoses	8 (17.5)
Aspergilloses (<i>Aspergillus fumigatus</i> , <i>Aspergillus flavus</i> , <i>Aspergillus sp</i>)	4 (8.7)
<i>Scedosporium apiospermum</i>	2 (4.3)
<i>Phialemonium dimorphosporum</i>	1 (2.2)
<i>Paecilomyces sp.</i>	1 (2.2)
Cryptococcoses /histoplasmoses	8 (17.5)
Cryptococcoses	6 (13)
Histoplasmoses	2 (4.3)
Scytalidioses	4 (8.7)
Mycetoma	2 (4.3)
Miscellaneous DCFIs not clustered	3 (6.6)

358 DCFIs for deep cutaneous fungal infections

359

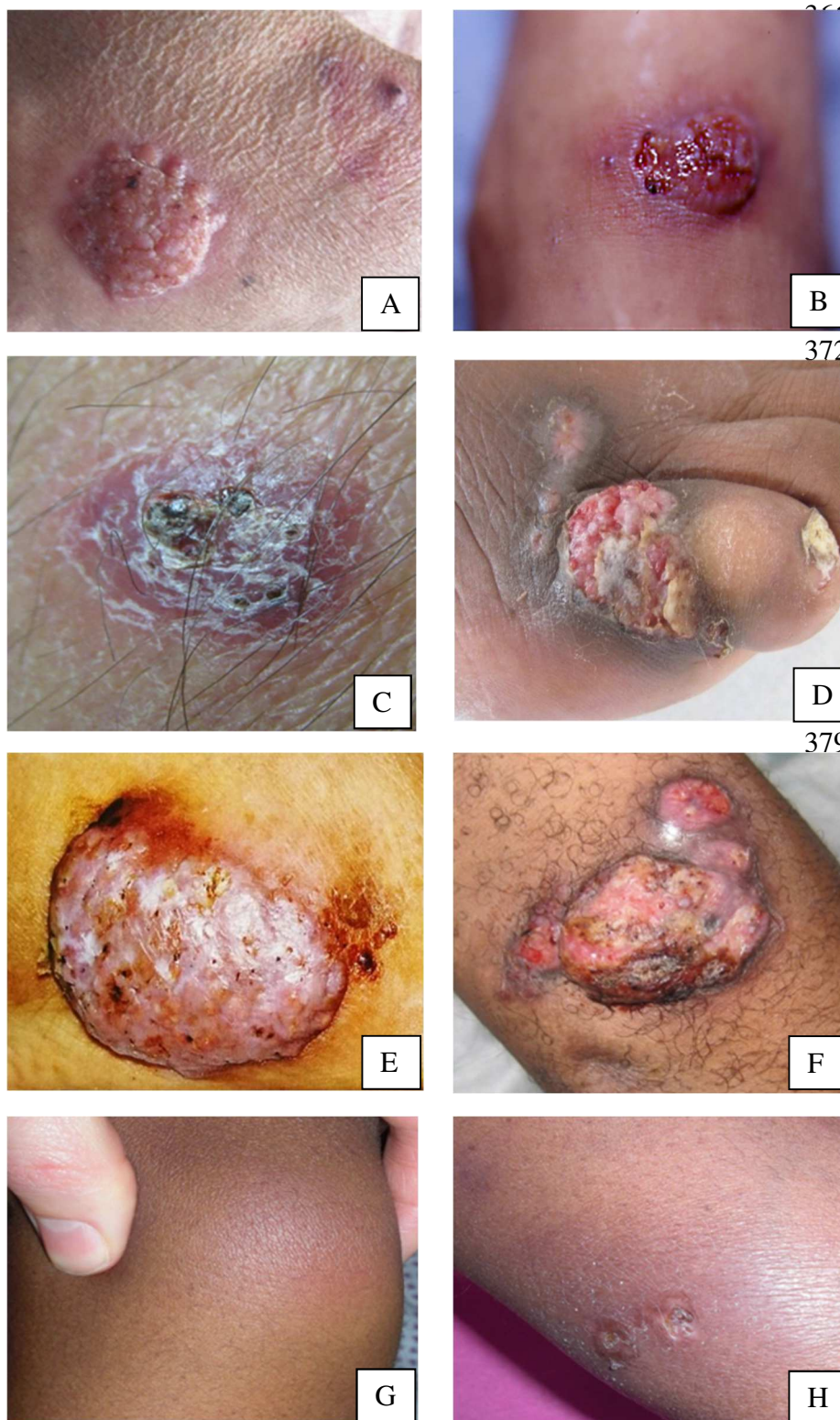
360 **Figures of legends**

361 **Figure 1: Representative cases of DCFIs in solid-OTR**

362

363 **Figure 2: Pathological and mycological analyses of alternariosis and scytalidiosis cases**

364

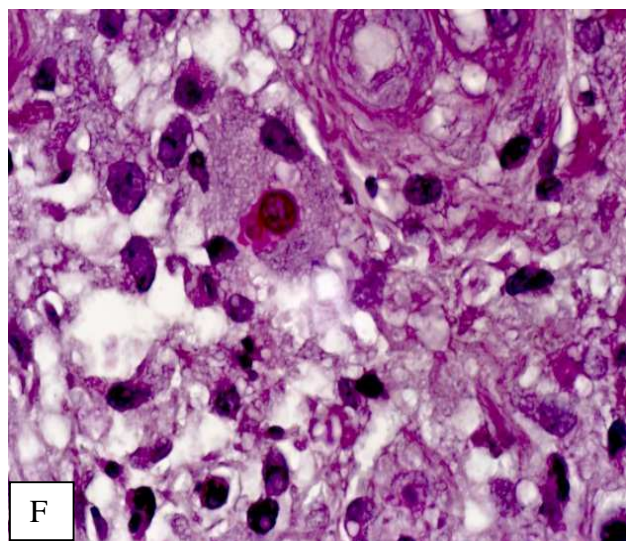
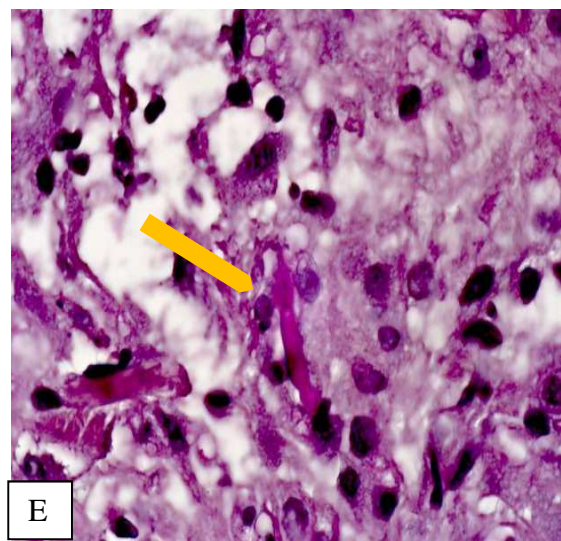
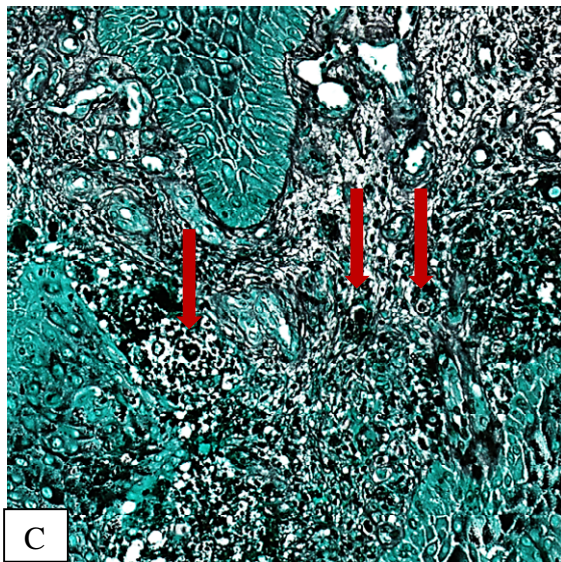
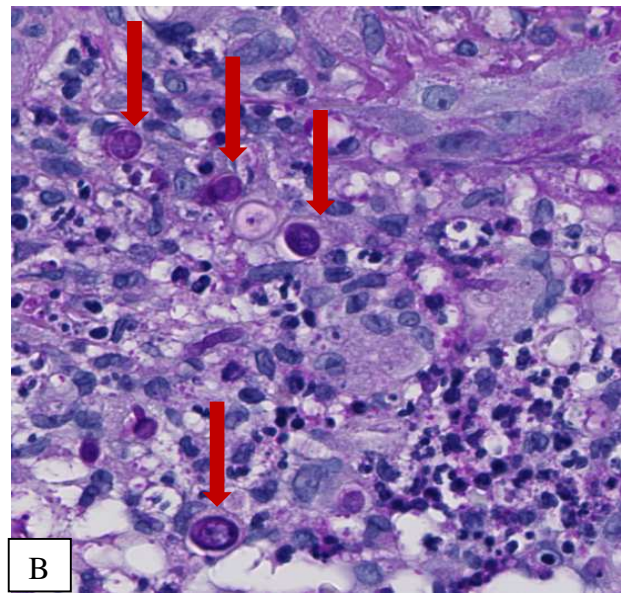
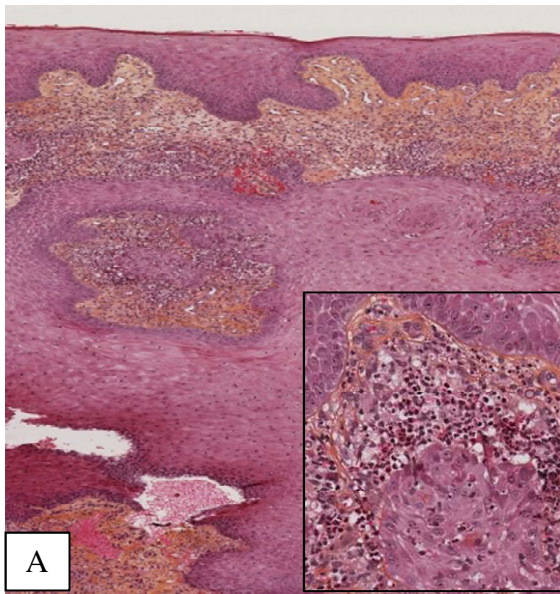
365 **Figure 1. Representative cases of DCFIs in solid-OTR**

392 **A, B and C:** cutaneous lesions due to *Alternaria sp*; **D:** *Scytalidium sp*; **E:** *Scytalidium*
 393 *dimidiatum*; **F:** *Madurella pseudomycetomatis*; **G and H:** *Histoplasma capsulatum*

394

395

396 **Figure 2. Pathological and mycological analyses of alternariosis and scytalidiosis cases**



407 **Alternariosis pathological and mycological analyses (A, B, C, D):**

408 **A:** multinucleated giant cells granuloma (HES) with a close-up square (X 200 magnification)

409 **B:** Hyphae and yeast in the dermis (specific histochemical stain with Periodic acid-Schiff)

410 **C:** Hyphae and yeast (indicated by red arrows) in the dermis (specific histochemical stains
411 with Grocott methenamine silver)

412 **D:** Microscopic visualization of dictyospores of *Alternaria alternata* upon culture (X 400
413 magnification).

414

415 **Neoscytalidium pathological analysis with HES (E, F):**

416 **E:** Fungal filaments (yellow arrow)

417 **F:** Pathological features showed multinucleated giant cells granuloma

418

419

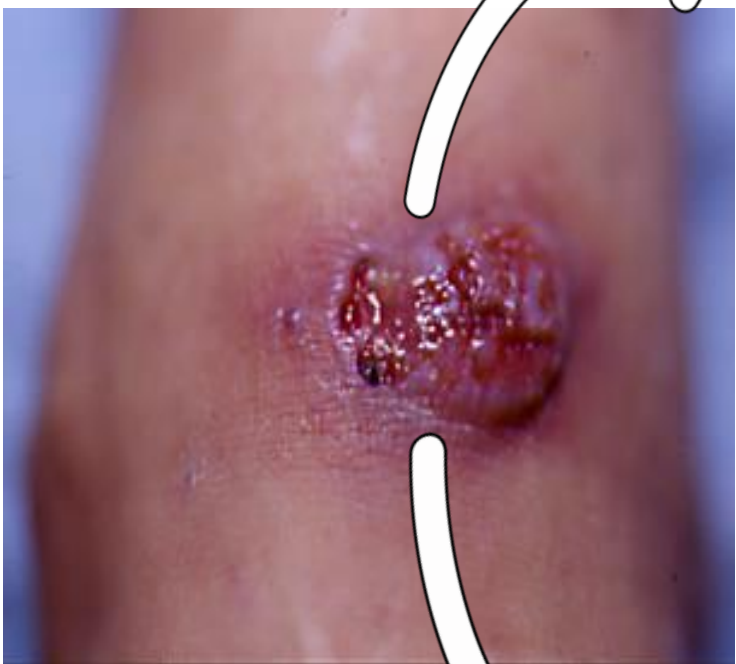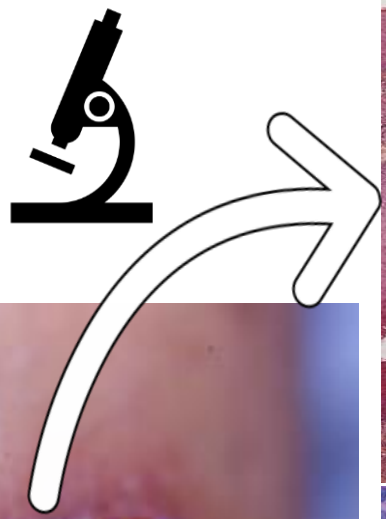
420

421

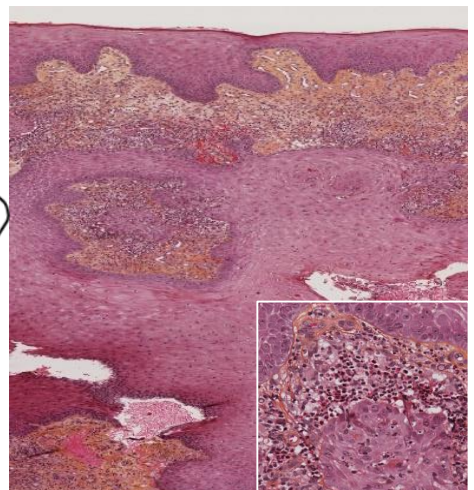
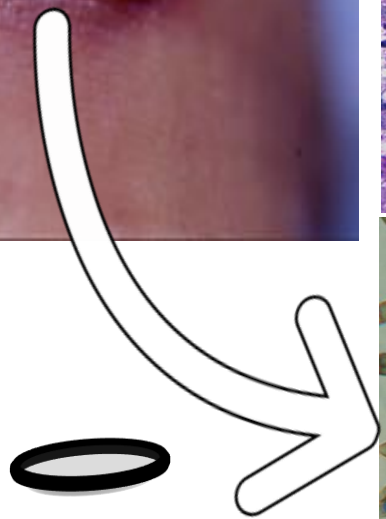D
C
F
I

S
U
S
P
E
C
T
E
D

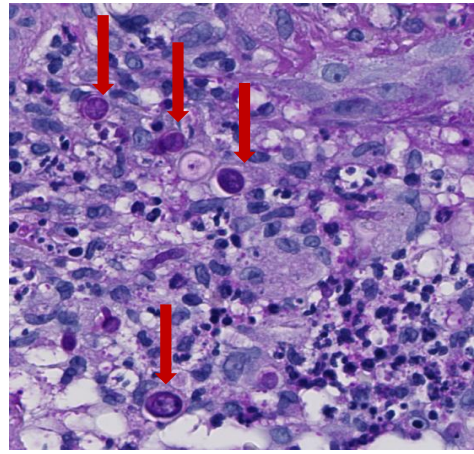
Biopsy for pathology analysis from a leg nodular lesion (specific stains)



Biopsy for Fungal species identification (culture)

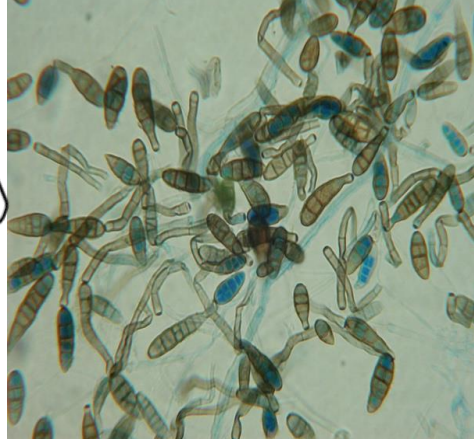

Skin pathology with dermal multinucleated giant cell granuloma (close-up)



Specific fungal stain (Periodic acid-schiff) for hyphae and yeast (red arrows)

DCFI confirmed: multidisciplinary therapeutic management



Fungal culture identification for *Alternaria alternata*

Modulation of immunosuppressive drug regimen

Systemic antifungal treatment

Surgery alone or combined