



HAL
open science

Implant-borne rehabilitation for alveolar dental cleft: Retrospective analysis of thirty-nine cases

I. Saint-Surin, T. Roman, S. Touzet-Roumazeille, J. Ferri, L. Lauwers

► To cite this version:

I. Saint-Surin, T. Roman, S. Touzet-Roumazeille, J. Ferri, L. Lauwers. Implant-borne rehabilitation for alveolar dental cleft: Retrospective analysis of thirty-nine cases. *Journal of Stomatology, Oral and Maxillofacial Surgery*, 2020, 121, pp.339 - 343. 10.1016/j.jormas.2019.10.007 . hal-03492396

HAL Id: hal-03492396

<https://hal.science/hal-03492396v1>

Submitted on 21 Sep 2022

HAL is a multi-disciplinary open access archive for the deposit and dissemination of scientific research documents, whether they are published or not. The documents may come from teaching and research institutions in France or abroad, or from public or private research centers.

L'archive ouverte pluridisciplinaire **HAL**, est destinée au dépôt et à la diffusion de documents scientifiques de niveau recherche, publiés ou non, émanant des établissements d'enseignement et de recherche français ou étrangers, des laboratoires publics ou privés.



Distributed under a Creative Commons Attribution - NonCommercial 4.0 International License

IMPLANT-BORNE REHABILITATION FOR ALVEOLAR DENTAL CLEFT: RETROSPECTIVE ANALYSIS OF THIRTY-NINE CASES

I Saint-Surin^{1*}, T Roman², S Touzet-Roumazeille³, J Ferri⁴, L Lauwers³

1. Interne en Chirurgie Orale, CHRU de Lille, Hôpital Salengro & Centre Abel Caumartin, France
2. Interne en Médecine Bucco-Dentaire, CHRU de Lille, Centre Abel Caumartin, France
3. Université Lille 2 Droit et Santé, F-59000, Lille, France; Oral and Maxillofacial Department, Roger Salengro Hospital, CHU Lille, F-59000, Lille, France.
4. Université Lille 2 Droit et Santé, F-59000, Lille, France; Oral and Maxillofacial Department, Roger Salengro Hospital, CHU Lille, F-59000, Lille, France; INSERM, U1008, Controlled Drug Delivery Systems and Biomaterials, F-59000, Lille, France.

*Corresponding author: isabelle.saints@gmail.com; 35 rue de Prague, 59777 Lille.

ABSTRACT

Introduction. Dental rehabilitation of patients with alveolar-dental cleft sequelae is a crucial issue in the final stages of functional and aesthetic management of these patients. The objectives of this study are to establish the success of implant-supported rehabilitations for patients with alveolar dental cleft sequelae followed in the Department of Maxillofacial Surgery and Stomatology of Lille University Hospital and the reasons for not using this type of rehabilitation for others.

Materials and method. Patients treated between January 2009 and December 2018 with implant-supported prostheses at an alveolar dental cleft site were included. Dental implants were placed after a complementary alveolar bone graft. Clinical and radiological criteria regarding periodontal, occlusal and prosthetic status were studied.

Results. A total of 12 implants in 8 patients were placed. One of these implants was lost, resulting in an implant survival rate of 91.7%. All patients were able to benefit from functional rehabilitation.

Discussion. The present results demonstrate the interest and reliability of implant rehabilitation in these patients. They furthermore highlight financial factors as a barrier to using this solution among the majority of patients in care.

KEY WORDS

- Alveolar dental cleft
- Implant
- Prosthesis
- Periodontal
- Marginal bone loss
- Occlusion

1. INTRODUCTION

Congenital malformation is very common (1.55 cases per 1000 births in Europe [1]): orofacial clefts are almost always associated with dental agenesis [2; 3]. In addition to a multidisciplinary treatment from an early age, patients with orofacial clefts must also complete prosthetic rehabilitation. Often complex, the prosthetic treatment is further complicated in the case of alveolar dental cleft (ADC) by a lack of periodontal tissue. Several therapeutic choices are currently possible for a patient with ADC. Orthodontic treatments which aim to close edentulous spaces associated with overall aesthetic rehabilitation are a systematic choice for some patients. Nevertheless, an optimal position of the teeth is impossible in 10 to 50% of cases [4] making the final aesthetic result debatable. Conventional prosthetic treatments involve either fixed rehabilitations - at the cost of dental dilapidation and occlusal compromises, using bridges with complete or partial peripheral preparations - or removable rehabilitations, which are often difficult for young people to accept.

Moreover, these prosthetic rehabilitations, following occlusal compromises, can encourage bone resorptions, especially on the site of the old cleft or on its periphery.

Implanted rehabilitations offer an elegant, effective and easily accepted solution for patients.

Recently, survival rates of over 90.5% at three year follow-up have been reported [5]. However, an implant treatment plan involves many stages, including primary and often secondary grafts in the case of ADC, implant surgery, one or more mucosal surgeries and, finally, prosthetic rehabilitation. The success of the treatment depends on the experience of the practitioner but more especially on the clinical follow-up and hygiene of the patient. Studies show satisfactory success rates with minimal bone loss consistent with those reported in patients without ADC sequelae [6].

Implant rehabilitations therefore seem to be the solution of choice for patients with ADC. However, the cost of this treatment represents a significant barrier to access to treatment. The social insurance system provides differing amounts of financial support depending on the country. However, patients with ADC most often have one to two missing teeth, often lateral incisors, which play an important role in the aesthetics and self-esteem of the patient. The main objective of this study is to establish the success rate of implant-supported prosthetic rehabilitations in patients with ADC sequelae monitored at the University Hospital of Lille through the evaluation of clinical and radiological parameters. The secondary objective is to establish the reason(s) for discontinuity of treatment and non-continuation of the proposed implant treatment for patients with ADC.

2. MATERIALS AND METHODS

2.1. Patients

This retrospective study included all patients with unilateral or bilateral ADC sequelae who underwent prosthetic implant-supported rehabilitation followed in the Department of Maxillofacial Surgery and Stomatology of Lille University Hospital between January 2009 and December 2018. Patients with ADC sequelae who received an implant-supported rehabilitation involving teeth not affected by the ADC, those who did not benefit from an implant rehabilitation, and patients without prosthetic follow-up after the implant placement were all excluded. Smokers were not excluded from this study. (Figure A)

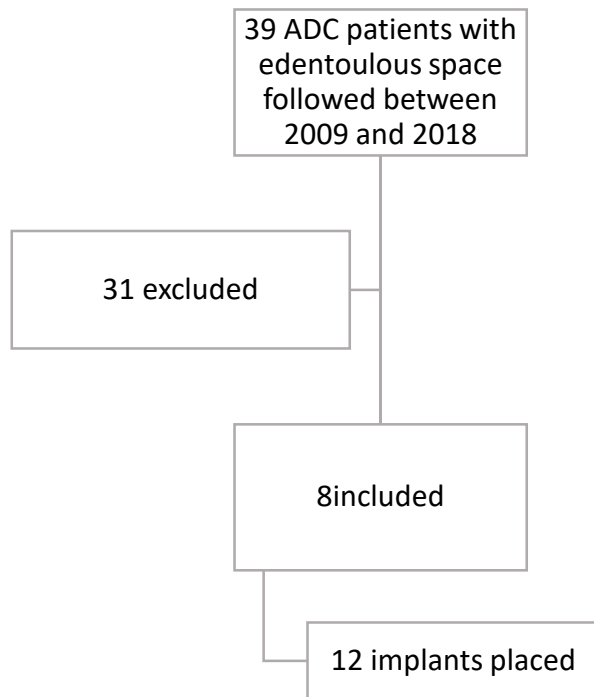


Figure A. Flow chart of included patients

All patients included were received in consultation between June and August 2019. An additional survey conducted via oral and written questionnaires, was carried out with excluded patients lost to follow-up after alveolar graft in order to know the reasons for this discontinuity of treatment.

2.2. Surgical protocol

All patients received a pre/peri-implant complementary alveolar bone graft. Prior 3D planning was done for each of them (Simplant® or DTX Studio Implant®) and resulted in the placement of Nobel® Active Conical Connection implants, Nobel® Replace Conical Connection and Zimmer® Tapered Screw Vent. The implants were placed according to the adapted instrumental sequence under local or general anesthesia.

2.3. Evaluation criteria

Implant survival was studied, as was the success of the implant, according to Buser criteria (absence of persistent subjective clinical signs: pain, foreign body sensation, dysesthesia, absence of chronic peri-implantitis associated with suppuration, absence of implant mobility, absence of a peri-implant radiolucent area). The pre-implant bone volume was measured using cone beam. Vertical compensation was measured on the pre-implant 3D mapping. Marginal bone loss (MBL) was measured using retro-alveolar X-rays performed with an angulator. Periodontal status was assessed clinically (observation and periodontal sounding) and radiologically to assess the Maynard and Wilson periodontal morphotype, Silness and Loë plaque index, keratinized gingival height, and presence of periodontal disease. The type of prosthetic rehabilitation and the static occlusion with 200 μ articulating paper were reported. Patient satisfaction with their implant-supported rehabilitation was assessed.

3. RESULTS

Eight patients were included, comprising four men and four women. The alveolar bone grafts were autogenic in three patients (cranial or endo-oral sampling) and alloplastic in five patients (MBCP Biomatlante®). These transplants were performed during the implant placement or up to twenty-two months before implant surgery.

Four patients underwent orthognathic maxillary surgery, three of which took place before implant surgery and one after.

A segmental osteotomy of the implanted area was performed in two patients to improve vertical compensation. These osteotomies were planned as early as the 3D implant planning phase.

Twelve implants were placed in patients with a mean age at the time of implant surgery of 20.25 years old, and a postoperative follow-up took place within a period ranging from 16 months to 92 months. The mean follow-up after functional loading of the implants was 26.9 months (Table A).

Patients	Sex	Age	Smoking	ADC type	Orthodontic treatment	Orthognathic surgery
Number 1	M	20	no	lateral left	yes	yes
Number 2	F	24	no	bilateral	yes	yes
Number 3	M	22	no	lateral left	yes	yes
Number 4	M	31	no	lateral left	yes	yes
Number 5	F	18	no	lateral left	yes	no
Number 6	F	26	no	bilateral	yes	no
Number 7	M	22	no	lateral left	yes	no
Number 8	F	30	no	lateral right	yes	no

Tableau A. Demographic distribution of patients and pre-implant management

The twelve implants placed had an average diameter of 3.5 mm (3 to 4.3 mm), and an average length of 10.8 mm (8 to 13 mm). Ten of these replaced a lateral incisor and two replaced the central incisor (Table B).

One implant, in the central incisor position (3.7 x 10mm) on a four-element bridge, was lost before osseointegration. This implant loss did not interfere with the functional loading of the other three implants in this patient. The implant survival rate was calculated at 91.7%.

The periodontal clinical and radiographic examination of the patients showed an average keratinized gingival height of 2.69 mm (0 mm to 7.5 mm). The periodontal morphotype was type I in three patients, type III in two patients and type IV in three patients. The plaque index at the implant site was 0 for three patients, 1 for three patients, 2 for one patient and 3 for another patient. The average peri-implant periodontal probing was between 0 and 2 mm in three patients, between 2 and 3 mm in two patients and between 3 and 4 mm in two further patients.

It was not possible to perform periodontal probing in the patient carrying a rehabilitation on four implants because of the prosthetic gingiva. Six patients had at least one sign of peri-implant mucositis, according to the new periodontal disease classification proposed by Heitz-Mayfield and Savi [7; 8] (visual signs of peri-implant gingival inflammation, bleeding on probing) (Table C).

No patients had additional periodontal soft tissue surgery.

None of the implants were clinically mobile, showed suppuration or coil exposure, or were the source of persistent subjective clinical signs. The implant success rate of implants in place was therefore calculated at 100%.

The average bone volume at the time of implant placement was 8.6 x 11.8mm (width x height). Measurements of MBL showed an average bone loss of 0.36 mm (0 to 1 mm). These bone losses did not affect implant integrity (Figure B).

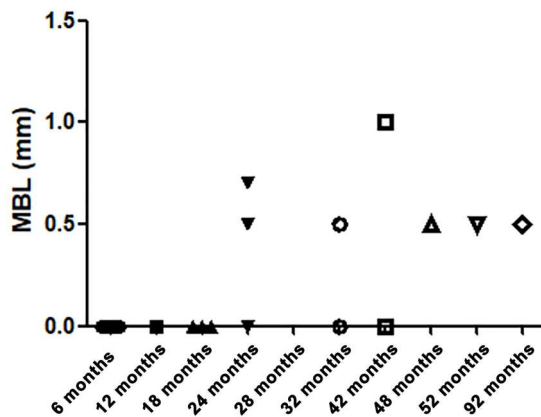


Figure B. Marginal bone loss (MBL) evolution

The sample of prosthetic rehabilitations supported on the implants comprised: seven unitary prostheses in the lateral incisor position, one implant-dental supported bridge fixed onto three elements and one implant-supported bridge comprising four elements. The four-element bridge replacing the maxillary incisal area was the only rehabilitation using false gingiva. Four unitary prostheses had a greater prosthetic height than the opposing tooth to effect vertical compensation. These vertical offsets averaged 3.38 mm (2 to 5 mm).

The occlusion after orthognathic surgery was reported as class III Angle in five patients and class II in three further patients. Five of these had an inter-incisor center shift averaging 1.6 mm. In all patients, occlusion of the implant-borne prosthesis presented attenuated or absent contacts with the antagonistic teeth. Posterior occlusal contacts were distributed in a balanced way.

In the end, seven patients reported that they were satisfied with their implant-borne prosthetic rehabilitation. One patient reported that she was not satisfied with her rehabilitation for aesthetic reasons due to the height of the prosthetic crown and the offset of the collar line. She will receive an epithelio-conjunctive graft in the coming months to improve the thickness and esthetic aspect of peri-implant soft tissues.

Regarding those patients who received a pre-implant alveolar graft but were not included in the study, four had implants but had not yet a prosthesis at the time of the study, two did not attend their follow-up appointments, one had their implant placement performed elsewhere, one had decided to stop all surgical management, one had total maxillary rehabilitation, and twenty-two (70.9%) had not been able to benefit from implantation due to a lack of financial means. These results were obtained from a supplementary survey conducted using oral and written questionnaire.

4. DISCUSSION

These results are in keeping with pre-existing studies concerning the reliability of graft site implant rehabilitation in patients with ADC sequelae [9; 6; 10; 11; 5].

They also confirm the results already established for the minimum implant length necessary (10 mm) [12; 13] and the lack of increased incidence of MBL [6] in patients with ADC sequelae.

However, a major difference should be observed in the present grafting protocol, because no difference in terms of osseointegration was observed in patients who received a complementary bone graft at the same time as implant placement, compared to those grafted remotely [11]. Nor was there any difference in the nature of the graft (autogenic or alloplastic).

The only reported implant failure concerned a rehabilitation with immediate esthetics loaded by screwed transitional crowns secured on four implants. Furthermore, this failure did not thwart the "definitive" rehabilitation of the remaining three implants and resulted in implant success.

In the present sample of patients, a downside is observed concerning soft tissues.

Periodontal surgery is not systematically considered in the protocol, even for patients who do not have satisfactory keratinized gingival height. This probably makes maintaining good oral hygiene more complicated in these patients. However, these findings must be balanced because MBL, periodontal disease and implant survival rates do not seem to have been affected as expected in the case of implants placed in an imperfect periodontal environment [14; 8]. These results can be explained by the low plaque indices found (greater than or equal to 2 in two patients) and the absence of smoking patients in the present sample.

Prosthetic restorations without occlusal loading or with diminished intensity of the occlusal contact points associated with a balanced posterior occlusion seem to be a preferred option for implant rehabilitation among these patients. However, only an in-depth study of the occlusion, including its dynamic components as well as the monitoring of any associated parafunctions, could have confirmed this with certainty [15; 16].

Maintaining the transverse direction was one of the difficulties of these prosthetic rehabilitations due to the high rate of occlusal asymmetry and the strong tendency of corrections to revert. Occlusal adaptations were required for one patient in this regard: in one case, a central incisor bis was necessary (Figure C).

Occlusal instability is an element to consider in the treatment plan for labio-maxillofacial clefts. Indeed, often anterior surgeries, which are sometimes numerous and repeated, cause significant retractions of the palatal tissues. In these cases, occlusal stability cannot be obtained without definitive restraint. In these cases, the implant-supported rehabilitation, if elected, must integrate this occlusal difficulty.

The presence of scars and mucosal bridles, as well as variable anatomical bone volumes, are among the anatomical difficulties of ADC sequelae which must be considered in order to anticipate potential technical difficulties. These difficulties may lead to a contra-indication of implant rehabilitation due to insufficient bone volume resulting from failed bone graft, or to new surgery being deemed impossible due to lack of vascularization of the site.

An essential feature of implant management of patients with ADC sequelae is openness to compromise, whether on technical (segmental osteotomy, vertical compensation) or aesthetic aspects (false gingiva, prosthesis shape, asymmetry of the dental formula).

On the other hand, the peculiarities inherent to the treatment pathways of these patients, such as repeated surgeries and treatment over a period of several years, certainly explain the lack of motivation shown by some to commit to an implant treatment plan. Added to this is the cost of these implant rehabilitations which are, for these patients, the only surgery options without systematic treatment. In this study, twenty-two patients (70.9% of ADC patients followed during the study period) were unable to access implant treatment because of the lack of social cover for this type of rehabilitation.

Implant rehabilitation of labio-maxillofacial clefts is a reliable therapeutic option, providing the best possible results for the management of these malformations. It is a technique which enables the preservation of dental organs and provides the most anatomical restoration of the occlusion.

However, this rehabilitation is not always possible, given a large number of constraints inherent to the management of ADC. Indeed, social reasons sometimes make it difficult to enforce the oral hygiene required for successful implant rehabilitation [17].

Occlusal stability is an element which must be integrated. In this context, primary surgery of the alveolar breach should consider the purpose of dental rehabilitation which cannot be obscured. The periodontal situation must be integrated even if the present sample does not seem to be impacted by the results of these rehabilitations. It is highly likely that very good hygiene can compensate for the absence of attached gingiva. Social cover is clearly a limiting factor in the choice of these supports. In this sample, it is a cause of lack of treatment for many patients. The need for better management of these patients, who have a disease described as rare in addition to being associated with dental agenesis, is evident.

The overall objective of this study was therefore also to gain an insight into how to better manage these patients until a complete implant rehabilitation is undertaken. The high satisfaction rate among the patients of this study reinforces the need to further develop this avenue of research.

ACKNOWLEDGMENTS AND CONTRIBUTION OF THE AUTHORS

The authors would like to thank Professor G Raoul, and Drs. O Garda, L Longueval, H Rakotomalala and D Nazat for their treatment of the patients included in this study and their sharing of clinical data.

REFERENCES

- [1]. Panamonta V, Msn SP, Panamonta M, Chowchuen B. Global birth prevalence of orofacial clefts: a systematic review. *Journal of medical association of Thailand*. 2015;98:11.
- [2]. Veiga KA, Porto AN, Matos FZ, Brand PC. Caries experience and periodontal status in children and adolescents with cleft lip and palate. *Pediatric dentistry*. 2017;39(2):6.
- [3]. Mangione F, Nguyen L, Foumou N, Bocquet E, Dursun E. Cleft palate with/without cleft lip in French children: radiographic evaluation of prevalence, location and coexistence of dental anomalies inside and outside cleft region. *Clinical Oral Investigations*. 2018 Mar;22(2):689–95.
- [4]. Wang F, Wu Y, Zou D, Wang G, Kaigler D. Clinical outcomes of dental implant therapy in alveolar cleft patients: a systematic review. *The International Journal of Oral & Maxillofacial Implants*. 2014 Sep 19;29(5):1098–105.
- [5]. Takashi T, Kochi S. Use of endosseous implants for dental reconstruction of patients with grafted alveolar cleft.pdf. *Journal of oral and maxillofacial surgery*. 1997;(55):576–83
- [6]. Takahashi T, Inai T, Kochi S, Fukuda M, Yamaguchi T, Matsui K, et al. Long-term follow-up of dental implants placed in a grafted alveolar cleft: evaluation of alveolar bone height. *Oral Surgery, Oral Medicine, Oral Pathology, Oral Radiology, and Endodontology*. 2008 Mar;105(3):297–302.
- [7]. Caton JG, Armitage G, Berglundh T, Chapple ILC, Jepsen S, Kornman KS, et al. A new classification scheme for periodontal and peri-implant diseases and conditions - Introduction and key changes from the 1999 classification. *Journal of Clinical Periodontology*. 2018 Jun; 45:S1–8.
- [8]. Heitz-Mayfield LJA, Salvi GE. Peri-implant mucositis. *Journal of Clinical Periodontology*. 2018 Jun;45:S237–45.
- [9]. Wermker K, Jung S, Joos U, Kleinheinz J. Dental implants in cleft lip, alveolus, and palate patients: a systematic review. *The International Journal of Oral & Maxillofacial Implants*. 2014;29(2):384–90.
- [10]. Matsui Y, Ohno K, Nishimura A, Shirota T, Kim S, Miyashita H. Long-term study of dental implants placed into alveolar cleft sites. *The Cleft Palate-Craniofacial Journal*. 2007 Jul;44(4):444–7.
- [11]. Jensen J, Sindet-Pedersen S, Enema H. Reconstruction of residual alveolar cleft defects with one-stage mandibular bone grafts and osseointegrated implants. *Journal of Oral and Maxillofacial Surgery*. 1998;56:460-466.
- [12]. Borgnat F, Martin P, Paulus C. Réhabilitation implanta-portée des patients porteurs de fentes labio-alvéolo-palatines : étude rétrospective sur 43 patients. *Revue de Stomatologie, de Chirurgie Maxillo-faciale et de Chirurgie Orale*. 2015 Sep;116(4):229–34.

[13]. Kearns G PD. Placement of endosseous implants in grafted alveolar cleft. *Cleft palate-craniofacial journal*. 1997 Nov;34(6).

[14]. Wyrębek B, Cudziło D, Plakwicz P. Evaluation of periodontal tissues in growing patients with bilateral cleft lip and palate: a pilot study. *Developmental period medicine*. 2017;XXI,2.

[15]. Delgado-Ruiz RA, Calvo-Guirado JL, Romanos GE. Effects of occlusal forces on the peri-implant-bone interface stability. Romanos GE, editor. *Periodontology 2000*. 2019 Oct;81(1):179–93.

[16]. Sheridan RA, Decker AM, Plonka AB, Wang H-L. The role of occlusion in implant therapy: a comprehensive updated review. *Implant Dentistry*. 2016 Dec;25(6):829–38.

[17]. Plakwicz P, Wyrębek B, Górski R, Cudziło D. Periodontal indices and status in 34 growing patients with unilateral cleft lip and palate: a split-mouth study. *The International Journal of Periodontics & Restorative Dentistry*. 2017 Nov;37(6):e344–53.

Table B. Implants and prostheses specifications

Patients	Alveolar bone graft	Implant type	Implant diameter	Implant length	Vertical compensation	Replaced teeth	Prosthesis type	Occlusion	Follow-up
Number 1	autogenic	Nobel Replace	3,5mm	10mm	4mm	22	unitary	III R, II L, I-i=1mm	52 months
Number 2	MBCP	Zimmer TSV	3,7mm x4	10mm x3 8mm x1	4mm	11-12-21-22	bridge of 4 elements	II, posterior butt R	32 months
Number 3	MBCP	Nobel Replace	3,5mm	11,5mm	3mm	22	unitary	III, posterior butt, I-i=3mm	18 months
Number 4	autogenic	Nobel Replace	4,3mm	10mm	5mm	22	unitary	III R, II L, I-i=2mm	42 months
Number 5	MBCP	Nobel Active	3,5mm	13mm	4mm	22	unitary	II	18 months
Number 6	MBCP + Bio Oss	Nobel Active	3mm x2	13mm x2	3mm	12-22	unitary	III	28 months
Number 7	MBCP	Nobel Active	3mm	11,5mm	2mm	22	unitary	II, I-i=1mm	84 months
Number 8	autogenic	Nobel Replace	3,5mm	10mm	2mm	12-11bis	Implant-dental supported bridge	III, I-i=1mm	92 months

*R = right, L = left, I-I = inter-incisor center shift

Table C. Periodontal characteristics

*NA= not applicable

Patients	Periodontal morphotype	Plaque index	Keratinized gingival height	Disease	Periodontal probing						
					Bleeding	VM	VC	VD	PM	PC	PD
Number 1	I	1	4mm	mucosite	no	3mm	2mm	5mm	4mm	2mm	3mm
Number 2	IV	2	0mm	mucosite	yes	NA	NA	NA	NA	NA	NA
Number 3	IV	3	0mm	mucosite	yes	1mm	0mm	1mm	1mm	0mm	1mm
Number 4	I	1	7,5mm	mucosite	yes	4mm	1mm	3mm	1mm	5mm	2mm
Number 5	IV	0	0mm	mucosite	no	1mm	0mm	1mm	4mm	3mm	3mm
Number 6	III	0	3,5 mm	none	no	1mm	3mm	1mm	0mm	4mm	3mm
Number 7	I	1	3,5 mm	mucosite	yes	5mm	2mm	3mm	4mm	3mm	2mm
Number 8	III	0	3mm	none	no	3mm	1mm	2mm	3mm	2mm	2mm

Figure C. Illustrations of patient number 8

A: intraoral front view, B: maxillary occlusal view, C: panoramic radiograph at the implant placement day, D: periapical radiograph at 92 months follow-up

