



HAL
open science

CASPR2 antibody encephalitis presenting as transient epileptic amnesia

Benjamin Cretin, Mathias Bilger, Nathalie Philippi, Frederic Blanc

► **To cite this version:**

Benjamin Cretin, Mathias Bilger, Nathalie Philippi, Frederic Blanc. CASPR2 antibody encephalitis presenting as transient epileptic amnesia. *Seizure - European Journal of Epilepsy*, 2020, 81, pp.175 - 177. 10.1016/j.seizure.2020.08.010 . hal-03492340

HAL Id: hal-03492340

<https://hal.science/hal-03492340>

Submitted on 22 Aug 2022

HAL is a multi-disciplinary open access archive for the deposit and dissemination of scientific research documents, whether they are published or not. The documents may come from teaching and research institutions in France or abroad, or from public or private research centers.

L'archive ouverte pluridisciplinaire **HAL**, est destinée au dépôt et à la diffusion de documents scientifiques de niveau recherche, publiés ou non, émanant des établissements d'enseignement et de recherche français ou étrangers, des laboratoires publics ou privés.



Distributed under a Creative Commons Attribution - NonCommercial 4.0 International License

Title: CASPR2 antibody encephalitis presenting as transient epileptic amnesia

Authors: Benjamin CRETIN^{a,b}, Mathias BILGER^a, Nathalie PHILIPPI^{a,b}, Frederic BLANC,^{b,c}

Affiliations:

^a University Hospital of Strasbourg, CM2R (Memory Resource and Research Centre), Clinical Neuropsychology Unit, Neurology Department, Strasbourg, France

^b University of Strasbourg, CNRS, ICube laboratory, UMR 7357 and FMTS (Fédération de Médecine Translationnelle de Strasbourg), team IMIS, Strasbourg, France

^c University Hospital of Strasbourg, CM2R (Memory Resource and Research Centre), Day Hospital, Geriatrics Department, Strasbourg, France

Corresponding author:

Benjamin Cretin, CMRR d'Alsace, Service de Neurologie des Hôpitaux Universitaires de Strasbourg, Pôle Tête et Cou, 1 Avenue Molière 67200 Strasbourg, France.

Phone number: +33 3 88 12 86 32

Fax number: +33 3 88 12 86 36

Email: benjamin.cretin@chru-strasbourg.fr

Word count: Body of text: 1073

Table(s): 0

Figure(s): 1

References: 4

1 Highlights

- 2 • Isolated **transient amnesia** can be of epileptic origin
- 3 • The epileptic origin may be suggested by a short duration of the episodes (< 1h)
- 4 • Interictal cognitive complaints are highly suggestive of the diagnosis
- 5 • Both interictal and ictal features can be of autoimmune origin (here, anti-CASPR2)

6

7 Title: **CASPR2 antibody encephalitis presenting as transient epileptic amnesia**

8

9 **Keywords:** transient epileptic amnesia, autoimmune encephalitis, anti-CASPR2, case report

10 Case report

11 **Transient epileptic amnesia** (TEA) is an underrecognized form of late-onset temporal lobe
12 epilepsy, generally occurring between the ages of 50 and 70, and manifesting as ictal episodes of
13 transient amnesia, either retro- and/or anterograde, of variable duration. The episodes are mostly
14 short (≤ 1 h), but can last for hours and thereby mimic benign transient global amnesia (TGA) [1]. In
15 addition to episodic amnesia, the diagnosis of TEA may be suggested by complaints of interictal
16 cognitive problems. These typically involve memory and consist in autobiographical deficits,
17 accelerated forgetting, and, to a lesser extent, topographical amnesia. This symptom profile indicates
18 hippocampal dysfunction, which can be of autoimmune origin [1,2]. Here, we present the case of a
19 patient in whom the first and only amnestic attack was appropriately diagnosed because of the
20 nature of his subjective cognitive impairment. The diagnosis of TEA, in turn, led to the secondary
21 identification of CASPR2 antineuronal antibodies, most likely involved in the aetiology of the clinical
22 picture.

23 The patient was 60 years old when an episode of TEA occurred **after he had been awake for**
24 **several hours**. He was an ex-smoker (stopped 4 months prior to presentation) with a history of mild
25 traumatic brain injury at the age of 22, dyslipidemia and hypertension. The patient gave a good
26 description of the first 5 min of the TEA because he recollected that he was unable to remember
27 anything at that time: He did not recognize a cheque he had signed 30 min earlier (**in the early**

28 **afternoon**) and experienced a strange feeling of “jamais vu” without any dysautonomic aura or
29 indicators of a confusional state. The retrograde amnesia was followed by anterograde amnesia for
30 3.5 h described by his wife, with repetitive questioning but no other accompanying signs **or**
31 **automatisms**. The patient reported that for the past 4 years he had been suffering from a blunted
32 sense of smell and fluctuating mood, in combination with “panic attacks” (weekly to monthly
33 unexplained and unpredictable spells **lasting 30 s to 2–3 min** with upper limb piloerection and
34 sudden tachycardia, sometimes followed by fear and subsequent loss of contact with speech arrest
35 for a few seconds). Besides, two similar episodes occurred in the 5 days after the transient amnesic
36 attack. Moreover, the patient had been complaining about his memory for the past 2 years: He gave
37 a clear account of accelerated forgetting from one week to the next (**e.g., he was unable to**
38 **remember details of a party at a friend’s house 10 days before attending our clinic**), and patchy
39 autobiographical amnesia over the past 4–5 years (**e.g., he could not remember clearly what he had**
40 **done with his colleague on the day of his retirement 18 months before presentation, nor did he**
41 **remember his wedding that took place 6 months before the TEA**). He also reported occasional word-
42 finding difficulties and attentional lapses. **Since the patient’s history and clinical presentation met the**
43 **recommended diagnostic criteria for TEA**, we immediately suspected TEA: The patient’s Mini-Mental
44 State Examination (MMSE) score was 29/30 at baseline and routine neuropsychological assessment
45 showed a dysexecutive profile with impaired attention (i.e. faulty retrieval in verbal memory task,
46 failed the Trail-Making Test [TMT]-B and short-term memory tasks). **Accelerated forgetting or**
47 **autobiographical amnesia were not specifically tested**. A standard electroencephalogram (EEG; 40-
48 min awake session) was normal. Since a computed tomography (CT) scan of the brain performed in
49 the emergency room was normal, we carried out magnetic resonance imaging (MRI) of the brain: It
50 revealed scattered cortical and juxta-cortical hyperintensities, as well as increased T2 signal in both
51 hippocampi but more marked on the right (figure 1). We therefore carried out an autoimmune work-
52 up: Antinuclear and antiphospholipid antibody levels were normal, anti-thyroid antibody levels were
53 slightly increased (anti-TPO = 64 UI/ml, antithyroglobulin = 357 UI/ml, N < 34 UI/ml and 115 UI/ml,

54 respectively), and antineuronal antibody samples were positive (immunofluorescent-positive
55 neuropil staining on monkey cerebellum slices). On cell-based assays, serum anti-CASPR2 antibody
56 samples were positive (the test employed provided no titer of the anti-CASPR2 or of the anti-VGKC-
57 complex antibodies). Whole-body CT scan did not reveal any malignancy. Treatment with lamotrigine
58 at 2 mg/kg/day (150 mg once daily) was progressively initiated, which led to the immediate cessation
59 of dysautonomic spells and prevented recurrence of amnesia for the following 12 months. The
60 patient refused **sleep-EEG**, lumbar puncture, and intravenous immunoglobulin treatment because he
61 felt better (improved sense of smell, better mood, and fewer memory complaints). **Repeat MRI after**
62 **6 months of treatment with lamotrigine showed no significant change from the initial scan.**

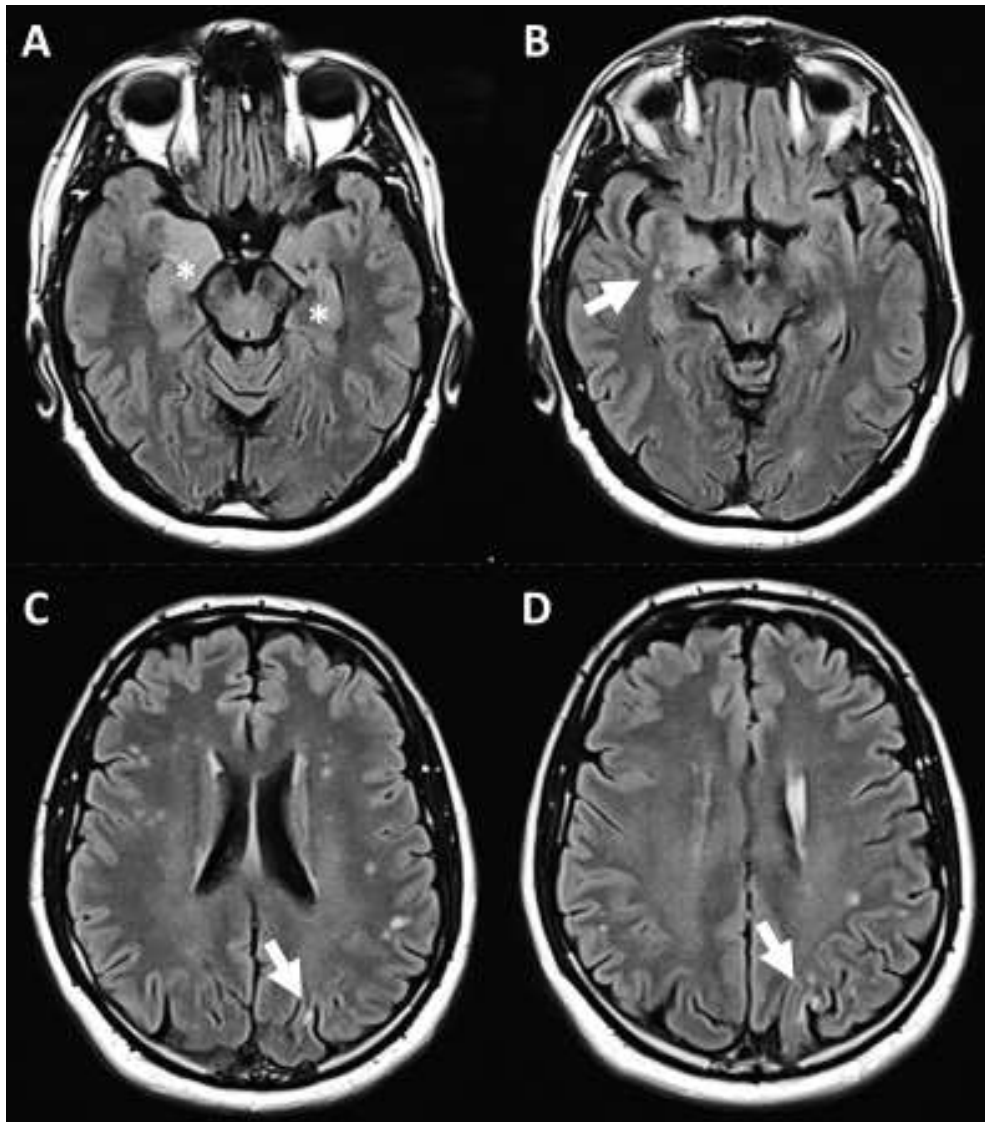
63 This case is the second, to our knowledge, to report TEA in association with a well-identified
64 antineuronal antibody. The first patient described had anti-NMDA antibodies: He was younger at
65 disease onset (44 years) than our patient, whose age was more typical of TEA. Not only the age but
66 also the other characteristics of our patient encompass the syndromic features of non-paraneoplastic
67 limbic encephalitis with CSF-positive anti-CASPR2: median age = 64.5 years, focal seizures with
68 typically normal EEG (in more than 75% of cases), episodic memory impairment, increased T2
69 hippocampal signal on brain MRI, and positive serum CASPR2 antibodies [3]. However, because our
70 patient refused CSF analysis, we could not definitively categorize his condition as this type of
71 autoimmune encephalitis. Nevertheless our report suggests that, in some cases, TEA may be due to a
72 subtle form of autoimmune encephalitis and that TEA should be considered part of the clinical
73 spectrum autoimmune encephalitides may present with [1,2]. In combination with the rare
74 degenerative forms reported, our case therefore highlights the etiological heterogeneity of TEA.
75 Moreover, we wish to stress the fact that the diagnosis of TEA was strongly suspected, and thereafter
76 quickly made, in this patient because he complained of chronic memory disturbances: these
77 complaints were suggestive of the diagnosis, as were the other episodes with dysautonomic signs,
78 despite the isolated antero-retrograde amnesic attack.

79 In conclusion, substantial progress has been made in the understanding of TEA. The
80 refinement of the ictal and interictal characteristics of TEA since the 1990s, now allows for an
81 accurate and quick recognition of the syndrome: not only in light of repetitive and stereotyped
82 transient amnesic episodes, but also in view of the peculiar and highly suggestive other memory
83 complaints [4]. As illustrated by our case, this scenario has therapeutic implications: First, antiseizure
84 medications can be prescribed; second, an early and correct aetiological diagnosis can be made with
85 subsequent appropriate follow-up and management (which should now include autoimmune
86 conditions).

87 References:

- 88 1. Mosbah A, Tramoni E, Guedj E, Aubert S, Daquin G, Ceccaldi M, Félician O, Bartolomei F. Clinical,
89 neuropsychological, and metabolic characteristics of transient epileptic amnesia syndrome.
90 *Epilepsia*. 2014 May;55(5):699-706.
- 91 2. Savage SA, Irani SR, Leite MI, Zeman AZ. NMDA receptor antibody encephalitis presenting as
92 Transient Epileptic Amnesia. *J Neuroimmunol*. 2019 Feb 15;327:41-43.
- 93 3. Joubert B, Saint-Martin M, Noraz N, Picard G, Rogemond V, Ducray F, Desestret V, Psimaras D,
94 Delattre JY, Antoine JC, Honnorat J. Characterization of a Subtype of Autoimmune Encephalitis
95 With Anti-Contactin-Associated Protein-like 2 Antibodies in the Cerebrospinal Fluid, Prominent
96 Limbic Symptoms, and Seizures. *JAMA Neurol*. 2016 Sep 1;73(9):1115-24.
- 97 4. Butler CR, Graham KS, Hodges JR, Kapur N, Wardlaw JM, Zeman AZ. The syndrome of transient
98 epileptic amnesia. *Ann Neurol*. 2007 Jun;61(6):587-98.

99



101

102 Note: A = bi-hippocampal hypersignal (stars) predominating on the right side; B = unusual white
103 matter hyperintensities close to the right hippocampus (thick arrow); C–D = scattered juxta-cortical
104 round-shaped white matter hyperintensities with cortical hypersignal (thick arrows)