



HAL
open science

Carbon dioxide laser treatment for vulvovaginal atrophy in women treated for breast cancer: Preliminary results of the feasibility EPIONE trial

B. Hersant, G. Werkoff, D. Sawan, M. Sidahmed-Mezi, R. Bosc, S. La Padula, S. Kalsoum, N. Ouidir, J.-P. Meningaud, Y. Belkacemi

► To cite this version:

B. Hersant, G. Werkoff, D. Sawan, M. Sidahmed-Mezi, R. Bosc, et al.. Carbon dioxide laser treatment for vulvovaginal atrophy in women treated for breast cancer: Preliminary results of the feasibility EPIONE trial. *Annales de Chirurgie Plastique Esthétique*, 2020, 65, pp.e23 - e31. 10.1016/j.anplas.2020.05.002 . hal-03492165

HAL Id: hal-03492165

<https://hal.science/hal-03492165>

Submitted on 22 Aug 2022

HAL is a multi-disciplinary open access archive for the deposit and dissemination of scientific research documents, whether they are published or not. The documents may come from teaching and research institutions in France or abroad, or from public or private research centers.

L'archive ouverte pluridisciplinaire **HAL**, est destinée au dépôt et à la diffusion de documents scientifiques de niveau recherche, publiés ou non, émanant des établissements d'enseignement et de recherche français ou étrangers, des laboratoires publics ou privés.



Distributed under a Creative Commons Attribution - NonCommercial 4.0 International License

Carbon Dioxide Laser Treatment for Vulvovaginal Atrophy in Women Treated for Breast Cancer: Preliminary Results of the Feasibility EPIONE Trial

Barbara Hersant MD, PhD ^{1,3,6}, Gabrielle Werkoff MD ^{1,2}, Dana Sawan MD ³, Mounia Sidahmed-Mezi PhD ³, Romain Bosc MD, PhD ^{1,3,6}, Simone La Padula MD ³, Sarah Kalsoum MD ⁷, Nabila Ouidir MD ⁷, Jean-Paul Meningaud MD, PhD ^{1,3,6}, Yazid Belkacemi MD, PhD ^{1,4,5,6}

¹ Henri Mondor Breast Center, Hôpitaux Universitaires Henri Mondor, 51 Avenue Marechal de Lattre de Tassigny, 94010 Créteil, France

² Gynecological Surgery Department, Bégin Army Teaching Hospital, 69 Avenue de Paris, 94160 Saint Mandé, France

³ Department of Maxillofacial Surgery, Plastic and Reconstructive, Hôpitaux Universitaires Henri Mondor, 51 Avenue Marechal de Lattre de Tassigny, 94010 Créteil, France

⁴ Department of Radiation Oncology, Hôpitaux Universitaires Henri Mondor, 51 Avenue Marechal de Lattre de Tassigny, 94010 Créteil, France

⁵ INSERM Unit 955, Team 21. IMRB. Creteil.

⁶ University of Paris East Creteil (UPEC).

⁷ Department of Pathology, Hôpitaux Universitaires Henri Mondor, 51 Avenue Marechal de Lattre de Tassigny, 94010 Créteil, France

Carbon Dioxide Laser Treatment for Vulvovaginal Atrophy

in Women Treated for Breast Cancer: Preliminary Results of the Feasibility EPIONE Trial

Abstract

Background and Objective: Quality of life preservation after anti-cancer therapy is a major challenge for breast cancer survivors. Approximately 42–70% of patients who receive systemic therapy for breast cancer, including endocrine therapy, will develop vulvovaginal atrophy (VVA). For these patients, the commonly proposed gel-based treatments for topical applications are restrictive. Recently, innovative, non-hormonal therapeutic approaches, such as laser therapy, have emerged. The purpose of this feasibility study is to investigate the safety and efficacy of CO₂-laser therapy in women with a history of breast cancer.

Material and Methods: This prospective monocentric study included 20 patients with vulvovaginal atrophy who were treated at Henri Mondor University Hospital between 2017 and 2018. We included patients with a vaginal health index (VHI) score < 15 and a contraindication for hormone administration due to a history of breast cancer. Two carbon dioxide laser sessions were used. The treatment was delivered using the following settings: vaginal tightening, FinePulse (pulse width 0.9 ms), and energy density of 11.5 J/cm² that allows coverage of 70% of the targeted vaginal area to be treated. All patients had their follow-up visit at one (M1), three (M3), and six (M6) months after the first treatment to evaluate efficacy of the treatment on vulvovaginal atrophy. Vaginal health index score and female sexual distress (FSD) score were used to assess treatment efficacy and its impact on sexual quality of life. A score ≥ 11 was

associated with sexual dysfunction. The vaginal health index and female sexual distress scores were evaluated at baseline, M1, M3, and M6 of follow-up.

Results: The mean age of the patients was 56.1 ± 8.8 years (range, 27–69 years). Seventeen of the 20 patients had experienced menopause (mean menopausal age, 51.25 ± 1.5 years). At inclusion, the mean vaginal health index and the female sexual distress scores were 10.58 ± 1.71 and 21.36 ± 15.10 , respectively. Fourteen out of 20 patients (70%) had FSD scores ≥ 11 at the baseline. At M1, the mean vaginal health index score increased significantly to 13.42 ± 2.3 ($p = 0.03$), which represented an improvement of 21% from the baseline. A persistent and significant improvement in the vaginal health index score was observed at M6, with the score increasing to 16.75 ± 4.23 post-treatment ($p < 0.0001$), representing a 34% improvement from the mean baseline score. The mean female sexual distress at M1 was 19.83 ± 13.57 , representing a 7% decrease compared to the baseline scores ($p < 0.01$). At M3, the female sexual distress significantly decreased to 13.88 ± 15.58 , representing an improvement of 35% ($p = 0.006$). It increased to 10.35 ± 14.7 at M6, representing an improvement of 52% ($p = 0.001$). At M3, 35% of the patients had a female sexual distress score > 11 , and at M6, only 15% had a female sexual distress score > 11 . No side effects were reported during follow-up.

Conclusion: This pilot feasibility study showed that carbon dioxide laser treatment appears to be an effective and safe method to improve the trophicity and decrease vaginal mucosal dryness in women with vulvovaginal atrophy that developed after systemic breast cancer therapy.

Key words: Vulvovaginal atrophy, VVA, CO2 laser, breast cancer.

INTRODUCTION

Quality of life is a major component of the benefit-risk ratio evaluation and outcome for patients treated for breast cancer. Given the excellent long-term survival rate of patients with breast cancer, it is of paramount importance to consider the late effects of systemic therapy and offer these patients all solutions that may improve their quality of life after treatment.

Approximately 42-70% of patients with a history of breast cancer develop menopausal genitourinary syndrome (MGS) (1). This syndrome is associated with not only sexual symptoms, including vaginal dryness and dyspareunia, but also non-sexual symptoms, such as pruritus, discomfort, bleeding, unusual leucorrhea, sexual dysfunction, urinary incontinence, and urinary tract infections (2). Although menopausal genitourinary syndrome is usually caused by a decline in estrogen at menopause, it can also occur after systemic therapy for cancer (such as chemotherapy or endocrine therapy) (3).

The standard treatment for menopausal genitourinary syndrome consists of systemic or local administration of estrogens. However, the management of menopausal genitourinary syndrome in women with a history of breast cancer is a dilemma because estrogen-based hormonal treatments (including local hormonal treatments, which can pass into the bloodstream) may increase the risk of local or distant breast cancer recurrences. Thus, such hormonal treatments are contraindicated in all patients with a history of breast cancer (4). For example, for local therapy of vulvovaginal atrophy (VVA), breast cancer patients are commonly offered non-hormonal gels, most often based on hyaluronic acid (HA). However, to optimize the therapy, HA protocols require at least two to three applications per week, which can compromise their long-term use and provide only minimal benefit (5).

In the recent years, innovative non-hormonal therapeutic approaches have emerged. These include physical (laser, radiofrequency), chemical (HA injection), and biological tissue inducers based on regenerative medicine such as autologous platelet concentrates (6). More recently, light- and energy-based devices, including different types of lasers (carbon dioxide [CO₂], erbium YAG laser) and radio frequency, have also been proposed for the management of MGS, (7). They have demonstrated significant effectiveness (8).

In a recent systematic review that evaluated the use of laser treatments for MGS in patients without a history of breast cancer, Pitsouni et al. (8) reported that CO₂ laser therapy resulted in an improvement of all the symptoms of MGS assessed either objectively or subjectively in 10 out of 14 studies. However, there is a dearth of studies specifically conducted on patients with a history of breast cancer (9-12).

The aim of this pilot study, which is part of the EPIONE randomized controlled trial (Prospective evaluation of innovative therapeutic approaches of vaginal and sexual dysfunction after breast cancer treatment: A randomized multicenter controlled trial), is to evaluate the safety and efficacy of CO₂ laser therapy on vulvovaginal atrophy in women treated for breast cancer. EPIONE study is designed with three arms: patients treated with CO₂ laser therapy (arm 1) vs HA injections (arm 2) vs topical application of HA-based gel (arm 3, control arm) (project code number, P01-18; registration number, 2018-A01678-47).

MATERIALS AND METHODS

Patients

Patients were recruited from the Henri Mondor University Hospital between 2017 and 2018. A total of 20 patients with breast cancer who had a vaginal health index (VHI) score (13) < 15 were included after signing an informed consent form. The study was approved by the local institutional review board of the Henri Mondor Breast Center. Vaginal health index score consists of five parameters: elasticity, fluid volume, pH, epithelial integrity, and moisture. Each parameter is ranked from 1 (worst) to 4 (best). Inclusion criteria were completion or currently completing endocrine therapy for breast cancer, age between 18 and 70 years, vaginal dryness defined by a vaginal health index score < 15. The exclusion criteria included patients without breast cancer, age less than 18 years or more than 70 years, pregnancy, breastfeeding, vulvovaginal infection (bacterial, viral, or fungal), a history of recurrent vaginal herpes (more than six episodes per year), and a history of papilloma virus infection.

Gynecological examination

Before inclusion in the study, all patient underwent a gynecological examination to confirm the absence of vaginal tissue alteration due to infection and suspicious lesions of the vulvovaginal area. A vaginal swab was obtained based on the findings of the clinical examination.

CO₂ laser treatment

INTERmedic's GyneLase™ CO₂ laser technology was used in all patients. The treatment was delivered using the following settings: vaginal tightening, FinePulse (pulse width 0.9 ms), and an energy density or fluence (fluence is the amount of energy emitted from an area of 1 cm². It is expressed in Joules/cm²) of 11.5 J/cm². This fluence allowed coverage of 70% of the targeted

vaginal area to be treated. Gynelase is a CO₂ fractional laser causes a controlled and highly precise photothermal effect into the vaginal mucosa, The healthy tissue surface preserved between laser impacts guarantees rapid re-epithelialization allowing coverage of 70% of the targeted vaginal area to be treated. (14)

Pulse stacking was applied with three pulses per area at the beginning of the procedure.

The Gynelase CO₂-laser combines photothermal power with soft treatment, delivering the fractional laser energy needed in a sensitive mucosa such as the vaginal wall. The uniform and orderly delivery of the number of pulses per spots allows for deleterious heat accumulation prevention. Healthy tissue is spared between treatment delivery to promote rapid epithelialization through precise control of depth, percentage of surface area treated, and amount of energy delivered.

Treatment application

A vaginal speculum examination was performed before treatment to confirm that patients met the inclusion criteria and to ensure the vaginal mucosa was kept dry.

To reduce the pain associated with laser treatment, xylocaine gel (Xylocaine® gel, Aspen Pharma Trading Ltd.) was applied one hour before the first session.

During treatment, the handset of the Gynelase device was inserted to a depth of 8–9 cm into the vaginal canal. The device was slowly rotated, and a laser shot was delivered every 30 degrees, which corresponds to 12 shots per rotation (360 degrees). Once a complete rotation was made, the probe was withdrawn by 0.5 cm, and a shot was again delivered every 30 degrees. The

procedure was repeated until the handset was 3 cm deep in the vaginal canal (Figure 1).

Treatment was performed in two consecutive sessions at one-month intervals (M0 and M1).

In the case of pain during the first laser impact, stacked pulses of lower fluence were used (decreased to two pulses or one).

Clinical evaluation of vaginal dryness and patient follow-up

Primary endpoint

The primary endpoint of the study was the effectiveness of CO₂ laser treatment, which was assessed using Gloria Bachmann's vaginal health index score(13) It is a tool with five items rating between 0 and 4 used to assess vaginal elasticity, volume of secretions, epithelial integrity, and hydration which is measured by visual inspection and palpation of the vaginal mucosa. For the vaginal pH, it was measured using cotton swabs (EcoCare™ Comfort, Merete Medical GmbH, 12247 Berlin-Germany). (Table 1)

The Vaginal health index score was assessed by a senior specialist different from the one who administered treatment and was done during a vaginal examination with a speculum. This assessor (senior specialist) is the same for all patients. The procedure was considered successful if the vaginal health index score was > 15 after treatment.

Secondary endpoints

The secondary endpoint of the study was the patient's quality of sexual life, which was assessed using a sexual distress scale - female sexual dysfunction (FSD) (15) - which allowed the assessment of sexual desire, orgasm, and arousal after treatment. Women with an female sexual dysfunction score ≥ 11 were considered to have sexual dysfunction (15).

Treatment tolerance was assessed by documenting adverse events and pain during treatment using the visual analog scale (VAS), with scores ranging from 0 to 10. Patient satisfaction with treatment was evaluated at M6 using a VAS.

Patient follow-up

After two treatment sessions, patients were evaluated at one month (M1), three months (M3), and six months (M6) to assess the effects of treatment on vulvovaginal atrophy.

Statistical analysis

A descriptive analysis was used for demographic data. The variables are presented as mean \pm standard deviation. An analysis of variance was used to compare the variables at different timepoints. A student's t-test was used to compare means. P-values < 0.05 were considered statistically significant. Graph Pad version 5 and JMP 10 software (SAS Institute Inc.) were used to perform statistical analyses.

RESULTS

A total of 20 patients with a history of breast cancer were included in this study. None of the patients was lost to follow-up. The median follow-up since the diagnosis of breast cancer therapy was five years (range, 1–15 years).

Patient characteristics

Nine patients (45%) had invasive ductal carcinoma, and one (5%) had lobular carcinoma. Most patients received chemotherapy (n = 12) and radiotherapy (n = 14) to the breast and/or lymph nodes. Endocrine therapy was administered in nine patients (45%). Of these patients, two received tamoxifen alone, four received aromatase inhibitors alone, and three received tamoxifen followed by an aromatase inhibitor.

Twenty-five (25 %) of patients had started laser treatment an average of two-five years after the end of their local breast cancer treatment and only 12.5% of patients have started her laser treatment after more than 5 years after the end of hormonotherapy. However, five of the eight patients who received tamoxifen or aromatase inhibitors (62.5%) were still under endocrine therapy at the time of inclusion in the study since 1 to four years.

The mean age of the patients was 56.1 ± 8.8 years (range, 27–69 years) and their mean body mass index was 24.54 ± 3.74 Kg/m². Seventeen of the 20 patients had experienced menopause (mean menopausal age, 51.25 ± 1.5 years). Six patients (30%) were smokers, two (10%) had a history of lichen sclerosis, one (5%) had a history of thyroidectomy (due to thyroid nodules), and one (5%) had hypertension and diabetes. Seventeen patients were menopausal. The patients' characteristics are presented in Table 2.

Laser treatment efficacy using vaginal health index score

Table 2 summarizes the results of each vaginal health index parameter before and after treatment. The mean vaginal health index score increased significantly one month after treatment (from 10.58 ± 1.71 before treatment to 13.42 ± 2.3 one month after treatment, $p = 0.03$), which represented an improvement of 21% from the baseline. Similarly, the vaginal health index score increased significantly to 15.21 ± 3.51 and 16.75 ± 4.23 at three and six months after treatment ($p < 0.0001$), respectively (Table 3, Figure 1). Overall, the vaginal health index score was improved by 21% at M1, 30% at M3, and 34% at M6 (Figure 1).

Results of 5 items of vaginal health index score

Vaginal elasticity results

Vaginal elasticity increased significantly from 2.31 ± 0.73 before treatment to 3.18 ± 0.81 at M3 ($p = 0.004$) and 3.37 ± 0.97 at M6 ($p = 0.0003$) (Figure 2, Table 3).

Fluid volume results

The volume of vaginal secretions increased significantly from 1.5 ± 1.04 before treatment to 2.62 ± 0.79 at M3 ($p = 0.0014$) and 2.81 ± 1.05 at M6 ($p = 0.0001$). (Figure 2, Table 3).

pH results

Conversely, there was a slight decrease in vaginal pH from 6.65 ± 0.57 before treatment to 6.59 ± 0.73 at M1, 6.5 ± 1.03 at M3, and 6.31 ± 0.82 at M6 (Table 3, Figure 3).

Vaginal epithelial integrity results

Vaginal epithelial integrity increased significant from 2.31 ± 1.17 before treatment to 3.37 ± 0.59 at M1 ($p = 0.003$), 3.93 ± 0.56 at M3 ($p < 0.0001$), and 3.25 ± 1.20 at M6 ($p = 0.016$). (Figure 2, Table 3).

Moisture results

In the same line, vaginal hydration increased significantly from 2.1 ± 0.78 before treatment to 3.8 ± 0.76 at M1 ($p = 0.03$), 3.9 ± 0.55 at M3 ($p < 0.00001$), and 4.4 ± 0.68 at M6 ($p < 0.00001$) (Figure 2 and Table 3).

Sexual quality results

The patients' sexual quality of life was assessed using the female sexual dysfunction score. The mean score was 21.36 ± 15.10 before treatment, with 70% of the patients having an FSD score of 11.00. At M1, the female sexual dysfunction scores decreased significantly to 19.83 ± 13.57 , representing a 7% improvement compared to the baseline ($p < 0.01$). The score continued to decrease significantly, and at M3, it was 13.88 ± 15.58 , representing a 35% improvement ($p = 0.006$). At this point, 35% of the patients had a score ≥ 11 . At M6, the female sexual dysfunction score declined significantly to 10.35 ± 14.7 , which represents a 52% improvement compared to baseline ($p = 0.001$). At this point, only 15% of the patients had an score ≥ 11 (Figure 4).

Patients satisfaction and treatment safety

Our analysis of patients' satisfaction showed that the mean score was 4.29 ± 2.76 at M1, 4.2 ± 2.77 at M3, and 7.15 ± 1.4 at M6 compared to the baseline. The women had a marked decrease in vaginal atrophy (n = 8; 40.0%) and reported a decrease in vaginal dryness (n = 2; 10.0%).

Regarding treatment tolerance, the mean pain VAS score at the time of treatment was 4.7 ± 2.26 . An analysis of adverse events revealed that two patients had moderate bleeding within 24 hours of receiving treatment. No other adverse effects were reported.

DISCUSSION

Menopausal genitourinary syndrome is a disease caused by a decreased estrogen levels during and following menopause and affects 50 % of postmenopausal women (16). Up to 70% of women surviving breast cancer are expected to experience menopausal genitourinary syndrome, because they are either post-menopausal at diagnosis or they have become menopausal as a result of endocrine therapy or chemotherapy (17-18).

The symptoms associated with menopausal genitourinary syndrome can be alleviated with hormone replacement therapy (HRT), there are safety concerns regarding the use of systemic hormone replacement therapy in breast cancer survivors due to the increased risk of cancer recurrence (19). Our preliminary study showed a significant improvement in the vaginal trophicity and sexual quality of life of women after two laser sessions administered at one-month intervals. These findings suggest that CO₂ laser therapy is potentially promising in women with vulvovaginal atrophy who have a history of breast cancer.

Different studies have demonstrated histological improvements in the vaginal mucosa and a decrease in symptoms of menopausal genitourinary syndrome after laser therapy (20–22). In fact, laser treatment has the potential to be a compelling treatment option for this population (23).

Among our patients, five were in a menopausal status (25%) and five of the eight patients who received tamoxifen or aromatase inhibitors (62.5%) were under endocrine therapy at the time of inclusion.

Although very common, vulvovaginal atrophy is rarely addressed during follow-up visits for patients treated for breast cancer. Most patients report dissatisfaction with the information they received about vulvovaginal atrophy and the treatments offered. A study conducted by Cook et al. in 2017 found that among 800 women treated for breast cancer, 279 reported vaginal symptoms among whom only 40% received treatment (24).

Several studies have shown the effectiveness and safety of CO₂ laser for the management of menopausal genitourinary syndrome (25–27). In fact, the thermal energy generated by laser causes the stimulation and proliferation of a healthy, pluristratified, and glycogen-rich epithelium in the genital mucosa. Additionally, the thermal energy can induce collagen production or synthesis in the lamina propria and neovascularization, resulting in improved lubrication. Histological examination of specimens obtained from the urogenital area before and after laser therapy suggests that the treatment restores optimal physiology of the epithelial compartments and connective tissue (7, 28).

To our knowledge, this is the first multiparameter prospective study to objectively assess the effectiveness of laser CO₂ in vulvovaginal atrophy on a background of breast cancer. Our results showed an improvement in vulvovaginal atrophy-related symptoms in patients with a history of breast cancer. There was a significant and sustained increase in the vaginal health index parameters, including vaginal elasticity, volume of secretions, epithelial integrity and vaginal hydration, at different timepoints (M1, M3, and M6). Furthermore, an improvement in sexual quality of life was observed after two sessions of CO₂ laser treatment, thus showing an improvement in vaginal trophicity. Indeed, the Gynelase laser delivers fractional laser energy. The uniform and orderly application of the spots limits any harmful accumulation of heat. The healthy tissue surface preserved between laser impacts ensures rapid re-epithelialization. Healthy

tissue is left between impacts to promote very rapid epithelialization through precise control of depth, percentage of surface area treated and amount of energy. Histological analyses on biopsies taken from patients after treatment with a fractional CO₂ laser have shown a thickening of the epithelium and basement membrane, improved vascularization, reduced inflammation, increased collagen, fibrin and elastin content, and increased water content improving the symptoms of vaginal dryness. (14)

Different studies conducted on patients with a history of breast cancer, found a significant improvement in the signs of vaginal atrophy and a significant improvement in quality of life scores and sexual distress. These studies did not report adverse events (10-12), (29) The study of Becorpi et al. conducted on 20 patients with breast cancer, showing the efficacy of CO₂ laser therapy suggest that the beneficial effect is due to biochemical and morphological alterations in the vaginal epithelial cells, which are, consequently, associated with the expression of specific cytokines during the anti-inflammatory process. (10).

Otherwise, few studies report complications related to laser therapy. A study of 102 patients treated with CO₂ laser reported the following complications: urinary infection in three patients, vaginal infections in two patients, three episodes of pelvic pain, recurrent herpes infection, and two cases of metrorrhagia in endometrial hyperplasia (26). In our cohort, after the treatment sessions, two patients had metrorrhagia after 24 hours. No other side effects were reported.

CONCLUSION

This preliminary pilot study showed the safety and efficacy of CO₂ laser in patients with vulvovaginal atrophy who have a history of breast cancer. Although the results show an improvement in vaginal health among breast cancer survivors, relevant conclusions cannot be

drawn regarding the long-term benefits of laser therapy in this group of patients. Additionally, given the short follow-up of the patients, it is unclear how often treatment should be administered to provide symptomatic relief in these patients and how much follow-up would be necessary. Therefore, this study will be part of the randomized controlled multicenter clinical trial EPIONE, which will include 300 patients randomly assigned to three treatment groups (topical treatments, laser, and parenteral).

Conflict of interest: None

REFERENCES

1. Biglia N, Bounous VE, D'Alonzo M, Ottino L, Tuninetti V, Robba E, et al. Vaginal Atrophy in Breast Cancer Survivors: Attitude and Approaches Among Oncologists. *Clin Breast Cancer*. 2017;17(8):611–7.
2. Portman DJ, Gass MLS, Vulvovaginal Atrophy Terminology Consensus Conference Panel. Genitourinary syndrome of menopause: new terminology for vulvovaginal atrophy from the International Society for the Study of Women's Sexual Health and the North American Menopause Society. *Menopause N Y N*. 2014 Oct;21(10):1063–8.
3. Kingsberg S, Larkin L. Shining the light on genitourinary syndrome of menopause in survivors of breast cancer. *Menopause N Y N*. 2017;24(12):1336–7.
4. Santen RJ, Stuenkel CA, Davis SR, Pinkerton JV, Gompel A, Lumsden MA. Managing Menopausal Symptoms and Associated Clinical Issues in Breast Cancer Survivors. *J Clin Endocrinol Metab*. 2017 01;102(10):3647–61.
5. Sturdee DW, Panay N, International Menopause Society Writing Group. Recommendations for the management of postmenopausal vaginal atrophy. *Climacteric J Int Menopause Soc*. 2010 Dec;13(6):509–22.
6. Hersant B, SidAhmed-Mezi M, Belkacemi Y, Darmon F, Bastuji-Garin S, Werkoff G, et al. Efficacy of injecting platelet concentrate combined with hyaluronic acid for the treatment of vulvovaginal atrophy in postmenopausal women with history of breast cancer: a phase 2 pilot study. *Menopause N Y N*. 2018;25(10):1124–30.
7. Tadir Y, Gaspar A, Lev-Sagie A, Alexiades M, Alinsod R, Bader A, et al. Light and energy based therapeutics for genitourinary syndrome of menopause: Consensus and controversies. *Lasers Surg Med*. 2017;49(2):137–59.
8. Pitsouni E, Grigoriadis T, Falagas ME, Salvatore S, Athanasiou S. Laser therapy for the genitourinary syndrome of menopause. A systematic review and meta-analysis. *Maturitas*. 2017 Sep;103:78–88.

9. Pagano I, Gieri S, Nocera F, Scibilia G, Fraggetta F, Galia A, et al. Evaluation of the CO₂ Laser Therapy on Vulvo-Vaginal Atrophy (VVA) in Oncological Patients: Preliminary Results. *J Cancer Ther.* 2017 May 18;8(5):452–63.
10. Becorpi A, Campisciano G, Zanotta N, Tredici Z, Guaschino S, Petraglia F, et al. Fractional CO₂ laser for genitourinary syndrome of menopause in breast cancer survivors: clinical, immunological, and microbiological aspects. *Lasers Med Sci.* 2018 Jul;33(5):1047–54.
11. Pieralli A, Fallani MG, Becorpi A, Bianchi C, Corioni S, Longinotti M, et al. Fractional CO₂ laser for vulvovaginal atrophy (VVA) dyspareunia relief in breast cancer survivors. *Arch Gynecol Obstet.* 2016;294(4):841–6.
12. Gittens P, Mullen G. The effects of fractional microablative CO₂ laser therapy on sexual function in postmenopausal women and women with a history of breast cancer treated with endocrine therapy. *J Cosmet Laser Ther Off Publ Eur Soc Laser Dermatol.* 2019;21(3):127–31.
13. Bachmann G. Urogenital ageing: an old problem newly recognized. *Maturitas* 1995;22:S1-S5.
14. Samuels JB, Garcia MA. Treatment to External Labia and Vaginal Canal With CO₂ Laser for Symptoms of Vulvovaginal Atrophy in Postmenopausal Women. *Aesthet Surg J.* 2019 Jan 1;39(1):83-93.
15. Derogatis L, Clayton A, Lewis-D'Agostino D, Wunderlich G, Fu Y. Validation of the female sexual distress scale-revised for assessing distress in women with hypoactive sexual desire disorder. *J Sex Med.* 2008 Feb;5(2):357–64.
16. Kingsberg SA, Wysocki S, Magnus L, Krychman ML. Vulvar and vaginal atrophy in postmenopausal women: findings from the REVIVE (REal Women's VIEWS of Treatment Options for Menopausal Vaginal ChangEs) survey. *J Sex Med.* 2013 Jul;10(7):1790-9
17. Knight C, Logan V, Fenlon D. A systematic review of laser therapy for vulvovaginal atrophy/genitourinary syndrome of menopause in breast cancer survivors. *Ecancermedicalsecience.* 2019 Dec 12;13:988.

18. Cleeland CS, Allen JD, Roberts SA, Brell JM, Giralt SA, Khakoo AY, et al. Reducing the toxicity of cancer therapy: recognizing needs, taking action. *Nat Rev Clin Oncol*. 2012 Aug;9(8):471–8.
19. North American Menopause Society. The 2012 hormone therapy position statement of: The North American Menopause Society. *Menopause N Y N*. 2012 Mar;19(3):257–71.
20. Salvatore S, Nappi RE, Zerbinati N, Calligaro A, Ferrero S, Origoni M, et al. A 12-week treatment with fractional CO2 laser for vulvovaginal atrophy: a pilot study. *Climacteric*. 2014 Aug 1;17(4):363–9.
21. Gaspar A, Addamo G, Brandi H. Vaginal Fractional CO2 Laser: A Minimally Invasive Option for Vaginal Rejuvenation: *Am J Cosmet Surg* [Internet]. 2011 Sep 1 [cited 2020 Mar 3]; Available from: <https://journals.sagepub.com/doi/10.1177/074880681102800309>
22. Zerbinati N, Serati M, Origoni M, Candiani M, Iannitti T, Salvatore S, et al. Microscopic and ultrastructural modifications of postmenopausal atrophic vaginal mucosa after fractional carbon dioxide laser treatment. *Lasers Med Sci*. 2015 Jan 1;30(1):429–36.
23. Biglia N, Bounous VE, Sgro LG, D’Alonzo M, Pecchio S, Nappi RE. Genitourinary Syndrome of Menopause in Breast Cancer Survivors: Are We Facing New and Safe Hopes? *Clin Breast Cancer*. 2015 Dec;15(6):413–20.
24. Cook ED, Iglehart EI, Baum G, Schover LL, Newman LL. Missing documentation in breast cancer survivors: genitourinary syndrome of menopause. *Menopause N Y N*. 2017 Dec;24(12):1360–4.
25. Quick AM, Zvinovski F, Hudson C, Hundley A, Evans C, Suresh A, et al. Fractional CO2 laser therapy for genitourinary syndrome of menopause for breast cancer survivors. *Support Care Cancer* [Internet]. 2019 Dec 6 [cited 2019 Dec 13]; Available from: <https://doi.org/10.1007/s00520-019-05211-3>
26. Behnia-Willison F, Sarraf S, Miller J, Mohamadi B, Care AS, Lam A, et al. Safety and long-term efficacy of fractional CO2 laser treatment in women suffering from genitourinary syndrome of menopause. *Eur J Obstet Gynecol Reprod Biol*. 2017 Jun;213:39–44.
27. Sokol ER, Karram MM. Use of a novel fractional CO2 laser for the treatment of genitourinary syndrome of menopause: 1-year outcomes. *Menopause N Y N*. 2017 Jul;24(7):810–4.

28. Salvatore S, Leone Roberti Maggiore U, Athanasiou S, Origoni M, Candiani M, Calligaro A, et al. Histological study on the effects of microablative fractional CO2 laser on atrophic vaginal tissue: an ex vivo study. *Menopause N Y N*. 2015 Aug;22(8):845–9.
29. Pagano T, De Rosa P, Vallone R, Schettini F, Arpino G, De Placido S, et al. Fractional microablative CO2 laser for vulvovaginal atrophy in women treated with chemotherapy and/or hormonal therapy for breast cancer: a retrospective study. *Menopause N Y N*. 2016;23(10):1108–13.

Tables and figure legends

Table 1: Parameters of *Gloria Bachman Vaginal Health Index (VHI)*

Table 2: Demographic and clinical characteristics of the sample

Table 3: Improvement in the parameters of the vaginal health index scores after treatment

Figure 1: Changes in the mean vaginal health index score and the percentage of improvement from the baseline (pre-treatment) at different points after treatment. The results represent mean \pm standard deviation. (**** $p < 0.0001$).

Figure 2: One-way ANOVA comparison of elasticity, fluid volume, epithelial integrity, and moisture at different points (baseline, M0, M1, M3, and M6) and Tukey post-hoc test results. The data are presented as mean \pm standard deviation (* $p < 0.05$, ** $p < 0.01$, *** $p < 0.001$, **** $p < 0.0001$).

Figure 3: Variation in pH at different points (baseline or pre-treatment, M1, M3, and M6). The bars represent the standard deviation.

Figure 4: Female sexual distress (FSD) score and percentage of improvement from baseline (pre-treatment) to different points after treatment (M1, M3, and M6). The results represent mean \pm standard deviation. (* $p < 0.05$, ** $p < 0.01$).



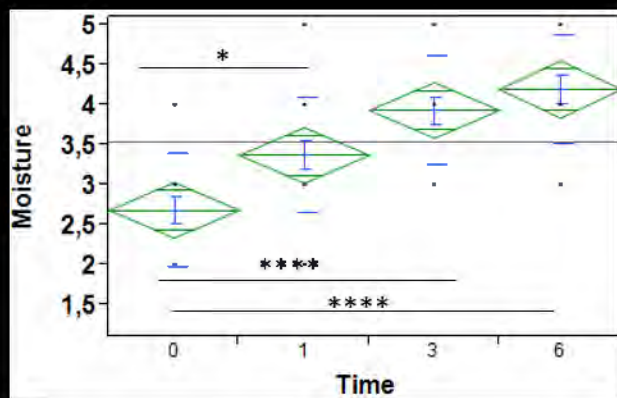
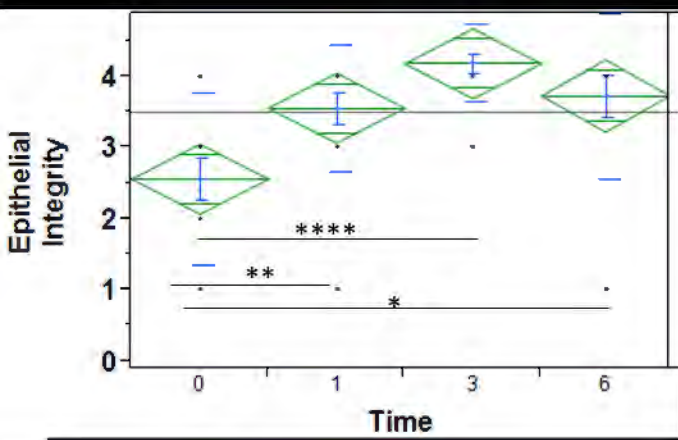
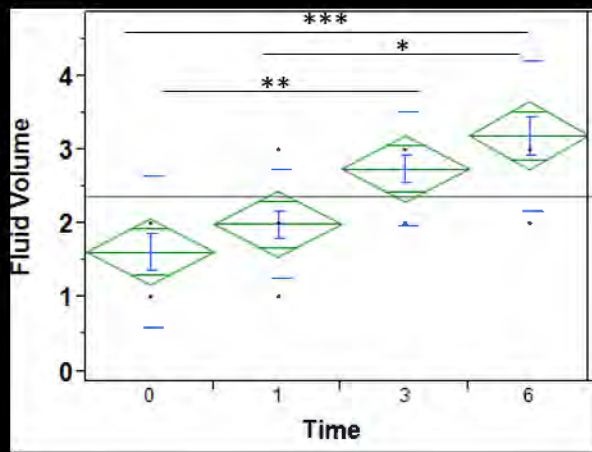
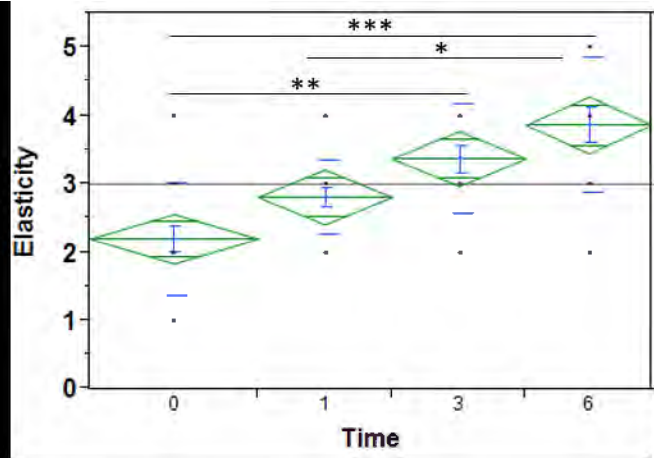


Table 1: Parameters of *Gloria Bachman* Vaginal Health Index (VHI)

	1	2	3	4	5
Elasticity	none	poor	Fair	good	Excellent
Fluid Volume (pooling of secretion)	none	scar amount, vault not entirely covered	superficial amount, vault entirely covered	Moderate amount of dryness (small areas of dryness on cotton tip applicator)	Normal amount
pH	≥ 6.1	5.6-6.0	5.1-5.5	4.7-5.0	≤ 4.6
Epithelial Integrity	petechiae noted before contact	bleeds with light contact	bleeds with scraping	not friable-thin epithelium	Normal
Moisture	None, surface inflamed	none, surface not inflamed	minimal	moderate	Normal

Table 1: Demographic and clinical characteristics of the sample

Characteristics	Frequency (Percent)*
Age (years)	
< 40	1 (5.0)
40–60	8 (16.0)
> 60	11 (55.0)
Smokers	6 (30.0%)
Menopausal	17 (85.0%)
Chemotherapy	
None	5 (29.4)
Adjuvant	7 (41.2)
Neoadjuvant	2 (11.8)
Concomitant	3 (17.6)
Radiotherapy	
Adjuvant	13 (92.9)
Concomitant	1 (7.1)
Hormone therapy	
None	4 (30.8)
Adjuvant	9 (69.2)
Duration of hormone therapy	
Ongoing	5 (62.5)
2–5 years	2 (25.0)
> 5 years	1 (12.5)

* Totals may differ due to missing values of some variables.

Table 2: Improvement in the parameters of the vaginal health index scores after treatment

Parameters	Pre-treatment (mean ± SD)	1 month (mean ± SD)	3 months (mean ± SD)	6 months (mean ± SD)
Elasticity	2.31 ± 0.73	2.62 ± 0.56	3.18 ± 0.81	3.37 ± 0.97
Fluid volume (pooling of secretions)	1.5 ± 1.04	1.87 ± 0.75	2.62 ± 0.79	2.81 ± 1.05
pH	6.65 ± 0.57	6.59 ± 0.73	6.5 ± 1.03	6.3 ± 0.82
Epithelial integrity	2.31 ± 1.17	3.37 ± 0.59	3.93 ± 0.56	3.25 ± 1.20
Moisture	2.1 ± 0.78	3.8 ± 0.76	3.9 ± 0.55	4.4 ± 0.68
Total	10.58 ± 1.71	13.4 ± 2.30**	15.21 ± 3.51****	16.75 ± 4.23****

Abbreviations: NS: non-significant; SD: standard deviation.

* p < 0.05

** p < 0.01

***p < 0.001

**** p < 0.0001