



**HAL**  
open science

## **Evidence of diaphragmatic dysfunction with severe alveolar hypoventilation syndrome in mitochondrial respiratory chain deficiency**

Giulia Barcia, Sonia Khirani, Alessandro Amaddeo, Zahra Assouline, Alessandra Pennisi, Nathalie Boddaert, Norma Romero, Isabelle Desguerre, Manuel Schiff, Agnès Rötig, et al.

### ► To cite this version:

Giulia Barcia, Sonia Khirani, Alessandro Amaddeo, Zahra Assouline, Alessandra Pennisi, et al.. Evidence of diaphragmatic dysfunction with severe alveolar hypoventilation syndrome in mitochondrial respiratory chain deficiency. *Neuromuscular Disorders*, 2020, 30, pp.593 - 598. 10.1016/j.nmd.2020.06.002 . hal-03492110

**HAL Id: hal-03492110**

**<https://hal.science/hal-03492110>**

Submitted on 22 Aug 2022

**HAL** is a multi-disciplinary open access archive for the deposit and dissemination of scientific research documents, whether they are published or not. The documents may come from teaching and research institutions in France or abroad, or from public or private research centers.

L'archive ouverte pluridisciplinaire **HAL**, est destinée au dépôt et à la diffusion de documents scientifiques de niveau recherche, publiés ou non, émanant des établissements d'enseignement et de recherche français ou étrangers, des laboratoires publics ou privés.



Distributed under a Creative Commons Attribution - NonCommercial 4.0 International License

# Evidence of diaphragmatic dysfunction with severe alveolar hypoventilation syndrome in mitochondrial respiratory chain deficiency

Giulia Barcia<sup>a</sup>, Sonia Khirani<sup>b,c,d</sup>, Alessandro Amaddeo<sup>b,c</sup>, Zahra Assouline<sup>a</sup>,  
Alessandra Pennisi<sup>a</sup>, Nathalie Boddaert<sup>a</sup>, Norma Romero<sup>e</sup>, Isabelle Desguerre<sup>a</sup>,  
Manuel Schiff<sup>a</sup>, Agnès Rötig<sup>a</sup>, Claude Besmond<sup>a</sup>, Jean-Paul Bonnefont<sup>a</sup>, Arnold  
Munnich<sup>a,\*</sup> and Brigitte Fauroux<sup>b,c</sup>

<sup>a</sup> *Fédération de Génétique Médicale, Hôpital Necker–Enfants Malades, and UMR 1163, Université de Paris, Institut IMAGINE, Paris, France*

<sup>b</sup> *Pediatric Noninvasive Ventilation and Sleep Unit, Hôpital Necker–Enfants Malades, Paris, France*

<sup>c</sup> *VIFASOM, Université de Paris, Paris, France*

<sup>d</sup> *ASV Santé, Gennevilliers, France*

<sup>e</sup> *Neuromuscular Morphology Unit and Myology Institute, Hôpital Pitié-Salpêtrière, Paris, France*

## Abstract

Diaphragmatic dysfunction has been reported in congenital myopathies, muscular dystrophies, and occasionally, mitochondrial respiratory chain deficiency. Using a minimally invasive procedure in 3 young girls—1 with a heteroplasmic *MT-CYB* mutation and 2 with biallelic pathogenic *TK2* variants—we provided functional evidence of diaphragmatic dysfunction with global respiratory muscle weakness in mitochondrial respiratory chain deficiency. Analysis of respiratory muscle performance using esogastric pressures revealed paradoxical breathing and severe global inspiratory and expiratory muscle weakness with a sniff esophageal inspiratory pressure and a gastric pressure during cough averaging 50% and 40% of predicted values, respectively. This diaphragmatic dysfunction was responsible for severe undiagnosed nocturnal hypoventilation, requiring noninvasive ventilation. Our results underline the interest of this minimally invasive procedure for the evaluation of respiratory muscle performance and its potential value for the monitoring of future clinical trials in respiratory chain deficiency.

**Keywords:** Mitochondrial disease; Diaphragmatic dysfunction; mtDNA; *MT-CYB*; *TK2*.

\* Corresponding author at :

Fédération de Génétique Médicale, Hôpital Necker–Enfants Malades, 149 rue de Sèvres,  
75015 Paris, France.

*E-mail:* arnold.munnich@inserm.fr (A. Munnich).

*Tel:* +33 6 08 23 21 61

# 1. Introduction

The diaphragm is the main inspiratory muscle. As breathing during sleep—especially REM sleep—relies almost exclusively on this muscle, it plays an essential role. Respiratory muscle weakness with selective diaphragmatic dysfunction has occasionally been reported in congenital myopathies and muscular dystrophies [1–3]. This dysfunction is frequently ignored, especially when peripheral muscle strength is preserved. Yet its detection is critical, due to the risk of severe nocturnal hypoventilation and respiratory failure.

It is generally accepted that mitochondrial respiratory chain deficiency can have a variety of symptoms concerning numerous organs and tissues, at different ages [4]. Among the organs involved, the respiratory muscles and diaphragm are occasionally mentioned [5–12]. Here we report on the minimally invasive analysis of respiratory muscle performance in 3 children carrying pathogenic variants of distinct mitochondrial respiratory enzyme genes, namely mitochondrially encoded cytochrome *b* (*MT-CYB*) and nuclear thymidine kinase 2 (*TK2*). We propose this minimally invasive evaluation of respiratory muscle performance for monitoring of disease progression and use in future clinical trials concerning respiratory chain deficiency.

## 2. Patients and Methods

Patient #1 was the first child of healthy, unrelated parents of Turkish origin. She was born at 39 wk of pregnancy by cesarean section (birthweight: 3.83 kg; height: 53 cm; occipital-frontal circumference: 34 cm). She could sit unaided by 6 mo, stand by 12 mo and walk by 17 mo. She first came to medical attention at 18 mo, because of late walking and inability to rise without assistance. At that age, she presented with peripheral muscle weakness, facial amimia, trunk hypotonia, poor sucking, frequent stools (4/d), and failure to thrive. Segmental hypotonia, unbalanced gait, reduced muscle bulk, and mild eyelid ptosis were observed, but no organ or cranial nerve involvement, nor pyramidal or cerebellar signs. From the age of 5 y on, the patient occasionally had to use a wheelchair due to frequent episodes of intense peripheral muscle weakness and also required spinal brace followed by posterior arthrodesis because of progressive lumbar scoliosis. Repeated episodes of rhinopharyngitis, bronchitis, and bronchial congestion occurred. At the age of 9 y, she was a normally intelligent, assiduous pupil exhibiting regular academic performance, but her parents reported learning and

memory difficulties and altered manual dexterity, arithmetic skills, reaction time, and cognitive reasoning.

Brain MRI and heart ultrasound were normal, and visual acuity was 9/10 on both sides after correction of a moderate myopia. Optic disks were moderately pale on both sides, suggesting a mild optic neuropathy. Metabolic workup consistently revealed high plasma lactate levels and lactate to pyruvate molar ratios (lactate: 3 mM, where normal levels are <2.4 mM; lactate to pyruvate ratio: 20:1 to 22:1, where normal ratios range from 10:1 to 12:1), normal plasma amino acid levels, large amounts of urinary Krebs cycle intermediates (lactate, fumarate, malate, 3-methylglutaconic acid and  $\alpha$ -ketoglutaric acid) and no evidence of proximal tubule disorder.

Patient #2 was the third child of healthy, unrelated parents of French ancestry. She was born after a term pregnancy and normal delivery (birthweight: 3.41 kg; height: 49 cm; occipital-frontal circumference: 33.5 cm). She could sit unaided by 10 mo and walk by 16 mo. She came to medical attention at 3 y for slow motor recovery following a fracture of her right tibia. At 4 y, school nurses noted a motor delay with progressive distal muscle weakness and fatigue. At 5 y, her gait slowed and became unsteady, and her speech was harder to understand. At 5½ y, she had combined proximal-distal muscle weakness, predominantly concerning the upper limbs, together with scapular muscle atrophy and a narrow thorax. Owing to extreme muscle weakness, she could not raise her arms and had to swing her upper limb to execute delicate hand movements. No retraction, lower limb flexion deformity, or scoliosis was observed, but a rigid spine and bilateral pes cavus were noted. Weak deep tendon reflexes were present, as well as Gowers' sign. Facial involvement included amimia and eyelid ptosis. Soft palate and throat muscle weakness resulted in rhinolalia and nonproductive cough. The patient experienced bilateral transmission hearing loss due to frequent serous otitis. She could not climb stairs and needed help to get dressed and use eating utensils. She received normal schooling and was considered a talented and engaged pupil with an outgoing personality. Her brain MRI and heart ultrasounds were normal.

Patient #3, the eldest sister of Patient #2, was delivered by caesarean section at 36 wk of pregnancy due to poor active fetal movements (birthweight: 2.9 kg; height: 50 cm; occipital-frontal circumference: 35 cm; Apgar score:10). She could sit unaided at 6 mo and walk at 14 mo, but her gait was clumsy and she fell frequently. She came to medical attention at 10 y when her younger sister (Patient #2) was first seen. Patient #3 was also less severely affected than her younger sister (29 kg,

142 cm). She had reduced limb muscle strength with major shoulder girdle weakness, orofacial involvement, eyelid ptosis, amimia, soft palate weakness, and rhinolalia. She exhibited markedly reduced chest expansion and a rigid spine but no scoliosis, limb retraction, or pes cavus. Though the patient could raise her arms horizontally, place her hands over her head, climb stairs using the handrail, walk unaided, and ride a bike, she complained of fatigue. Her brain MRI and heart ultrasounds were normal and she received normal schooling. The metabolic workup for the 2 sisters was unremarkable (lactate: 1.8 mM; CPK: 145 and 83 U/L respectively, where normal range is 30 to 180 U/L).

Respiratory muscle evaluation was performed by measurement of esogastric pressures [1–3]. This minimally invasive technique uses a thin esogastric catheter (external diameter: 2.1 mm; Gaeltec, Dunvegan, Isle of Skye, UK) to measure esogastric pressures during spontaneous breathing and natural, easy-to-perform, volitional maneuvers (e.g., cough or sniff). It is particularly useful in children who may have difficulty correctly performing standard reproducible tests such as forced vital capacity (FVC) and maximal static pressures [1–3]. Transdiaphragmatic pressure (P<sub>di</sub>), which indicates the strength of the diaphragm, was obtained by subtracting esophageal pressure (P<sub>es</sub>) from gastric pressure (P<sub>gas</sub>). Paradoxical breathing was defined by a negative P<sub>gas</sub>-P<sub>di</sub> swing index ( $\Delta P_{gas}/\Delta P_{di}$ ) on at least 10 stable respiratory cycles. Strength of global inspiratory muscles, and specifically the diaphragm, was determined using  $\Delta P_{es}$  and  $\Delta P_{di}$  during maximal sniffs. Gastric pressure during a maximal cough (cough P<sub>gas</sub>) was measured to assess the strength of the expiratory muscles.

Spectrophotometric assays of respiratory chain enzymes were carried out as previously described [13]. Genomic DNA was extracted from peripheral blood using QIAGEN or Autopure DNA purification kits. For whole exome sequencing and next-generation panel resequencing of nuclear genes associated with mitochondrial disease, paired-end sequence data sets from Illumina NextSeq runs were processed in 3 main steps: alignment against the human genome (hg19), variant calling for SNPs and small base insertions or deletions using SAMtools [14] and GATK [15], and variant annotation based on the Ensembl human database (GRCh37). Data were integrated in pipelines enabling copy number variant analysis based on double normalization of depth coverage.

Mitochondrial DNA (mtDNA) was first amplified in 2 fragments by long-range PCR (8.2 kb and 8.3 kb, respectively). Libraries were prepared from 1.5  $\mu$ g of PCR product sheared by sonication (Covaris S2 system). Fragment indexation for each patient was performed using Ovation Target Capture

Module (NuGEN), and DNA was sequenced with an Illumina MiSeq (Illumina Inc., San Diego, CA) generating  $2 \times 130$  paired-end reads. Paired-end sequence data sets from Illumina MiSeq were aligned against human mitochondrial DNA (NC\_012920.1) with BWA. SNP variant calling (with SAMtools, GATK, and FreeBayes) and variant annotation were based on the Ensembl human database (GRCh37).

### 3. Results

Overnight polysomnography in Patient #1 detected severe alveolar hypoventilation with hypoxemia and hypercapnia requiring nocturnal noninvasive ventilation at the age of 7 y. Concomitant evaluation of respiratory muscle performance revealed paradoxical breathing and severe global inspiratory and expiratory muscle weakness with average sniff  $P_{es}$  and cough  $P_{gas}$  measurements respectively at 50% and 40% of expected values (Table and Fig. 1). Interestingly, analysis of the gastric pressure during a maximal sniff (sniff  $P_{gas}$ ) revealed an abnormal negative deflection despite a small initial positive deflection, reflecting diaphragmatic dysfunction [1–3].

The pattern of respiratory muscle weakness and diaphragmatic dysfunction of Patient #2 at 8 y and Patient #3 at 12 y was similar to that of Patient #1, with an abnormal negative sniff  $P_{gas}$  (Table and Fig. 1). Interestingly, paradoxical breathing was intermittent in Patient #3 and not observed in her younger sister, Patient #2. Respiratory muscle weakness and diaphragmatic dysfunction worsened in the 2 sisters on a second assessment 2 y later, with lower sniff  $P_{es}$  and sniff  $P_{di}$  values (Table). Both required long-term, noninvasive ventilation because of nocturnal hypoventilation associated with recurrent respiratory tract infections and weight loss.

Histological and histochemical analyses of a deltoid muscle biopsy for Patient #1 showed typical signs of mitochondrial myopathy: numerous ragged red fibers upon modified Gömöri trichrome staining and fibers positive for cytochrome *c* oxidase (COX) and succinic dehydrogenase (SDH), most associated with large lipid droplets (Fig. 2). A skeletal biopsy for Patient #2 displayed a similar pattern of mitochondrial myopathy: many ragged red fibers upon modified Gömöri trichrome staining and COX-negative, SDH-positive fibers, many with large lipid droplets, while others were apparently preserved (not shown).

Spectrophotometric analyses of skeletal muscle homogenate from Patient #1 showed elevated citrate synthase, respiratory chain complex II, and respiratory chain complex V activity, suggesting

increased mitochondrial mass. Complexes I, III, and IV were severely defective (complex I / citrate synthase = 0.03, normal: 0.12 to 0.22; complex III / citrate synthase = 0.2, normal: 2.3 to 3.6; complex IV / citrate synthase = 0.4, normal: 1.2 to 2). In Patient #2, citrate synthase activity was elevated while complexes III and IV were severely defective (complex III / citrate synthase = 0.2, normal: 2.3 to 3.6; complex IV / citrate synthase = 0.59, normal: 1.2 to 2).

High-throughput sequencing of long-range PCR-amplified mtDNA from Patient #1 detected a hitherto unreported heteroplasmic m.15108T>G variation in the *MT-CYB* gene with variable levels of mutant species in skeletal muscle (30%), urinary epithelia (60%), and circulating leukocytes (45%). No other variation was detected by sequencing the entire mitochondrial genome, and whole exome sequencing failed to detect pathogenic nuclear variants, including known congenital myasthenic syndrome genes. No detectable levels of the m.15108T>G *MT-CYB* variation were found in circulating leukocytes and urinary epithelia of Patient #1's mother. This variation, which changes a hydrophobic leucine into a basic arginine residue (p.Leu121Arg), affects a conserved nucleotide and has never been reported as a polymorphism (MITOMAP database) [16]. Patients #2 and #3 were found to be compound heterozygotes for 2 nucleotide variants concerning the thymidine kinase 2 gene (*TK2*, NM\_004614.4) previously reported in the HGMD database: a single nucleotide missense variant in exon 8 of the maternal *TK2* gene (c.588A>T; p.Arg196Ser) [17], predicted to be damaging by Alamut Visual software (SIFT: deleterious, score: 0; MutationTaster: disease-causing [ $p = 1$ ]; PolyPhen-2: probably damaging, score: 1.000, sensitivity: 0.00; specificity: 1.00), and a single nucleotide variant at the paternal intron 2 splice donor site [18].

## 4. Discussion

Using a minimally invasive procedure based on the measurement of esogastric pressures in 3 young girls carrying biallelic pathogenic *TK2* variants and a heteroplasmic *MT-CYB* variant, respectively, we provide the first direct, functional evidence of diaphragmatic dysfunction and respiratory muscle weakness in mitochondrial respiratory chain deficiency. Evaluation of respiratory muscle performance in vivo revealed paradoxical breathing and severe global inspiratory and expiratory muscle weakness in the 3 patients, with a markedly reduced sniff  $P_{es}$  and cough  $P_{gas}$ . Interestingly, they all exhibited rather similar patterns of diaphragmatic dysfunction, irrespective of the gene causing the mitochondrial disease.

This observation is especially important since each child was found to have severe nocturnal hypoventilation requiring noninvasive ventilation without the common clinical symptoms of nocturnal hypoventilation. It is worth noting that diaphragmatic dysfunction may be overlooked when peripheral muscle strength is preserved (i.e., still able to walk or stand alone), which was the case in our patients. The value of the esogastric pressure measurement was of particular interest in these patients because the “classical” noninvasive tests, such as FVC and maximal static pressures, used to evaluate respiratory muscle strength in clinical practice, were not contributive because none of the patients was able to perform maximal, reproducible, and technically acceptable maneuvers.

Patient #1 carried a previously unreported, de novo heteroplasmic mutation in the mitochondrial *MT-CYB* gene, encoding cytochrome *b*, a subunit of the mitochondrial *bc<sub>1</sub>* complex (complex III). Evidence of the pathogenicity of the m.15108T>G variation in the *MT-CYB* gene includes (i) the conservation of the affected nucleotide; (ii) the variable heteroplasmic levels of mutant species among tissues; (iii) its absence in circulating leukocytes and urinary epithelia of the mother, suggesting that the variant arose de novo; and finally, (iv) the absence of other pathogenic variants in the whole exome and mitochondrial genome. Complex III is a membrane-bound enzyme that catalyzes the transfer of electrons from ubiquinol to cytochrome *c*. Cytochrome *b* is a hydrophobic, integral membrane protein essential for proper assembly and function of complex III. It forms the catalytic core of the enzyme with cytochrome *c<sub>1</sub>* and an iron-sulfur protein. Why a variant in this mtDNA-encoded complex III subunit caused multiple respiratory chain deficiency in the muscle of Patient #1 deserves attention. A study by Blakely et al. reported that a small number of *MT-CYB* mutations are associated with a combined defect involving complexes I and III [19]. Studying a patient with a mutation in the *MT-CYB* gene (Arg318Pro) and severely reduced complex I and complex III activity in skeletal muscle, they showed that lack of assembled complex III greatly reduces the amount of complex I, confirming their structural interdependence [19]. To date, only a few cases of respiratory complex III deficiency have been ascribed to *MT-CYB* mutations. Clinical presentations of reported patients have included mitochondrial myopathy with exercise intolerance [20], muscle weakness, myoglobinuria, encephalomyopathy [21], cardiomyopathy [22], septo-optic dysplasia [23], and multisystem disorder [24], but neither diaphragmatic dysfunction nor alveolar hypoventilation syndrome.

Patients #2 and #3 carried biallelic mutations in *TK2*, a nuclear gene encoding a mitochondrial kinase required for synthesis of mitochondrial thymidine and deoxycytidine triphosphate, which are



deoxyribonucleoside triphosphates (dNTPs). In mitochondria, dNTP production relies solely on the salvage pathway. Imbalanced mitochondrial dNTP pools lead to mtDNA depletion or deletions resulting in serious mitochondrial diseases. While biallelic *TK2* mutations are usually associated with a myopathic mitochondrial DNA depletion syndrome [7], late-onset forms of the disease have recently been described in a series of 18 patients >12 y old [5]. All showed evidence of respiratory muscle weakness—necessitating noninvasive mechanical ventilation in 12 of the 18 cases—and 4 died from respiratory insufficiency [5]. Hence, the risks of early progressive respiratory insufficiency and acute respiratory failure seriously compromise the prognosis of late-onset conditions associated with *TK2* mutations. Along the same lines, fulminant respiratory muscle paralysis has been reported in a 20-year-old Asian female with mild weakness of the limbs carrying a m.3243A>G *MTTL* mutation [12]. Functional studies showed evidence of myopathy in this patient, and pulmonary function testing indicated restrictive lung function.

While a wide variety of presenting or associated symptoms have been reported in respiratory chain deficiency [3], no direct evidence of severe alveolar hypoventilation secondary to diaphragmatic dysfunction with global respiratory muscle weakness has hitherto been documented in mitochondrial disorders. Whether diaphragmatic involvement is specific to particular genotypes, as the ones reported here, or underdiagnosed in respiratory chain deficiency merits special attention. Future studies using the minimally invasive procedure we have described—i.e., in vivo evaluation of respiratory muscle performance using esogastric pressures—and aimed at systematically investigating selective respiratory muscle performance in patients carrying pathogenic variants of oxidative phosphorylation genes, will hopefully address this question. Finally, we propose using the procedure for monitoring disease course, as well as a tool for future clinical trials concerned with respiratory chain deficiency.

## Table and Figure Captions

### Table Breathing pattern and respiratory muscle function in patients

**Fig. 1 Breathing pattern and sniff maneuver.** A: Normal breath tracing showing a negative esophageal pressure swing (arrow) during inspiration, and a positive gastric (arrow) and transdiaphragmatic pressure swing. B: Paradoxical breath tracing with a negative esophageal (arrow) and gastric (arrow) pressure swing during inspiration in Patient #2. C: Normal sniff tracing with a sharp negative esophageal pressure swing during inspiration, and a positive gastric and transdiaphragmatic pressure swing. D: Abnormal sniff tracing showing a moderate negative esophageal pressure swing and an abnormal negative gastric pressure swing reflecting diaphragmatic dysfunction in Patient #1. Note that the esophageal, nasal, and transdiaphragmatic pressures are severely reduced, reflecting respiratory muscle weakness. Abbreviations: I: inspiration; E: expiration; Pes: esophageal pressure; Pgas, gastric pressure; Pn: nasal pressure; Pdi: transdiaphragmatic pressure.

**Fig. 2 Skeletal muscle histopathology for deltoid biopsy of Patient #1 at 6 y.** **A:** Gömöri trichrome (GT) staining shows variable fiber size and many ragged red fibers. **B:** Succinic dehydrogenase (SDH) reaction unravels numerous fibers harboring mitochondrial aggregates beneath the sarcolemma and ragged red fibers. **C:** Positive cytochrome *c* oxidase (COX) reaction. **D:** Adenosine triphosphatase staining (pH 9.4) reveals predominance of type 1 fibers.

## **Declarations of Interest**

None.

## **Author Contributions**

All authors have approved the final version of this article.

## **Funding**

This research did not receive any specific grant from funding agencies in the public, commercial, or not-for-profit sectors.

## **Acknowledgements**

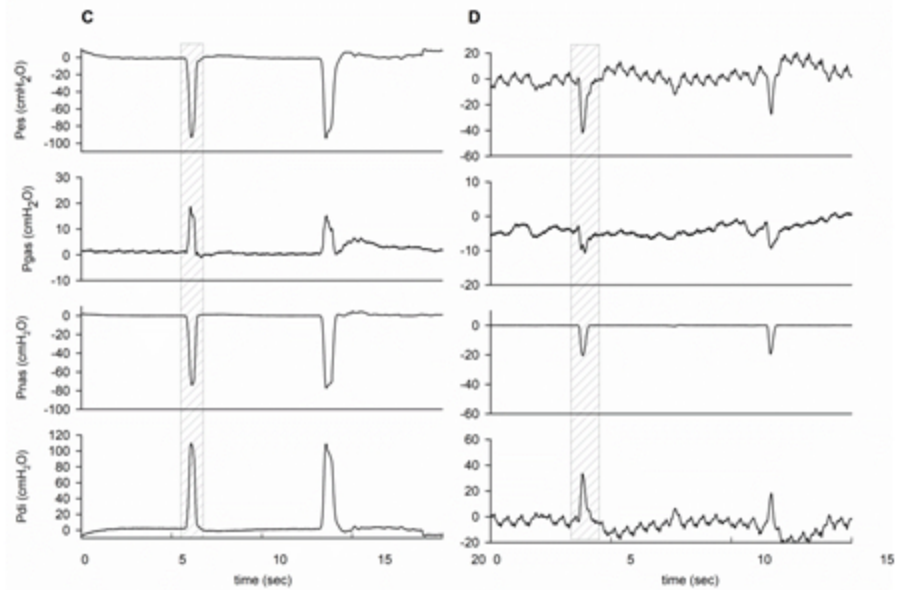
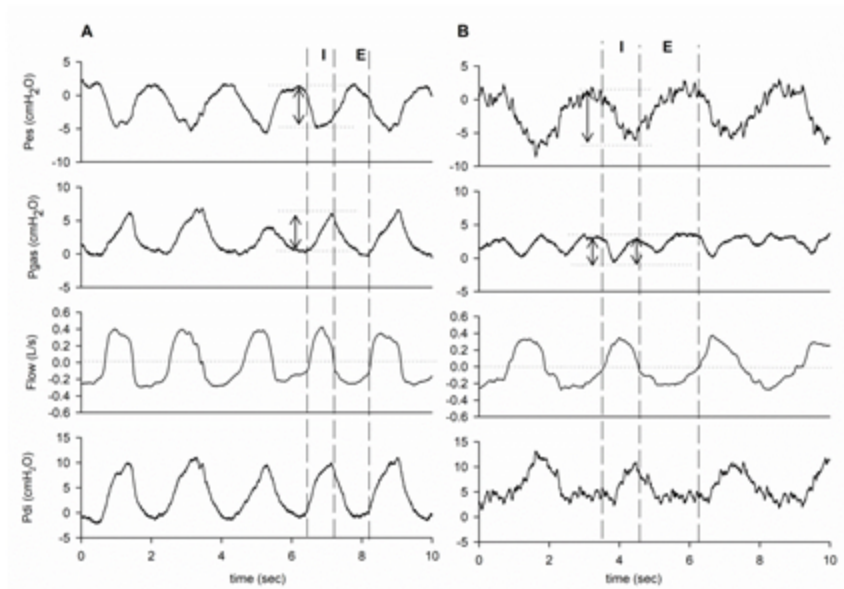
We thank the patients and their families for participating in this study.


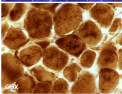
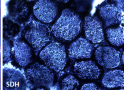
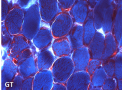
## References

- [1] Caggiano S, Khirani S, Dabaj I, Cavassa E, Amaddeo A, Arroyo JO, et al. Diaphragmatic dysfunction in SEPN1-related myopathy. *Neuromuscul Disord* 2017;27:747–55.
- [2] Quijano-Roy S, Khirani S, Colella M, Ramirez A, Aloui S, Wehbi S, et al. Diaphragmatic dysfunction in Collagen VI myopathies. *Neuromuscul Disord* 2014;24:125–33.
- [3] Fauroux B, Amaddeo A, Quijano-Roy S, Barnerias C, Desguerre I, Khirani S. Respiratory insight to congenital muscular dystrophies and congenital myopathies and its relation to clinical trial. *Neuromuscul Disord* 2018;28:731–40.
- [4] Munnich A, Rotig A, Chretien D, Saudubray JM, Cormier V, Rustin P. Clinical presentations and laboratory investigations in respiratory chain deficiency. *Eur J Pediatr* 1996;155:262–74.
- [5] Dominguez-Gonzalez C, Hernandez-Lain A, Rivas E, Hernandez-Voth A, Sayas Catalan J, Fernandez-Torron R, et al. Late-onset thymidine kinase 2 deficiency: a review of 18 cases. *Orphanet J Rare Dis* 2019;14:100.
- [6] Koo P, Sethi JM. Metabolic myopathies and the respiratory system. *Clin Chest Med* 2018;39:401–10.
- [7] Garone C, Taylor RW, Nascimento A, Poulton J, Fratter C, Dominguez-Gonzalez C, et al. Retrospective natural history of thymidine kinase 2 deficiency. *J Med Genet* 2018;55:515–21.
- [8] Sommerville EW, Ng YS, Alston CL, Dallabona C, Gilberti M, He L, et al. Clinical features, molecular heterogeneity, and prognostic implications in YARS2-related mitochondrial myopathy. *JAMA Neurol* 2017;74:686–94.
- [9] Finsterer J, Rauschka H, Segal L, Kovacs GG, Rolinski B. Affection of the respiratory muscles in combined complex I and IV deficiency. *Open Neurol J* 2017;11:1–6.
- [10] Catteruccia M, Sauchelli D, Della Marca G, Primiano G, Cuccagna C, Bernardo D, et al. "Myo-cardiomyopathy" is commonly associated with the A8344G "MERRF" mutation. *J Neurol* 2015;262:701–10.
- [11] Blakely EL, Alston CL, Lecky B, Chakrabarti B, Falkous G, Turnbull DM, et al. Distal weakness with respiratory insufficiency caused by the m.8344A > G "MERRF" mutation. *Neuromuscul Disord* 2014;24:533–6.

- [12] Osanai S, Takahashi T, Enomoto H, Satoh N, Yahara O, Akiba Y, et al. Hypoxic ventilatory depression in a patient with mitochondrial myopathy, encephalopathy, lactic acidosis and stroke-like episodes. *Respirology* 2001;6:163–6.
- [13] Rustin P, Chretien D, Bourgeron T, Gerard B, Rotig A, Saudubray JM, et al. Biochemical and molecular investigations in respiratory chain deficiencies. *Clin Chim Acta* 1994;228:35–51.
- [14] Li H, Handsaker B, Wysoker A, Fennell T, Ruan J, Homer N, et al. The Sequence Alignment/Map format and SAMtools. *Bioinformatics* 2009;25:2078–9.
- [15] McKenna A, Hanna M, Banks E, Sivachenko A, Cibulskis K, Kernytzky A, et al. The Genome Analysis Toolkit: a MapReduce framework for analyzing next-generation DNA sequencing data. *Genome Res* 2010;20:1297–303.
- [16] Ruiz-Pesini E, Lott MT, Procaccio V, Poole JC, Brandon MC, Mishmar D, et al. An enhanced MITOMAP with a global mtDNA mutational phylogeny. *Nucleic Acids Res* 2007;35:D823–8.
- [17] Chanprasert S, Wang J, Weng SW, Enns GM, Boue DR, Wong BL, et al. Molecular and clinical characterization of the myopathic form of mitochondrial DNA depletion syndrome caused by mutations in the thymidine kinase (TK2) gene. *Mol Genet Metab* 2013;110:153–61.
- [18] Poulton J, Hirano M, Spinazzola A, Arenas Hernandez M, Jardel C, Lombes A, et al. Collated mutations in mitochondrial DNA (mtDNA) depletion syndrome (excluding the mitochondrial gamma polymerase, POLG1). *Biochim Biophys Acta* 2009;1792:1109–12.
- [19] Blakely EL, Mitchell AL, Fisher N, Meunier B, Nijtmans LG, Schaefer AM, et al. A mitochondrial cytochrome b mutation causing severe respiratory chain enzyme deficiency in humans and yeast. *FEBS J* 2005;272:3583–92.
- [20] Andreu AL, Hanna MG, Reichmann H, Bruno C, Penn AS, Tanji K, et al. Exercise intolerance due to mutations in the cytochrome b gene of mitochondrial DNA. *N Engl J Med* 1999;341:1037–44.
- [21] Valente L, Piga D, Lamantea E, Carrara F, Uziel G, Cudia P, et al. Identification of novel mutations in five patients with mitochondrial encephalomyopathy. *Biochim Biophys Acta* 2009;1787:491–501.

- [22] Valnot I, Kassis J, Chretien D, de Lonlay P, Parfait B, Munnich A, et al. A mitochondrial cytochrome b mutation but no mutations of nuclearly encoded subunits in ubiquinol cytochrome c reductase (complex III) deficiency. *Hum Genet* 1999;104:460–6.
- [23] Schuelke M, Krude H, Finckh B, Mayatepek E, Janssen A, Schmelz M, et al. Septo-optic dysplasia associated with a new mitochondrial cytochrome b mutation. *Ann Neurol* 2002;51:388–92.
- [24] Wibrand F, Ravn K, Schwartz M, Rosenberg T, Horn N, Vissing J. Multisystem disorder associated with a missense mutation in the mitochondrial cytochrome b gene. *Ann Neurol* 2001;50:540–3.







**Table 1. Breathing pattern and respiratory muscle function in patients**

	Normal values (cmH <sub>2</sub> O)	Patient #1 7 years	Patient #2 8 years	Patient #2 10 years	Patient #3 12 years	Patient #3 14 years
Paradoxical breathing	no	permanent	no	no	intermittent	intermittent
<i>Sniff</i>						
Oesophageal pressure (cmH <sub>2</sub> O)	< -70	-42	-43	-34	-49	-32
Gastric pressure (cmH <sub>2</sub> O)	> +40	-6	-8	-8	-2.5	-9
Transdiaphragmatic pressure (cmH <sub>2</sub> O)	> +120	+36	+45	+30	+49	+22
<i>Cough</i>						
Gastric pressure (cmH <sub>2</sub> O)	> +120	+54	+28	+35	+45	+27