



HAL
open science

Fetal sheep cerebral electrical activity: A new technique to record EEG

Laure Lacan, Yasmine Hamoud, Sylvie Nguyen, Julien de Jonckheere, Laurent Storme, Véronique Houfflin-Debargé, Stéphane Auvin, Dyuti Sharma, Charles Garabedian, Louise Ghesquière

► To cite this version:

Laure Lacan, Yasmine Hamoud, Sylvie Nguyen, Julien de Jonckheere, Laurent Storme, et al.. Fetal sheep cerebral electrical activity: A new technique to record EEG. *Journal of Neuroscience Methods*, 2020, 345, pp.108888 -. 10.1016/j.jneumeth.2020.108888 . hal-03492077

HAL Id: hal-03492077

<https://hal.science/hal-03492077>

Submitted on 22 Aug 2022

HAL is a multi-disciplinary open access archive for the deposit and dissemination of scientific research documents, whether they are published or not. The documents may come from teaching and research institutions in France or abroad, or from public or private research centers.

L'archive ouverte pluridisciplinaire **HAL**, est destinée au dépôt et à la diffusion de documents scientifiques de niveau recherche, publiés ou non, émanant des établissements d'enseignement et de recherche français ou étrangers, des laboratoires publics ou privés.



Distributed under a Creative Commons Attribution - NonCommercial 4.0 International License

Fetal sheep cerebral electrical activity: a new technique to record EEG

Laure Lacan^{1,3}, Yasmine Hamoud^{1,2}, Sylvie Nguyen^{1,3}, Julien De Jonckheere^{1,4},
Laurent Storme^{1,5}, Véronique Houfflin-Debarge^{1,2}, Stéphane Auvin⁷, Dyuti Sharma^{1,6},
Charles Garabedian^{1,2}, Louise Ghesquière^{1,2}

¹ Univ. Lille, CHU Lille, ULR 2694 - METRICS, F-59000 Lille, France

² CHU Lille, Department of Obstetrics, F-59000 Lille, France

³ CHU Lille, Department of Pediatric Neurology, F-59000 Lille, France

⁴ CHU Lille, CIC-IT 1403, F-59000 Lille, France

⁵ CHU Lille, Department of Neonatology, F-59000 Lille, France

⁶ CHU Lille, Department of Pediatric Surgery, F-59000 Lille, France

⁷ APHP, Hôpital Robert Debré, Department of Pediatric Neurology, F-75019 Paris, France

Declarations of interest: none.

Highlights:

- Description of a new method for *in utero* fetal sheep EEG recording.
- The EEG technique is simpler and less invasive than the standard technique
- Fetal EEG had reliable visual and quantitative characteristics compared to ECOG
- *In utero* EEG recording can be used to study cerebral response to perinatal anoxia

Corresponding Author:

Laure LACAN

CHU Lille, Hôpital Roger Salengro, Department of Pediatric Neurology

Avenue du Professeur Emile Laine,

59037 Lille Cedex, France

laurelacan@yahoo.fr

Abstract

Background: Sheep models are commonly used to study fetal cortical activity, including response to hypoxia. The standard technique consists of recording electrocorticogram (ECOG) *in utero* using electrodes placed on the dura mater.

New Method: We propose a new method for recording the electroencephalogram (EEG) of fetal sheep, using electrodes placed above the skull bone and fixed to the cranial periosteum.

Results: Twelve animals were instrumented with this new technique. The EEG signal recorded *in utero* was of sufficient quality for visual and quantitative analysis of the fetal cortical activity.

Comparison with Existing Method: This new method is less invasive than the standard method commonly used to record cerebral activity in fetal sheep, because it avoids drilling the skull by hand. The EEG signal recorded *in utero* had visual and quantitative characteristics comparable to ECOG.

Conclusions: We present a new method of EEG recording that appears to be an acceptable alternative to the standard ECOG recording method. Fetal sheep EEG can be used to better understand the physiological mechanisms involved in the cerebral response to hypoxia.

Key words: EEG technique; fetal sheep; perinatal hypoxia

Abbreviations

CFM	Cerebral Function Monitor
ECG	Electrocardiogram
ECOG	Electrocorticogram
EEG	Electroencephalogram
FSI	Fetal Stress Index
HIE	Hypoxic-ischemic encephalopathy
HRV	Heart Rate Variability
Max Amp	Maximal Amplitude Index
Min Amp	Minimal Amplitude Index
95% SEF	Spectral Edge Frequency 95%
UCO	Umbilical Cord Occlusion

1. Introduction:

First recordings of *in utero* fetal sheep cortical activity were reported in the early 1970s (1–4). Brain maturation in the fetal sheep is faster than fetal human brain but follows the same model with comparable patterns of electrocortical activity (5–8). Access to cerebral activity *in utero* is of particular interest for studying the normal evolution of fetal electrocortical activity during gestation or the response to events such as perinatal anoxia. Since then, the standard technique is the recording of an electrocorticogram (ECOG) using electrodes placed directly on the dura mater of the fetal sheep (9–11): after a laparotomy with exposure of the fetal head, a midline scalp incision is made, the periosteum is removed from the calvarium and stainless steel electrodes screws are inserted through burr-holes into the bone, their ends rested on the dura mater. A mold is formed from dental acrylic cement over the electrodes providing both mechanical stability and insulation from the scalp and the amniotic fluid. However, this technique requires drilling the skull by hand for electrode placement, which is quite invasive and can, in our experience, result in complications such as extradural hematomas and even fetal loss.

We propose herewith a new technique of *in utero* electroencephalogram (EEG) recording using electrodes fixed above the cranial bone, which avoids drilling burr-holes.

2. Methods:

2.1. Ethics

The anesthesia, surgery and experimental protocols followed the recommendations of the National Institutes of Health guide for the care and use of Laboratory animals (NIH Publications No. 8023, revised 1978) and the ARRIVE guidelines. The study was approved by the local Animal Experimentation Ethics Committee (Approval No. 2016121312148878).

2.2. Surgical procedure

Pregnant ewes (breed 'Ile de France', coming from Tours'INRA, Orfrasière animal physiology experimental Unit, Val de Loire Center) were housed at least 7 days prior to intervention in metabolic cages with unlimited access to water, hay and a 400g portion of granules was administered twice a day. A 24-hour fast was imposed before the operation. Near term fetal sheep (124+/-1 days gestational age, term: 145 days) were surgically instrumented to record cortical activity *in utero*, during and after hypoxic insults.

Surgery was performed under general anesthesia: premedication with Xylazine 0.3 ml/kg (Sedaxylan® 20mg/ml, Dechra, Netherlands), ventilation with halogen gas before intubation and mechanical ventilation, sedation maintained by inhaled Isoflurane during the operation (Isoflurane, Aerrane®, Baxter, Maurepas, France). Maternal analgesia was provided by an intramuscular injection of Buprenorphine 0.6ml/10kg (Bupaq®, Virbac, France) at the beginning of the operation. Intramuscular antibiotic prophylaxis of 1mL/10kg Amoxicillin (Clamoxyl LA® 150mg/ml, Zoetis, France) was administered intra-operatively to the mother.

We followed our usual protocol (12–15): the right anterior forelimb of the fetus was delivered through maternal midline laparotomy and hysterotomy under surgical asepsis conditions. Axilla skin incision was made after local anesthesia, provided by subcutaneous injection of 1mL lidocaine hydrochloride 10mg/mL (Xylocaine® Astrazeneca, Reuil-malmaison, France), combined with fetal analgesia by intramuscular injection of 0.3 mL Buprenorphine (Bupaq®, Virbac, France). 4Fr diameter catheter (Arrow, USA) was inserted into the right axillary artery until reaching the fetal aorta for hemodynamic parameters recording and fetal blood sampling. The same procedure was repeated on the left. Four precordial electrodes (MYWIRE 10, MAQUET, Germany) were placed in axillary intercostal muscles for ECG signal recording.

An occluder (OC VO-16HD - DOCXS Biomedical Products - Ukiah, California) was placed around the umbilical cord of the fetus to induce cord compression by injection of saline.

For EEG electrodes placement, the fetal head was exposed through the hysterotomy. Two pairs of pre-prepared needle electrodes (MYWIRE 10, MAQUET, Germany Figure 2B) were set up on both sides over the frontal and parietal cortex, 10 mm lateral to the sagittal suture, and about 5 mm anterior and 10 mm posterior respectively to the fronto-parietal suture (Figure 1). A reference electrode and a ground electrode were placed over the occiput. Skin incision of 5 mm was made for each electrode, ensuring good control of hemostasis at the level of the scalp. The electrode was placed so that the bared portion was under the periosteum, in contact with the bone thus completely isolated from amniotic fluid (Figure 2). The scalp was then sutured, the electrode was tied around the suture and fixed.

Placental circulation was maintained intact and the fetus was placed back into the uterus. An additional 5Fr diameter catheter (Arrow, USA) was placed into the amniotic

cavity for measuring baseline pressure. Uterus and abdominal wall were closed after instillation of 500 mg of amoxicillin-clavulanic acid (Amoxicillin-clavulanic acid SANDOZ®, Sandoz, Levallois-Perret, France) into the amniotic fluid. The occluder, EEG and ECG wires, fetal and intra-amniotic catheters connected to extenders, were externalized on the right lateral flank of the sheep by subcutaneous tunneling.

After the operation, the sheep were allowed to eat and drink. The permeability of the fetal catheters was maintained by daily injection of 10 IU/mL isotonic heparinized saline (Heparin CHOAY®5000UI, Sanofi-aventis France, Paris). Postoperative analgesia was provided by a maternal intramuscular injection of 0.3mL/10kg Buprenorphine (Bupaq®, Virbac, France) 24 and 48 hours postoperatively.

2.3. Experimental procedure

After three days of post-operative rest, animals were subjected to a labor-like acidosis using repetitive umbilical cord occlusion (UCO) with increasing severity as described by Prout and al (16). Total UCO was induced by injecting an isotonic solution into the occluder (the required volume was calculated during surgery). After a one-hour stability control period, three phases of successively mild, moderate and severe repetitive UCOs were performed for one hour each. One-minute UCOs were repeated every 5 minutes during the phase A (mild UCOs), every 3 minutes during the phase B (moderate UCOs) and every 2 minutes during the phase C (severe UCOs). The protocol was interrupted if the arterial pH obtained reached 6.90 or less.

After the occlusion phases, fetuses were monitored continuously for a 6-hour recuperation phase and were allowed to recover for 48 hours. After the experiment, animals were sacrificed by an intravenous injection of a veterinary anesthetic: 6ml/50kg of

T61® (Embutramide 20g, Mebezonium iodide 5g, Tetracaine hydrochloride 0.5g, Dimethylformamide 60ml).

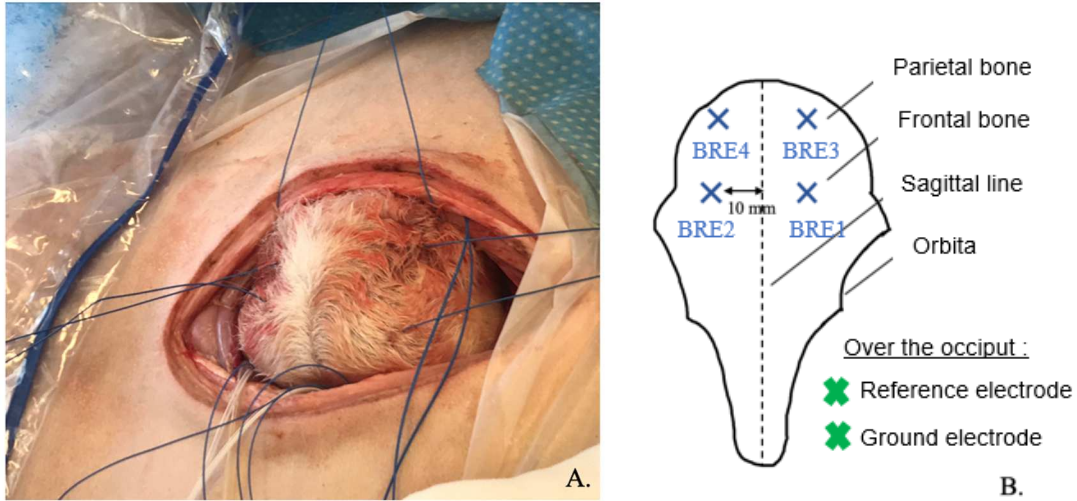


Fig. 1 – Electrode placement on the head of the fetal lamb

- A. Fetal head exposed through the hysterotomy during the surgical procedure (anterior up, posterior down on this picture)
- B. Front view of a fetal sheep skull. Placement of EEG electrodes.

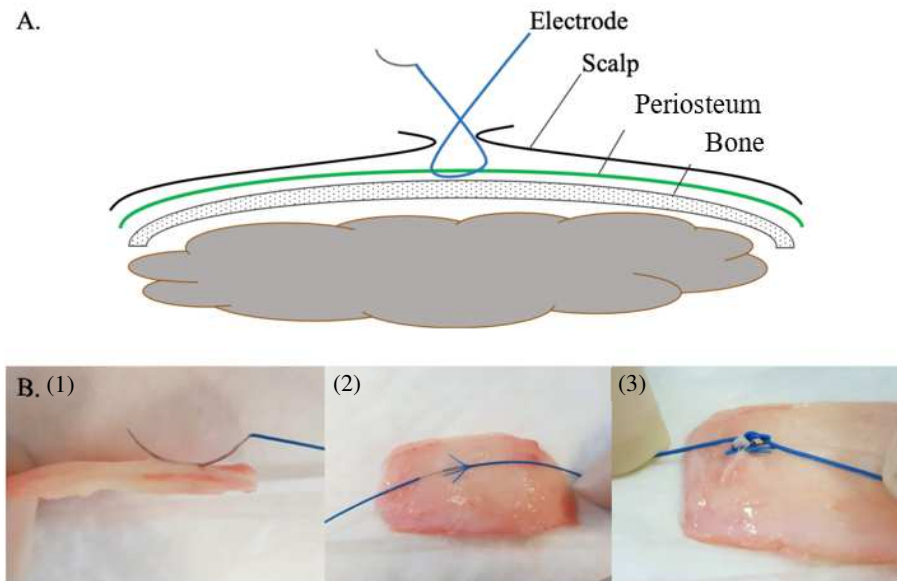


Fig. 2 – Positioning of the EEG electrodes

A. Pattern of pose

B. Step by step illustration of the technique on post-mortem fetal sheep skull.

The needle electrode is placed underneath the periosteum (1) so that the barred portion of the wire is directly in contact with the bone (2), then tied with a knot (3).

2.4. EEG recording and data analysis

EEG was continuously recorded during the one-hour stability phase, the occlusion phase, up to 6 hours (H6) post-occlusion during the recovery phase and one hour at 24 hours (H24) and 48 hours (H48). The four channels (BRE1, 2, 3, 4) were monopolar recorded against a reference electrode using Micromed EEG System®. The signal was filtered with high-pass and low-pass filters at 0.5 and 70 Hz respectively and digitalized at a sampling rate of 256 Hz.

Recordings were analysed offline on the System Plus Evolution Software® unit (Micromed SAS, Macon, France) at specific time points. Each record was visually analysed by a neurophysiologist using a bipolar montage. Quantitative analysis was performed using the program “EEG Analyser” (Micromed®) and the EEG parameters were calculated every two seconds over the analysed periods. The amplitude was measured by the minimal and maximal Amplitude Index (min and max Amp), defined as the minimal and maximal peak of amplitude (μV), measured using CFM after filtering the signal at 2–20 Hz. The Spectral Edge Frequency was defined as the frequency (Hz) below which 95% of the power in EEG exists (95% SEF).

3. Results:

Twelve animals were instrumented with the EEG technique. Two manipulations were unsuccessful (rupture of the umbilical cord occluder and a fetal death during the protocol). The time required to fix the electrodes was not measured precisely for all manipulations but estimated at about 5 minutes per electrode, i.e. a total of 15 to 30 minutes' maximum for 6 electrodes depending on the number of operators (1 or 2).

The recorded EEG signal was of sufficient quality for visual and quantitative analysis. The signal artefacts were intermittent and consisted mainly of large waves related to movements of the ewe or the fetal lamb but did not interfere with the EEG visual analysis (Figure 3).

Considering the qualitative visual analysis, the EEG signal was continuous and labile in stability phase. Two kinds of electrical activities could be visually distinguished: high-voltage slow activity and low-voltage fast activity (Figure 4A and B). Concurrently with UCOs, we could visually observe a decrease in the signal amplitude, frequently followed by large amplitude artefacts (Figure 4C). At the beginning of the recovery phase, the signal amplitude was generally depressed with slower frequencies. During the six hours of recovering, we observed a progressive enrichment of the signal with reappearance of the lability. Spikes and periods of rhythmic activity were observed in some tracings during this phase, which could correspond to seizures (Figure 4D). After the maternal sacrifice, the amplitude of the EEG signal was decreasing to an inactive tracing in less than 20 minutes (7.50 min in average \pm 5.32 [1.2-19.0]) (Figure 4E).

The EEG quantitative measures are presented in Table 1 and Figure 5 but are not subject to statistical analysis as this is not the objective of this paper.

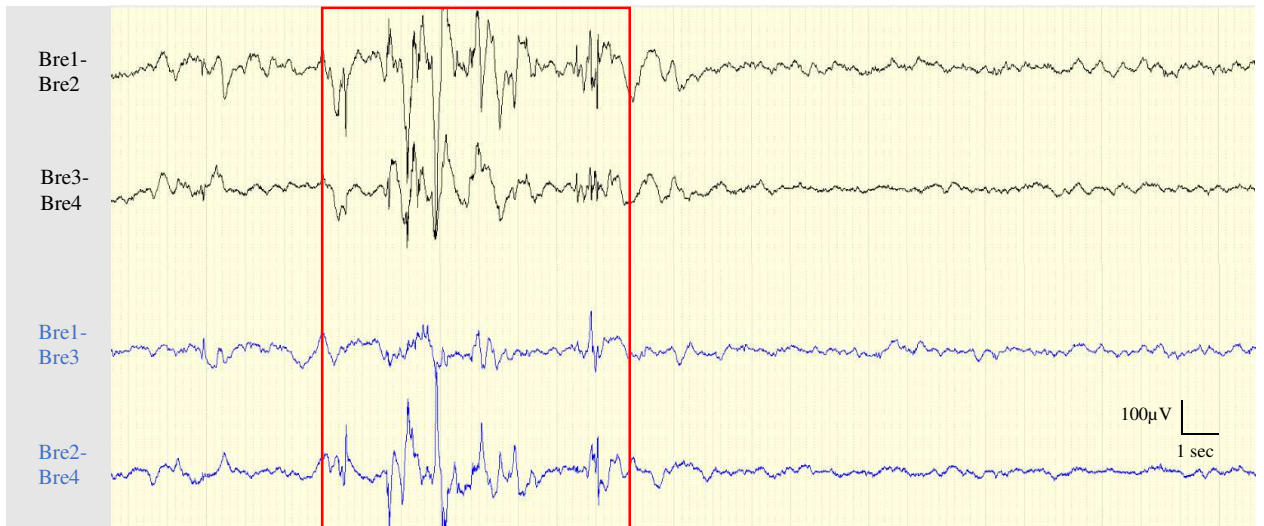


Fig. 3 – Example of EEG tracing with signal artefact

Transverse (black) and longitudinal (blue) bipolar montage with Bre1 to 4 corresponding to the EEG electrodes shown in Figure 1B).

The artefact (framed in red) was recorded during the stability period and was concomitant with ewe movements. It is representative of intermittent artefacts we usually recorded with a large amplitude averaging 250 µV here and a slow frequency (peak frequency at 1 Hz).

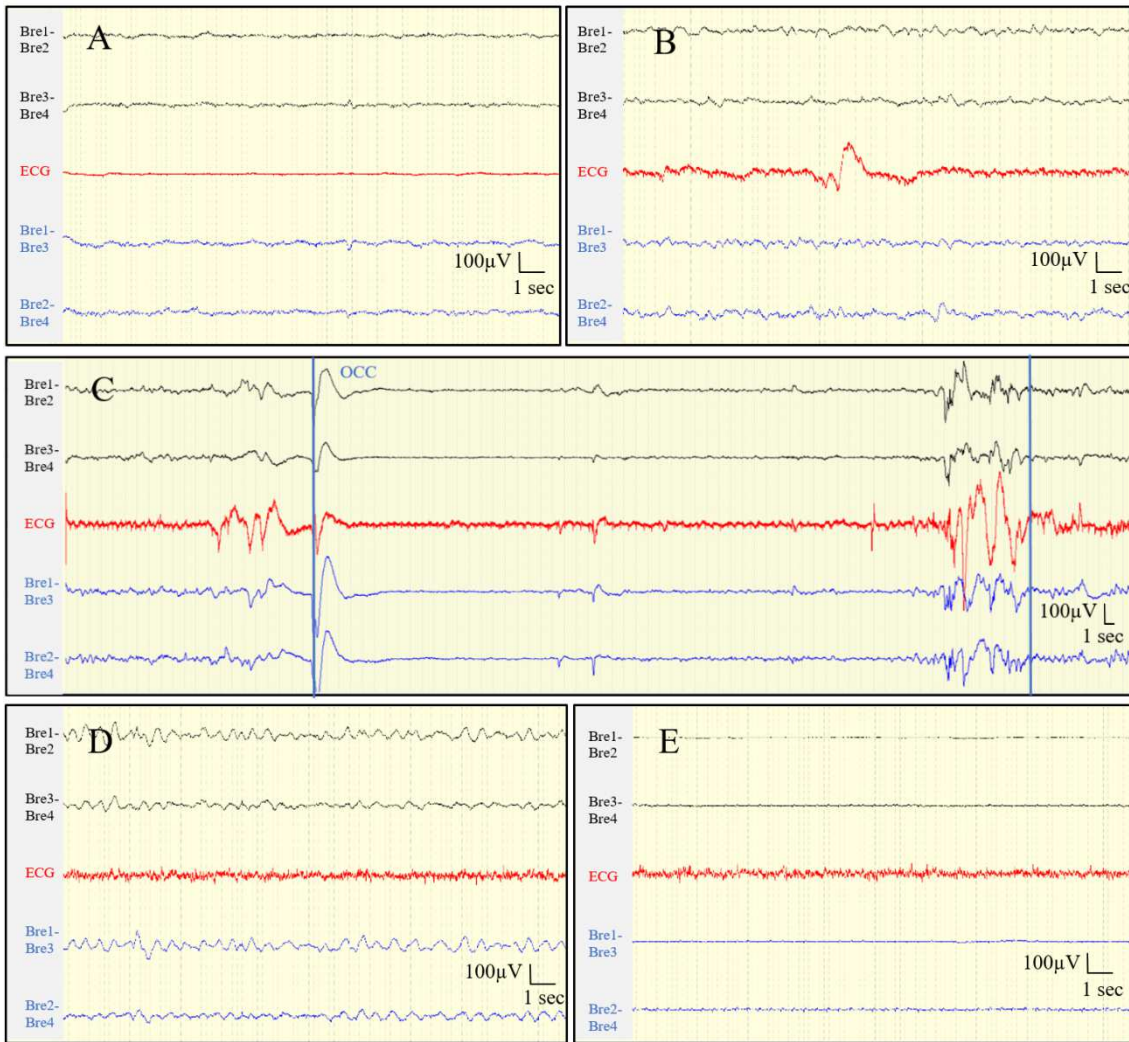


Fig. 4 – Examples of EEG tracings at the different phases of the protocol

Transverse (black) and longitudinal (blue) bipolar montage with Bre1 to 4 corresponding to the EEG electrodes shown in Figure 1B). ECG in red.

- A. Stability phase (20 sec epoch): low-voltage fast activity with maximum signal amplitude around 20 μ V, frequency 10-13 Hz.
- B. Stability phase (20 sec epoch): high voltage slow activity with maximum signal amplitude around 60 μ V, frequency 2-5 Hz.
- C. Moderate umbilical cord occlusion (1 minute of occlusion every 3 minutes; the beginning and the end of the occlusion (occ) are marked by the blue bars): diminution of the signal amplitude; artefacts at the beginning and the end of the umbilical cord occlusion (90 sec epoch).
- D. Recovery phase / H2 post-occlusions (20 sec epoch): rhythmic activity, recorded on all derivations.
- E. Inactive tracing (20 sec epoch): 7 minutes after the maternal sacrifice.

Table 1 – Fetal EEG measurements

	Baseline	Mild UCO		Moderate UCO		Severe UCO	
		Phase	Per-UCO	Phase	Per-UCO	Phase	Per-UCO
Min Amp (μV)	3.5 ± 1.6	2.7 ± 1.4	3.4 ± 2.8	2.0 ± 1.2	4.2 ± 10.3	1.7 ± 1.3	1.4 ± 1.6
Max Amp (μV)	79 ± 17	78 ± 16	76 ± 20	78 ± 15	77 ± 20	80 ± 12	76 ± 21
95% SEF (Hz)	8.7 ± 3.8	7.6 ± 2.8	7.9 ± 3.3	7.2 ± 3.0	7.5 ± 3.6	6.3 ± 2.1	6.0 ± 2.8

Values are means \pm standard error. $N=10$. UCO = umbilical cord occlusion; Min Amp = minimal amplitude; Max Amp = maximal amplitude; 95% SEF = 95% Spectral Edge Frequency.

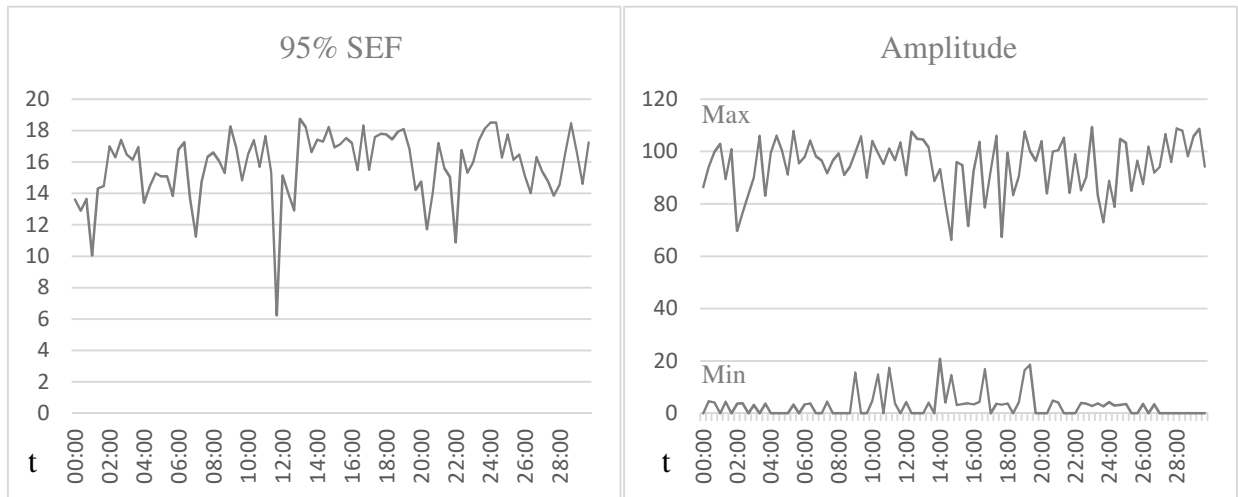


Fig. 5 – Example of quantitative EEG measurements in stability phase

95% SEF = Spectral Edge Frequency 95% (Hz); Max = maximal amplitude over 20 sec (μV); Min = minimal amplitude over 20 sec (μV); t = time (mm:ss)

4. Discussion:

Fetal sheep preparation requires substantial cost and infrastructure thus models have to be reproducible with low mortality and morbidity rates in order to reduce the number of animals needed (18). We propose an *in utero* EEG recording technique in the fetal sheep that avoids drilling the skull by hand for electrode placement. This allows a quite simple and less invasive procedure. The learning curve of this technique is short, making it easy and quick to implement in a team which does not include neurosurgeons.

The EEG signal recorded using this technique appears to be of sufficient quality for visual and quantitative analysis of fetal sheep cortical activity. Recording the signal using electrodes placed above the skull bone is likely to produce more signal artefacts than when the electrodes are fixed in the bone. Nevertheless, the recorded artefacts were intermittent and easily visually detectable, which did not interfere with the signal visual analysis.

When comparing to the raw ECOG tracings presented in previous studies (Figure 6), the obtained EEG signal was continuous and labile in stability phase, as described at this gestational age in the fetal lamb (1,3,5,19). Visually, it was possible to distinguish the two types of activity described the literature as associated with the sleep-wake stages in the fetal lamb (3–5,20–23) but to be certain, further analysis with recording of eye movements, EMG and respiration movements during these activities would be required, which could be the subject of future studies.

Our quantitative EEG measures in stability phase were comparable with ECOG data at the same gestational age in previous studies (10,24–26). The EEG signal amplitude appeared to be somewhat lower, which was expected since the cortical activity is recorded above the bone. Experimental data obtained during the occlusion phases were not compared with previous studies as the occlusion protocols differ between studies.

To our knowledge only one team succeeded in recording fetal sheep brain activity without drilling holes in the skull, using a modified double spiral fetal heart rate electrode placed directly on the scalp (27). Their findings confirm that ECOG activity acquired from supra-dural electrodes and EEG activity acquired from scalp electrodes are similar despite a reduced amplitude and more technical artefacts in the latter. Our technique using periosteum to secure EEG electrodes seems to be a good compromise between a more invasive technique and a more artefacted signal. Although, the scalp receives a rich blood supply and the placement of electrodes requires great hemostasis, as the occurrence of subcutaneous hematoma can attenuate the signal.

This study therefore proposes the EEG technique as an acceptable alternative to ECOG. However, the comparison with the standard technique is limited because we did not record ECOG tracings at the same time and the duration of the procedure was not measured exactly.

In utero recording of fetal cortical activity is of particular interest to study the physiological mechanisms involved in the cerebral response to perinatal hypoxia and predict hypoxic-ischemic encephalopathy (HIE). Indeed, an estimated 30% of cases of neonatal encephalopathy in developed countries are still associated with evidence of intrapartum hypoxic-ischemia (28) and HIE is responsible for significant neonatal mortality and morbidity (29–31). However, reliable biomarkers of perinatal asphyxia are still missing : fetal heart rate monitoring during labor is commonly used to evaluate the fetal well-being but lack at predicting HIE (32). Severe fetal metabolic acidosis during labor, measured by scalp or cord pH and lactate, is one of the most sensitive signs of fetal anoxia. Arterial pH below 7.00 at birth is associated with abnormal outcome but the positive predictive value for HIE is low (33). Lactate has also been shown to be a poor

predictor of perinatal brain injury (34). As early post-natal EEG is known to be highly predictive of clinical prognosis (35), the identification of relevant prenatal EEG markers in the fetal lamb could potentially be used in humans to predict the onset of HIE, e.g. through the use of per partum scalp electrodes, which however is not yet available in clinical practice.

Furthermore, our team has recently developed a new index of fetal surveillance during labor (Fetal Stress Index, FSI), using an original method of Heart Rate Variability (HRV) analysis. Previous experimental studies showed that FSI was specific for the parasympathetic tone and correlated to pH and lactate in labour-like acidosis models (12–14). Frasch et al. showed a synchronization of cardiac and cerebral activity prior to the onset of severe acidosis in fetal sheep (27), it could be therefore interesting to correlate FSI with cerebral activity markers.

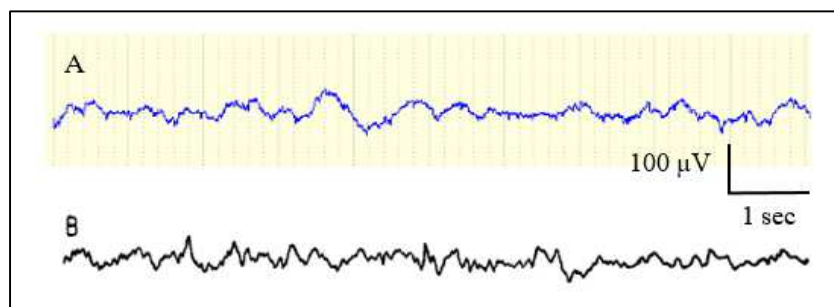


Fig. 6 – Comparison of tracings: EEG technique vs ECOG technique

A. Example of EEG tracing recorded *in utero* in a fetal sheep using the EEG technique (gestational age 128 days, stability phase).

B. ECOG tracing presented in “EEG, ECG, and acid-base observations during acute fetal hypoxia”, Mann 1970 (gestational age 130 days, stability phase) (1)

5. Conclusion

We propose a method of *in utero* EEG recording in the fetal sheep using electrodes fixed above the cranial bone. This method is less invasive and the recorded EEG signal is of sufficient quality with visual and quantitative characteristics comparable to ECOG. This appears to be an acceptable alternative to the standard ECOG recording method and can be used for future studies.

6. Acknowledgements

We thank Capucine Besengez, Thomas Hubert and all the staff of the Research Experimental Department of University Lille for their veterinary care and their expert assistance with sheep surgery.

Declarations of interest: none.

7. References

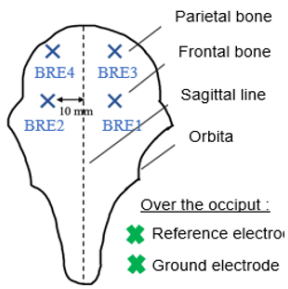
1. Mann LI, Prichard JW, Symmes D. EEG, ECG, and acid-base observations during acute fetal hypoxia. *Am J Obstet Gynecol.* 1970 Jan 1;106(1):39–51.
2. Symmes D, Prichard JW, Mann LI. Spectral analysis of fetal sheep EEG during hypoxia. *Electroencephalogr Clin Neurophysiol.* 1970 Nov;29(5):511–5.
3. Ruckebusch Y. Development of sleep and wakefulness in the foetal lamb. *Electroencephalogr Clin Neurophysiol.* 1972 Feb 1;32(2):119–28.
4. Dawes GS, Fox HE, Leduc BM, Liggins GC, Richards RT. Respiratory movements and rapid eye movement sleep in the foetal lamb. *J Physiol.* 1972 Jan;220(1):119–43.
5. Clewlow F, Dawes GS, Johnston BM, Walker DW. Changes in breathing, electrocortical and muscle activity in unanaesthetized fetal lambs with age. *J Physiol.* 1983 Aug;341:463–76.
6. McINTOSH GH, Baghurst KI, Potter BJ, Hetzel BS. Foetal Brain Development in the Sheep. *Neuropathol Appl Neurobiol.* 1979;5(2):103–14.
7. Bernhard CG, Kaiser IH, Kolmodin GM. On the development of cortical activity in fetal sheep. *Acta Physiol Scand.* 1959 Dec 12;47:333–49.
8. Jones MD. Energy metabolism in the developing brain. *Semin Perinatol.* 1979 Apr;3(2):121–9.
9. Abbasi H, Bennet L, Gunn AJ, Unsworth CP. Robust Wavelet Stabilized “Footprints of Uncertainty” for Fuzzy System Classifiers to Automatically Detect Sharp Waves in the EEG after Hypoxia Ischemia. *Int J Neural Syst.* 2017 May;27(3):1650051.
10. Frasch MG, Durosier LD, Gold N, Cao M, Matuszewski B, Keenlside L, et al. Adaptive shut-down of EEG activity predicts critical acidemia in the near-term ovine fetus. *Physiol Rep.* 2015 Jul;3(7).
11. Yamaguchi K, Lear CA, Beacom MJ, Ikeda T, Gunn AJ, Bennet L. Evolving changes in fetal heart rate variability and brain injury after hypoxia-ischaemia in preterm fetal sheep. *J Physiol.* 2018;596(23):6093–104.
12. Garabedian C, Champion C, Servan-Schreiber E, Butruille L, Aubry E, Sharma D, et al. A new analysis of heart rate variability in the assessment of fetal parasympathetic activity: An experimental study in a fetal sheep model. *PLOS ONE.* 2017 Jul;12(7):e0180653.
13. Garabedian C, Clermont-Hama Y, Sharma D, Aubry E, Butruille L, Deruelle P, et al. Correlation of a new index reflecting the fluctuation of parasympathetic tone and fetal acidosis in an experimental study in a sheep model. *PLOS ONE.* 2018 Jan 10;13(1):e0190463.

14. Ghesquière L, De Jonckheere J, Drumez E, Sharma D, Aubry E, Deruelle P, et al. Parasympathetic nervous system response to acidosis: evaluation in an experimental fetal sheep model. *Acta Obstet Gynecol Scand*. 2018 Dec 19;
15. Garabedian C, Aubry E, Sharma D, Bleu G, Clermont-Hama Y, Ghesquière L, et al. Exploring fetal response to acidosis in ewes: Choosing an adequate experimental model. *J Gynecol Obstet Hum Reprod [Internet]*. 2018 Apr 11; Available from: <http://www.sciencedirect.com/science/article/pii/S2468784718300576>
16. Prout AP, Frasc MG, Veldhuizen RAW, Hammond R, Ross MG, Richardson BS. Systemic and cerebral inflammatory response to umbilical cord occlusions with worsening acidosis in the ovine fetus. *Am J Obstet Gynecol*. 2010 Jan;202(1):e1-9.
17. Prout AP, Frasc MG, Veldhuizen RAW, Hammond R, Ross MG, Richardson BS. Systemic and cerebral inflammatory response to umbilical cord occlusions with worsening acidosis in the ovine fetus. *Am J Obstet Gynecol*. 2010 Jan;202(1):e1-9.
18. Back SA, Riddle A, Dean J, Hohimer AR. The Instrumented Fetal Sheep as a Model of Cerebral White Matter Injury in the Premature Infant. *Neurotherapeutics*. 2012 Apr;9(2):359–70.
19. Bernhard CG, Kolmodin GM, Meyerson BA. On the Prenatal Development of Function and Structure in the Somesthetic Cortex of the Sheep. In: Bernhard CG, Schadé JP, editors. *Progress in Brain Research [Internet]*. Elsevier; 1967 [cited 2020 Jan 26]. p. 60–77. (Developmental Neurology; vol. 26). Available from: <http://www.sciencedirect.com/science/article/pii/S0079612308614193>
20. Ioffe S, Jansen AH, Russell BJ, Chernick V. Sleep, wakefulness and the monosynaptic reflex in fetal and newborn lambs. *Pflugers Arch*. 1980 Nov;388(2):149–57.
21. Jost RG, Quilligan EJ, Yeh SY, Anderson GG. Intrauterine electroencephalogram of the sheep fetus. *Am J Obstet Gynecol*. 1972 Oct 15;114(4):535–9.
22. Mann LI, Duchin S, Weiss RR. Fetal EEG sleep stages and physiologic variability. *Am J Obstet Gynecol*. 1974 Jun 15;119(4):533–8.
23. Rao N, Keen A, Czikk M, Frasc M, Richardson BS. Behavioural state linkage in the ovine fetus near term. *Brain Res*. 2009 Jan 23;1250:149–56.
24. Lee SJ, Hatran DP, Tomimatsu T, Peña JP, McAuley G, Longo LD. Fetal cerebral blood flow, electrocorticographic activity, and oxygenation: responses to acute hypoxia. *J Physiol*. 2009;587(9):2033–47.
25. Frasc MG, Keen AE, Gagnon R, Ross MG, Richardson BS. Monitoring fetal electrocortical activity during labour for predicting worsening acidemia: a prospective study in the ovine fetus near term. *PloS One*. 2011;6(7):e22100.

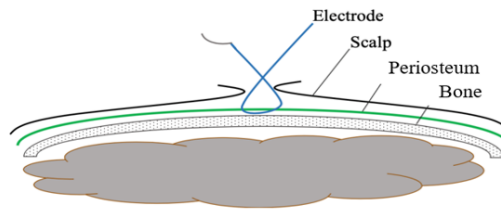
26. Keen AE, Frasch MG, Sheehan MA, Matuszewski BJ, Richardson BS. Electrocortical activity in the near-term ovine fetus: Automated analysis using amplitude frequency components. *Brain Res.* 2011 Jul 21;1402:30–7.
27. Frasch MG, Durosier LD, Gold N, Cao M, Matuszewski B, Keenliside L, et al. Adaptive shut-down of EEG activity predicts critical acidemia in the near-term ovine fetus. *Physiol Rep.* 2015 Jul;3(7).
28. Kurinczuk JJ, White-Koning M, Badawi N. Epidemiology of neonatal encephalopathy and hypoxic-ischaemic encephalopathy. *Early Hum Dev.* 2010 Jun;86(6):329–38.
29. Pin TW, Eldridge B, Galea MP. A review of developmental outcomes of term infants with post-asphyxia neonatal encephalopathy. *Eur J Paediatr Neurol* [Internet]. 2009 [cited 2020 Apr 17];13(3). Available from: /scholarlywork/316468-a-review-of-developmental-outcomes-of-term-infants-with-post-asphyxia-neonatal-encephalopathy
30. Volpe's Neurology of the Newborn - 6th Edition [Internet]. [cited 2020 Apr 17]. Available from: <https://www.elsevier.com/books/volpes-neurology-of-the-newborn/volpe/978-0-323-42876-7>
31. Lawn JE, Cousens S, Zupan J. 4 million neonatal deaths: When? Where? Why? *The Lancet.* 2005 Mar 5;365(9462):891–900.
32. Graham Em, Adami Rr, Mckenney Sl, Jennings Jm, Burd I, Witter FR. Diagnostic Accuracy of Fetal Heart Rate Monitoring in the Identification of Neonatal Encephalopathy. *Obstet Gynecol.* 2014 Sep;124(3):507–13.
33. Ruth VJ, Raivio KO. Perinatal brain damage: predictive value of metabolic acidosis and the Apgar score. *Br Med J.* 1988 Jul 2;297(6640):24–7.
34. East CE, Leader LR, Sheehan P, Henshall NE, Colditz PB, Lau R. Intrapartum fetal scalp lactate sampling for fetal assessment in the presence of a non-reassuring fetal heart rate trace. *Cochrane Database Syst Rev.* 2015 May 1;(5):CD006174.
35. Azzopardi D, TOBY study group. Predictive value of the amplitude integrated EEG in infants with hypoxic ischaemic encephalopathy: data from a randomised trial of therapeutic hypothermia. *Arch Dis Child Fetal Neonatal Ed.* 2014 Jan;99(1):F80-82.

Graphical Abstract

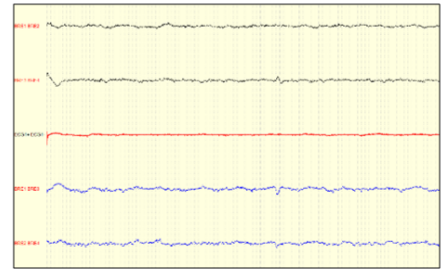
New technique for *in utero* EEG recording in fetal sheep



EEG electrodes placement



EEG electrodes fixation



EEG tracing