



HAL
open science

Indocyanine green in deep infiltrating endometriosis: a preliminary feasibility study to examine vascularization after rectal shaving

Nicolas Bourdel, Lucie Jaillet, Yochay Bar-Shavit, Aurélie Comptour, Bruno Pereira, Michel Canis, Pauline Chauvet

► To cite this version:

Nicolas Bourdel, Lucie Jaillet, Yochay Bar-Shavit, Aurélie Comptour, Bruno Pereira, et al.. Indocyanine green in deep infiltrating endometriosis: a preliminary feasibility study to examine vascularization after rectal shaving. *Fertility and Sterility*, 2020, 114, pp.367 - 373. 10.1016/j.fertnstert.2020.03.042 . hal-03492069

HAL Id: hal-03492069

<https://hal.science/hal-03492069>

Submitted on 22 Aug 2022

HAL is a multi-disciplinary open access archive for the deposit and dissemination of scientific research documents, whether they are published or not. The documents may come from teaching and research institutions in France or abroad, or from public or private research centers.

L'archive ouverte pluridisciplinaire **HAL**, est destinée au dépôt et à la diffusion de documents scientifiques de niveau recherche, publiés ou non, émanant des établissements d'enseignement et de recherche français ou étrangers, des laboratoires publics ou privés.



Distributed under a Creative Commons Attribution - NonCommercial 4.0 International License

1 **Title:** Indocyanine Green in Deep Infiltrating Endometriosis (INDIE): a preliminary feasibility
2 study to examine vascularization after rectal shaving

3 **Running title:** Indocyanine Green in Deep Endometriosis

4 Nicolas Bourdel ^{1,2*}, M.D, PhD; Lucie Jaillet ^{1,2}, M.D ; Yochay Bar-Shavit ³, M.D ; Aurélie
5 Comptour ¹, PhD; Bruno Pereira⁴, PhD; Michel Canis^{1,2}, M.D, PhD and Pauline Chauvet ^{1,2}
6 M.D, PhD

7
8 ¹ Department of Gynecological surgery. Clermont-Ferrand, France.

9 ² Faculty of Medecine, ALCoV UMR6284, CNRS/Université d'Auvergne, ISIT, Clermont-
10 Ferrand, France.

11 ³ Department of Obstetrics and Gynecology, Sheba Medical Center Tel Hashomer, Ramat
12 Gan, Israel; Sackler Faculty of Medicine, Tel Aviv University, Tel Aviv, Israel.

13 ⁴ University Hospital Clermont-Ferrand, Biostatistics Unit, Clermont-Ferrand, France.

14
15 ***Corresponding author: Nicolas Bourdel, nicolas.bourdel@gmail.com.**

16 Department of Gynecological surgery. Clermont-Ferrand, France.
17 **nicolas.bourdel@gmail.com. +0033473750679**

18
19
20
21
22
23

24 **Capsule:** Indocyanine Green fluorescent imaging is feasible in endometriosis surgery, and
25 may be considered a potential candidate to further enhance patient safety in endometriosis
26 bowel surgery.

27 **Abstract**

28 Objective: To evaluate the feasibility of using Indocyanine Green (ICG) to estimate the
29 vascularization of the resected zone during a laparoscopic rectal shaving.

30 Design: ICG can highlight blood vascularization when injected intravenously. Actually, there
31 is no relevant, objective, intraoperative method to assess the vascularity of the resected
32 zone during a laparoscopic rectal shaving for deep infiltrating endometriosis (DIE) to prevent
33 fistula. We conducted a registered clinical trial examining the feasibility of the use of ICG to
34 evaluate the bowel vascularization after endometriosis rectal shaving (Institutional Review
35 Board no 2016-002773-35).

36 Setting: Tertiary university hospital.

37 Patients: 21 patients underwent laparoscopic surgery for DIE with a rectal shaving.

38 Intervention(s): Patients undergoing laparoscopic surgery for DIE received ICG intravenously
39 at the end of endometriosis resection.

40 Main Outcome Measure(s): The main evaluation criteria was the fluorescence degree in the
41 operated rectal area, and in the vaginal suture. We used a visual assessment with a Likert-
42 type scale from 0 to 4 (0 = no fluorescence; 4 = very good fluorescence).

43 Results: No adverse reaction was recorded. Most of the patients (81%) showed very good
44 fluorescence levels at the rectal shaving area. The protocol did not increase the operating
45 time. In one patient we changed the surgical strategy making two stitches to bring the rectal

46 muscularis closer together, which improved the degree of fluorescence. There was no case
47 of digestive fistula.

48 Conclusion: ICG fluorescent imaging is feasible in endometriosis surgery, and may be
49 considered as a potential candidate to further enhance patient safety in endometriosis
50 bowel surgery

51 clinical trial registration number: NCT03080558

52
53 **Keywords**: Deep Infiltrating Endometriosis; fistula; indocyanine green (ICG); rectal shaving

54

55 **Introduction**

56 There is no consensus regarding the surgical technique for the treatment of
57 rectovaginal septal endometriosis lesions with rectal muscle infiltration. Three surgical
58 techniques are described: rectal shaving, discoid resection and rectal resection (1). The
59 choice between those three techniques consider the symptomatology of the patient, the
60 size of the lesion, the depth of the rectal involvement but also the risk of complications of
61 this kind of surgery and the morbidity that results from it.

62 The major complication of this type of surgery is rectal or recto-vaginal digestive
63 fistula. The fistula rate varies with the technique. According to a recent multicenter study by
64 Roman et al. (1) on 1135 patients, it would be 1.3% after shaving, 3.6% after discoid
65 resection and 3.9% after rectal resection.

66 One of the main mechanism of this type of complication is probably ischemia (2).
67 New techniques for evaluating tissue vascularization are currently under development.
68 Indocyanine green (ICG) is one of the promising techniques in the evaluation of
69 vascularization of tissue. In a recent meta-analysis of 555 patients in the ICG group it has

70 shown the usefulness of ICG to decrease the rate of anastomotic leakage in rectal colorectal
71 surgery (3), causing surgical modification attributed to the ICG assessment. In gynecological
72 surgery, after deep rectal shaving there is no objective and relevant method to evaluate
73 vascularization of the surgical site. As after resection, ICG could be a method to evaluate the
74 rectal wall perfusion after deep shaving. We published recently our preliminary results (4)
75 describing our method.

76 We describe here a prospective single center clinical study. The main objective was to
77 evaluate the feasibility of injecting ICG after resection of a recto vaginal endometriosis
78 nodule by laparoscopic rectal shaving, with or without vaginal resection, using a
79 fluorescence scale. This could allow the estimation of the vascularization of these resection
80 areas, and could possibly modify our surgical strategy and thus reduce the risk of fistula.

81

82 **Material and methods**

83 This is a prospective, single center, feasibility clinical trial (one-armed therapeutic
84 trial, evaluating ICG out of its marketing authorization) conducted between august 2017 and
85 october 2018. The main objective of this study was to evaluate the feasibility of using ICG as
86 a fluorescent marker in order to estimate, through the degree of fluorescence revealed by
87 an infrared light source, the vascularization of the resected zone during the treatment of a
88 rectovaginal nodule by laparoscopic shaving technique. Secondary objectives were; to
89 evaluate the immediate or delayed tolerance of ICG, to estimate the time added by the
90 protocol over the total operating time, to estimate the vascularization at the serosa and
91 rectal mucosa level, to estimate the vaginal vascularization when a vaginal resection is
92 associated, and finally to study the relationship between poor vascularization and the
93 occurrence of postoperative complications, including postoperative fistula.

94 Inclusion criteria were patients with a deep endometriosis nodule infiltrating the
95 rectovaginal septum, having a surgical indication of rectal shaving by laparoscopy, with or
96 without vaginal resection. The objectives of this study wasn't to describe the characteristics
97 of our population, that's why we didn't describe precisely the TVS, and MRI results for the
98 patients. But all patients had a deep endometriosis nodule, infiltrating the rectovaginal
99 septum, analyzed by both TVS and MRI, done by a expert radiologist, with a bowel
100 involvement at least of the serosa, which are the criteria usually used in clinical practice in
101 our team for the surgical recruitment. All the included patients agreed to participate in the
102 study.

103 Exclusion criteria were minors, protected adult patients (under guardianship or
104 trusteeship), and patients who refused the protocol. Patients with a known iodine allergy,
105 pregnant or breastfeeding were not included.

106

107 The protocol: A rectal shaving was performed as described previously by our team (5, 6):
108 shaving was performed using the "reverse technique" starting by the lateral and the vaginal
109 parts of the nodule and ending with the rectal area. The nodule was dissected all around the
110 rectal involvement so as to provide essential exposure of the rectal part of the nodule for
111 the most difficult part of the procedure. At the end of the surgery, 0.2 mg/kg of ICG were
112 injected (one vial with 25 mg diluted in 10ml of solvent composed of water and glucose)
113 intravenously. The degree of fluorescence of the rectal wall was then assessed, with the use
114 of the Likert-type scale (**video 1**). If present, the vaginal suture was also evaluated. Then a
115 transrectal evaluation was performed (a 10 mm trocar was introduced in the anus to
116 evaluate the fluorescence in the rectal mucosa). We used a fluorescence scale based on a

117 Likert scale, with a score from 0 to 4 to evaluate the degree of fluorescence (0= no
118 fluorescence and 4= very good fluorescence) (7) (**video 1**). In order to improve the
119 objectivity of the results, we have made a double interpretation of the fluorescence. The
120 surgeon gave a score during the operation, and then another surgeon gave another score
121 from the recovered videos.

122 The gas and blue test methods were also used to verify the rectal zone of dissection but for
123 verify vascularization, there were insufficient tools.

124 The main evaluation criteria was the degree of fluorescence of the shaving area, in the
125 serosa and rectal mucosa, and in the vaginal suture if a vaginal resection was associated.

126 The secondary evaluation criteria were: side effects related to ICG injection,
127 estimation of vascularization of the shaving area and possibly of the vaginal scar depending
128 on the degree of fluorescence, and occurrence of postoperative complications: infectious,
129 hematoma or fistula. Time limit for bowel activity, indication for re-hospitalization or repeat
130 surgery, and duration of hospitalization were registered as well. Duration of the protocol
131 (time between injection and fluorescence visualization), total dose of ICG used (a repeat
132 injection of 0.2mg/kg was possible when needed) were also collected.

133 Study approval: The study was approved by the French Ethic committee “Comite de
134 Protection des Personnes Sud-Est VI, France”, 2016-002773-35. The protocol was registered
135 in Clinicaltrials.gov (NCT03080558).

136 **Statistical method**

137 Considering this study as pilot aiming to evaluate the feasibility, the sample size justification
138 was determined sequentially, after analyses every each 5 included patients. More precisely,
139 the sample size estimation was fixed according to Fleming's multi-stage design, which
140 includes only one group and between 1 and 5 multi-stages in order to provide filtering steps
141 leading to a go/no go decision. According to the recruitment capacity and feasibility, it was
142 decided to consider 3 steps, with the following assumptions: lower boundary of 50%
143 (maximum inefficacy) and an upper boundary of 80% (minimum efficacy defined as
144 fluorescence levels very good). The type I error and statistical power were fixed, respectively
145 to 5% and 90%. The following decision rules were determined according to Fleming's sample
146 size calculation: with 10 patients included at the end of the first stage, treatment was
147 considered not efficient if 4 or less patients reported a fluorescence levels very good, and
148 efficient if 10 or more fluorescence levels very good were observed. In the event of 5 to 9
149 responses being observed, 10 additional patients would be needed. At the second step,
150 treatment was considered not efficient if 12 (/20) or less patients reported a fluorescence
151 levels very good, and efficient if 16 (/20) or more fluorescence levels very good were
152 observed. In the event of 13 to 15 responses being observed, 10 additional patients would
153 be needed, for a definitive conclusions at 21 patients (/30). With 17 fluorescence levels very
154 good for 21 patients (two patients were included at the same time), the study could be
155 stopped according to Fleming's calculation.

156 The statistical analysis was performed using Stata software (version 13, StataCorp, College
157 Station). As this study can be seen exploratory, the statistical analyses were principally
158 descriptive. The continuous data were expressed as mean \pm standard deviation (SD) or as
159 median [interquartile range] according to the statistical distribution. Assumption of

160 normality was assessed with the Shapiro-Wilk test. No other inferential statistical test was
161 performed

162 **Results**

163 A total of 23 were recruited for an endometriosis surgery with a rectal shaving, 21 patients
164 underwent endometriosis rectovaginal node resection with the shaving technique, and 2
165 patients were finally excluded because underwent a rectal resection at the end (**Figure 1**,
166 Flow-chart). Patient characteristics are presented in **Table 1**. All had preoperative imaging
167 with ultra-sound evaluation, and were additionally evaluated by MRI. For 81% of patients,
168 the muscularis was involved. At the end of the surgery, the time lag between ICG injection to
169 visual detection was 60 seconds (45 to 60). The fluorescence degree of the rectal serosa was:
170 II, III, IV in 1 (4.8%), 3 (14.3%), and 17 (81.0%) patients respectively. The values upon second
171 reading were equal. Fluorescence degree of rectal mucosa was III in 1 (4.8%) patient, IV in 12
172 (57.1%), and not evaluated in 8 (38.1%). On second reading all 13 patients were evaluated as
173 IV (100%). A total of 15 patients (71,4%) had vaginal resection. In the presence of a palpable
174 nodule during vaginal examination, preferably a full-thickness excision of the vaginal wall
175 was performed. The vaginal defect was sutured most of the time by laparoscopy, or by
176 vaginal approach, depending on the defect localization. The vaginal fluorescence degree on
177 the first reading was 0, I, II, III, IV in 3 (14.3%), 2 (9.5%), 3 (14.3%), 2 (9,5%) and 4 (19.0%)
178 patients respectively (in one patient the assessment was not done); on the second reading 0,
179 4 (19.0%), 3 (14.3%), 5 (23.8%) and 1 (4,8%) patients respectively (**supplemental figure 1**).

180 The total dose of ICG injected was 12 mg [10 to 15] with no related adverse reactions.
181 Operation time was 240 min [180 to 254] and the time added by the protocol over the total
182 operating time was evaluated at 5 min.

183 Bowel activity recovery occurred on post-operative day one in 16 (84.2%) patients.
184 Minor complications were post-operative fever (3), lab test with inflammation (3), vaginal
185 disunion (7), hematoma (3), vaginal suture abscess (2). 7 patients were readmitted within 30
186 days: 6 with fever and 1 with active bleeding. One patient had a surgical reoperation a few
187 weeks after the initial surgery, for abnormal vaginal bleeding, with hemorrhagic shock. The
188 patient was reoperated for vaginal bleeding, near to the vaginal suture. A pelvic CT scan was
189 realized, and showed also the presence of an aneurysm of the uterine artery, near the
190 vaginal suture. The aneurysm was radiology embolized, and the post treatment course was
191 after uneventfull.

192 The follow-up duration was at least 3 months for all patients. No patient had a post-
193 operative fistula. One patient, with rectal serosa fluorescence intra-operatively evaluated as
194 I, had a surgical strategy modification: the surgeon added two stitches, to approximate the
195 serosa and muscularis layer of the rectal wall, resulting in improved fluorescence (degree IV
196 after the suture) (**figure 2**). Before this suture, the surgeon did the Blue test, and the gas
197 test. Both were negative, and only the ICG fluorescence allowed us to identify the serosa
198 defect.

199

200 **Discussion**

201 ICG is a molecule that fluoresces in contact with infrared light. During an intravenous
202 injection, in a few seconds, it can easily highlight blood vascularization. Historically used for
203 the study of cardiac output, the detection of choroidal vascularization and the measurement
204 of liver function, its use has been recently developed in digestive surgery to estimate the
205 vascularization of colorectal anastomoses (4).

206

207 Rectovaginal node excision for deep infiltrating endometriosis is a complex surgical
208 procedure. The recommended surgical technique is still controversial in the literature. A
209 recent review comparing rectal shaving, disc excision and bowel resection found a higher
210 rate of complications in bowel resection; mainly rectovaginal fistulas, anastomotic leakage,
211 delayed hemorrhage, and long term bladder catheterization (8). Specifically the rates for
212 rectovaginal fistula for rectovaginal node shaving, disc excision and bowel resection were up
213 to 2.3%, 11.6% and 18.1%, respectively. These higher rates as compared to a previously
214 mentioned study (1) with fistula rates of 1.3%, 3.6% and 3.9% respectively, are attributed
215 mainly to the lower level of rectal endometriosis involvement correlated with higher
216 complication rates. Additionally, with the demonstrated feasibility of rectovaginal shaving
217 technique in the vast majority of cases, better functional outcomes and equal rates of
218 recurrence, the authors concluded that rectovaginal shaving should be the first-line choice of
219 surgical treatment, keeping the alternative techniques for the situations in which the results
220 are unsatisfactory. Anyway, a randomized controlled trial is the only way to get good
221 answers on complication rates. However, to this date there is no intraoperative tool to
222 objectively assess the surgical result of endometriosis bowel surgery. In our center, we try as
223 much as possible to perform a deep rectal shaving, because of low rates of post-operative
224 complications. The patients are always informed before surgery about the risks of digestive
225 resection, or even transient colostomy. Intraoperative estimation of the rectal residual
226 vascularization after shaving is difficult, while this seems to be a good indicator of the risk of
227 postoperative fistula (2). We have reported (4) ICG (pilot study) to intraoperatively evaluate
228 the vascular perfusion of the bowel after rectal shaving. Our series supports the evidence in
229 the literature for a high safety profile of ICG use, with no related adverse reactions

230 registered. The high level evidence that in colorectal surgery ICG use reduces rates of
231 anastomotic leaks (2, 3, 9), with intraoperative assessment causing change of surgical plan in
232 8-13% of patients, supports its use to evaluate bowel perfusion intraoperatively.

233 Fistula is a rare complication of rectovaginal node shaving as mentioned above, and
234 presumably, fistula formation pathogenesis is of vascular impairment origin. ICG use for
235 perfusion assessment has the potential to increase the diagnosis of impaired vascularization,
236 and so to reduce fistula rates. This study has shown ICG as a feasible tool for intraoperative
237 objective evaluation of bowel perfusion after rectovaginal node shaving. For all the patients
238 included, , we also tried gas method or blue test method to verify the rectal zone of
239 dissection, as we always do in this shaving technique at the end of the dissection. In our
240 point of view, the gas and blue test methods are effective tools to identify microperforation
241 and real perforation, but not really for insufficient vascularization, so those two methods
242 have different objectives, and are more complementary than comparable. With the IV
243 injection of ICG, the detection of fluorescence from injection was rapid and convenient
244 (average 60 seconds), and the protocol did not interfere severely with the operation time
245 (adding 5 minutes on average). Other strengths of our study is that it is prospective, reducing
246 selection bias. We have also demonstrated the feasibility of rectal mucosa perfusion
247 assessment technique, which is done with proctoscopy in the colorectal surgery studies
248 assessing anastomosis sites. The subjective evaluation of the fluorescence is a limitation in
249 our study. We tried to manage that by having 2 independent evaluations that showed good
250 correlation (correlation coefficient at 0,82 ($p < 0.001$) which is good and relevant).

251 In the digestive surgery literature, subjective fluorescence analysis has been used as well,
252 and proved to be of clinical benefit. However, even if the evaluation remains really

253 subjective, there is good correlations between evaluation and clinical events. Future studies
254 might incorporate objective evaluation systems. One promising tool is discrimination
255 between arterial and venous bowel ischemia by computer-assisted analysis of the
256 fluorescent signal (intensity and time to maximum fluorescence) (7). Our small sample size is
257 a limitation, with no power to show rare fistula events. However, ICG has led to modify the
258 surgical plan in our series in one case (placing a protective suture on the serosa) showing a
259 potential surgical impact. The benefits of the technique are not already proven, but this
260 study made us think about our surgical habits.

261
262 Recently, there is a rise in reports of IV injection of ICG use in endometriosis surgery,
263 exercising different strategies. In this study we used ICG to evaluate the perfusion of the
264 rectal area after the rectovaginal node shaving procedure, aiming to reduce fistula rate.
265 Another report of ICG use was in a case with recto-sigmoid resection of endometriosis: ICG
266 was injected IV prior to the resection, perfusion assessment helped selecting the transecting
267 line, and after resection ICG was used to assess the anastomosis site (11). A pilot study using
268 ICG to detect occult endometriosis lesions was published. The authors showed the
269 possibility to mark the hyper vascularization of the chronic inflamed lesions (12). In their
270 study of 27 patients, a total of 100 lesions were identified and resected in white light,
271 followed by 16 new lesions (histologically confirmed for endometriosis) in near infrared light.
272 In another series of 5 patients undergoing shaving procedure (13), ICG marked the
273 rectovaginal node. In one patient after the node removal, the posterior vaginal fornix still
274 appeared fluorescent even though no lesion was palpated and was removed, potentially
275 helping achieve a more complete excision of endometriosis (histologic confirmation was not

276 mentioned). All of those reports lead to the interest of using ICG in endometriosis surgery,
277 and larger studies are called for better evidence.

278 One of the weaknesses of our study is the important rate of post-operative vaginal disunion.
279 The possible explanation of the high frequency of the vaginal disunion is that most of the
280 time the objectives of the vaginal suture is hemostatic, so induce necessarily low
281 vascularization. Most of the time, during the post-operative period those vaginal disunion
282 are not really symptomatic, and not major complications. Furthermore, for an experimental
283 studie during lots of cases we also analyzed the vascularization directly through the vagina
284 after the suture, and conversely to the pelvic analyses the fluorescence was mostly really
285 satisfying, so we don't really know which size of the suture can be predictive of the healing
286 quality, and these reports lead to the interest of further studies on this subject.

287

288

289 **Conclusion**

290 Endometriosis bowel surgery complications are at the frontier of endometriosis treatment
291 dilemmas. We cannot conclude from this study that rectovaginal fistula rates are reduced
292 with ICG use after RectoVaginal Nodule shaving, but we propose that with a rare-event
293 complication as rectovaginal fistula, a specific technique is needed to decrease this rate.
294 Given the evidence known in colorectal surgery studies as mentioned, and the report of this
295 study on the specific use of ICG for bowel evaluation in endometriosis surgery, ICG should be
296 considered a potential candidate to further enhance patient safety in endometriosis bowel
297 surgery.

298

299 **Funding**

300 No funding

301

302 **Conflicts of interest**

303 The authors report no conflict of interest

304

305 **Contribution to Authorship**

306 NB, LJ, BP, MC, PC: conception and design of the study, performed the surgical procedures

307 NB, LJ, AC, BSY, BP, MC, PC: acquisition of data, analysis and interpretation of data, drafting
308 the article

309 NB, LJ, BSY, MC, PC: final approval of the version to be submitted

310

311 **References:**

- 312 1. Roman H. FRIENDS group (French Colorectal Infiltrating Endometriosis Study group).
313 A national snapshot of the surgical management of deep infiltrating endometriosis of
314 the rectum and colon in France in 2015: a multicenter series of 1135 cases. *J Gynecol*
315 *Obstet Hum Reprod* 2017;46:159–65.
- 316 2. Jafari MD, Wexner SD, Martz JE, McLemore EC, Margolin DA, Sherwinter DA, et al.
317 Perfusion assessment in laparoscopic left-sided/anterior resection (PILLAR II): A
318 multi-institutional study. *J Am Coll Surg* 2015;220:82–92.e1. Available from:
319 <http://dx.doi.org/10.1016/j.jamcollsurg.2014.09.015>
- 320 3. Colino RB, Basany EE. Intraoperative use of ICG fluorescence imaging to reduce the
321 risk of anastomotic leakage in colorectal surgery: a systematic review and
322 meta - analysis. *Tech Coloproctol* 2018;22:15–23. Available from:
323 <https://doi.org/10.1007/s10151-017-1731-8>
- 324 4. Bar-Shavit Y, Jaillet L, Chauvet P, Canis M, Bourdel N. Use of indocyanine green in
325 endometriosis surgery. *Fertil Steril* 2018;109:1136–7. Available from:
326 <https://doi.org/10.1016/j.fertnstert.2018.02.113>
- 327 5. Bourdel N, Comptour A, Bouchet P, Gremeau AS, Pouly JL, Slim K et al. Long-term
328 evaluation of painful symptoms and fertility after surgery for large rectovaginal
329 endometriosis nodule: a retrospective study. *Acta Obstet Gynecol Scand.*
330 2018;97:158–67.

- 331 6. Kondo W, Bourdel N, Tamburro S, Cavoli D, Jardon K, Rabischong B et al.
332 Complications after surgery for deeply infiltrating pelvic endometriosis. *BJOG An Int J*
333 *Obstet Gynaecol.* 2011;118:292–8.
- 334 7. Sherwinter DA. Transanal near-infrared imaging of colorectal anastomotic perfusion.
335 *Surg Laparosc Endosc Percutan Tech.* 2012 Oct;22:433–6.
- 336 8. Donnez O, Roman H. Choosing the right surgical technique for deep endometriosis:
337 shaving, disc excision, or bowel resection? *Fertil Steril.* 2017;108:931–42. Available
338 from: <https://doi.org/10.1016/j.fertnstert.2017.09.006>
- 339 9. Mizrahi I, Abu-Gazala M, Rickles AS, Fernandez LM, Petrucci A, Wolf J, et al.
340 Indocyanine green fluorescence angiography during low anterior resection for low
341 rectal cancer: results of a comparative cohort study. *Tech Coloproctol.* 2018;22:535–
342 40. Available from: <http://dx.doi.org/10.1007/s10151-018-1832-z>
- 343 10. Diana M, Dallemagne B, Chung H, Nagao Y, Halvax P, Agnus V, et al. Probe-based
344 confocal laser endomicroscopy and fluorescence-based enhanced reality for real-
345 time assessment of intestinal microcirculation in a porcine model of sigmoid
346 ischemia. *Surg Endosc.* 2014;28:3224–33.
- 347 11. Seracchioli R, Raimondo D, Arena A, Zanella M, Mabrouk M. Clinical use of
348 endovenous indocyanine green during rectosigmoid segmental resection for
349 endometriosis. *Fertil Steril.* 2018;109:1135.
- 350 12. Cosentino F, Vizzielli G, Turco LC, Fagotti A, Cianci S, Vargiu V, et al. Near-Infrared
351 Imaging with Indocyanine Green for Detection of Endometriosis Lesions (Gre-Endo
352 Trial): A Pilot Study. *J Minim Invasive Gynecol.* 2018;25:1249–54. Available from:
353 <https://doi.org/10.1016/j.jmig.2018.02.023>
- 354 13. De Neef A, Cadière G-B, Bourgeois P, Barbieux R, Dapri G, Fastrez M. Fluorescence of
355 Deep Infiltrating Endometriosis During Laparoscopic Surgery: A Preliminary Report on
356 6 Cases. *Surg Innov.* 2018;25:450–4. Available from:
357 <https://doi.org/10.1177/1553350618785486>
358 [http://journals.sagepub.com/doi/10](http://journals.sagepub.com/doi/10.1177/1553350618785486)
359 [.1177/1553350618785486](http://journals.sagepub.com/doi/10.1177/1553350618785486)

360

361 **Figures captions:**

362 Video 1: ICG fluorescence: Time lag between injection to visual detection and the degree of
363 fluorescence with the use of the Likert-type scale

364 Figure 1: Flow-chart

365 Table 1: Patients characteristics

366 Supplemental figure 1: Illustration of fluorescence at the rectal mucosa (left) and of the
367 vaginal scar (right), A: rectal mucosa (white light); B: rectal mucosa (ICG); C: vaginal scar
368 (white light); D: vaginal scar (ICG)

369 Figure 2: Patient with modification of the surgical procedure

370 A: Before suture (white light). Rectal serosa fragility; B: Before suture (ICG). Rectal serosa
371 fluorescence intra-operatively evaluated as I; C: After suture (white light). Rectal shaving
372 zone after the add of the two stiches; D: After suture (ICG). Improved fluorescence (degree
373 IV)

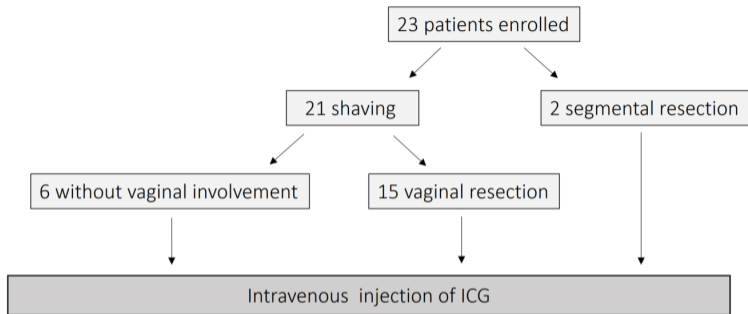
374

375

table 1: patients characteristics	n=21
Age (years) (Mean ± SD)	35±6.7
BMI (median. range)	25 [22.7-30.8]
Smoking n (%)	7 (33.3)
Previous surgery n (%)	
Cesarean section	3 (14.2)
Appendicectomy	6 (28.6)
Ectopic pregnancy	1 (4.8)
Laparoscopy	6 (28.6)
Caucasian n (%)	20 (95.2)
Associated endometriosis distribution n (%)	
Ovarian endometrioma	14 (66.7)
Bladder	2 (9.5)
Adenomyosis	8 (38.1)
Preoperative imaging n (%)	
Pelvic ultrasound	21 (100)
X-ray Scan	1 (4.8)
MRI	21 (100)
rectal infiltration (%)	
serosa	100
muscularis	100
submucosa	81.0
mucosa	0.0
lesions involved (%)	
uterosacral ligaments	71.4
rectum	81.0
torus	57.1
rectosigmoid junction	23.8
vagina pouch	57.1
pouch of Douglas	33.3
dimensions of rectovaginal nodule (cm)	
height	2.02±0.7
thickness	1.8±0.9
Time between ICG injection and visual detection sec (median. range)	60 [45-60]
Fluorescence degree of the rectal serosa n (%)	
II	1 (4.8)
III	3 (14.3)
IV	17 (81.0)
Fluorescence degree of the rectal mucosa n (%)	
III	1 (4.8)
IV	12 (57.1)
not evaluated	8 (38.1)
Fluorescence degree of the vaginal suture (15 patients) n (%)	
0	3 (20.0)
1	2 (13.3)
2	3 (20.0)
3	2 (13.3)
4	4 (26.7)
not evaluated	1 (6.7)

Mean dose of ICG injected (mg) (median. range)	12 [10;15]
Operative time (min) (median. range)	240 [180;254]
Duration of protocole (min) (median. range)	5 [5;5]
Transit recovery J1 n (%)	16 (84.2%)
Minor complications n (%)	
post-operative fever	3 (14.3)
biological inflammatory syndrome	3 (14.3)
vaginal disunion	6 (42.9)
hematoma	3 (14.3)
vaginal suture abscess	2 (9.5)
rehospitalization	7
- fever	6 (28.6)
- bleeding	1 (4.8)
surgical reoperation	1 (4.8)
fistula	0

376



1 patient with modification of the surgical procedure due to Intravenous ICG: Suture of the serosa

