



HAL
open science

3D-imaging in percutaneous spine surgery using the Surgivisio system

Mehdi Boudissa, Marc Prod'homme, Gaël Kerschbaumer, Sébastien Ruatti, Jérôme Tonetti

► To cite this version:

Mehdi Boudissa, Marc Prod'homme, Gaël Kerschbaumer, Sébastien Ruatti, Jérôme Tonetti. 3D-imaging in percutaneous spine surgery using the Surgivisio system. *Orthopaedics & Traumatology: Surgery & Research*, 2020, 106, pp.1183 - 1186. <10.1016/j.otsr.2020.01.018>. <hal-03492036>

HAL Id: hal-03492036

<https://hal.science/hal-03492036v1>

Submitted on 23 Sep 2022

HAL is a multi-disciplinary open access archive for the deposit and dissemination of scientific research documents, whether they are published or not. The documents may come from teaching and research institutions in France or abroad, or from public or private research centers.

L'archive ouverte pluridisciplinaire **HAL**, est destinée au dépôt et à la diffusion de documents scientifiques de niveau recherche, publiés ou non, émanant des établissements d'enseignement et de recherche français ou étrangers, des laboratoires publics ou privés.



Distributed under a Creative Commons CC BY-NC 4.0 - Attribution - Non-commercial use - International License

3D-imaging in percutaneous spine surgery using the SURGIVISIO system

Mehdi **Boudissa**^{a,b,*}, Marc **Prod'homme**^a, Gaël **Kerschbaumer**^a, Sébastien **Ruatti**^a, Jérôme **Tonetti**^{a,b}

a. Service de Chirurgie Orthopédique et Traumatologique, CHU Grenoble, Hôpital Nord, Boulevard de la Chantourne, 38700 La Tronche, Université Grenoble Alpes, Grenoble, France.

b. Laboratoire TIMC-IMAG, Université Grenoble Alpes, CNRS UMR 5525, Pavillon Taillefer 38700 La Tronche, France.

* Corresponding author: Mehdi Boudissa, Service de Chirurgie Orthopédique et Traumatologique, CHU Grenoble, Hôpital Nord, Boulevard de la Chantourne, 38700 La Tronche, Université Grenoble Alpes, Grenoble, France.

E-mail: Mehdi Boudissa

mboudissa@chu-grenoble.fr

Abstract

The Surgivision system is a new generation of intraoperative 3D imaging, used in our institution for pedicle insertion in minimally invasive spine surgery since January 2018. The purpose of this technical note is to describe the Surgivision system, its advantages and its limitations, in percutaneous spinal surgery. Results of the first year of use were analyzed, in a series of 29 patients, to evaluate accuracy of pedicle screw insertion, operative time and radiation exposure. On the Heary and Gertzbein classifications, 95.5% of pedicle screw placements (107/112) were rated as acceptable. Mean operative time was 29.3 min per vertebra; mean radiation exposure per vertebra was 0.61 mSv.

The Surgivision system is an effective navigation tool for pedicle screw insertion in minimally invasive spinal surgery, with acceptable radiation exposure and operative time for each navigated vertebra.

Level of evidence: II, prospective cohort study

Keywords: Spine surgery; 3D imaging; Computer-assisted surgery; Navigation;

Radioprotection

2. Introduction

With the advent of percutaneous spinal surgery, new-generation 3D imaging systems are used to improve the accuracy of pedicular screw insertion, reducing the malpositioning rate of 1-15% [1-4]. This improvement, however, entails an extra radiation dose, depending on the navigation system, with a mean dose between 0.4 and 5.8 mSv [1-5].

Surgivisio is a new 2D/3D imaging system providing real-time navigation for screw insertion. It is easy to use and does not require blocking breathing during acquisition. We have been using it regularly since January 2018.

The aim of the present technical note was to describe the functioning of the Surgivisio system, and its advantages and limitations in percutaneous spinal surgery. Results for the first year of use were analyzed to assess accuracy of screw positioning, total surgery time and radiation dose.

3. Description of the technique

Patients were operated on under general anesthesia, in prone position on a radiotransparent carbon traction table (Allen, Massachusetts, USA). The Surgivisio system (Surgivisio, Gières, France) provides 2D and 3D intraoperative imaging and real-time navigation via a single platform. Navigation comprises 3 stages:

- Patient landmark positioning and C-arm centering

The landmark is fixed on the spinal processes by K-wires, usually 3, interconnected by a rigid fixation system. A single-use butterfly-shaped calibration phantom is positioned on the landmark (figure 1).

- Image acquisition and 3D reconstruction

An optimal C-arm trajectory is programmed so as to maximize reconstruction volume while avoiding collisions with the traction table and minimizing radiation dose by acquiring either 90 or 180 projections, as chosen by the surgeon. The team is protected behind a lead screen throughout this stage. The calibration phantom is automatically detected on each projection; the 3D image is reconstructed with compensation for any patient movement, including respiration (Figure 2).

- Navigation

The calibration phantom is replaced by an optical tracker, automatically fitted to the 3D imaging. Navigation uses a specific single-use trocar fitted with tracking devices (figure 3). The surgeon can then navigate the trocar within the reconstructed images in real time to insert the pedicle screw. Screw length is measured on the trocar trajectory gradation in the reconstructed image (figure 4).

Pedicle fixation used the ES2 system (Stryker, Pusignan, France) or Longitude2 system (Medtronic, Boulogne-Billancourt, France), with cementable screws as necessary.

All patients undergoing Surgivisio-navigated percutaneous surgery between January and December 2018 were analyzed. Demographic and epidemiological data, Magerl fracture types, surgical indications and surgical strategies were collected [6]. Surgery was performed by 3 surgeons experienced in spine surgery. Operating times, overall and per vertebra, were collected. Radiation dose (in milliSievert: mSv) was calculated for the whole procedure and per vertebra, using PCXMC 2.0 software (Stuk, Helsinki, Finland). Dose-area product (DAP) was calculated in Gy.cm². Individual effective dose was assessed by Monte Carlo simulation [7]. Intraoperative screw repositioning and intra- and post-operative complications were reported. High-resolution millimetric-slice CT was performed postoperatively, with screw

positioning assessed on the Heary and Gertzbein classifications by 2 independent observers [8,9] as acceptable for Heary grade ≤ 3 or Gertzbein grade $\leq B$ [10]; in case of disagreement, the poorer grade was kept.

Statistical analysis used StatView 5.5 software (SAS Institute, Cary, NC, USA). Qualitative variables were compared on χ^2 and quantitative variables on Student test. The significance threshold was set at $p < 0.05$.

4. Results

Between January and December 2018, 29 patients, for 87 vertebrae and 173 pedicle screws, underwent Surgivision-navigated percutaneous surgery. Demographic and clinical data, surgical indications and fracture distribution and classification are shown in Table 1 and figure 5. Mean surgery time was 95 ± 37.1 min (range, 39-180 min) per procedure and 29.3 ± 18.7 min (range, 12-90 min) per vertebra. Mean number of vertebrae per procedure was 3 ± 1 (range, 2-5). Twenty of the 29 patients underwent postoperative high-resolution millimetric CT, assessing 112 screws. On the Heary and Gertzbein classifications, 95.5% of screws (107/112) were acceptably positioned [8,9]. Only 5 of the 25 cortical breakages involved medial breach: i.e., 5/112 (4%). Results are shown in Table 2.

Mean DAP was 8.07 ± 5.73 Gy.cm² (range, 1.85-22.27 Gy.cm²). Mean effective dose (E PCXMC ICRP 103) was 1.97 ± 1.52 mSv (range, 0.54-6.27 mSv). Mean surgeon dose was 0.88 ± 0.78 mSv (range, 0.11-3.82 mSv) and mean dose per vertebra was 0.61 ± 0.55 mSv (range, 0.16-2.43 mSv). No intraoperative screw repositioning was necessary. There were no complications or revision surgeries during follow-up.

5. Discussion

This new all-in-one navigation system combining 2D and 3D imaging with real-time navigation is easy to use and secures pedicle screw positioning in percutaneous spine surgery. It can be applied in open surgery and in pelvic ring surgery (e.g., sacroiliac screwing). With 95.5% acceptable positioning, the present results were comparable to those reported with other navigation systems. In a recent comparative study between O-arm and Airo, Farah et al. reported 90.8% acceptability with O-arm and 92.2% with Airo [10]; depending on the report, rates range between 89% and 100% [11]. The learning curve may account for the present cases of medial breach, which occurred early in our experience [12,13].

Mean radiation dose per vertebra was 0.61 mSv, comparable to or lower than with other systems. Farah et al., comparing O-arm versus Airo, reported mean doses of respectively 1.04 mSv and 3.9 mSv [10]. According to Noriega et al., the extra irradiation entailed by navigation is justified by the significant decrease in malpositioning (3.6%) compared to the conventional technique (10.3%) [2]. As the team leaves the operating room or is protected behind a lead screen during acquisition, irradiation concerns only intraoperative fluoroscopy. Surgivision 3D reconstructions can use 90 or 180 projections. In our early experience, we systematically used 180, but now mainly use 90, without qualitative impairment of reconstruction. The present sample size did not allow subgroup analysis of this factor, and a larger cohort would be needed to extend the results.

Mean operating time per vertebra was 29.3 minutes, which was longer than for Ruatti et al., who reported a mean 21 minutes per vertebra in conventional surgery, but this is to be set against better precision: Ruatti et al. had 24% malpositioning in percutaneous surgery [3]. A

study is underway to compare intraoperative radiation dose with and without the Surgivisio system. After the first year of use and the learning curve, we now use Surgivisio regularly in degenerative surgery, with promising results, including for interbody implantation.

Applications for degenerative surgery and deformities are currently under assessment.

The Surgivisio system is an effective new navigation tool for pedicular screwing in minimally invasive spine surgery, with acceptable mean radiation dose and operating time per vertebra.

Conflicts of interest:

Mehdi Boudissa, Gael Kerschbaumer and Jérôme Tonetti are consultants for Surgivisio.

Funding: none

Author contributions:

Mehdi Boudissa, Gael Kerschbaumer and Jérôme Tonetti: article writing

Sébastien Ruatti and Marc Prod'homme: data collection and statistics

References

- [1] Meng XT, Guan XF, Zhang HL, He SS. Computer navigation versus fluoroscopy-guided navigation for thoracic pedicle screw placement: a meta-analysis. *Neurosurg Rev.* 2016;39:385-91.
- [2] Noriega DC, Hernández-Ramajo R, Rodríguez-Monsalve Milano F, Sanchez-Lite I, Toribio B, Ardura F, Torres R, Corredera R, Kruger A. Risk-benefit analysis of navigation techniques for vertebral transpedicular instrumentation: a prospective study. *Spine J* 2017;17:70-75.
- [3] Ruatti S, Dubois C, Chipon E, Kerschbaumer G, Milaire M, Moreau-Gaudry A, Tonetti J, Merloz P. Interest of intra-operative 3D imaging in spine surgery: a prospective randomized study. *Eur Spine J* 2016;25:1738-44.
- [4] Tajsic T, Patel K, Farmer R, Mannion RJ, Trivedi RA. Spinal navigation for minimally invasive thoracic and lumbosacral spine fixation: implications for radiation exposure, operative time, and accuracy of pedicle screw placement. *Eur Spine J.* 2018;27:1918-1924
- [5] Cordemans V, Kaminski L, Banse X, Francq BG, Detrembleur C, Cartiaux O. Pedicle screw insertion accuracy in terms of breach and reposition using a new intraoperative cone beam computed tomography imaging technique and evaluation of the factors associated with these parameters of accuracy: a series of 695 screws. *Eur Spine J.* 2017;26:2917-2926.
- [6] Magerl F, Aebi M, Gertzbein SD, Harms J, Nazarian S. A comprehensive classification of thoracic and lumbar injuries. *Eur Spine J* 1994;3:184-201.
- [7] Dedulle A, Fitousi N, Zhang G, Jacobs J, Bosmans H. Two-step validation of a Monte Carlo dosimetry framework for general radiology. *Phys Med.* 2018;53:72-79
- [8] Heary RF, Bono CM, Black M. Thoracic pedicle screws: postoperative computerized tomography scanning assessment. *J Neurosurg.* 2004;100(4 Suppl Spine):325-31.

[9] Gertzbein SD, Robbins SE. Accuracy of pedicular screw placement in vivo. *Spine (Phila Pa 1976)*. 1990;15:11-4.

[10] Farah K, Coudert P, Graillon T, Blondel B, Dufour H, Gille O, Fuentes S. Prospective Comparative Study in Spine Surgery Between O-Arm and Airo Systems: Efficacy and Radiation Exposure. *World Neurosurg*. 2018;118:e175-e184.

[11] Gelalis ID, Paschos NK, Pakos EE, Politis AN, Arnaoutoglou CM, Karageorgos AC, Ploumis A, Xenakis TA. Accuracy of pedicle screw placement: a systematic review of prospective in vivo studies comparing free hand, fluoroscopy guidance and navigation techniques. *Eur Spine J* 2012;21:247-55.

[12] Rivkin MA, Yocom SS. Thoracolumbar instrumentation with CT-guided navigation (O-arm) in 270 consecutive patients: accuracy rates and lessons learned. *Neurosurg Focus*. 2014;36(3):E7.

[13] Rahmathulla G, Nottmeier EW, Pirris SM, Deen HG, Pichelmann MA. Intraoperative image-guided spinal navigation: technical pitfalls and their avoidance. *Neurosurg Focus*. 2014;36(3):E3.

Legends:

Figure 1: Single use “butterfly” calibration phantom positioned on patient landmark.

Figure 2: Surgivision 3D reconstruction, axial, coronal and sagittal slices (acquisition of 90 images).

Figure 3: Single use navigation hardware. Left to right: navigation trocar, optical tracker, calibration phantom, patient landmark and K-wire anchoring onto spinal processes.

Figure 4: Trocar navigation and fitting trocar trajectory on reconstruction images. The space between 2 blue dots is 10 mm, used for measuring screw length.

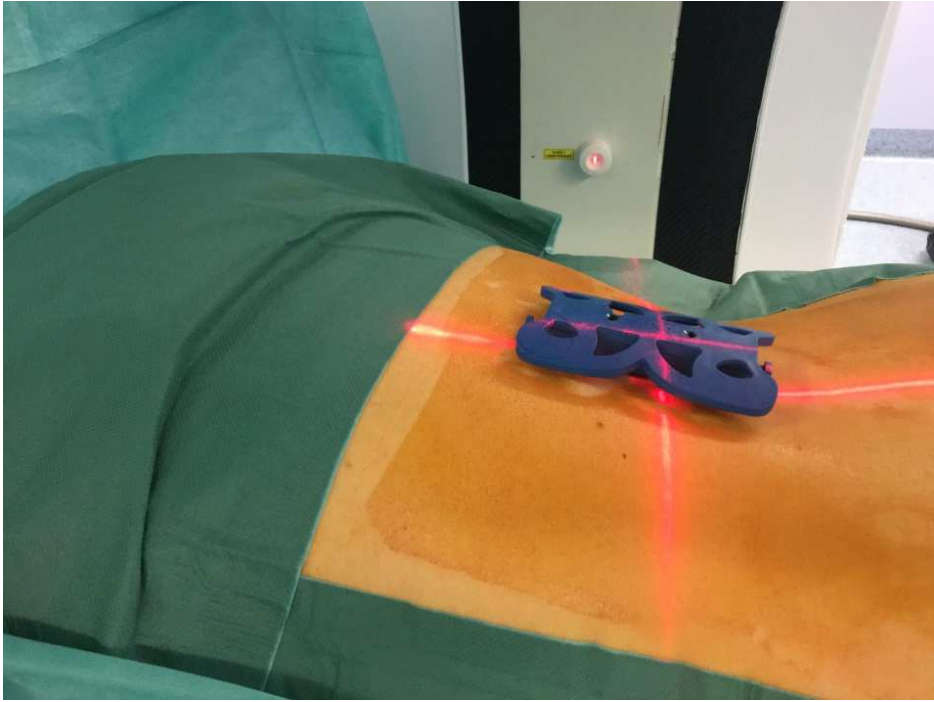
Figure 5: Distribution of (a) navigated vertebrae and (b) Magerl fracture types [6].

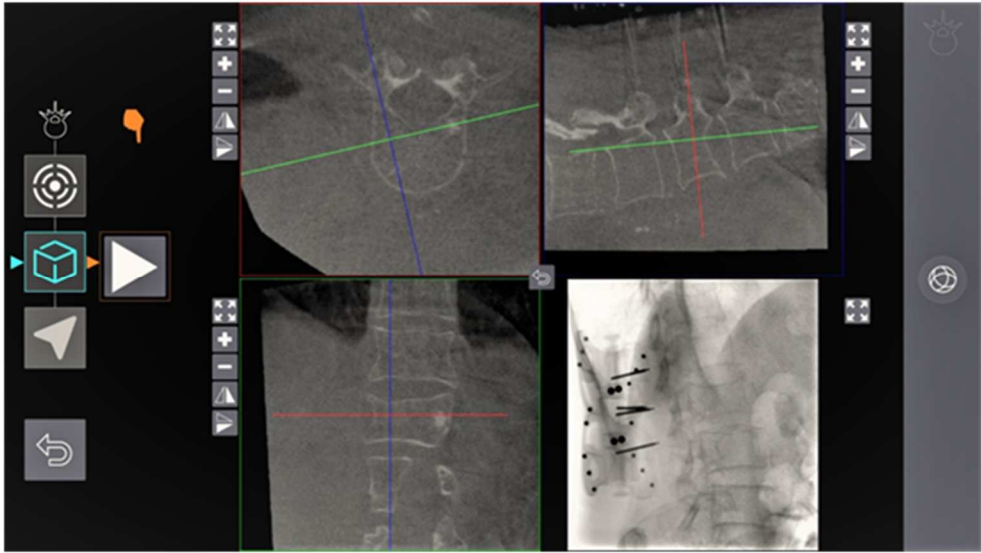
Table 1: Demographic data.

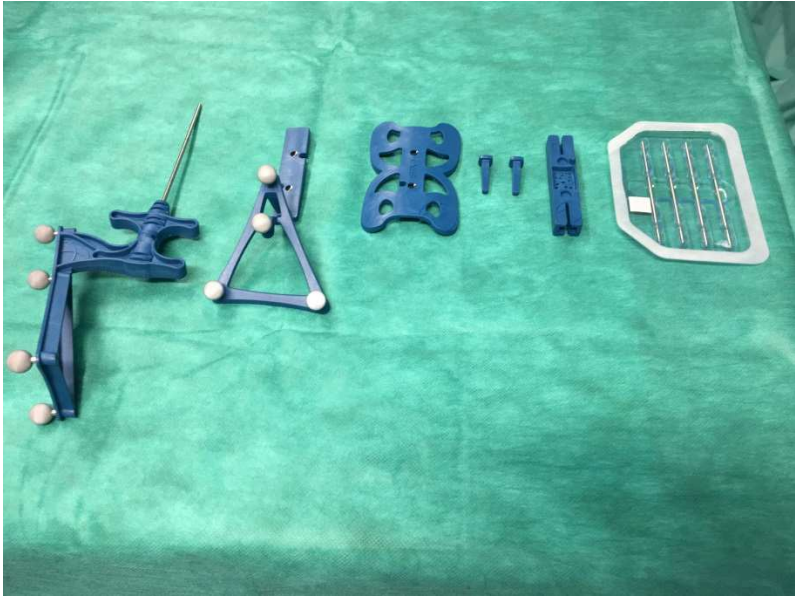
Mean	Series (n=29)
Sex ratio	
<i>male</i>	17
<i>female</i>	12
Age, years (range)	69.6 (42-92)
Body-mass index (kg/m ²)	24.7 (18-34.4)
Surgical indications	1
<i>traumatic</i>	17
<i>tumoral</i>	6
<i>degenerative</i>	6
Operating time, minutes (range)	
<i>procedure</i>	95 (39-180)
<i>vertebra</i>	29.3 (12-90)
Hospital stay, days (range)	
<i>overall</i>	10.8 (3-20)
<i>postoperative</i>	7 (1-15)

Table 2: Pedicle screw positioning according to the Heary and Gertzbein classifications [8,9].

HEARY CLASSIFICATION	POSITIONING, n =112 (%)
GRADE 1	87 (78%)
GRADE 2	13 (12%)
GRADE 3	7 (6%)
GRADE 4	5 (4%)
GRADE 5	0 (0%)
GERTZBEIN CLASSIFICATION	
GRADE A	87 (78%)
GRADE B	20 (18%)
GRADE C	5 (4%)
GRADE D	0 (0%)
GRADE E	0 (0%)







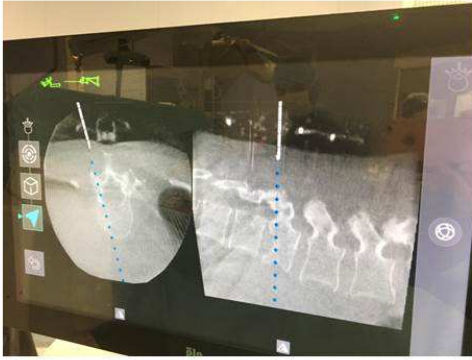
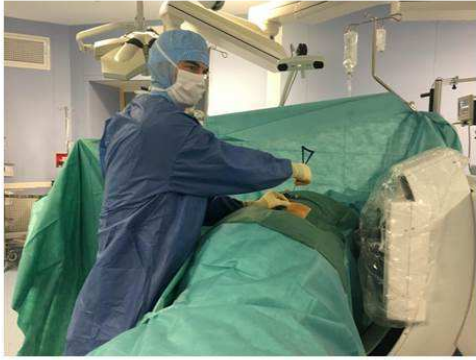

Figure 5a: Distribution of the fractured levels

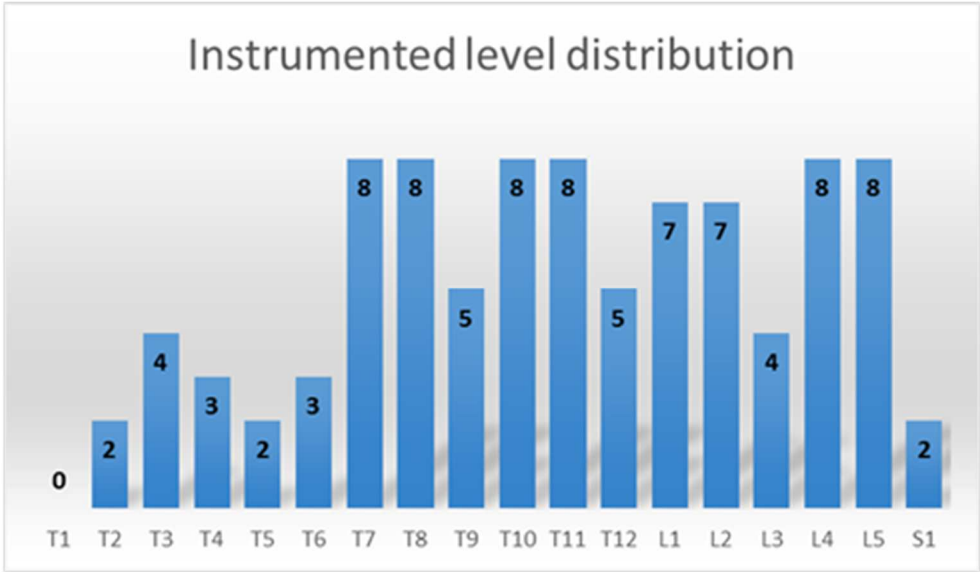


Figure 5b: Fracture distribution according to the Magerl classification [9]

