



HAL
open science

A case of congenital toxoplasmosis-associated miscarriage with maternal infection four months prior to conception

Loïc Simon, Cynthia Trastour, Albert Soler, Fabienne Jeannet, Marie-Fleur Durieux, Karine Passebosc-Faure, Pierre Marty, Christelle Pomares

► To cite this version:

Loïc Simon, Cynthia Trastour, Albert Soler, Fabienne Jeannet, Marie-Fleur Durieux, et al.. A case of congenital toxoplasmosis-associated miscarriage with maternal infection four months prior to conception. *Parasitology International*, 2020, 79, pp.102165 -. 10.1016/j.parint.2020.102165 . hal-03492006

HAL Id: hal-03492006

<https://hal.science/hal-03492006v1>

Submitted on 15 Jul 2022

HAL is a multi-disciplinary open access archive for the deposit and dissemination of scientific research documents, whether they are published or not. The documents may come from teaching and research institutions in France or abroad, or from public or private research centers.

L'archive ouverte pluridisciplinaire **HAL**, est destinée au dépôt et à la diffusion de documents scientifiques de niveau recherche, publiés ou non, émanant des établissements d'enseignement et de recherche français ou étrangers, des laboratoires publics ou privés.



Distributed under a Creative Commons Attribution - NonCommercial 4.0 International License

1 **A case of congenital toxoplasmosis-associated miscarriage with maternal infection four months prior to**
2 **conception.**

3 Loïc Simon^{a,b*}, Cynthia Trastour^c, Albert Soler^d, Fabienne Jeannot^e, Marie-Fleur Durieux^{f,g}, Karine Passebosc-
4 Faure^f, Pierre Marty^{a,b}, Christelle Pomares^{a,b}.

5 a- Service de Parasitologie-Mycologie, CHU de Nice, Université Côte d'Azur, Nice, France

6 b- Inserm U1065, C3M, Nice, France

7 c- Service de Gynécologie-Obstétrique, CHU de Nice, Nice, France

8 d- Polyclinique Saint-Jean, Cagnes-sur-Mer, France

9 e- Médecine générale, Saint-Laurent-Du-Var, France

10 f- Centre National de Référence Toxoplasmose / *Toxoplasma* Biological Resource Center, CHU Limoges,
11 Limoges, France

12 g- Inserm UMR_S 1094, Neuroépidémiologie Tropicale, Laboratoire de Parasitologie-Mycologie, Faculté de
13 Médecine, Université de Limoges, Limoges, France

14

15 Word count: 1367 ; Figure count: 1 ; Table count: 1

16 Short title: Maternal toxoplasmosis before conception

17

18 * Corresponding author:

19 Loïc Simon (email: simon.l@chu-nice.fr, tel: +33 (0)4 92 03 62 54)

20 Service de Parasitologie-Mycologie, CHU de Nice - Hôpital l'Archet, 151 route Saint-Antoine de Ginestière, CS
21 23079, 06202 Nice cedex 3, France.

22

23 Disclosure: The authors have no competing interests and no financial support or funding to declare.

24 ABSTRACT

25 **Background:** We report a case of fatal congenital toxoplasmosis with maternal infection dated four months
26 before pregnancy in the absence of any specific immunosuppressive condition.

27 **Case:** Ms. D. experienced submaxillary lymphadenitis in February 2018. The medical workup performed
28 revealed an acute *T. gondii* infection. She became pregnant in June 2018 while she still had adenopathy. The
29 second obstetrical ultrasound, performed at 16 weeks of pregnancy, revealed a fetal death. The research for *T.*
30 *gondii* by PCR was positive in the products of conception.

31 **Conclusion:** Diagnosis of toxoplasmosis should be discussed in case of miscarriage with lymphadenitis. As
32 lymph nodes in *T. gondii* infection could be responsible for iterative release of parasites and fetal death,
33 symptomatic toxoplasmosis should be treated in women of childbearing age.

34

35 Keywords: *Toxoplasma gondii*, congenital toxoplasmosis, preconception, miscarriage, fetal death.

36

37

38

39

40

41

42

43

44

45

46

47 CASE REPORT

48 The intracellular parasite *Toxoplasma gondii* is responsible for toxoplasmosis, whose primary infection is
49 asymptomatic in about 80% of cases in healthy people. Sometimes, mild symptoms may be present, including
50 asthenia, cervical lymphadenitis, fever and biological mononucleosis syndrome. Newborns are at risk of
51 congenital toxoplasmosis when the infection occurs during pregnancy. The tachyzoite form of the parasite can
52 then be transmitted to the fetus by random breaks from placental foci. The risk of transmission is considered low
53 when the maternal infection occurs at the beginning of pregnancy but it increases up to 70% at the end of
54 pregnancy [1]. Conversely, severity of congenital infection is higher at the beginning compared to the end of
55 pregnancy. Few congenital infections are described when women were infected before the date of conception. In
56 the majority of cases, these infections can be explained by reactivation of a past infection during pregnancy in
57 immunocompromised mothers [2]. Here, we report a case of fatal congenital toxoplasmosis with maternal
58 infection dated four months before pregnancy in the absence of any specific immunosuppressive condition.

59 In February 2018, Ms. D., a 28-year-old G1P1 with no medical conditions and no foreign travel, presented with
60 fatigue and enlarged cervical lymph nodes. After an evaluation by general physicians and ENT specialists, she
61 was diagnosed with submaxillary lymphadenitis, confirmed by a cervical ultrasound. The biological workup,
62 including a complete blood count with differential, was normal and did not show obvious sign of
63 immunosuppression. The cytomegalovirus, Epstein-Barr Virus, Hepatitis B and C Virus, and HIV serological
64 tests results were negative and rubella serology demonstrated immunity. As the lymphadenitis persisted, a *T.*
65 *gondii* serology was performed the 4th of April and was consistent with an acute infection dated beginning of
66 February with presence of specific IgG, IgM and IgA (Table 1). IgG avidity was low, which was not relevant in
67 helping to assume the age of the infection, as only high-avidity anti-*Toxoplasma* IgG antibodies is informative to
68 exclude acute infection in the preceding 4 months. The last known negative *T. gondii* serology dated November
69 29, 2017: IgG = < 0.5 UI/mL; IgM index = 0.37 (ADVIA Centaur[®] Toxo Assay). An ophthalmologic exam did
70 not reveal any abnormality. No treatment was prescribed at that time.

71 Few months later, Ms. D. became pregnant. The first day of the last menstrual period was May 22, 2018 and the
72 estimated date of conception was June 05, 2018. The first fetal ultrasound performed on August 17 during the
73 first trimester demonstrated an embryo with a crown-rump length of 63.8 mm, consistent with a gestational age
74 of 12 weeks and 4 days. All biometric measurements were between the 10th and the 90th percentiles and no
75 morphological abnormalities were observed. On September 12, at 16 weeks and 2 days of pregnancy, a second

76 obstetrical ultrasound highlighted fetal death that probably occurred few days after the first ultrasound according
77 to the obstetrical measurements. Uterine curettage was performed the following day at the teaching hospital of
78 Nice, France. Analysis of the products of conception by the laboratory of Parasitology-Mycology revealed a
79 positive *T. gondii* PCR. Microsatellite genotyping performed on the PCR products by the National Reference
80 Center for Toxoplasmosis, in Limoges, found a Type II *T. gondii* strain (TgH 23069A). Type II strains represent
81 95% of the circulating strains in France [3–5]. *Toxoplasma gondii* PCR performed on the peripheral blood of Ms.
82 D. was negative. **Figure 1** summarizes the timeline of the events. After questioning Ms. D., we learned that the
83 submaxillary lymphadenitis was still palpable when she became pregnant and during the pregnancy. To date,
84 Ms. D. is doing well. She became pregnant again on April 2019 and gave birth to a healthy baby on December
85 31.

86 In some countries like France, pregnant women are tested in the early weeks of gestation for the presence of
87 specific IgG and IgM against *T. gondii*. When the first serology is negative, a monthly prenatal screening is
88 performed. This approach allows prompt initiation of treatment of the mothers who seroconvert and of infected
89 fetuses along with being cost-effective [1,6]. In our case, *T. gondii* infection, proven by the association of
90 symptomatology and specific serology, occurred four months before conception. Per protocol, no further
91 treatment or evaluation was performed and there should have been no consequences on the pregnancy.
92 *Toxoplasma gondii* was transmitted to the fetus long after the estimated date of infection. Similar cases are rare
93 in the literature and to our knowledge, this is the first description of proven fetus infection with such a long
94 period of time between mother infection and conception [2,7–14]. The presence of enlarged cervical lymph
95 nodes seems to be the common feature in similar situations of pregnant women without immunosuppressive
96 pathology [7,10–12]. We might wonder if an iterative release of parasites from the lymph nodes may have been
97 responsible, in our case and the others, for fetus infection. Moreover, when primary infection is symptomatic,
98 there could be a prolonged parasitemia, promoting transmission to the fetus. Our patient was not treated at the
99 time of diagnostic but treatment with spiramycin before conception have been performed in other cases and
100 failed to prevent infection of the fetus [2,7,8,11]. Currently, there are no official recommendations about the
101 preconceptional toxoplasmosis care. We agree with Villena *et al.* [7] on advocating a pregnancy-free interval of
102 at least six months after proven toxoplasmosis infection. In addition, specific monitoring, by regular ultrasound
103 and prenatal diagnosis, in pregnant immune women with adenopathy should be recommended. Effective
104 treatment of symptomatic toxoplasmosis in women with a desire for pregnancy could be advisable too.
105 Treatment strategy with trimethoprim-sulfamethoxazole (already used for *T. gondii* infection in

106 immunocompromised patients) could be a good alternative to spiramycin. A double-blind, randomized clinical
107 trial by Alavi *et al.* [15] showed the benefits of a treatment by trimethoprim-sulfamethoxazole (= cotrimoxazole)
108 at 48 mg/kg/day for 1 month on the healing of lymphadenitis and the decrease of anti-*T. gondii* IgM level.
109 Moreover, it is also important to encourage practitioners to examine women with miscarriage for the presence of
110 enlarged lymph nodes. In case of lymphadenitis, the diagnosis of toxoplasmosis should be discussed. The role of
111 *T. gondii* in unexplained miscarriages has been rarely assessed and is probably underestimated. According to the
112 review by Giakoumelou *et al.* [16], the link between miscarriages and congenital toxoplasmosis was poorly
113 studied. In this review, the study populations ranged from 100 to 326 women with a history of miscarriage. The
114 analyses performed were often limited to serological tests or *T. gondii* PCR in mothers' blood and these assays
115 are not those which make it possible to diagnose a congenital toxoplasmosis. Prevalence of toxoplasmosis ranges
116 from 20% to 70% worldwide and more powerful studies about the potential role of *T. gondii* in miscarriages are
117 needed to better prevent fetus infection.

118 This case report highlights the fact that a symptomatic acute infection by *T. gondii* should be considered
119 differently than an asymptomatic one. A period of six months should be considered between the symptomatic
120 infection and the pregnancy, in order to prevent unexplained miscarriage.

121

122

123

124

125

126

127

128

129

130

131 REFERENCES

- 132 [1] Wallon M, Peyron F, Cornu C, Vinault S, Abrahamowicz M, Kopp CB, Binquet C. Congenital
133 *Toxoplasma* Infection: Monthly Prenatal Screening Decreases Transmission Rate and Improves Clinical
134 Outcome at Age 3 Years. *Clin Infect Dis*. 2013;56(9):1223–31.
- 135 [2] Marty P, Bongain A, Rahal A, Thulliez P, Wasfi D, Lambert JC, Le Fichoux Y, Gillet JY. Prenatal
136 diagnosis of severe fetal toxoplasmosis as a result of toxoplasmic reactivation in an HIV-1 seropositive
137 woman. *Prenat Diagn*. 1994;14(5):414–5.
- 138 [3] Ajzenberg D, Collinet F, Aubert D, Villena I, Dardé M-L, French ToxoBs network group, Devillard S.
139 The rural-urban effect on spatial genetic structure of type II *Toxoplasma gondii* strains involved in human
140 congenital toxoplasmosis, France, 2002-2009. *Infect Genet Evol*. 2015;36:511–6.
- 141 [4] Aubert D, Ajzenberg D, Richomme C, Gilot-Fromont E, Terrier ME, de Gevigney C, Game Y, Maillard
142 D, Gibert P, Dardé ML, Villena I. Molecular and biological characteristics of *Toxoplasma gondii* isolates
143 from wildlife in France. *Veterinary Parasitology*. 2010;171(3):346–9.
- 144 [5] Halos L, Thébault A, Aubert D, Thomas M, Perret C, Geers R, Alliot A, Escotte-Binet S, Ajzenberg D,
145 Dardé M-L, Durand B, Boireau P, Villena I. An innovative survey underlining the significant level of
146 contamination by *Toxoplasma gondii* of ovine meat consumed in France. *International Journal for*
147 *Parasitology*. 2010;40(2):193–200.
- 148 [6] Binquet C, Lejeune C, Seror V, Peyron F, Bertaux A-C, Scemama O, Quantin C, Béjean S, Stillwaggon E,
149 Wallon M. The cost-effectiveness of neonatal versus prenatal screening for congenital toxoplasmosis.
150 *PLoS ONE*. 2019;14(9):e0221709.
- 151 [7] Villena I, Chemla C, Quereux C, Dupouy D, Leroux B, Foudrinier F, Pinon J. Prenatal diagnosis of
152 congenital toxoplasmosis transmitted by an immunocompetent woman infected before conception. Reims
153 Toxoplasmosis Group. *Prenatal diagnosis*. 1998;18:1079–81.
- 154 [8] Dollfus H, Dureau P, Hennequin C, Uteza Y, Bron A, Dufier JL. Congenital *toxoplasma* chorioretinitis
155 transmitted by preconceptionally immune women. *Br J Ophthalmol*. 1998;82(12):1444–5.

- 156 [9] Pons JC, Sigrand C, Grangeot-Keros L, Frydman R, Thulliez P. [Congenital toxoplasmosis: transmission
157 to the fetus of a pre-pregnancy maternal infection]. *Presse Med.* 1995;24(3):179–82.
- 158 [10] Desmots G, Couvreur J, Thulliez P. [Congenital toxoplasmosis. 5 cases of mother-to-child transmission
159 of pre-pregnancy infection]. *Presse Med.* 1990;19(31):1445–9.
- 160 [11] Boumahni B, Randrianivo H, Flodrops H, Kauffmann E, Sauve F, Chauvet O, Renouil M, Fourmaintraux
161 A. [Maternal toxoplasmosis before conception and chorioretinitis in twin sisters]. *J Gynecol Obstet Biol
162 Reprod (Paris)*. 2004;33(3):248–50.
- 163 [12] Vogel N, Kirisits M, Michael E, Bach H, Hostetter M, Boyer K, Simpson R, Holfels E, Hopkins J, Mack
164 D, Mets MB, Swisher CN, Patel D, Roizen N, Stein L, Stein M, Withers S, Mui E, Egwuagu C,
165 Remington J, Dorfman R, McLeod R. Congenital toxoplasmosis transmitted from an immunologically
166 competent mother infected before conception. *Clin Infect Dis.* 1996;23(5):1055–60.
- 167 [13] Marty P, Le Fichoux Y, Deville A, Forest H. [Congenital toxoplasmosis and preconceptional maternal
168 ganglionic toxoplasmosis]. *Presse Med.* 1991;20(8):387.
- 169 [14] Chemla C, Villena I, Aubert D, Hornoy P, Dupouy D, Leroux B, Bory JP, Pinon JM. Preconception
170 seroconversion and maternal seronegativity at delivery do not rule out the risk of congenital
171 toxoplasmosis. *Clin Diagn Lab Immunol.* 2002;9(2):489–90.
- 172 [15] Alavi SM, Alavi L. Treatment of toxoplasmic lymphadenitis with co-trimoxazole: double-blind,
173 randomized clinical trial. *Int J Infect Dis.* 2010;14 Suppl 3:e67-69.
- 174 [16] Giakoumelou S, Wheelhouse N, Cuschieri K, Entrican G, Howie SEM, Horne AW. The role of infection
175 in miscarriage. *Hum Reprod Update.* 2016;22(1):116–33.

176

177

178

179

180

181 TABLE

Table 1. Biological results

Assay performed	11/29/2017	04/04/2018	08/18/2018	09/07/2018	09/13/2018	09/24/2018	11/14/2018
IgG (IU/mL)	< 0.5 ^a	194.9	732.3	1362.3	n/a	1350.9	1096.2
IgG avidity	n/a	5.04%	38.10%	n/a	n/a	n/a	n/a
IgM (index)	0.37 ^b	15.38	4.74	3.04	n/a	3.87	5.01
IgA (index)	n/a	4.2	3	n/a	n/a	n/a	n/a
PCR (products of conception)	n/a	n/a	n/a	n/a	Positive	n/a	n/a
PCR (patient's blood)	n/a	n/a	n/a	n/a	n/a	Negative	n/a

IgG (Architect®, Abbott Laboratories): negative < 1.6 ; equivocal 1.6 - 2.9 ; positive ≥ 3

IgG avidity (Architect®, Abbott Laboratories): ≥ 60% → past infection > 4 months ago

IgM (Architect®, Abbott Laboratories): negative < 0.50 ; equivocal 0.50 - 0.59 ; positive ≥ 0.60

IgA (Platelia™, Bio-Rad): negative < 0.8 ; equivocal 0.8 - 1 ; positive ≥ 1

^a **IgG** (ADVIA Centaur®, Siemens): negative < 6.4 ; equivocal 6.4 - 9.9 ; positive ≥ 10

^b **IgM** (ADVIA Centaur®, Siemens): negative < 0.9 ; equivocal 0.90 - 0.99 ; positive ≥ 1

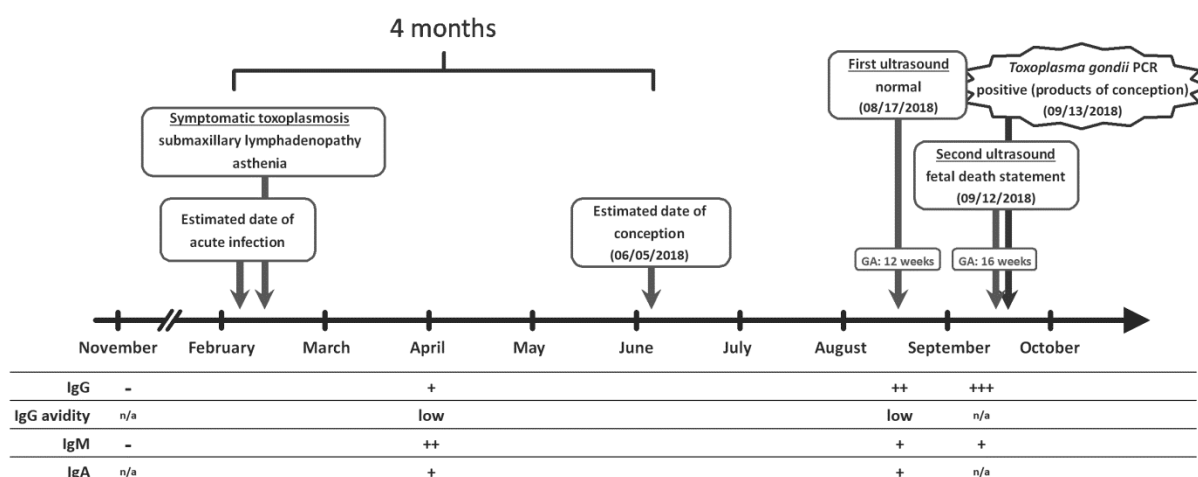
n/a: not available

182

183

184

185 FIGURE



186

187

Figure 1: Timeline of the events and important serological findings

188

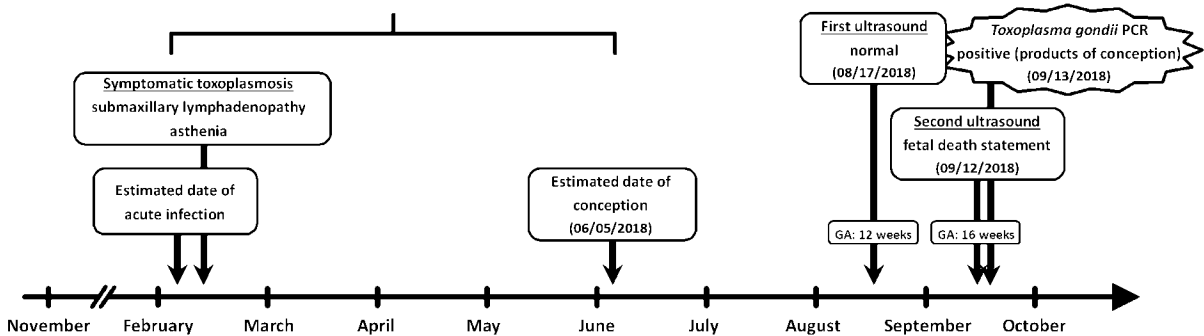
189 LEGENDS

190 **Table 1:** Biological results

191 **Figure 1:** Timeline of the events and important serological findings (serological results are expressed

192 qualitatively according to the cut-offs of the tests described in Table 1; GA: Gestational age; n/a: not available)

4 months



IgG	-	+	++	+++
IgG avidity	n/a	low	low	n/a
IgM	-	++	+	+
IgA	n/a	+	+	n/a