



BONE PERFUSION AND ADIPOSITY BEYOND THE NECROTIC ZONE IN FEMORAL HEAD OSTEONECROSIS: A QUANTITATIVE MRI STUDY

Aurélie Cultot, Laurène Norberciak, Raphaël Coursier, Sophie Putman, Bernard Cortet, Julien Paccou, Tristan Pascart, Jean-François Budzik

► To cite this version:

Aurélie Cultot, Laurène Norberciak, Raphaël Coursier, Sophie Putman, Bernard Cortet, et al.. BONE PERFUSION AND ADIPOSITY BEYOND THE NECROTIC ZONE IN FEMORAL HEAD OSTEONECROSIS: A QUANTITATIVE MRI STUDY. *European Journal of Radiology*, 2020, 131, pp.109206 -. 10.1016/j.ejrad.2020.109206 . hal-03491522

HAL Id: hal-03491522

<https://hal.science/hal-03491522>

Submitted on 30 Aug 2022

HAL is a multi-disciplinary open access archive for the deposit and dissemination of scientific research documents, whether they are published or not. The documents may come from teaching and research institutions in France or abroad, or from public or private research centers.

L'archive ouverte pluridisciplinaire **HAL**, est destinée au dépôt et à la diffusion de documents scientifiques de niveau recherche, publiés ou non, émanant des établissements d'enseignement et de recherche français ou étrangers, des laboratoires publics ou privés.



Distributed under a Creative Commons Attribution - NonCommercial 4.0 International License

BONE PERFUSION AND ADIPOSITY BEYOND THE NECROTIC ZONE IN FEMORAL HEAD OSTEONECROSIS: A QUANTITATIVE MRI STUDY

FEMORAL HEAD OSTEONECROSIS: A Q-MRI STUDY

**Aurélie Cultot ¹, MD, Laurène Norberciak ², Raphaël Coursier ³, MD, PhD,
Sophie Putman⁴, MD, Bernard Cortet ^{5,6}, MD, PhD, Julien Paccou ^{5,6}, MD, PhD,
Tristan Pascart ^{6,7}, MD, PhD, Jean-François Budzik ^{1,6}, MD, PhD**

¹ Diagnostic and interventional imaging department, Lille Catholic University Hospital Group, Lille, France

² Biostatistics, Clinical research department, Lille Catholic University Hospital Group, Lille, France

³ Orthopaedic surgery department, Lille Catholic University Hospital Group, Lille, France

⁴ Orthopaedic surgery department, Roger Salengro hospital, Lille University Hospital, France

⁵ Rheumatology department, Roger Salengro hospital, Lille University Hospital, France

⁶ UR 4490 - PMOI - PMOI (Physiopathologie des Maladies Osseuses Inflammatoires)/MABLab (Marrow Adiposity and Bone Laboratory), Lille, France

⁷ Rheumatology department, Lille Catholic University Hospital Group, Lille, France

Corresponding Author: Jean-François BUDZIK, MD, PhD

Budzik.jean-francois@ghicl.net

Service d'imagerie médicale
Hôpital Saint Vincent de Paul
Boulevard de Belfort
Lille, France

Authors list

Aurélie Cultot, MD
aurelie.cultot@gmail.com

Service d'imagerie médicale diagnostique et interventionnelle
Groupement des Hôpitaux de l'Institut Catholique de Lille
Hôpital Saint Vincent de Paul
Boulevard de Belfort
59000 Lille, France

Laurène Norberciak

Norberciak.laurene@ghicl.net

Direction de la Recherche et de l'Innovation
Groupement des Hôpitaux de l'Institut Catholique de Lille
Hôpital Saint Philibert
Rue du Grand But
59160 Lomme, France

Raphaël Coursier, MD, PhD

Coursier.rafael@ghicl.net
Service de chirurgie orthopédique
Groupement des Hôpitaux de l'Institut Catholique de Lille
Hôpital Saint Vincent de Paul
Boulevard de Belfort
59000 Lille, France

Sophie Putman, MD

sophie.putman@chru-lille.fr
Service d'Orthopédie,
Hôpital Roger-Salengro,
Centre hospitalier régional universitaire de Lille
Place de Verdun, 59037 Lille, France

Bernard Cortet, MD, PhD

Bernard.cortet@chru-lille.fr

Service de Rhumatologie,
Centre hospitalier régional universitaire de Lille
Place de Verdun, 59037 Lille, France

UR 4490 - PMOI - PMOI (Physiopathologie des Maladies Osseuses
Inflammatoires)/MABLab (Marrow Adiposity and Bone Laboratory), Lille, France
Faculté de chirurgie dentaire, 59000 Lille, France

Julien Paccou, MD, PhD

julien.paccou@chru-lille.fr

Service de Rhumatologie,
Centre hospitalier régional universitaire de Lille
Place de Verdun, 59037 Lille, France

UR 4490 - PMOI - PMOI (Physiopathologie des Maladies Osseuses Inflammatoires)/MABLab (Marrow Adiposity and Bone Laboratory), Lille, France
Faculté de chirurgie dentaire, 59000 Lille, France

Tristan Pascart, MD, PhD

Pascart.tristan@ghicl.net

Service de Rhumatologie
Groupement des Hôpitaux de l'Institut Catholique de Lille
Hôpital Saint Philibert
Rue du Grand But
59160 Lomme, France

UR 4490 - PMOI - PMOI (Physiopathologie des Maladies Osseuses Inflammatoires)/MABLab (Marrow Adiposity and Bone Laboratory), Lille, France
Faculté de chirurgie dentaire, 59000 Lille, France

Jean-François Budzik, MD, PhD

Budzik.jean-francois@ghicl.net

Service d'imagerie médicale diagnostique et interventionnelle
Groupement des Hôpitaux de l'Institut Catholique de Lille
Hôpital Saint Vincent de Paul
Boulevard de Belfort
59000 Lille, France

UR 4490 - PMOI - PMOI (Physiopathologie des Maladies Osseuses Inflammatoires)/MABLab (Marrow Adiposity and Bone Laboratory), Lille, France
Faculté de chirurgie dentaire, 59000 Lille, France

Declarations of interest

None

Fundings

This research did not receive any specific grant from funding agencies in the public, commercial, or not-for-profit sectors.

ABSTRACT

Purpose: To describe bone perfusion and adiposity beyond the necrotic zone with quantitative MRI techniques in osteonecrosis of the femoral head (ONFH).

Method: In this cross-sectional multicentre study, we recruited patients suffering from late-stage ONFH or hip osteoarthritis. Hip MRI included quantitative MRI sequences: chemical-shift imaging and dynamic contrast-enhanced MRI. We drew regions of interest inside the necrotic zone (inner necrosis and its border) and outside (femoral head, neck and greater trochanter) in ONFH. In the control group, regions of interest were drawn in the femoral head, femoral neck and the greater trochanter. For each region of interest, we measured fat fraction, and calculated semi-quantitative (area under the curve, initial slope) and pharmacokinetic perfusion parameters (K_{trans} and K_{ep}).

Results: Thirty-two male adults (mean age 58 ± 9 years, range 38–74 years) were included. Sixteen patients formed the ONFH group and fifteen the control group; one was excluded. In the normal-appearing non-necrotic part of the femoral head, fat fraction was not significantly different in comparison with controls ($p=1$), but K_{trans} was significantly lower than in controls (0.012 ± 0.018 vs. 0.027 ± 0.045 ; $p=0.05$). This perfusion parameter reflects exchanges between blood microvessels and bone marrow.

Conclusions: Our results question the concept of adipose toxicity on the macroscopic scale, and bring up the concept of regional ischemic penumbra that goes beyond the visible necrotic zone. Further studies are required to test these hypotheses in larger populations and earlier disease states.

KEYWORDS

Femoral head osteonecrosis; Dynamic contrast-enhanced magnetic resonance imaging; Chemical Shift Imaging; Bone marrow adiposity; Bone

ABBREVIATIONS

ONFH: Osteonecrosis of the femoral head

qMRI: quantitative magnetic resonance imaging

DCE-MRI: Dynamic Contrast Enhanced MRI

BM: bone marrow

INTRODUCTION

Femoral head osteonecrosis (ONFH) affects patients in their third to fifth decades and often leads to total hip replacement. Its early evolution is silent, which explains incidental findings on hip imaging examinations. Articular surface collapse is the breakpoint in the course of this disease. If limited, joint-preserving procedures such as core decompression combined with autologous bone marrow (BM) stem cells transplantation can be performed. If extended, or if joint-preserving procedures fail, total hip arthroplasty must be performed [1].

ONFH management is challenging, particularly because its pathogenesis is not understood. Currently the main theories being studied are insufficient blood supply, lipid metabolism disorder, inflammation, genetics, and decreased osteogenesis potential of BM mesenchymal stem cells [2]. Within this multiple-hit theory, the two main actors seem to be BM adiposity and blood supply.

Insufficient blood supply is the intuitive explanation for osteonecrosis. MRI clearly depicts a well-demarcated zone that reaches bone surface in all points, which makes it concordant with a terminal vascularization failure. The thing is that normal femoral head micro-vascularization is far from being well-known, mainly because invasive methods were required until recently [3]. Dynamic contrast enhanced magnetic resonance imaging (DCE-MRI) is a non-invasive tool used to study bone perfusion. It is feasible on clinical MRIs and can be included in clinical protocols. Its main limits are complex post-processing procedures and spatial resolution (as fast acquisitions are required on large structures). DCE-MRI was recently reported in hip bone studies [3–5].

Adipose toxicity has been known as suspect in ONFH for the last three decades.

Two complementary mechanisms are proposed: a mechanical invasion of BM

adiposity and a local increase in pro-inflammatory adipokines [6]. The mechanical invasion of adipose tissue could explain fat embolism within the microvessels, and also BM fat accumulation with enlarged adipocytes, leading to increased medullar hypertension, further worsening ischemia by collapsing microvessels and decreasing blood flow [2,7]. BM adiposity content can be non-invasively assessed with chemical shift imaging, which can be implemented on clinical MRIs. Acquisition is fast and image analysis is straightforward. It provides global fat fraction within a given volume, but cannot detail adipose content, as magnetic resonance spectroscopy does [8]. Evidence merges towards primitive BM responsibility, as a recent Raman spectroscopy study demonstrated that trabecular bone mineral and biochemical properties are not altered within necrotic bone [9]. The authors found necrotic cells far beyond the identified necrotic zone borders on MRI, which suggests that ONFH implies regional changes in the proximal femur, not only in the necrotic zone that is visible on imaging or macroscopic studies.

Exploring better the suspected main actors of ONFH – BM adiposity and blood supply – is a pre-requisite for improving understanding of ONFH pathogenesis and its assessment. We designed this study to use DCE-MRI and chemical shift imaging, two quantitative MRI (qMRI) techniques, to assess BM changes related to ONFH. Our main objective was to describe bone perfusion and adiposity beyond the necrotic zone with qMRI techniques.

MATERIALS AND METHODS

Ethical concerns

This cross-sectional multicentric study was authorized by our local Ethics Committee (*blinded*) and declared to the Clinical Trials registry (*blinded*). All procedures

performed were in accordance with the 1964 Helsinki Declaration and its later amendments or comparable ethical standards. Informed consent was obtained from all individual participants included in the study.

Study subjects

We prospectively recruited adult patients from our orthopaedic surgery departments or outpatient clinics (*blinded*) that needed total hip replacement surgery for either ONFH or osteoarthritis (OA) with a maximal age of 70 years. The inclusion period lasted from April 2016 to September 2017. Inclusion was restricted to males in order to avoid potential bias related to known gender differences in BM adiposity and perfusion [4,10], which would have been difficult to manage regarding group sizes. For ONFH, the inclusion criteria were radiographic FICAT stage III or stage IV [11] from non-traumatic causes including only alcohol abuse, steroid therapy and idiopathic ONFH, with a surgical indication for total hip replacement. As changes related to secondary OA could constitute a bias in the interpretation of our results, we chose patients suffering from primary OA as a control group. In this group, the inclusion criteria were radiographic Kellgren-Lawrence stage III or IV [12], with a surgical indication for total hip replacement.

To avoid potential pathological changes of the BM, we applied several non-inclusion criteria. The patients were not included if they reported any of the following: neoplastic or haematological disease, osteoporosis or osteopenia, a history of hip fracture.

We collected the following clinical data: age, gender, body mass index, alcohol consumption and current corticosteroid treatment.

MRI protocol

Patients were examined on a 1.5-T MR scanner Optima MR 450W Gem (General Electric Healthcare, Milwaukee, IL) in supine position, using a body coil. The right antecubital vein was catheterized.

The MR protocol included 3D T1-weighted, chemical shift imaging and DCE sequences. Left or right hip was imaged, depending on which had to benefit from surgery.

The 3D T1-weighted sequence covered the pelvis with 256 slices acquired in the coronal plane. Time of repetition was 440ms and TE was 14ms. Field of view was 410 x 410mm, matrix was 352 x 320, and slice thickness was 1.6 mm resulting in acquired 1.2 x 1.3 x 1.6 mm voxels. Parallel imaging (autocalibrating reconstruction for cartesian imaging) was used with an acceleration factor of 2. Acquisition time was 4 min 45.

The chemical shift imaging was a DIXON sequence (IDEAL IQ, General Electric brand name). 104 images were acquired in the coronal plane. Slice thickness was 5mm. Field of view was 400 x 400 mm, matrix was 256 x 256, resulting in an acquired in-plane 1.56 x 1.56 mm resolution. Time of repetition was 14.5ms and TE was set as minimal. Flip angle was 7°, echo train length was 6, bandwidth was 100 Hz per pixel, parallel imaging acceleration factor was 2, and number of excitations was 1.5. Acquisition time was 6 min 15.

DCE was a high spatio-temporal resolution technique, referred to as DISCO (differential sub-sampling with cartesian ordering), which combines a dual-echo spoiled gradient echo sequence with pseudo-random variable density k-space segmentation. This dynamic sequence included 25 phases that is to say 25 repeated 3D acquisitions. Each acquisition was acquired in 15 seconds (which defines

temporal resolution), for a total of 6 min 25. For each dynamic, 120 slices were acquired in the coronal plane. Field of view was 230 x 230 mm, matrix was 180 x 160, slice thickness was 2mm, and frequency-encoding direction was cranio-caudal. Acquired voxel size was 1.3 x 1.4 x 2mm. Time of repetition was 6.2 ms, TE was set as minimal, flip angle was 15°, bandwidth was 50 Hz per pixel, and parallel imaging acceleration factor was 2.2.

Five baseline volumes were acquired. At the beginning of the sixth scan, a 0.1 mmol/kg infusion of gadoteric acid (DOTAREM, Guerbet, France) was injected at a rate of 2.5 ml/s followed by a 20 cm³ saline flush. Twenty dynamic scans were collected.

Total acquisition time was about 20 minutes (including sequence calibration, shimming time and injection).

Post-processing

A junior MSK radiologist (*blinded*) analysed T1-weighted and DIXON images on our PACS workstation (Carestream, Rochester, NY, USA), and post-processed DCE-MRI using DCE-Tool software (Kyung Sung, Body MRI research group, Stanford University, CA, USA) on an OsiriX DICOM workstation, using a method previously described [4,13], under the supervision of a senior MSK radiologist (*blinded*).

In ONFH patients, regions of interest (ROIs) were drawn as shown in figure 1, following a reproducible method used in previous studies [3]. The low intensity line visible on T1 images defined the necrotic zone. The necrotic zone was identified as ‘white necrosis’ – “mummified” according to the literature description [14] – if the BM T1 signal intensity was identical or close to that of non-necrotic BM, and ‘black necrosis’ if its T1 signal intensity was clearly inferior. To avoid bias related to the

different perfusion properties of red and yellow BM in the proximal femur [3], as well as perfusion changes related to BM oedema [13], all selected ROIs were carefully positioned in areas of yellow BM identified on T1-weighted images, to exclude oedema or red BM. Five ROIs were drawn in trabecular bone in ONFH patients: two inside the necrotic bone (necrotic border, necrosis), and three outside the necrotic bone (femoral head, femoral neck and greater trochanter). In patients in whom black and white necrosis coexisted, one ROI was drawn in each type of necrosis. In OA patients, three ROIs were drawn in normal-appearing bone (femoral head, femoral neck and greater trochanter).

For each ROI, BM fat content was measured on the “fat fraction” reconstruction issued from DIXON images. For DCE, we measured two semi-quantitative parameters (area under the curve, AUC, and initial slope, IS) and two pharmacokinetic parameters (transfer constant, K_{trans} , and rate constant, K_{ep}). AUC and IS describe the time-concentration curve. AUC reflects tissue blood flow, vascular permeability, and the fractional interstitial space. IS reflects initial tissular gadolinium uptake [15]. K_{trans} is the volume transfer constant between blood plasma and the extravascular extra-cellular space and K_{ep} is the rate constant between the extravascular extracellular space and blood plasma [16].

Statistical analyses

All statistical analyses were performed using R version 3.4.2. Quantitative variables are described by the mean \pm standard deviation. ONFH and OA clinical characteristics were compared using Student's t test for normal continuous data or Mann-Whitney-Wilcoxon test, and Chi-square test or Fisher's exact test as

appropriate for proportions. As age differed significantly between groups, multiple linear regressions were applied to compare perfusion parameters between groups adjusted on age, and also body mass index. The model validation was assessed graphically using the residuals (normality and homoscedasticity). When conditions were not satisfied even after log-transformation, permutation tests were implemented. This test consists of randomly switching groups, and calculating the statistics in the mixed model. This permutation was repeated up to 5 000 times, to estimate the distribution of the statistics under the null hypothesis of no differences between the groups (nullity of the group coefficient in the model). We then compared the statistics obtained on the initial data with this distribution and this made it possible to estimate p-values. These p-values were corrected using Holm's technique to avoid inflation of the α risk due to repeated comparisons within each parameter. As specific to incomplete blocks, Skillings-Mack test was used to compare ROIs within the ONFH group for each parameter because of the presence of missing values. As p-values were significant except for K_{ep} , Wilcoxon signed rank test was used to identify which 2-2 ROI differed significantly. As the test was repeated for each 2-2 comparison, Holm's technique as applied too to correct p-values within each parameter. Significance level was set at 5%.

RESULTS

Population

Thirty-two male adults (mean 58 ± 9 years, 38–74 years) were included. 23 patients were recruited at (*blinded*) hospital and 9 patients at (*blinded*) hospital. DCE-MRI was performed successfully in 31 of the 32 patients included. One ONFH patient was

excluded because metallic artefacts in the iliac bone impaired the analysis. Among the remaining 31 patients, 16 were in the ONFH group and 15 were in the OA group. The groups were not statistically different regarding all clinical data, but age: patients in the OA group were significantly older ($p=0,02$): mean age was 54 years (38–70) in the ONFH group versus 61 years (44–74) in the OA group. Further statistical analyses took this potential bias into consideration. Among 16 ONFH patients, 5 had a normal-appearing contralateral hip on MR. Other patients had either contralateral avascular necrosis or total hip replacement.

MRI

We present here the more significant results. Other analyses are detailed in tables 1 to 3.

Comparisons between ONFH and OA (table 1)

Perfusion parameters

In the normal-appearing non-necrotic part of the femoral head, mean K_{trans} values were significantly lower ($p=0.05$) in ONFH than in OA patients. On the contrary, perfusion parameters did not differ significantly in the neck or greater trochanter.

Fat fraction

In the normal-appearing part of the femoral head as in trabecular bone, fat fraction was not significantly different ($p=1$) between ONFH and OA patients: $86\% \pm 9$ versus $87\% \pm 9$ respectively.

Regional comparisons in ONFH patients (tables 2 and 3)

Perfusion parameters

In ONFH patients, AUC and K_{trans} values in the necrotic border were significantly higher than in the other zones: necrosis and non-necrotic femoral head, neck and greater trochanter ($p=0.0215$, $p=0.0199$, $p=0.0102$, and $p=0.0023$ respectively).

Fat fraction

In ONFH patients, fat fraction was significantly lower inside the necrotic zone than outside, in normal-appearing BM, whether in black or white necrosis ($p<0.0088$ and $p<0.0312$ respectively). In ONFH patients, fat fraction values were significantly higher in the greater trochanter than in the femoral head and the femoral neck.

DISCUSSION

We found that beyond the necrotic zone, femoral head perfusion is altered in ONFH patients although BM adiposity is not, in comparison with OA patients. These results would put into question the concept of “adipose toxicity” in ONFH and raise the hypothesis of a regional ischemic penumbra.

Regional ischemic penumbra

Changes in BM perfusion outside the necrotic zone, identified on T1 sequences, suggest that the ischemic phenomenon is not restricted to the visible necrosis.

In comparison with OA patients, K_{trans} values in ONFH patients are significantly lower within the extra-necrotic part of the femoral head. This suggests that vascular

permeability decreases, that is to say that exchanges between blood and BM are altered. A previous study has already described changes in the BM perfusion of the proximal femur in ONFH [17]. The comparison with our study is limited as the authors essentially reported changes in semi-quantitative parameters, the ones that describe the gadolinium concentration – time curve. Yet, these results could be in accordance with ours as the authors interpret their results as a potential vascular stasis within the bone, which could be a consequence of impaired exchanges between blood and BM. One might draw a parallel with stroke: in acute brain ischemia, the phenomenon of ischemic penumbra and mismatch are well known. Indeed, MRI clearly shows the geographic limits of the brain ischemic zone on diffusion sequences, which identifies the consequences of cytotoxic oedema. From there, radiologists took interest in brain perfusion, and they discovered that the under-perfused area could be far more important than what is seen on diffusion sequences. This constitutes the concept of mismatch: albeit a brain area is clearly in metabolic breakdown, a wider one is in a state of ischemia. In equivocal situations, the importance of this mismatch can drive therapeutic decisions [18]. The common points between stroke and ONFH are a terminal vasculature and a precise limit of the corrupted zone. Applying this concept in ONFH would have an impact on management practices, as the assessment of the local extent of the disease is decisive for the choice and success of conservational procedures [19,20].

BM adipose toxicity

The absence of significant changes in BM adiposity put into question the concept of BM adiposity intoxication. Indeed, while vascular perfusion differed, no significant changes in fat fraction were found in femoral head non-necrotic areas in ONFH

patients in comparison with the same zones in OA patients. These results put into question the generally accepted hypothesis of extrinsic vascular compression in bone induced by increased BM adipose volume responsible for ischemia-driven necrosis [21]. This hypothesis relies mainly on imaging studies and animal studies. A rabbit model of ONFH showed that adipocyte number and volume increased as far as the proximal femur [22], although the question of whether animal models reproduce the same ONFH as in humans is highly debated. In humans, evidence reported in histological and biochemical studies [6,7] goes beyond the scope of our observations: we do not question the concept on a microscopic, but on a macroscopic scale. Indeed, in our opinion, the interpretations based on the rather scarce previous imaging studies are debatable. One study reported that metaphyseal (femoral neck) marrow fat content was increased in ONFH patients compared with controls [23]. Another study assessed baseline femoral neck marrow fat content in patients treated by corticosteroids, and reported that this content was higher in patients who developed ONFH during a 12-month follow-up [24]. These studies are limited by the visual assessment of fat content, or by bulk T1 signal measurements, that is to say by the lack of quantitative assessment of marrow fat content. The second study is also limited by the number of subjects: 4 ONFH versus 16 controls [24]. These studies describe correlations and therefore do not demonstrate causality. It is interesting to notice that similar differences in BM fat content have been reported in patients suffering from transient BM oedema compared with controls [25]: the differences in BM fat content that were identified with non-quantitative methods might not be specific of ONFH. Finally, recent anatomical studies of femoral head vasculature demonstrated that vessels penetrate the femoral head at the cervico-

cephalic junction, and therefore cannot be compressed in the femoral neck, were it infiltrated by fat [26].

Expectable results regarding literature

Aside from these two points, we report expectable results that do not add to the understanding of ONFH pathophysiology. Yet, they support the validity of our measurements.

First, mean fat fraction values were higher in the greater trochanter than in the femoral head and neck, both in ONFH and OA patients. This is related to the well-known different proportion of red and yellow marrow fat [3], this latter being nearly exclusive in the greater trochanter [10]. Higher standard deviations in the femoral necks (table 1) are likely related to higher red BM proportion in this area [10], even though we avoided areas of visible red BM.

Second, perfusion was significantly higher in the necrotic border: increased AUC and K_{trans} values. This is concordant with the increased metabolic activity related to bone repair attempt, also a well-known finding [9].

Third, fat content was significantly lower in the sclerotic and dark necrosis zones compared with the adjacent trabecular bone. This can be explained by the regenerating processes and by adipocyte necrosis respectively [9].

Limitations

We acknowledge several limitations.

First, our population. Our sample subjects had late-stage ONFH because they were eligible for total hip replacement. This is because our patients were included in a larger study in which femoral heads were harvested after total hip replacement for

further analysis. Consequently, we acknowledge that our study does not reflect the full pathogenesis of ONFH, as bone fat content may not remain static from early to late disease. For the same reason, the number of subjects is limited (16 ONFH and 15 OA), which may have limited the power of our statistical analysis. Yet, this population is larger [24] (or in the same range) than previous imaging studies on ONFH [17,23]. Also, our population was restricted to males, for reasons explained in the methods section. Thus we do not know if our results can be extrapolated in females. Finally, we did not compare our values with data from the literature, as no references values exist: previous studies report the influence of age, sex, body mass index [4], and acquisition protocols or post-processing methods [27]; moreover different perfusion parameters are reported depending on the software [28,29]. For example, AUC values from a previous study including 59 patients [4] were in the same range as those from our study, but cannot be compared as subjects were younger, sex ratio was different, and MRI scanner and field strength were not the same.

Second, our control group. We would have liked to compare the fat content in osteonecrotic femoral heads with that in contralateral normal-appearing femoral heads. Unfortunately, only five out of our 16 patients were in this situation: 11 out of 16 had either contralateral osteonecrosis or hip prosthesis. We did not perform such measurements because of predictable insufficient statistical power. Also, we chose not to use healthy controls because we identified secondary OA changes as a confounding factor.

Third, our methodological choices. We assessed the fat fraction within each zone with chemical shift imaging. This overall evaluation gives no clue on lipid changes, which would have required MR spectroscopy. We chose not to include this sequence

in our protocol to limit acquisition time in patients who were frequently suffering from pain. Yet, chemical shift imaging is known as an adequate alternative to MR spectroscopy in clinical research [30]. Also, we focused on areas of predominant visible yellow marrow (more intense signal on T1-weighted images) which is less perfused than red marrow [3]. This was intended to avoid subtle perfusion changes to be occulted by red marrow or BM oedema. The drawback is that mean perfusion parameters values are smaller overall and thus standard deviation values are higher. Finally, although we discuss two hypotheses, one must keep in mind that we report a correlation in a case-control study, which does not constitute a proof of causality.

Conclusion

We report an in vivo assessment of BM adiposity and perfusion in end-stage ONFH patients compared with OA patients. Our results question the concept of adipose toxicity on the macroscopic scale, and bring up the concept of regional ischemic penumbra that goes beyond the visible necrotic zone. Further studies are required to test these hypotheses in larger populations, particularly with a longitudinal study focused on early-stage patients, and to determine whether the extent of this penumbra is clinically meaningful.

BIBLIOGRAPHY

- [1] A. Cohen-Rosenblum, Q. Cui, Osteonecrosis of the Femoral Head, *Orthop. Clin. North Am.* 50 (2019) 139–149. <https://doi.org/10.1016/j.ocl.2018.10.001>.
- [2] A. Wang, M. Ren, J. Wang, The pathogenesis of steroid-induced osteonecrosis of the femoral head: A systematic review of the literature, *Gene*. 671 (2018) 103–109. <https://doi.org/10.1016/j.gene.2018.05.091>.
- [3] J.-F. Budzik, G. Lefebvre, G. Forzy, M. El Rafei, D. Chechin, A. Cotten, Study of proximal femoral bone perfusion with 3D T1 dynamic contrast-enhanced MRI: a feasibility study, *Eur. Radiol.* 24 (2014) 3217–3223. <https://doi.org/10.1007/s00330-014-3340-5>.
- [4] J.-F. Budzik, G. Lefebvre, H. Behal, S. Verclytte, P. Hardouin, P.A.G. Teixeira, A. Cotten, Bone marrow perfusion measured with dynamic contrast enhanced magnetic resonance imaging is correlated to body mass index in adults., *Bone*. 99 (2017) 47–52. <https://doi.org/10.1016/j.bone.2017.03.048>.
- [5] J.-F. Budzik, G. Lefebvre, H. Behal, S. Verclytte, P. Hardouin, P. Teixeira, A. Cotten, Assessment of the zonal variation of perfusion parameters in the femoral head: a 3-T dynamic contrast-enhanced MRI pilot study, *Skeletal Radiol.* 47 (2018) 261–270. <https://doi.org/10.1007/s00256-017-2802-7>.
- [6] C. Gillet, A. Dalla Valle, N. Gaspard, D. Spruyt, P. Vertongen, J. Lechanteur, S. Rigutto, E.-R. Dragan, A. Heuschling, V. Gangji, J. Rasschaert, Osteonecrosis of the Femoral Head: Lipotoxicity Exacerbation in MSC and Modifications of the Bone

Marrow Fluid, *Endocrinology*. 158 (2017) 490–502. <https://doi.org/10.1210/en.2016-1687>.

[7] G. Motomura, T. Yamamoto, K. Miyanishi, A. Yamashita, K. Sueishi, Y. Iwamoto, Bone marrow fat-cell enlargement in early steroid-induced osteonecrosis--a histomorphometric study of autopsy cases, *Pathol. Res. Pract.* 200 (2005) 807–811. <https://doi.org/10.1016/j.prp.2004.10.003>.

[8] V. Singhal, M.A. Bredella, Marrow adipose tissue imaging in humans, *Bone*. 118 (2019) 69–76. <https://doi.org/10.1016/j.bone.2018.01.009>.

[9] T. Pascart, G. Falgayrac, H. Migaud, J.-F. Quinchon, L. Norberciak, J.-F. Budzik, J. Paccou, A. Cotten, G. Penel, B. Cortet, Region specific Raman spectroscopy analysis of the femoral head reveals that trabecular bone is unlikely to contribute to non-traumatic osteonecrosis, *Sci. Rep.* 7 (2017) 97. <https://doi.org/10.1038/s41598-017-00162-3>.

[10] V. Pansini, A. Monnet, J. Salleron, P. Hardouin, B. Cortet, A. Cotten, 3 Tesla (1) H MR spectroscopy of hip bone marrow in a healthy population, assessment of normal fat content values and influence of age and sex, *J. Magn. Reson. Imaging JMRI*. 39 (2014) 369–376. <https://doi.org/10.1002/jmri.24176>.

[11] R.P. Ficat, Idiopathic bone necrosis of the femoral head. Early diagnosis and treatment, *J. Bone Joint Surg. Br.* 67 (1985) 3–9.

[12] A. Guermazi, D. Hayashi, F.W. Roemer, D.T. Felson, Osteoarthritis, *Rheum. Dis. Clin. N. Am.* 39 (2013) 567–591. <https://doi.org/10.1016/j.rdc.2013.02.001>.

[13] J.-F. Budzik, J. Ding, L. Norberciak, T. Pascart, H. Toumi, S. Verclytte, R. Coursier, Perfusion of subchondral bone marrow in knee osteoarthritis: A dynamic contrast-enhanced magnetic resonance imaging preliminary study, *Eur. J. Radiol.* 88 (2017) 129–134. <https://doi.org/10.1016/j.ejrad.2016.12.023>.

- [14] A.H. Karantanas, E.E. Drakonaki, The role of MR imaging in avascular necrosis of the femoral head, *Semin. Musculoskelet. Radiol.* 15 (2011) 281–300. <https://doi.org/10.1055/s-0031-1278427>.
- [15] T.E. Yankeelov, J.C. Gore, Dynamic Contrast Enhanced Magnetic Resonance Imaging in Oncology: Theory, Data Acquisition, Analysis, and Examples, *Curr. Med. Imaging Rev.* 3 (2009) 91–107. <https://doi.org/10.2174/157340507780619179>.
- [16] P.S. Tofts, G. Brix, D.L. Buckley, J.L. Evelhoch, E. Henderson, M.V. Knopp, H.B. Larsson, T.Y. Lee, N.A. Mayr, G.J. Parker, R.E. Port, J. Taylor, R.M. Weisskoff, Estimating kinetic parameters from dynamic contrast-enhanced T(1)-weighted MRI of a diffusable tracer: standardized quantities and symbols, *J. Magn. Reson. Imaging JMRI.* 10 (1999) 223–232.
- [17] W.P. Chan, Y.-J. Liu, G.-S. Huang, M.-F. Lin, S. Huang, Y.-C. Chang, C.-C. Jiang, Relationship of idiopathic osteonecrosis of the femoral head to perfusion changes in the proximal femur by dynamic contrast-enhanced MRI, *AJR Am. J. Roentgenol.* 196 (2011) 637–643. <https://doi.org/10.2214/AJR.10.4322>.
- [18] S. Verclytte, O. Fisch, L. Colas, O. Vanaerde, M. Toledano, J.-F. Budzik, ASL and susceptibility-weighted imaging contribution to the management of acute ischaemic stroke, *Insights Imaging.* 8 (2017) 91–100. <https://doi.org/10.1007/s13244-016-0529-y>.
- [19] B. Mazieres, F. Marin, P. Chiron, L. Moulinier, J.-M. Amigues, M. Laroche, A. Cantagrel, Influence of the volume of osteonecrosis on the outcome of core decompression of the femoral head, *Ann. Rheum. Dis.* 56 (1997) 747–750. <https://doi.org/10.1136/ard.56.12.747>.

- [20] S. Nakasone, M. Takao, T. Sakai, T. Nishii, N. Sugano, Does the Extent of Osteonecrosis Affect the Survival of Hip Resurfacing?., *Clin. Orthop.* 471 (2013) 1926–1934. <https://doi.org/10.1007/s11999-013-2833-x>.
- [21] D.S. Hungerford, D.W. Lennox, The importance of increased intraosseous pressure in the development of osteonecrosis of the femoral head: implications for treatment, *Orthop. Clin. North Am.* 16 (1985) 635–654.
- [22] H. Sheng, C.-J. Sheng, X.-Y. Cheng, G. Zhang, K.-M. Lee, K.-S. Leung, S. Qu, L. Qin, Pathomorphological changes of bone marrow adipocytes in process of steroid-associated osteonecrosis, *Int. J. Clin. Exp. Pathol.* 6 (2013) 1046–1050.
- [23] K.H. Koo, R.G. Dussault, P.A. Kaplan, I.O. Ahn, R. Kim, M.J. Devine, Q. Cui, S.H. Cho, G.J. Wang, Fatty marrow conversion of the proximal femoral metaphysis in osteonecrotic hips, *Clin. Orthop.* (1999) 159–167. <https://doi.org/10.1097/00003086-199904000-00021>.
- [24] B.C. Vande Berg, R. Gilon, J. Malghem, F. Lecouvet, G. Depresseux, F.A. Houssiau, Correlation between baseline femoral neck marrow status and the development of femoral head osteonecrosis in corticosteroid-treated patients: a longitudinal study by MR imaging, *Eur. J. Radiol.* 58 (2006) 444–449. <https://doi.org/10.1016/j.ejrad.2006.01.009>.
- [25] S.-Y. Kim, K.-H. Koo, K.-T. Suh, Y.-S. Kim, Y.-J. Cho, B.-W. Min, Y.-C. Ha, J.-A. Choi, Fatty marrow conversion of the proximal femoral metaphysis in transient bone marrow edema syndrome, *Arch. Orthop. Trauma Surg.* 125 (2005) 390–395. <https://doi.org/10.1007/s00402-005-0824-4>.
- [26] P. Rego, V. Mascarenhas, D. Collado, A. Coelho, L. Barbosa, R. Ganz, Arterial Topographic Anatomy Near the Femoral Head-Neck Perforation with Surgical

Relevance:, J. Bone Jt. Surg. 99 (2017) 1213–1221.

<https://doi.org/10.2106/JBJS.16.01386>.

[27] T. Heye, E.M. Merkle, C.S. Reiner, M.S. Davenport, J.J. Horvath, S. Feuerlein, S.R. Breault, P. Gall, M.R. Bashir, B.M. Dale, A.P. Kiraly, D.T. Boll, Reproducibility of dynamic contrast-enhanced MR imaging. Part II. Comparison of intra- and interobserver variability with manual region of interest placement versus semiautomatic lesion segmentation and histogram analysis, *Radiology*. 266 (2013) 812–821. <https://doi.org/10.1148/radiol.12120255>.

[28] T. Geith, T. Niethammer, S. Milz, O. Dietrich, M. Reiser, A. Baur-Melnyk, Transient Bone Marrow Edema Syndrome versus Osteonecrosis: Perfusion Patterns at Dynamic Contrast-enhanced MR Imaging with High Temporal Resolution Can Allow Differentiation, *Radiology*. 283 (2017) 478–485. <https://doi.org/10.1148/radiol.2016152665>.

[29] D. Mueller, C. Schaeffeler, T. Baum, F. Walter, H. Rechl, E.J. Rummeny, K. Woertler, Magnetic resonance perfusion and diffusion imaging characteristics of transient bone marrow edema, avascular necrosis and subchondral insufficiency fractures of the proximal femur, *Eur. J. Radiol*. 83 (2014) 1862–1869. <https://doi.org/10.1016/j.ejrad.2014.07.017>.

[30] C.P. Bernard, G.P. Liney, D.J. Manton, L.W. Turnbull, C.M. Langton, Comparison of fat quantification methods: a phantom study at 3.0T, *J. Magn. Reson. Imaging JMRI*. 27 (2008) 192–197. <https://doi.org/10.1002/jmri.21201>.

TABLES

Table 1. Perfusion comparisons between ONFH and OA groups

Measured values are expressed as mean \pm SD. P-values are adjusted on age, body mass index and corrected by Holm technique. Significant p-value appears in bold characters. *In ONFH patients this measure concerns the normal-appearing BM within the femoral head, outside the necrotic zone.

AUC: area under the curve; IS: initial slope (both derived from gadolinium concentration – time curve), K_{trans} : transfer constant; K_{ep} : rate constant

ROI	Group	Fat Fraction	AUC	IS	K_{trans}	K_{ep}
Femoral head	ONFH*	86 \pm 9	4.6 \pm 4.4	1.1 \pm 2	0.012 \pm 0.018	0.59 \pm 0.97
	OA	87 \pm 7	4.4 \pm 1.4	0.6 \pm 0.5	0.027 \pm 0.045	0.47 \pm 0.54
		p = 1	p = 1	p = 1	p = 0.05	p = 1
Femoral neck	ONFH	82 \pm 17	5.2 \pm 2.9	1.4 \pm 1.4	0.021 \pm 0.03	1.01 \pm 1.36
	OA	78 \pm 14	6.8 \pm 3.7	1.8 \pm 2.5	0.044 \pm 0.063	0.91 \pm 1.13
		p = 1	p = 0.29	p = 0.59	p = 1	p = 1
Greater trochanter	ONFH	94 \pm 2	2.5 \pm 1.2	0.5 \pm 0.6	0.007 \pm 0.005	0.81 \pm 0.69
	OA	93 \pm 2	2.8 \pm 0.9	0.5 \pm 0.3	0.011 \pm 0.018	0.63 \pm 1
		p = 1	p = 1	p = 0.74	p = 1	p = 1

Table 2. Perfusion mean \pm standard deviation within the ONFH group

Measured values are expressed as mean \pm SD. * This measure concerns the normal-appearing BM within the femoral head, outside the necrotic zone.

ROI	Fat Fraction	AUC	IS	K _{trans}	K _{ep}
Black necrosis	13 \pm 5	13.2 \pm 16	2.9 \pm 4.7	0.052 \pm 0.054	0.32 \pm 0.29
White necrosis	61 \pm 18	4.6 \pm 4.3	0.8 \pm 1.1	0.017 \pm 0.031	0.65 \pm 0.87
Necrotic border	38 \pm 11	25.1 \pm 17.8	9.5 \pm 9.8	0.077 \pm 0.049	0.41 \pm 0.25
Normal femoral head*	86 \pm 9	4.6 \pm 4.4	1.1 \pm 2	0.012 \pm 0.018	0.59 \pm 0.97
Normal femoral neck	82 \pm 17	5.2 \pm 2.9	1.4 \pm 1.4	0.021 \pm 0.03	1.01 \pm 1.36
Normal greater trochanter	94 \pm 2	2.5 \pm 1.2	0.5 \pm 0.6	0.007 \pm 0.005	0.81 \pm 0.69

Table 3. Corrected p-values for 2-2 comparisons (by Holm technique) within ONFH group

Significant p-values appear in bold characters.

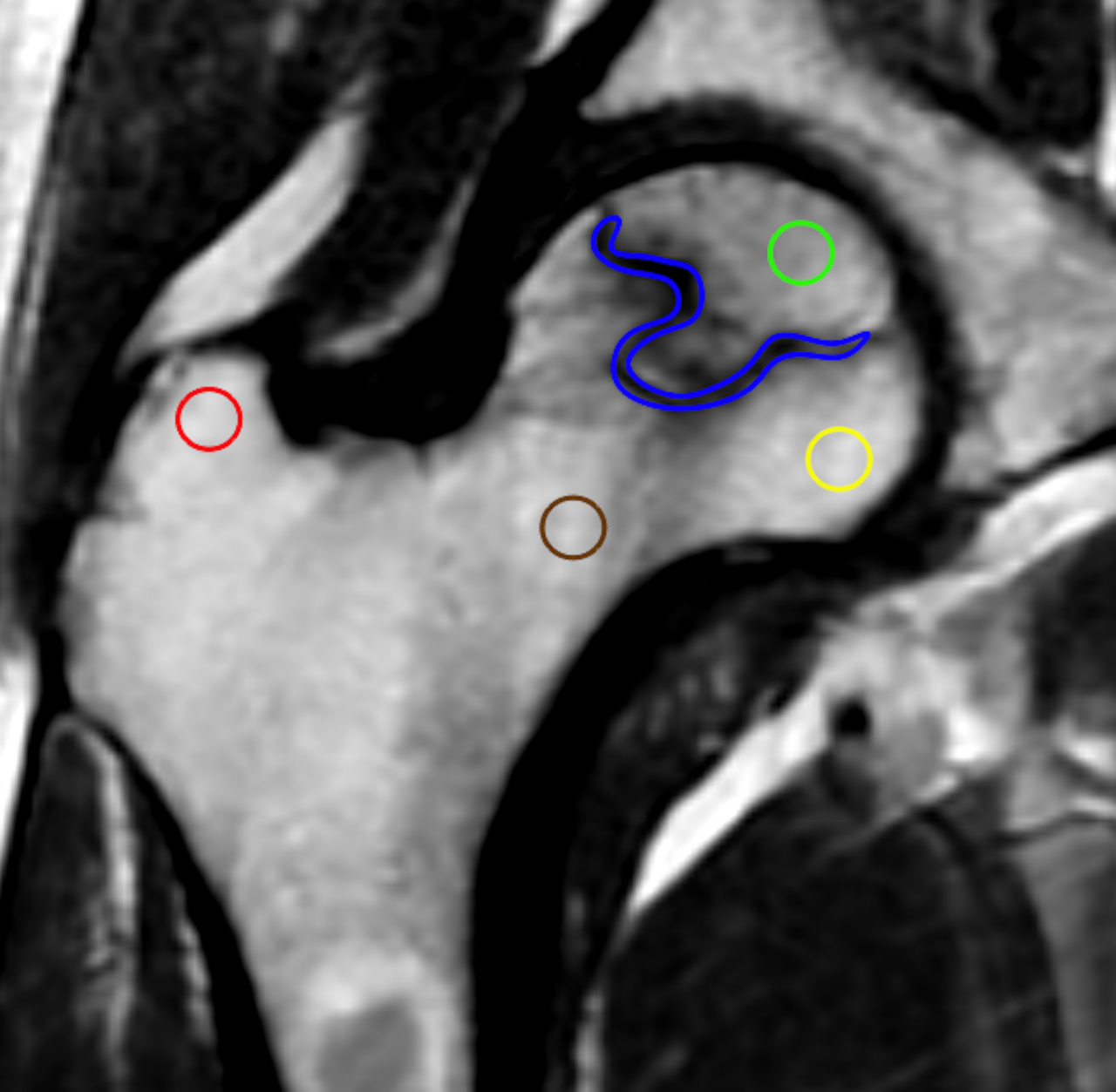
2-2 comparisons	Fat Fraction	AUC	IS	K _{trans}
Black vs white necrosis	0.0195	0.3125	0.3008	0.1953
Black necrosis vs necrotic border	0.0016	0.1824	0.0494	0.9686
Black necrosis vs normal femoral head	0.0088	0.9648	0.8311	0.6467
Black necrosis vs normal femoral neck	0.0016	0.9648	0.7148	0.8115
Black necrosis vs normal greater trochanter	0.0016	0.0525	0.104	0.2517
White necrosis vs necrotic border	0.0117	0.0215	0.001	0.0127
White necrosis vs normal femoral head	0.0312	1	0.7422	1
White necrosis vs normal femoral neck	0.0644	0.7373	0.3652	1
White necrosis vs normal greater trochanter	0.0088	0.7109	0.4131	1
Necrotic border vs normal femoral head	0.0024	0.0068	0.0024	0.0199
Necrotic border vs normal femoral neck	0.0005	0.0099	0.0021	0.0102
Necrotic border vs normal greater trochanter	0.0005	0.0023	0.0002	0.0005
Normal femoral head vs normal femoral neck	0.3757	0.9648	0.2734	0.3636
Normal femoral head vs normal greater trochanter	0.0315	0.7109	0.7353	1
Normal femoral neck vs normal greater trochanter	0.0088	0.0099	0.0041	0.1601

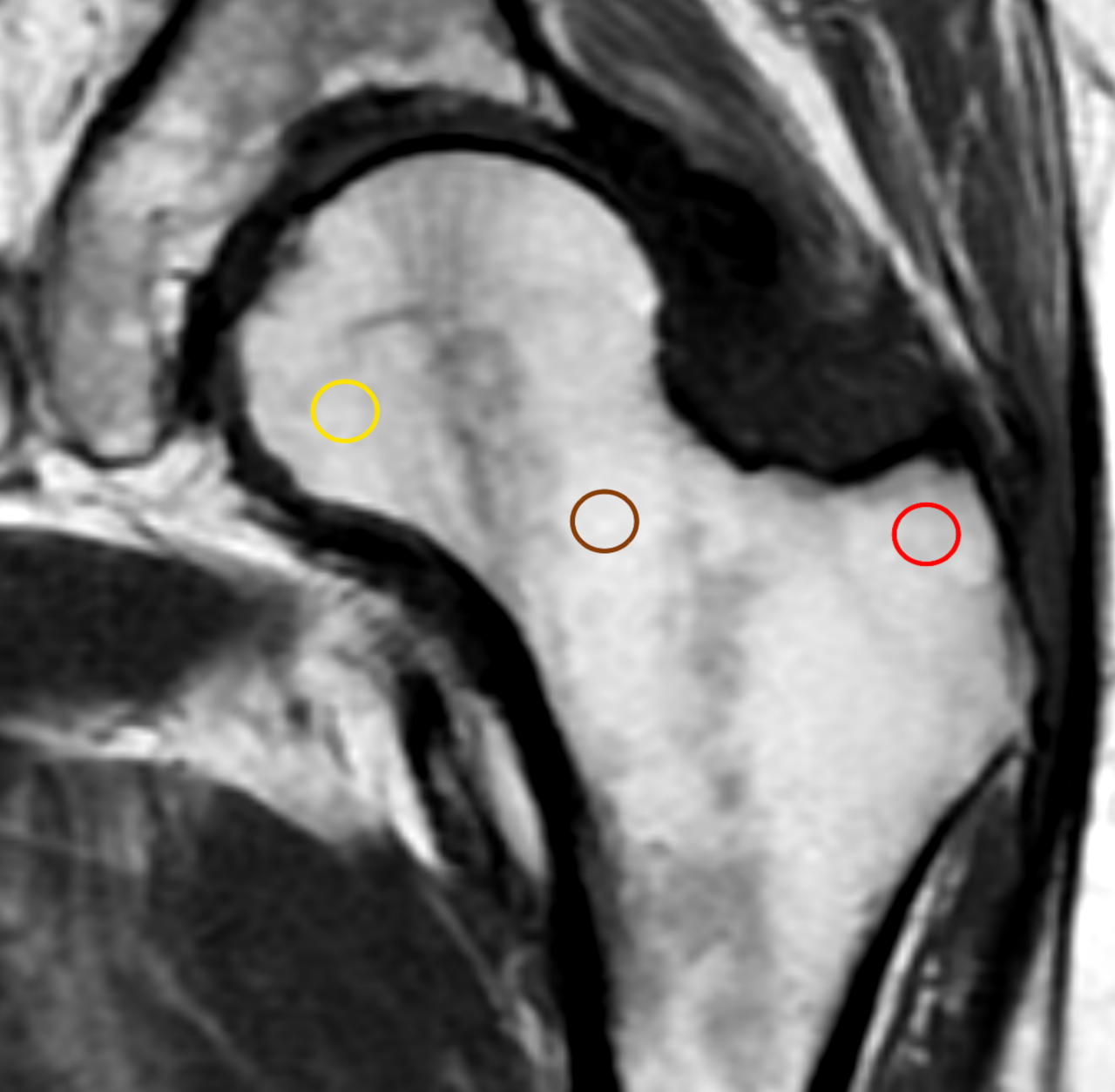
FIGURE LEGEND

Figure 1. ROIs positions

Figure 1a (left) Five ROIs were drawn in trabecular bone in ONFH patients: two inside the necrotic bone (necrotic border –blue-, necrosis –green-), and three outside the necrotic bone (femoral head –yellow-, femoral neck –brown- and greater trochanter -red).

Figure 1b (right) In OA patients, three ROIs were drawn in normal appearing bone (femoral head –yellow-, femoral neck –brown- and greater trochanter -red).



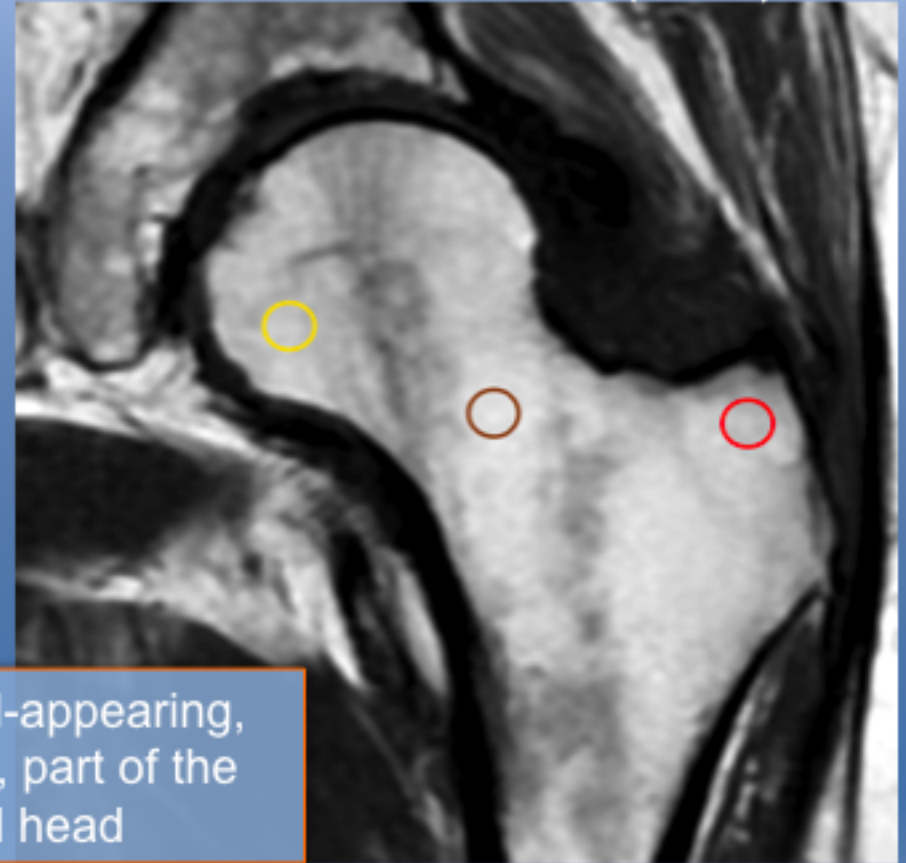
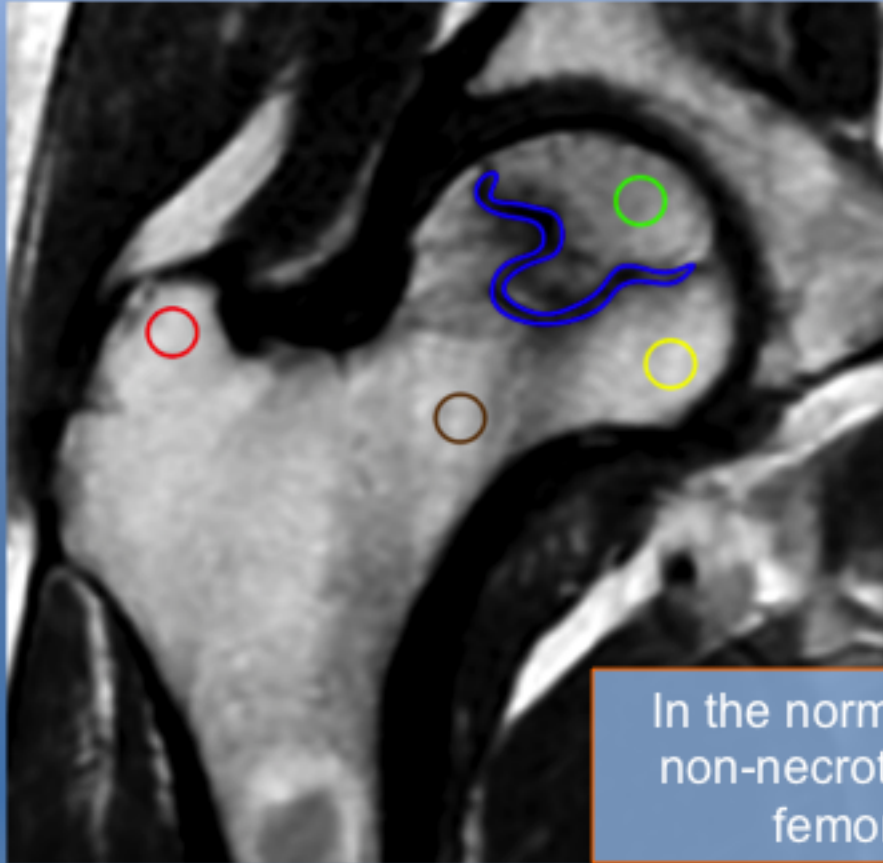


Quantitative Magnetic Resonance Imaging Chemical shift (adiposity) & Dynamic Contrast-enhanced (perfusion)

31 adult males (mean 58 ± 9 years, 38–74 years)

Femoral Head OSTEONECROSIS (n=16)

CONTROL GROUP (n=15)



In the normal-appearing,
non-necrotic, part of the
femoral head

Bone marrow adiposity is not significantly different ($p=1$)

Exchanges between blood and bone marrow are significantly different ($p=0.05$)
osteonecrosis < control group