



HAL
open science

Delayed positive skin tests in patients with immediate hypersensitivity reactions to beta-lactams

Rik Schrijvers, Bárbara Kong Cardoso, Jean Luc Bourrain, Pascal Demoly, Anca Mirela Chiriac

► **To cite this version:**

Rik Schrijvers, Bárbara Kong Cardoso, Jean Luc Bourrain, Pascal Demoly, Anca Mirela Chiriac. Delayed positive skin tests in patients with immediate hypersensitivity reactions to beta-lactams. *Journal of Allergy and Clinical Immunology: In Practice*, 2020, 8, pp.2431 - 2433. 10.1016/j.jaip.2020.03.039 . hal-03491493

HAL Id: hal-03491493

<https://hal.science/hal-03491493>

Submitted on 18 Jul 2022

HAL is a multi-disciplinary open access archive for the deposit and dissemination of scientific research documents, whether they are published or not. The documents may come from teaching and research institutions in France or abroad, or from public or private research centers.

L'archive ouverte pluridisciplinaire **HAL**, est destinée au dépôt et à la diffusion de documents scientifiques de niveau recherche, publiés ou non, émanant des établissements d'enseignement et de recherche français ou étrangers, des laboratoires publics ou privés.



Distributed under a Creative Commons Attribution - NonCommercial 4.0 International License

1 **Title:** Delayed positive skin tests in patients with immediate hypersensitivity reactions to beta-lactams

2 **Authors:**

3 Rik Schrijvers M.D. PhD*¹, Bárbara Kong Cardoso M.D.*², Jean Luc Bourrain M.D.³, Pascal Demoly M.D.
4 Ph.D.^{3,4}, Anca M Chiriac M.D. Ph.D.^{3,4}

5 **Author's affiliation:**

6 ¹ KU Leuven department of microbiology and clinical immunology, allergy and clinical immunology
7 research group, KU Leuven, Leuven, Belgium

8 ² Department of Immunoallergology, Hospital São Bernardo – Centro Hospitalar de Setúbal, Portugal

9 ³ Department of Pulmonology, Division of Allergy, Hôpital Arnaud de Villeneuve, University Hospital of
10 Montpellier, Univ Montpellier, France;

11 ⁴ UMR-S 1136 INSERM-Sorbonne Université, Equipe EPAR - IPLESP, Paris, France

12

13 **Corresponding author:**

14 Dr Anca Mirela CHIRIAC

15 a-chiriac@chu-montpellier.fr

16 0033 467 33 61 07

17 Allergy Unit

18 Arnaud de Villeneuve Hospital

19 University Hospital of Montpellier

20 371, Avenue du Doyen Gaston Giraud

21 34295 Montpellier Cedex 5, Montpellier, France

22

23 *These authors have contributed equally to this work

24 **Word count: 1082**

25 **Conflicts of interest:** None for this paper.

26 **Sources of funding:** Rik Schrijvers is recipient of a FWO (Fonds Wetenschappelijk Onderzoek) senior clinical
27 investigator fellowship; Bárbara Kong Cardoso is an EAACI clinical fellowship recipient (2018).

28

29 **Clinical implications**

30 Skin tests for presumed IgE-mediated reactions to beta-lactams may be negative on immediate
31 reading, but rarely demonstrate positivity on delayed reading with wheal-and-flare. Clinicians should
32 be aware of this possible presentation.

33

34 The allergy work-up of a presumed immediate drug hypersensitivity reaction (DHR) is well established
35 for beta-lactams (BL)¹. Patients undergo skin tests (ST) (prick (SPT) and intradermal (IDT) tests),
36 followed by an immediate reading. In case of negative results and in the absence of contraindications,
37 a drug provocation test (DPT) is performed, often on the same day.

38 We describe three cases of immediate DHR to BL in which ST were negative on immediate reading, yet
39 all developed a late wheal-and-flare reaction, that contra-indicated DPT (**Table 1**).

40 **Case 1**, 64-year-old female, presented with palm and sole pruritus, malaise and dyspnea 30 minutes
41 after taking amoxicillin/clavulanic acid (AxC), 500/62.5mg for a dental infection. She returned to her
42 dentist where she was treated with prednisolone 80mg. The treatment was ineffective and the
43 reaction worsened (vomiting, loss of consciousness, systolic pressure 60mmHg). Adrenaline was
44 administered, and she was transferred to the emergency department. Tryptase measurements at the
45 time of the event and baseline were 9.8 and 6.2 µg/mL, respectively. She had no atopy but suffered
46 from SAPHO (Synovitis, Acne, Pustulosis, Hyperostosis and Osteitis) syndrome and hypothyroidism
47 treated with infliximab and L-thyroxine, respectively. She took 1g of paracetamol 9h before the event.
48 Intake of amoxicillin 4 months earlier was uneventful. ST to penicillin G (Pen G), AxC, ampicillin (Amp) 4
49 weeks later were all negative on immediate reading. When the patient returned for the DPT, she

50 mentioned a late reaction at the prior ST had occurred. IDTs were repeated and revealed again
51 negative immediate reading. However, 4h and 6h later a dose-dependent wheal for IDT to AxC and
52 Amp was observed, fading over the following days (**Figure 1-** Case1). The patient was considered
53 allergic to AxC and Amp. A paracetamol DPT was negative.

54 **Case 2**, 26-year-old male was on noradrenaline because of circulatory instability after a trauma. He
55 received suxamethonium, etomidate, midazolam, sufentanyl to induce general anaesthesia. After
56 achieving circulatory stability, he was rushed to emergency orthopedic surgery (where propofol,
57 sufentanyl, paracetamol were administered). Two hours after the beginning of the procedure and 30
58 minutes after the (presumably) second injection of AxC (2g; the patient seemed to have received AxC
59 and gentamycin while in the emergency unit, but this information could not be undoubtedly
60 confirmed) he experienced rapidly increasing circulatory instability, demanding increasing doses of
61 noradrenalin and then adrenalin syringe-pump. After cardio-circulatory recovery, the patient
62 developed urticaria. Tryptase and histamine levels 30 minutes after the onset were 4.8 µg/mL and 36.9
63 nmol/L (normal <10 nmol/L), respectively. Baseline tryptase was <1 µg/L. The patient had a history of
64 allergic rhinoconjunctivitis, took no maintenance treatment and previously underwent general
65 anesthesia uneventfully. He didn't recall prior penicillin use. ST with PenG, AxC, Amp 6 weeks later
66 were negative on immediate reading. When the patient returned for the DPT, he described a late
67 reaction on the previous ST that lasted for several days. IDTs were repeated demonstrating negative
68 immediate reading, yet wheal-and-flare at PenG, AxC, and Amp 24h later, lasting for several days, with
69 an accompanying lymphangitis on day 3 (**Figure 1-** Case2). Further allergy work-up was negative. The
70 patient was considered allergic to penicillins. He tolerated cefuroxime and ceftriaxone.

71 **Case 3**, 49-year-old male, presented 1 hour and 30 minutes after the start of renal stent placement with
72 isolated generalized erythema while in the post-operative care unit. The patient had received propofol,
73 sufentanil, mivacurium, betamethasone, cefazolin, ketoralac, paracetamol, and desflurane. Baseline
74 tryptase level was 10.6 µg/L, no acute measurement was performed. The patient suffered from
75 Crohn's disease but received no maintenance treatment. ST performed 10 weeks later were negative
76 on immediate reading. A few hours later, a reaction was observed at the cefazolin ST. The IDT for
77 cefazolin was repeated, together with other BL ST, and negative on immediate reading yet an itchy
78 wheal-and-flare appeared at the cefazolin ST appeared 3h30 and again waned 8h30 later (**Figure 1-**
79 **Case3**). The patient was considered allergic to cefazoline, a DPT for cefuroxime was negative.

80 An immediate IgE-mediated reaction on ST is expressed by a wheal-and-flare reaction caused by mast
81 cell degranulation. The release of histamine, the major mediator in this reaction, begins within 5
82 minutes after allergen exposure and peaks at 30 minutes. Histamine and other mediators can trigger
83 the release of substance P by axonal reflexes and additionally expand histamine release from the
84 cutaneous mast cells². Any IgE-mediated reaction consists of an immediate and a late-phase reaction
85 (LPR). It is the former that is used in clinical practice as a reference for ST reading.

86 The IgE-mediated LPR in ST is a reaction that begins several hours after the exposure of the allergen via
87 SPT or IDT (peaking at 6-12h and resolving in approximately 24-48h). Generally, this reaction occurs
88 when the immediate reading of the IDT reveals a large wheal-and-flare reaction, as shown for
89 respiratory allergens^{3,4}.

90 Several mechanisms have been put forward to explain the LPR, involving other mediators than
91 histamine (such as TNF-alpha, IL-6⁵) that orchestrate the recruitment of a mixed cellular infiltrate⁶, a
92 prolonged stimulation of mast cells, and altered expression of adhesion molecules on vascular

93 endothelium at the reaction site⁴. Late-onset presumed IgE-mediated reactions (urticaria, anaphylaxis)
94 have been described⁷ mostly after bee-stings. The authors suggested a stimulation of IgE antibodies
95 with persisting venom antigen. In asthmatics, intradermal administration of allergens was able to elicit
96 a late phase asthmatic reaction without an early, IgE-mediated response, and was attributed as T-cell-
97 mediated^{6,8,9}. Here, skin reaction was absent both on immediate and LPR⁹.

98 In our work, case 1 and 2 suffered from an immediate DHR with ST positivity only on delayed reading
99 suggesting a mitigated early phase ST response. In case 3, concordant late-onset index reaction and ST
100 were observed, possibly alluding to a reaction to a metabolite. Of note, none of the index reactions
101 were reminiscent of a type IV reaction. The peculiarity of the cases is that no immediate phase reaction
102 preceded the alleged LPR and, to our knowledge, there is no previous report of this in beta-lactam
103 allergy.

104 We did not perform confirmatory DPTs for ethical reasons and our observations do not provide a
105 definite mechanistic explanation. Delayed ST positivity in the evaluation of a presumed IgE-mediated
106 DHR is rare. We do not envision that this approach changes the recommendation of the use of ST,
107 immediately followed by DPT in case of negative ST on immediate reading. However, if ST performed
108 for a possible immediate DHR results in a delayed reaction, this should be taken into consideration
109 despite the atypical presentation, before exposing patients to a potentially high risk DPT.

110

111 **References:**

- 112 1. Brockow K, Garvey LH, Aberer W, Atanaskovic-Markovic M, Barbaud A, Biló MB, et al. Skin test
113 concentrations for systemically administered drugs – an ENDA/EAACI Drug Allergy Interest Group position
114 paper. *Allergy*. 2013;68:702–712.
- 115 2. Chiriac AM, Bousquet J, Demoly P. In Vivo Methods for the Study and Diagnosis of Allergy. In: Elsevier Inc,
116 editor. *Middleton's Allergy: Principles and Practice*: 8th ed. 2013. p. 1119–32.
- 117 3. Yates AB, deShazo RD. Delayed Hypersensitivity Skin Testing. *Immunology and Allergy Clinics of North*
118 *America*. 2001;21:383–97.

- 119 4. Barata LT, Ying S, Meng Q, Barkans J, Rajakulasingam K, Durham SR, et al. IL-4- and IL-5-positive T
120 lymphocytes, eosinophils, and mast cells in allergen-induced late-phase cutaneous reactions in atopic
121 subjects. *J Allergy Clin Immunol.* 1998;101:222–30.
- 122 5. Nagai H, Abe T, Yamaguchi I, Mito K, Tsunematsu M, Kimata M, et al. Role of mast cells in the onset of IgE-
123 mediated late-phase cutaneous response in mice. *J Allergy Clin Immunol.* 2000;106:91-98.
- 124 6. Galli SJ, Tsai M. IgE and mast cells in allergic disease. *Nature Medicine.* 2012;18:693–704.
- 125 7. Asai Y, Uhara H, Miyazaki A, Saiki M, Okuyama R. Late Onset of Acute Urticaria after Bee Stings. *Case Rep*
126 *Dermatol.* 2016;8:341–3.
- 127 8. Kay AB. Allergy and allergic diseases. First of two parts. *N Engl J Med.* 2001;344:30–7.
- 128 9. Haselden BM, Kay AB, Larché M. Immunoglobulin E-independent major histocompatibility complex-
129 restricted T cell peptide epitope-induced late asthmatic reactions. *J Exp Med.* 1999;189:1885–94.
- 130
- 131
- 132

133 Table 1 - Characterization of Clinical Cases (on separate file)

134

135

136

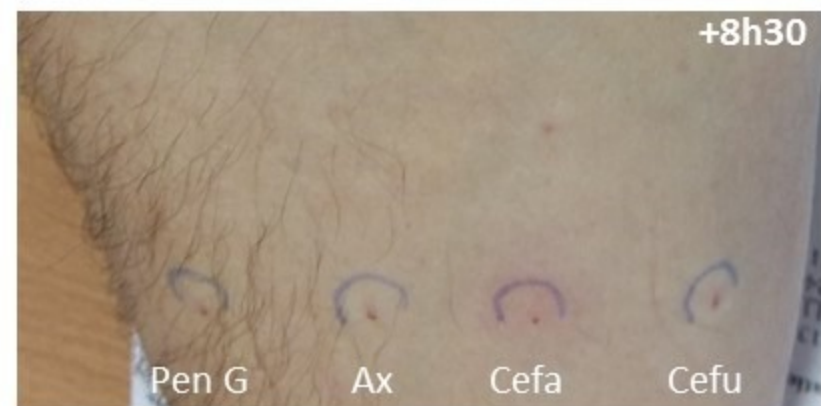
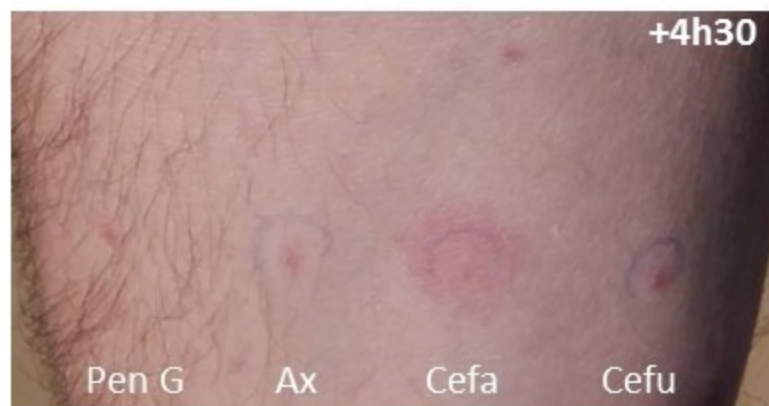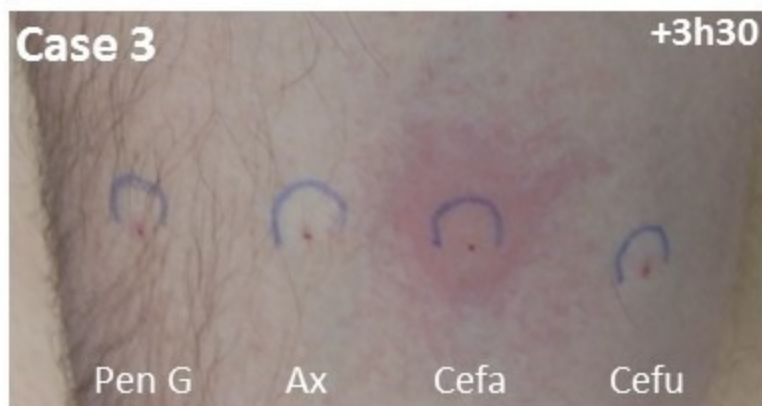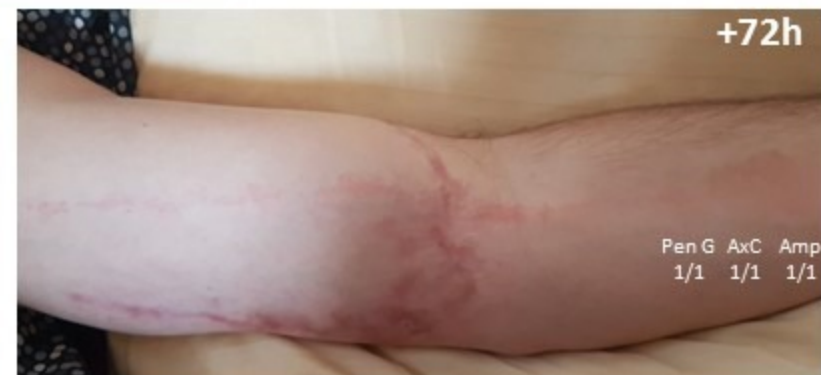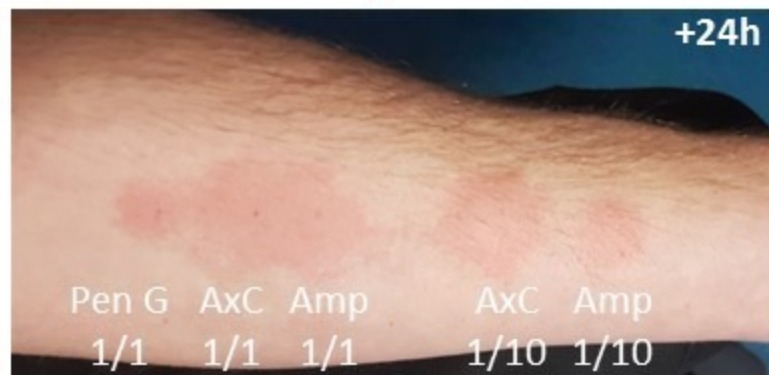
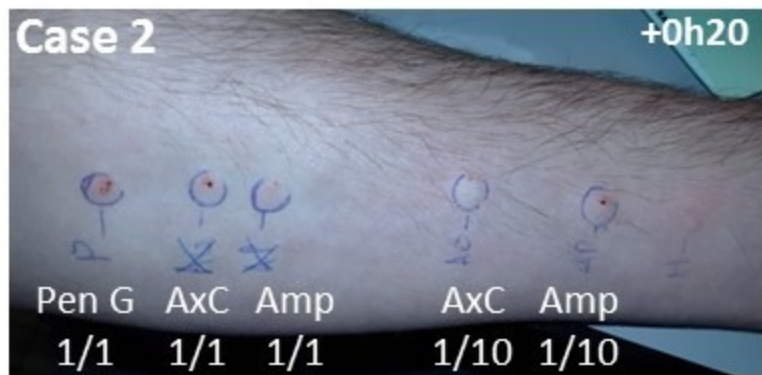
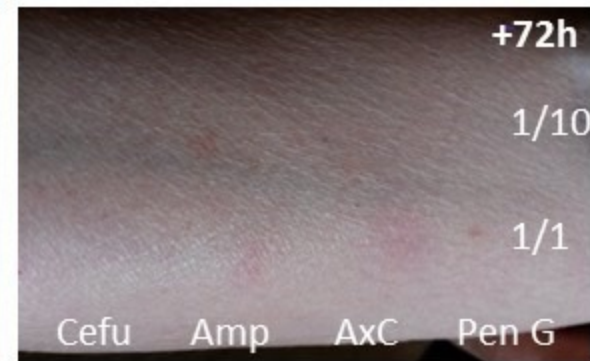
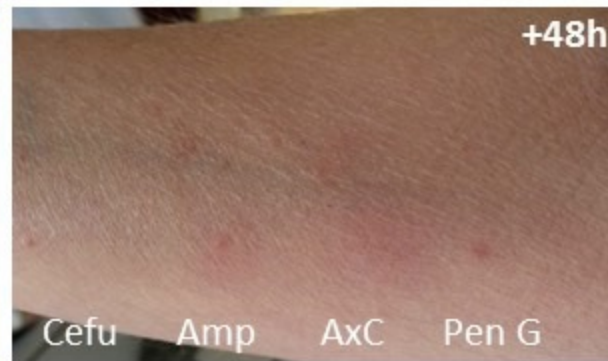
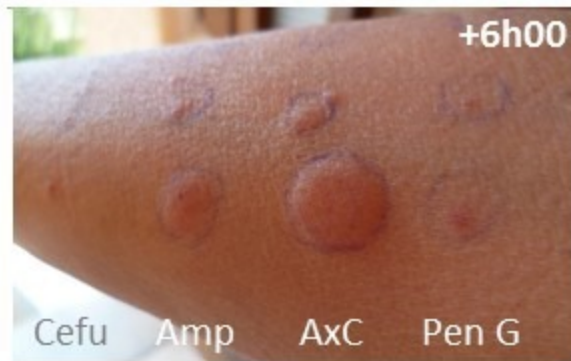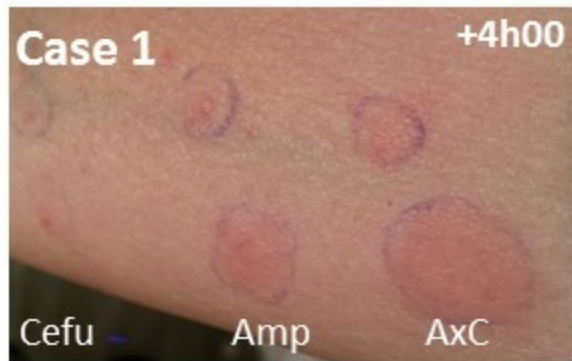137

138 Figure 1 - Skin Test positive results in the 3 cases

139

140

141 Legend: Skin test results in the 3 cases, on different time points, using the indicated drugs (penicillin G, Pen G;
142 ampicilline, Amp; amoxicilline, Ax; amoxicillin clavulanic acid, AxC; cefuroxim, Cefu; cefazoline, Cefa)
143 demonstrate late skin test positivity with a wheal-and-flare-like reaction for Amp and AxC in case 1; Pen G, AxC,
144 Amp in case 2; and Cefa in case 3. The outer right picture in case 2 demonstrates an accompanying lymphangitis
145 on day 3. ST were performed according to ENDA/DAIG recommendations¹ (maximal concentration (1/1) for Cefu
146 2 mg/mL; Amp 25 mg/mL; Ax 25 mg/mL; AxC 25 mg/mL of Ax; Pen G 10,000 IU/mL), except for benzyl
147 penicilloyl-polylysine (PPL, e.g. PRE-PEN, ALK Abello, USA) and minor determinant mixture (MDM) associated
148 with increased ST sensitivity for diagnosing penicillin allergy, that are not available in France and Cefa IDT at 30
149 mg/ml in case 3, being negative in 20 controls. Co-sensitization to clavulanic acid was deemed unlikely but
150 testing for clavulanic acid alone is not available in France.



Case	Age, sex	Index reaction	Culprit (administration route)	Reaction interval	Reaction duration	Reaction treatment	Test interval	ST positivity*	Duration of ST positivity (start-end)	Tryptase acute (µg/L)	Tryptase baseline (µg/L)	Maintenance treatment(s)
#1	64, F	Anaphylaxis	AxC (po)	30 min	Short (Minutes – hours)	CS, adrenaline	4 we	Amp, AxC	4h – 4d	9.8	6.2	Infliximab, L-thyroxine
#2	26, M	Anaphylaxis	AxC (IV)	30 min after 2 nd dose [£]	Short (Minutes – hours)	Nor-adrenaline	6 we	Amp, AxC, Pen G	24h – 5d	4.8	<1	None
#3	49, M	Generalized erythema	Cefa (IV)	1h30	Short (30 min)	CS, anti-H2	10 we	Cefa	3h30-8h30	ND	10.6	None

Table 1 - Characterization of Clinical Cases

Legend:

Abbreviations: ST, skin tests; AxC, amoxicillin clavulanic acid; Cefa, cefazoline; CS, corticosteroids; IV, intravenous; ND, not determined; po, per os; we, weeks;

* Skin test results were independently confirmed. [£] It remains uncertain whether a ‘first’ dose was actually given (discordant recordings in emergency mobile unit, emergency department, and surgery unit concerning a first dose early before the event). Alternatively, a reaction after a first dose was missed due to co-administration of noradrenaline, or a delayed presentation of anaphylaxis with concordant late skin test positivity occurred, with unknown mechanism.