



HAL
open science

Superficial Siderosis of the Central Nervous System associated with Hemophilia A: A case report

Quentin Thomas, Gauthier Duloquin, Sophie Mohr, Guy-Victor Osseby,
Maurice Giroud, Yannick B ejot

► **To cite this version:**

Quentin Thomas, Gauthier Duloquin, Sophie Mohr, Guy-Victor Osseby, Maurice Giroud, et al.. Superficial Siderosis of the Central Nervous System associated with Hemophilia A: A case report. *Interdisciplinary Neurosurgery - Advanced techniques and case management*, 2021, 23, pp.100912 -. 10.1016/j.inat.2020.100912 . hal-03491323

HAL Id: hal-03491323

<https://hal.science/hal-03491323>

Submitted on 21 Sep 2022

HAL is a multi-disciplinary open access archive for the deposit and dissemination of scientific research documents, whether they are published or not. The documents may come from teaching and research institutions in France or abroad, or from public or private research centers.

L'archive ouverte pluridisciplinaire **HAL**, est destin ee au d ep ot et  a la diffusion de documents scientifiques de niveau recherche, publi es ou non,  emanant des  tablissements d'enseignement et de recherche fran ais ou  trangers, des laboratoires publics ou priv es.



Distributed under a Creative Commons Attribution - NonCommercial 4.0 International License

Superficial Siderosis of the Central Nervous System associated with Hemophilia A: a case report.

Q. Thomas^{1,2}, G. Duloquin^{2,3}, S. Mohr², G-V. Osseby², M. Giroud³, Y. Béjot^{2,3}

1 Inserm UMR1231 team GAD, University of Burgundy and Franche-Comté, F-21000 Dijon, France

2 Department of Neurology, Dijon Bourgogne University Hospital, F-21000 Dijon, France

3 Dijon Stroke Registry, EA7460, Pathophysiology and Epidemiology of Cerebro-Cardiovascular Diseases (PEC2), University Hospital of Dijon, University of Burgundy, Dijon, France

Corresponding author

Quentin THOMAS, MS

Laboratoire GAD, Bâtiment B3, Université de Bourgogne, 15 boulevard Maréchal De Lattre de Tassigny, 21070 Dijon Cedex

Phone: 03.80.39.32.38

Fax: 03.80.29.32.66

e-mail: quentin.thomas@chu-dijon.fr

Search Terms/Key points: Superficial Siderosis of the Central Nervous system, Congenital Hemophilia A, chronic bleeding, etiological diagnosis,

Submission Type: Case Report

Number of characters in the title: 83

Number of words in the abstract: 136

Number of words in main text: 1171

Tables: 0

Figures: 3

References: 12

Case Report

A 61-year-old man was referred to our consultation because of progressively worsening gait disorders, hearing impairment, lower limbs pain and saddle anesthesia. His medical history was marked with mild congenital hemophilia A (factor VIII activity: 20I U DL⁻¹), bladder polyp removal, ongoing smoking, and alcohol misuse. At the age of 37-year-old, he underwent an audiometric testing following a work-related accident which revealed a bilateral subclinical sensorineural hearing loss. At the age of 57 years old, he noticed lower back pain radiating throughout his lower limbs, along with progressive gait disorders. The diagnosis of lumbar spinal stenosis was evoked and, as medical management failed, surgery was suggested. Presurgical spinal Magnetic Resonance Imaging (MRI) was then interpreted as unremarkable apart from multiple hernia and mild lumbar stenosis (Figure 1). Immediately after the lumbar spinal stenosis surgery (laminectomy and lumbar arthrodesis from L2 to L5), he developed a sudden paraplegia with bladder and sphincter disorders and severe lower limbs pain. An MRI revealed an epidural hematoma (Figure 2) which was surgically drained, unfortunately only partially improving his symptoms as the patient still displayed lower back pain and mild gait disturbances on discharge. A year later, because of worsening symptoms with reduced ability to walk and increasing back pain and sphincter disorders, a new surgery was considered (spinal recalibration with extended arthrodesis to L1-S1). During pre-surgical screening, spinal and brain MRI demonstrated an extensive hypo-intensity on fast 2D gradient-echo-weighted sequences, along the spinal cord, posterior fossa's structures and cerebral cortex for which our expertise was requested (Figure 3).

On admission, clinical examination showed cerebellar ataxia, pyramidal syndrome with bilateral extensor plantar response and brisk reflexes of the four limbs, saddle anesthesia and bilateral hearing impairment. Neuropsychological assessment revealed mild cognitive impairment including memory, attention and concentration disorders. The diagnosis of Superficial Siderosis of the CNS was made.

Comprehensive etiological investigations were performed including laboratory work-up, conventional cerebral and medullar angiography, and were all unremarkable. A treatment with high doses of steroids (IV infusion of 1000mg of methylprednisolone once, followed by 80mg of prednisone for a week with a gradual withdrawal over a month) was initiated. Limbs pain were relieved and a significant clinical improvement of the patient in terms of mobility and quality of life was observed. Unfortunately, within a month after steroids were stopped, symptoms reappeared with comparable intensity.

Discussion

Superficial Siderosis of the Central Nervous System (SSCNS) is a condition secondary to the deposition of hemosiderin within the subpial layers of central nervous system leading to its progressive degeneration[1]. Clinically, it is most frequently characterized by the association of hearing impairment, cerebellar ataxia and pyramidal syndrome but patients often also display cognitive decline, bladder and sphincter disorders or sensory symptoms. Since Iwanonowski's and Noetzel's experiments in the 60's, Superficial Siderosis (SS) is known to be secondary to a chronic bleeding within the central nervous system (CNS)[2], although some reports suggest that an acute bleeding might be sufficient to generate the disease. Hence, many disorders can be responsible for SSCNS, including aneurysm rupture, chronic subdural hematoma, cerebral amyloid angiopathy, cerebral vasculitis, all kind of neurosurgical procedures, all vascular malformations within the CNS, cerebral tumors or head traumas[3]. Yet, 6 to 35% of SSCNS are considered idiopathic without obvious source of chronic bleeding identified despite extensive investigations[3].

Regarding our patient, although his spinal surgery might appear as the obvious cause for his SS at first sight, his history clearly suggests that his disorder was not caused but worsened and revealed by the surgery. Indeed, 20 years before the procedure, he was already suffering from subclinical neurosensory hearing impairment. Furthermore, reinterpretation of his first presurgical spinal MRI revealed pre-existing T2* hypo-intensity of the spinal cord, with mild lumbar spinal stenosis (Figure 1). It is then most likely that his lower limbs pain and gait disturbances were already caused by the SS of his spinal cord, as it is known that this disorder may initially present itself as a progressive myelopathy[4].

Thus, this raises the question of the etiology of his SS. As in many other cases, our investigations did not identify any obvious source of chronic hemorrhage despite including laboratory work-up with antibodies known to be associated with vasculitis, and dedicated imaging to detect vascular malformations with both CT cerebral angiography and medullar angiography. For these patients with negative findings, it has been hypothesized that the chronic bleeding may be impossible to visualize through common imaging[5] and that it may be facilitated by increased permeability of meningeal arteries[6]. Thus, the concurrent presence of a clotting disorder such as hemophilia A should worsen and facilitate this process, adding thinner blood to altered vascular permeability and may be sufficient to generate chronic bleeding and SS.

Congenital Hemophilia A is a hereditary X-linked recessive bleeding disorder secondary to mutations in the factor VIII gene leading to the deficiency or absence of this fundamental clotting protein. Affecting 1 out of 5000 live births, it is responsible for acute, spontaneous or post-traumatic muscular or joint hemorrhages[7]. Neurological complications of the disease include post-traumatic hematomas leading to peripheral nerve damage, spinal cord compression and various lesions of the central nervous system[8].

Regarding SSCNS, our report is the second ever published case in a patient with Hemophilia A without any apparent cause[9]. In their own report, López-Blanco and Bartolomé-Villar describe a very similar story with comparable clinical presentation. Hence our report reinforces the hypothesis that Hemophilia A might be a new cause of SSCNS which would be critical for patients follow-up. Indeed, physicians should be aware of the appearance of gait disorders, hearing impairment or cognitive decline in patients with hemophilia A and not hesitate to perform an MRI with adequate sequences with T2* or Susceptibility Weighted Imaging in order to detect a SSCNS at its earlier stages.

Different therapeutic approaches have been tried in SS including surgery[10] or iron chelation, specifically with Deferiprone[11] as it has been proven to be safe and well tolerated while offering the benefit of crossing the brain-blood-barrier. Unfortunately, although surgery may prevent further worsening of the symptoms when the source of chronic bleeding is identified, medical therapies have all failed to prove any reproducible efficiency to date.

Regarding steroids, other articles have reported its use with moderate benefit that has been already argued as probably associated with other underlying conditions or temporary booster-effect[12]. In our case, high doses led to a quick and significant clinical improvement. This dramatic effect might be correlated to the unusually extensive aspect of our patient's siderosis, generating higher microglial activation, reactive gliosis, and arachnoiditis, making steroids and their anti-inflammatory effects so effective. Unfortunately, our patient became quickly steroids dependent as cessation of the treatment irrevocably led the resumption of his symptoms.

Conclusion

This report highlights the need for awareness for physicians when managing patients with medical history of congenital Hemophilia A and symptoms suggestive of SSCNS, and encourages them to perform cerebral and spinal MRI with T2* or SWI (Susceptibility Weighted Imaging) sequences to help in diagnosing this condition. Better understanding of the disease pathophysiology should offer new therapeutic prospects in the future.

Funding

No funding was received in the writing of this article.

Author Contribution

Q.T. collected and analyzed data and wrote the manuscript, G.D. collected and analyzed the data, S.M. collected the data, G-V.O. collected the data, M.G. collected the data, Y.B collected the data and wrote the manuscript.

Declaration of Interest

The authors declare no conflict of interest.

Patient Consent

Patient gave his signed consent for the publication of his anonymized clinical and imaging data.

References

- [1] J. Trevor Hughes, D.R. Oppenheimer, Superficial siderosis of the central nervous system - A report on nine cases with autopsy, *Acta Neuropathol.* 13 (1969) 56–74. <https://doi.org/10.1007/BF00686141>.
- [2] H. Noetzel, R. Ohlmeier, Zur Frage der Randzonensiderose des Zentralnervensystems - Tierexperimentelle Untersuchung, *Acta Neuropathol.* 3 (1963) 164–183. <https://doi.org/10.1007/BF00687065>.
- [3] A. Stabile, V. Di Lazzaro, C. Colosimo, F. Piazza, C. Ferrarese, J.C. DiFrancesco, Idiopathic infratentorial superficial siderosis of the central nervous system: case report and review of literature, *Neurol. Neurochir. Pol.* 52 (2018) 102–106. <https://doi.org/10.1016/j.pjnns.2017.10.006>.
- [4] H. Offenbacher, F. Fazekas, F. Reisecker, R. Schmidt, F. Payer, H. Lechner, Superficial siderosis of the spinal cord: A rare cause of myelopathy diagnosed by MRI, *Neurology.* 41 (1991) 1987–1989. <https://doi.org/10.1212/wnl.41.12.1987>.
- [5] M. Bracchi, M. Savoiaro, F. Triulzi, D. Daniele, M. Grisoli, G.B. Bradac, C. Agostinis, D. Pelucchetti, G. Scott, Superficial siderosis of the CNS: MR diagnosis and clinical findings, *Am. J. Neuroradiol.* 14 (1993) 227–236.
- [6] P. Rosenthal, Siderose der Randzonen des Zentralnervensystems, *Dtsch. Z. Nervenheilkd.* 178 (1958) 431–472. <https://doi.org/10.1007/BF00242858>.
- [7] M. Franchini, P.M. Mannucci, Hemophilia A in the third millennium, *Blood Rev.* 27 (2013) 179–184. <https://doi.org/10.1016/j.blre.2013.06.002>.
- [8] A.S. Douglas, S.G. McAlpine, Neurological Complications of Haemophilia and Christmas Disease, *Scott. Med. J.* 1 (1956) 270–273. <https://doi.org/10.1177/003693305600100805>.
- [9] R. López-Blanco, A. Bartolomé-Villar, Superficial siderosis of central nervous system in a patient with hemophilia, *Interdiscip. Neurosurg. Adv. Tech. Case Manag.* 18 (2019) 100509. <https://doi.org/10.1016/j.inat.2019.100509>.
- [10] E. de A.S. Vellutini, A.E.C. Stamm, H.O. Martins, M.F. de Oliveira, G.P. Rodriguez Coy, L.F. Godoy, M. de Q. Teles Gomes, Role of Transnasal Endoscopic Surgery in the Treatment of

Superficial Siderosis of Central Nervous System Secondary to Clivus Arachnoidocele: Report of Successful Case and Literature Review, *World Neurosurg.* 126 (2019) 142–145. <https://doi.org/10.1016/j.wneu.2019.02.186>.

- [11] M. Levy, R.H. Llinas, Deferiprone reduces hemosiderin deposits in the brain of a patient with superficial siderosis, *Am. J. Neuroradiol.* 32 (2011). <https://doi.org/10.3174/ajnr.A2331>.
- [12] R. Scheid, S. Frisch, M.L. Schroeter, Superficial siderosis of the central nervous system - Treatment with steroids?, *J. Clin. Pharm. Ther.* 34 (2009) 603–605. <https://doi.org/10.1111/j.1365-2710.2009.01030.x>.

Legend

Figure 1: Presurgical spinal MRI performed at the age of 59 years old. T2-weighted sequences with axial (A-C) and sagittal (D, E) views. White arrows showing the extensive hypo-intensity surrounding the lumbar and thoracic spinal cord. Picture A corresponds to the L3, B to L1 and C to Th12-L1 levels.

Figure 2: Post-surgical spinal MRI performed 4 months later. T2-weighted sagittal sequences with blue arrows displaying the epidural hematoma with compression on the “queue de cheval”.

Figure 3: Follow-up cerebral and spinal MRI performed two years later. A-E: axial T2-weighted Gradient Echo (T2*) sequences. F-H: 3D T1-weighted axial sequences. I-K: axial T2 FLAIR sequences. L-M: axial T1-weighted. Notice how extensive and visible the T2 hyposignal is on T2* sequences (white arrows) while other sequences appear normal.

Figures

Figure 1: Presurgical spinal MRI performed at the age of 59 years old. T2-weighted sequences with sagittal views. White arrows showing the extensive hypo-intensity surrounding the lumbar and thoracic spinal cord.

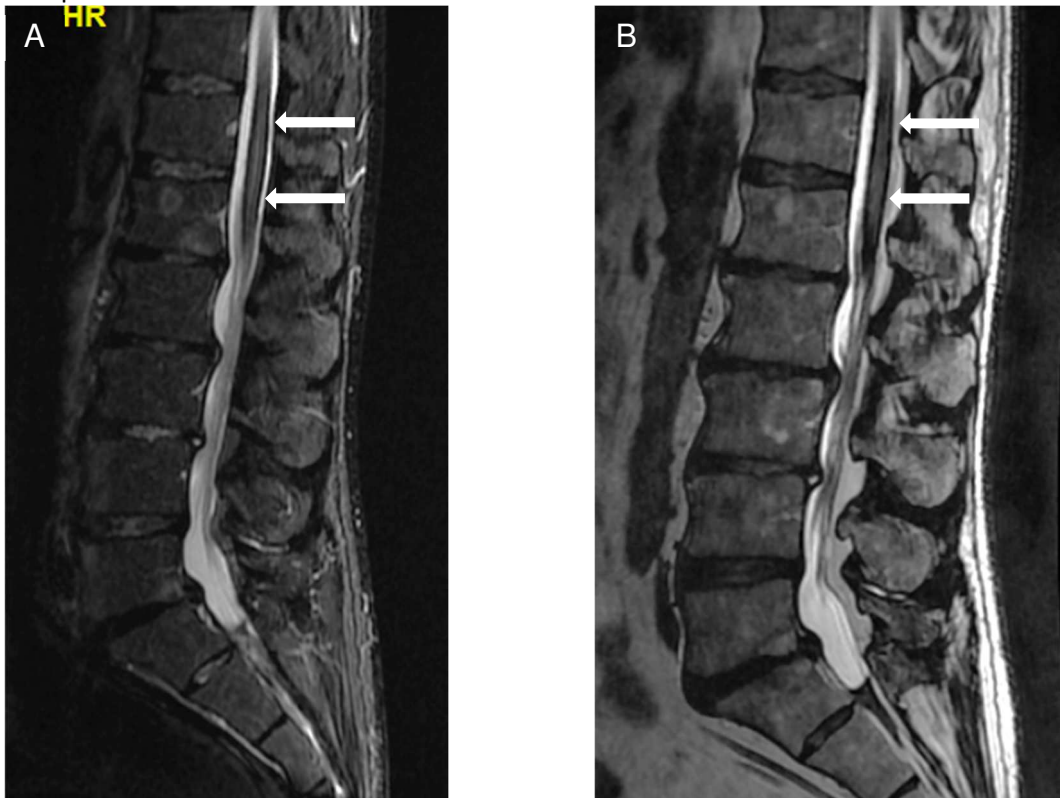


Figure 2: Post-surgical spinal MRI performed 4 months later. T2-weighted sagittal sequences with white arrows displaying the epidural hematoma with compression on the “queue de cheval”.

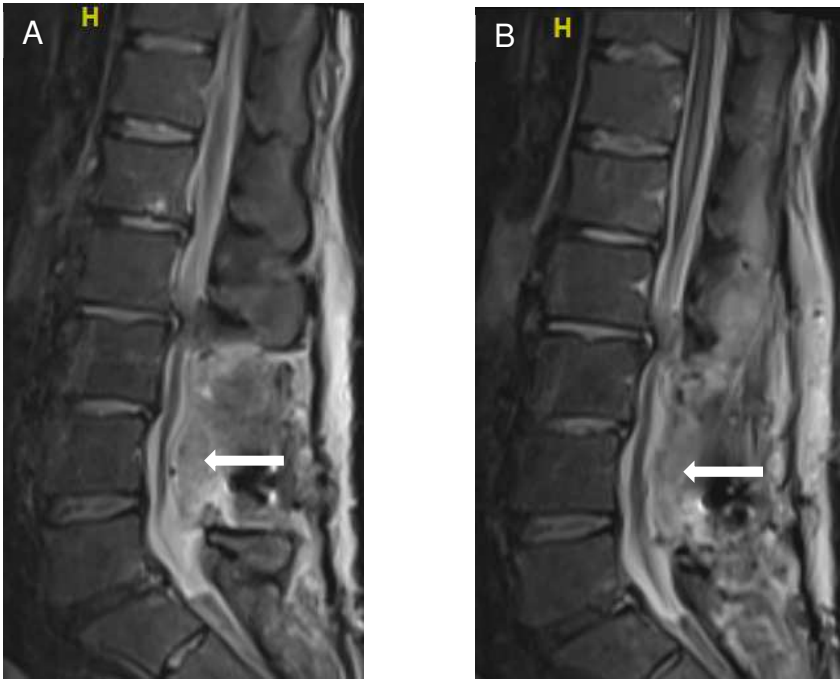


Figure 3: Follow-up cerebral and spinal MRI performed two years later. A-E: axial T2-weighted Gradient Echo (T2*) sequences. F-H: 3D T1-weighted axial sequences. I-K: axial T2 FLAIR sequences. L-M: axial T1-weighted. Notice how extensive and visible the T2 hyposignal is on T2* sequences (white arrows) while other sequences appear normal.

