



HAL
open science

New Insights into Expression of Hormonal Receptors by Meningiomas

Sylvain Portet, Tania Banor, Jonathan Bousquet, Adrien Simonneau, Marie Flores, Pierre Ingrand, Serge Milin, Lucie Karayan-Tapon, Benoit Bataille

► **To cite this version:**

Sylvain Portet, Tania Banor, Jonathan Bousquet, Adrien Simonneau, Marie Flores, et al.. New Insights into Expression of Hormonal Receptors by Meningiomas. *World Neurosurgery*, 2020, 140, pp.e87 - e96. 10.1016/j.wneu.2020.04.168 . hal-03491283

HAL Id: hal-03491283

<https://hal.science/hal-03491283>

Submitted on 22 Aug 2022

HAL is a multi-disciplinary open access archive for the deposit and dissemination of scientific research documents, whether they are published or not. The documents may come from teaching and research institutions in France or abroad, or from public or private research centers.

L'archive ouverte pluridisciplinaire **HAL**, est destinée au dépôt et à la diffusion de documents scientifiques de niveau recherche, publiés ou non, émanant des établissements d'enseignement et de recherche français ou étrangers, des laboratoires publics ou privés.



Distributed under a Creative Commons Attribution - NonCommercial 4.0 International License

TITLE PAGE

Title:

NEW INSIGHTS INTO EXPRESSION OF HORMONAL RECEPTORS BY MENINGIOMAS

Authors:

Sylvain PORTET, MD^{a,b*}

Tania BANOR, resident^{a,b}

Jonathan BOUSQUET, resident^{a,b}

Adrien SIMONNEAU, MD^c

Marie FLORES, MD^{a,d}

Pierre INGRAND, MD-PhD^{a,e}

Serge MILIN, MD^{a,d}

Lucie KARAYAN-TAPON, MD-PhD^{a,f,g}

Benoit BATAILLE, MD^{a,b}

Affiliations:

^a Faculty of Medicine, University of Poitiers, 86021 Poitiers, France.

^b Department of Neurosurgery, University Hospital of Poitiers, 86021 Poitiers, France.

^c Department of Neurosurgery, Fondation Ophtalmologique Adolphe de Rothschild, 75019 Paris, France.

^d Pathology Department, University Hospital of Poitiers, 86021 Poitiers, France.

^e Department of Statistics, University Hospital of Poitiers, 86021 Poitiers, France.

^f INSERM 1084, Experimental and Clinical Neurosciences Laboratory, University of Poitiers, 86073 Poitiers, France.

^g Cancer Biology Department, University Hospital of Poitiers, 86021 Poitiers, France.

Corresponding author:

*Corresponding author: mail address: portetsylvain@gmail.com, telephone: +33 6 47 92 42 00.

Keywords:

meningioma, cyproterone acetate, progesterone receptor, estrogen receptor, androgen receptor

Running title:

HORMONAL RECEPTORS IN MENINGIOMAS

Funding:

This research did not receive any specific grant from funding agencies in the public, commercial, or not-for-profit sectors.

Conflict of interest:

All authors declare that there is no conflict of interest regarding the publication of this article.

Word count:

Abstract word count: 249

Text word count: 3491

Number of references: 43

Number of tables and/or figures (total): 6

Number of videos: 0

ABSTRACT

Objective. Meningiomas have a female predilection which is even stronger for spinal than for intracranial meningiomas. The relationship between meningiomas and endogenous or exogenous sex hormones such as cyproterone acetate (CPA) is well-documented, yet their underlying mechanism remains unknown. Clarification of the expression profile of hormonal receptors by meningiomas would help us to better understand their hormonal susceptibility.

Methods. We used tissue-microarray and immunohistochemistry to determine the receptor status of the three main sex hormones: androgen (AR), estrogen (ER) and progesterone (PR) in 30 intracranial meningiomas, 30 spinal meningiomas and 30 meningiomas developed on CPA.

Results. AR status was positive in 73% of meningiomas of the intracranial group, 87% of meningiomas of the CPA group and in all meningiomas of the spinal group. ER status was positive in only 7% of meningiomas of the intracranial group and in only 3% of meningiomas of the CPA group but in 30% of meningiomas of the spinal group. PR status was positive in 90% of meningiomas of the intracranial group, in 97% of meningiomas of the CPA group and in 87% of meningiomas of the spinal group. These specific hormonal receptor statuses based on immunoreactive score were reflected on staining intensities. Furthermore, AR and PR expression were correlated in each group.

Conclusion. Our study shows that intracranial meningiomas, spinal meningiomas and meningiomas developed on CPA express very specific hormonal receptor patterns. This result invites the scientific community to review the potential role of AR in the unbalanced sex ratio of meningiomas.

INTRODUCTION

Meningiomas may occur anywhere that arachnoid cells are found, which means between brain and skull, within ventricles, and along spinal cord.¹ They are classified according to their localizations in 2 groups: intracranial and spinal. Intracranial meningiomas are the most frequent brain tumors in adults and spinal meningiomas account for 10% of all meningiomas and about 30% of intradural extramedullary tumors.^{2,3} From a histopathologic perspective, meningiomas are mostly WHO classification grade I and their most frequent architectural pattern is meningothelial, whatever their localization.⁴ Prevalence for intracranial meningiomas is higher in females with a sex ratio of 2:1 while spinal meningiomas have a stronger sex predilection with females accounting for 75-90% of cases.^{5,6}

It is now well-documented that meningiomas have endogenous and exogenous sex hormonal susceptibility. The higher incidence of meningiomas among women, their behavior during pregnancy, the reported epidemiological link between meningiomas and breast carcinomas, and increased meningioma risk associated with the use of progestins, such as cyproterone acetate (CPA, Androcur®), have led to the assumption that sex steroid hormones may influence the growth of meningiomas.⁷⁻¹⁰ Up until now hormonal therapy may have offered some benefits to selected patients with recurrent tumors, but they have failed to show efficacy in prospective trials.¹¹

To explain this hormonal influence, numerous reports have dealt with the presence or absence of hormonal receptors in the tumors. It is generally agreed that most meningiomas express progesterone receptor (PR) but are devoid of estrogen receptor (ER).^{12,13} The results of some studies have indicated that PR expression in meningiomas is related to the tumor's grade and recurrence.¹⁴ The role of androgen receptors (AR) in meningiomas is unknown. A significant correlation of the AR with PR has been reported suggesting that AR rather than ER may regulate PR in meningiomas.¹⁵ Furthermore, despite contradictory studies on AR status, it seems that women express more AR mRNA than men.^{16,17}

While these results concern intracranial meningiomas developed in the general population, the specific expression profile of sex hormonal receptors by spinal meningiomas and by meningiomas developed on hormonal treatment has not been sufficiently explored.

Here, we have assessed clinical cases of different kinds of meningiomas including intracranial, spinal and those developed on CPA by tissue-microarray (TMA) and immunohistochemistry (IHC) and we have highlighted typical histologic features. We compared androgen, estrogen and progesterone receptor status between each group to search for specific expression patterns.

MATERIALS AND METHODS

This is an observational study, descriptive and comparative, conducted at the University Hospital Center of Poitiers (UHCP), in collaboration with the Adolphe de Rothschild Foundation Hospital (RFH) in Paris. The study was validated by the Committee of Biologic Resources of UHCP (identification number BB0033-00068).

Patients and Specimens

The tumor samples were obtained from patients who had undergone surgery between 2005 and 2019. None had received radiotherapy before surgery. The specimens consisted of Formalin Fixed, Paraffin Embedded (FFPE) tissue sections, with at least 60% of tumor cells. All meningioma samples were reviewed by a neuropathologist (S.M.) and classified according to the 2016 WHO classification.¹⁸ Tumor samples of meningiomas developed on high-dose cyproterone acetate (CPA group) were collected from 2 tumor banks (5 from the tumor bank of UHCP and 25 from RFH). We only included patients with regulatory indications for Androcur® which are severe hirsutism with a serious impact on the patient's psycho-emotional and social life in women and prostate cancer in men. Clinical information on these patients is available in Table 1. Our 30 spinal meningiomas (spinal group) were all collected from the UHCP tumor bank. None were developed on Androcur®. Our results were compared to a series of 30 intracranial adult meningiomas without informed history of Androcur® (intracranial or control group) collected from the UHCP tumor bank. The meningioma cohorts used in this study are representative of the general patient populations at our institutions. The selection of meningiomas was made regardless of grade, age and sex in order to study general intracranial, spinal and CPA groups.

Tissue-microarray

For each meningioma, a zone of interest was selected on the hematoxylin and eosin (H&E) stain section by a neuropathologist (S.M.). These zones were then transferred to the corresponding paraffin block. Core drilling was performed in the zone of interest and deposited in a virgin paraffin block (3 cores of 1 mm diameter per zone). A 3µm section of the TMA block was then carried out.

Immunohistochemistry

The IHC step was performed on VENTANA BenchMark automaton (ROCHE), according to the recommendations of the supplier. We used the UltraView Universal DAB Detection Kit (ref: 760-500, supplier: ROCHE) and specific rabbit antibodies for each receptor: Anti-AR, clone SP107, ref: 760-4605, supplier:

ROCHE, Anti-ER, clone SP1, ref: 790-4324, supplier: ROCHE and Anti-PR, clone 1E2, ref: 790-2223, supplier: ROCHE. These antibodies were localized by a cocktail of secondary antibodies labeled with enzymes. The complex was then revealed using hydrogen peroxide as a substrate and 3,3'-diaminobenzidine-tetrahydrochloride (DAB) as a chromogen, which produced a brown precipitate, easily identified by light microscope.

The staining protocol consisted of several steps in which the reagents are incubated for a predetermined time at specific temperatures. After each incubation, the BenchMark analyzer rinsed the tissue sections to remove unbound material and deposited on the slide a liquid coverslip to minimize evaporation of aqueous reagents. The results were interpreted using a light microscope. For each antibody, a positive and a negative control were made. Results obtained with this product were interpreted by a qualified neuropathologist (S.M.) in relation to histological examination, relevant clinical data and appropriate controls.

Receptor status was determined by a semiquantitative scoring scale with respect to staining intensity (graded according to the recommendations for immunohistochemistry of hormonal receptors on paraffin sections as: 0, absent; 1, weak; 2, moderate; and 3, strong)¹⁹ (Figure 1) and percentage of positive tumor cells (0, indicating the absence of positive nuclei; 1, the presence of a few positive tumor nuclei, 10% in the entire section; 2, an estimated 10–50% of positive nuclei; 3, 51–80% of positive tumor nuclei; and 4, > 80% of positive tumor nuclei). As recommended for breast cancer,²⁰ and verified with meningioma tissue,²¹ an immunoreactive score (IRS) was calculated for each tumor by multiplying the staining intensity by the indicator for positive tumor cells, producing an IRS range from 0 to 12. Tumors with an IRS of 2 or more were considered receptor positive (+).

Statistical Analysis

The analyses were conducted using SAS 9.4 software. Associations between variables were assessed with Fisher's exact test. Correlations between expression of AR and PR in our series were estimated by Spearman's rank correlation coefficient. A *p*-value less than 0.05 was considered significant.

RESULTS

Intracranial group

Our intracranial, control, group comprised 23 female patients and 7 male patients, with mean age of 60 years. All meningiomas were supratentorial and 8 (27%) were localized in the skull base. This group presented 22 (73%) grade I and 8 (27%) grade II (classified grade II based on cellular atypia N=8). In this group there were 11 (37%) meningothelial meningiomas, 9 (30%) transitional meningiomas, 2 (7%) fibroblastic meningiomas and none were of the microcystic, psammomatous, metaplastic or chordoid subtypes (Figure 2 and Table 2).

CPA group

Our CPA group consisted of 29 female patients and only one male patient. Mean age was 50 years. The sex ratio was very unbalanced with a strong prevalence of females since in a majority of cases they are the patients in whom Androcur® is indicated. All women in the CPA group had received 25mg/day Androcur® for management of hirsutism. The one male patient of our group had used Androcur® at a dose of 100mg/day for treatment of prostate cancer. Of the 30 patients who had been exposed to Androcur®, 26 (86.7%) had prolonged exposure >10 years and 21 (70%) had clinical and/or radiographic improvement upon discontinuation of the treatment (Table 1) but remained symptomatic. All meningiomas were inside the skull with 26 (86.7%) in the skull base and only 4 (13.3%) in the convexities. A positive relation was found between skull base localization of meningiomas and use of Androcur® ($p<0.0001$) (Figure 2 and Table 2). Twenty-seven (90%) meningiomas of the CPA group were grade I, and 3 (10%) were grade II (classified grade II based on focal invasion of the cerebral parenchyma n=2, and grade II due to the presence of a major chordoid component n=1). Our CPA group included 17 (57%) meningothelial meningiomas, 6 (20%) transitional meningiomas, 3 (10%) microcystic, 1 (3%) metaplastic and 1 (3%) chordoid. Fifteen (50%) meningiomas developed on Androcur® treatment had microcystic components. A positive association was observed between microcystic histology and Androcur® use ($p=0.026$) (Figure 2 and Table 2).

Spinal group

Our spinal group included 27 female patients and 3 male patients, with mean age of 73 years. Four (13%) were localized in the cervical spine, 25 (83%) in the thoracic spine and only one (3%) was in the lumbar spine. All meningiomas of the spinal group were grade I. A positive relation was found between spine localization and low-grade ($p<0.0046$) (Table 2). In this group, 13 (43%) meningiomas were meningothelial, 6 (20%) were transitional and 11 (37%) were psammomatous (Figure 2 and Table 2). Regarding major and minor components,

27 (90%) spinal meningiomas had psammomatous components. A positive association was shown between psammomatous histology and spinal localization ($p<0.0001$) (Figure 2 and Table 2).

Intracranial meningiomas, spinal meningiomas and meningiomas developed on CPA express very specific hormonal receptor patterns.

Hormonal status

AR status was positive in 22 (73%) meningiomas of the intracranial group, in 26 (87%) meningiomas of the CPA group and in all meningiomas (100%) of the spinal group (Figure 2 and Table 2). ER status was positive in only 2 (7%) meningiomas of the intracranial group and in only 1 (3%) meningiomas of the CPA group, but it was positive in 9 (30%) meningiomas of the spinal group (Figure 2 and Table 2). PR status was positive in 27 (90%) meningiomas of the intracranial group, in 29 (97%) meningiomas of the CPA group and in 26 (87%) meningiomas of the spinal group (Figure 2 and Table 2).

Staining intensity

AR immunoreactivity was significantly stronger in spinal meningiomas (1=7 (23%), 2=12 (40%), 3=11 (37%), mean staining intensity=2.1) than in intracranial meningiomas (1=10 (33%), 2=7 (23%), 3=5 (17%), mean staining intensity=1.3; $p=0.005$) and than in meningiomas developed on CPA (1=12 (40%), 2=10 (33%), 3=4 (13%), mean staining intensity=1.5; $p=0.029$) (Figure 2, Figure 3 and Table 2). There was no significant difference in PR staining intensity between intracranial meningiomas and meningiomas developed on CPA. ER staining intensity was significantly higher in spinal meningiomas (1=9 (30%), 2=0, 3=0) than in intracranial meningiomas (1=2 (7%), 2=0, 3=0; $p=0.042$) and than in meningiomas developed on CPA (1=1 (3%), 2=0, 3=0; $p=0.0012$) (Figure 2, Figure 3 and Table 2). There was no significant difference in ER staining intensity between intracranial meningiomas and meningiomas developed on CPA. When we compared staining intensity, it appeared that meningiomas developed on CPA expressed significantly stronger the PR (1=2 (7%), 2=2 (7%), 3=25 (83%), mean staining intensity=2.7) than spontaneous intracranial meningiomas (1=9 (30%), 2=6 (20%), 3=13 (43%), mean staining intensity=2; $p=0.010$) and than spinal meningiomas (1=5 (17%), 2=14 (47%), 3=10 (33%), mean staining intensity=2.1; $p=0.0002$) (Figure 2, Figure 3 and Table 2). There was no significant difference in PR staining intensity between intracranial meningiomas and spinal meningiomas.

Expression profile of hormonal receptor status depends on some clinical and histopathological features.

Considering our whole series of meningiomas, 71 (90%) female patients were AR+, 12 (15%) were ER+ and 77 (97%) were PR+ while only 11 (64%), 0 and 9 (82%) male patients were AR+, ER+ and PR+ respectively. There

was no significant association between gender and ER or PR status but there was a significant association between being a woman and being AR+ ($p=0.037$) (Table 3).

There was no association between any hormonal receptor status and histological types, but there was a significant association between having a psammomatous component and being AR+ ($p=0.015$). Indeed, on 27 meningiomas with a psammomatous component, all (100%) were AR+, whereas on 63 meningiomas without psammomatous component only 51 (81%) were AR+ (Table 3). There was also a significant association between having a psammomatous component and being ER+ ($p=0.0007$). Indeed, on 27 meningiomas with psammomatous component, 9 (33%) were ER+, whereas on 63 meningiomas without psammomatous component only 3 (5%) were ER+ (Table 3). PR status did not reach significance considering this histopathological feature (Table 3). Location at the skull base and WHO grades were not significantly associated with hormonal receptor status (Table 3).

Finally, regarding the distribution of PR staining intensity values according to AR staining intensity values, we found significant correlations in our different series: whole series ($p=0.0006$), CPA group ($p=0.0016$), control group ($p=0.031$) and spinal group ($p=0.016$).

DISCUSSION

Our results suggest that meningioma cells express different patterns of sex hormonal receptors according to tumor localization: inside the skull or along the spine. Furthermore, meningiomas arising on CPA have not the same hormonal receptor status as spontaneous, intracranial or spinal meningiomas. Indeed, in our study, spinal meningiomas are more often AR+ and ER+ than intracranial meningiomas, whether or not they have been exposed to CPA. And meningiomas developed on CPA are more often PR+ than other meningiomas, regardless of the site of the tumor. These specific hormonal receptor statuses based on IRS are reflected on staining intensities.

Progesterone Receptor

Our three groups of meningiomas are widely PR+ (> 90% in each group). These results confirmed the ubiquity of PR in meningiomas.¹² Unfortunately, and despite a trend, the lack of samples in our series did not allow us to draw conclusions about an association between low-grade meningioma and PR+ ($p=0.0072$), as has been suggested in several studies.^{13,16,22,23} While almost all published studies have detected high levels of PR in meningiomas, it remains unclear whether their function is activating or inhibiting. PR has two different isoforms: type A and B. PR-A has a repressive action on steroid receptors and in particular on isoform B.²⁴ PR-B has a better affinity with progesterone and a dominant action which is activating.^{24,25} As progesterone, or its agonists, interacts with these 2 isoforms, we decided to use Anti-PR, which targets PR-A and PR-B indifferently, in order to define the whole PR status of meningiomas without preconceptions on the intracellular molecular chain reactions induced by these 2 kinds of receptor. But a subsequent study using specific antibodies for each isoform would be of great interest to further clarify the PR status of meningiomas.

Meningioma risk associated with the use of progesterone agonists, such as CPA, has been described by several authors but so far, none have analyzed the hormonal receptor status of these tumors in a comparative study.^{26,27} CPA is a synthetic steroid derived from 17-hydroxyprogesterone with antiandrogenic properties. As a progestin, it interacts with PR. From this standpoint, it is very interesting to see that in our study meningiomas developed on CPA are the most RP+ with 97% positivity and have the strongest RP immunoreactivity with a mean staining intensity evaluated at 2.7. This specific RP status seems to constitute a favorable environment to onco-pharmacologic interaction between meningioma and Androcur®, which is fully logical. Furthermore, the results of our CPA group point toward preferential skull base localization for meningiomas arising on Androcur® use.

This point must be correlated with the mutational status of skull base meningiomas, in particular mutations of the PI3K pathway, as several studies have shown.^{9,10,28,29} It has also been observed that skull base meningiomas had significantly higher PR expression than non-skull base meningiomas.³⁰ We can assume that meningiomas developed on CPA are more frequent in the skull base because of tumor cells on this site expressing higher PR+ and are more often PI3K-mutated. PR status could be the starter of the onco-pharmacological interaction with CPA and molecular status could be the driver of this interaction. In sum, our study reinforces the idea of a link between PR expression and the development of meningiomas and gives new insight into interaction between meningiomas and progesterone agonists.

Estrogen receptor

In our study, as in the literature,⁵ ER immunostaining was found only in scattered occasional cell nuclei in intracranial meningiomas, whether or not they had been exposed to CPA. But surprisingly, ER status was significantly different in spinal meningiomas. Indeed, despite poor staining intensity, which did not exceed 1+, meningiomas along the spinal cord are more often ER+ than other meningiomas (30% of spinal meningioma were ER+ while > 90% of other meningiomas were ER-). As PR, ER also has 2 isoforms: alpha and beta, with 44% of meningiomas expressing ER-alpha mRNA and 68% expressing ER-beta mRNA.³¹ Once again, we decided to use Anti-ER, which targets the 2 ER isoforms indifferently, in order to define the whole ER status of meningiomas. In breast cancer, ER-beta+ seems to be involved in resistance to tamoxifen but no similar data exist for meningioma response.³² This lack of information about ER isoforms and the common ER- status of intracranial meningiomas may explain why anti-estrogen drugs such as tamoxifen as a treatment option for meningioma have led to inconclusive results.³³ In view of these elements, our results invite the scientific community to continue the study of the expression of the different ER isoforms by meningiomas, especially spinal meningiomas. Moreover, our study gives new insight into anti-estrogen drugs used as a treatment option for ER+ meningiomas.

Androgen receptor

AR expression was fairly common in our series (from 73% to 100% according to the group). This result on AR status is in agreement with several studies on this subject.^{5,17} Furthermore, we found that more women than men express AR (respectively 90% and 64%). This difference according to gender has been described in the literature, especially by studying AR mRNA expression.¹⁶ Even more interesting is that we found a significant

correlation between AR and PR expression in each group. Although this correlation has previously been described,^{17,34} for the first time we showed it on different meningioma populations including spinal meningiomas and meningiomas developed on CPA. While nuclear localization of AR suggests its functional relevance, its role in meningiomagenesis remains unknown. Because AR and PR expressions seem correlated, some researchers have suggested that AR may regulate PR in meningiomas,¹⁵ although it seems more likely that AR and PR regulate each other. It has also been shown that AR in meningiomas has the capacity to bind androgens with high affinity.³⁵ Considering its prognostic value, it is well-documented that AR may play dual roles in the promotion of cell growth and apoptosis in other hormone-dependent tumors.^{36,37} In meningiomas, some authors have suggested that AR may indirectly represent tumor growth potential.³⁸ Another study found a greater mortality of spinal meningiomas among males.³⁹ In our study, positive relations were found between on the one hand spine localization and on the other hand low-grade and spine localization and AR+, we would tend to conclude that AR+ is a favorable prognosis factor. Considering AR and PR correlated expression, this agrees with authors who have suggested a more favorable prognosis for PR+ meningiomas.^{22,40} Unfortunately, in vitro studies have produced mixed results and did not allow us to draw a conclusion on the role of androgen in the development of meningiomas.⁴¹ For some authors the expression profile of hormonal receptors could not explain the sex ratio of meningiomas,³⁹ but given the highly unbalanced sex ratio of spinal meningiomas reported in the literature,⁴² and the very specific hormonal receptor patterns expressed by spinal meningiomas in our study (including high AR positivity), we can assume that AR plays an underestimated role in sex predilection. There are currently no clinical trials investigating anti-androgen therapies but in light of our findings, it could be interesting to continue in vitro investigations on androgen effects in the development of meningiomas.

Histological features

Despite a low number of cases by groups, our results were coherent with available data in the literature for each meningioma population. Moreover, the strength of our study lies in its CPA sample size: with 30 meningiomas developed on CPA intake, it constitutes the largest group described in the literature. As previously described,^{4,10} we found meningothelioma to be the predominant histological subtype of intracranial and spinal meningiomas. On spinal meningiomas, some studies have concluded that psammomatous is the main subtype.⁴³ This point is very interesting and not totally in contradiction with our findings; it is well-known that meningiomas are histologically heterogeneous tumors in which we classically distinguish one major component and some minor components. In our spinal group, psammomatous was the second most frequent subtype (37%) after

meningothelial (43%). But looking at it more closely, 90% of spinal meningiomas had psammomatous components (11 had major components and 16 had minor psammomatous components) while none of the intracranial meningiomas had this component, whether or not they had been exposed to CPA. The significant association that we found between presence of psammoma bodies and spinal localization is congruent with the literature mentioned above. As for the meningiomas developed on CPA, half of them showed microcystic components: 3 had major components and 12 had minor microcystic components of variable importance. Given that microcystic meningiomas commonly represent only 1.6% of meningiomas,⁴⁴ our findings imply an association between microcystic components and exposure to Androcur®. Minor components have not been thoroughly described but these significant associations lead to the assumption that they might be an indirect marker of underlying mechanisms of meningiomagenesis.

Limitations

The sex ratio between our three cohorts was quite unbalanced with a strong prevalence of females and a subsequent study with sex-matched control would be of great interest to ascertain our results.

Our study was designed to clarify the expression profile of hormonal receptors by meningiomas bringing new insights on spinal meningiomas and meningiomas developed on CPA. We did not study the prognostic value of sex hormonal receptors or their correlation with cellular proliferation or apoptosis biomarkers. These points could be interesting to study in subsequent works in order to better understand the roles of hormone receptors in meningiomagenesis.

In conclusion, the discovery of divergences in hormonal receptor status between intracranial meningiomas, spinal meningiomas and meningiomas developed on CPA facilitates the understanding of the underlying chemical mechanisms involved in the hormonal sensitivity of these tumors. We hypothesize that PR is the starter of the interaction between meningioma and CPA and that AR plays an underestimated role in the unbalanced sex ratio of meningiomas. The refinement of our knowledge on hormonal susceptibility of meningiomas could have a direct impact on the diagnosis and management of these tumors.

ACKNOWLEDGMENTS

The authors wish to thank J. ARSHAM, an American translator, for having reviewed and revised the original English-language text. We thank J. GODET for her technical help.

REFERENCES

1. Kalamarides M, Niwa-Kawakita M, Leblois H, et al. Nf2 gene inactivation in arachnoidal cells is rate-limiting for meningioma development in the mouse. *Genes Dev.* 2002;16(9):1060-1065. doi:10.1101/gad.226302
2. Louis DN, Perry A, Reifenberger G, et al. The 2016 World Health Organization Classification of Tumors of the Central Nervous System: a summary. *Acta Neuropathol.* 2016;131(6):803-820. doi:10.1007/s00401-016-1545-1
3. Romdhane A, André A, Clémenceau S, Kalamarides M, Carpentier A, Cornu P. Méningiomes rachidiens : une série de 55 cas. *Neurochirurgie.* 2017;63(1):51-52. doi:10.1016/j.neuchi.2016.11.058
4. Lee JH, Sade B, Choi E, Golubic M, Prayson R. Meningothelioma as the predominant histological subtype of midline skull base and spinal meningioma. *Journal of Neurosurgery.* 2006;105(1):60-64. doi:10.3171/jns.2006.105.1.60
5. Claus EB, Bondy ML, Schildkraut JM, Wiemels JL, Wrensch M, Black PM. Epidemiology of Intracranial Meningioma: *Neurosurgery.* 2005;57(6):1088-1095. doi:10.1227/01.NEU.0000188281.91351.B9
6. Koeller KK, Shih RY. Intradural Extramedullary Spinal Neoplasms: Radiologic-Pathologic Correlation. *Radiographics.* 2019;39(2):468-490. doi:10.1148/rg.2019180200
7. Miller RE. Breast cancer and meningioma. *J Surg Oncol.* 1986;31(3):182-183.
8. Bickerstaff ER, Small JM, Guest IA. THE RELAPSING COURSE OF CERTAIN MENINGIOMAS IN RELATION TO PREGNANCY AND MENSTRUATION*. *J Neurol Neurosurg Psychiatry.* 1958;21(2):89-91.
9. Peyre M, Gaillard S, de Marcellus C, et al. Progestin-associated shift of meningioma mutational landscape. *Ann Oncol.* 2018;29(3):681-686. doi:10.1093/annonc/mdx763
10. Portet S, Naoufal R, Tachon G, et al. Histomolecular characterization of intracranial meningiomas developed in patients exposed to high-dose cyproterone acetate: an antiandrogen treatment. *Neuro Oncol Adv.* 2019;1(1). doi:10.1093/noajnl/vdz003
11. Grunberg SM, Weiss MH, Spitz IM, et al. Treatment of unresectable meningiomas with the antiprogestone agent mifepristone. *J Neurosurg.* 1991;74(6):861-866. doi:10.3171/jns.1991.74.6.0861
12. Blaauw G, Blankenstein MA, Lamberts SW. Sex steroid receptors in human meningiomas. *Acta*

- Neurochir (Wien)*. 1986;79(1):42-47.
13. Pravdenkova S, Al-Mefty O, Sawyer J, Husain M. Progesterone and estrogen receptors: opposing prognostic indicators in meningiomas. *J Neurosurg*. 2006;105(2):163-173. doi:10.3171/jns.2006.105.2.163
 14. Strik HM, Strobelt I, Pietsch-Breitfeld B, Iglesias-Rozas JR, Will B, Meyermann R. The impact of progesterone receptor expression on relapse in the long-term clinical course of 93 benign meningiomas. *In Vivo*. 2002;16(4):265-270.
 15. Maxwell M, Galanopoulos T, Neville-Golden J, Antoniades HN. Expression of androgen and progesterone receptors in primary human meningiomas. *J Neurosurg*. 1993;78(3):456-462. doi:10.3171/jns.1993.78.3.0456
 16. Baxter DS, Orrego A, Rosenfeld JV, Mathiesen T. An audit of immunohistochemical marker patterns in meningioma. *Journal of Clinical Neuroscience*. 2014;21(3):421-426. doi:10.1016/j.jocn.2013.06.008
 17. Carroll RS, Zhang J, Dashner K, Sar M, Wilson EM, Black PM. Androgen receptor expression in meningiomas. *J Neurosurg*. 1995;82(3):453-460. doi:10.3171/jns.1995.82.3.0453
 18. Banan R, Hartmann C. The new WHO 2016 classification of brain tumors—what neurosurgeons need to know. *Acta Neurochir*. 2017;159(3):403-418. doi:10.1007/s00701-016-3062-3
 19. [Recommendations for the immunohistochemistry of the hormonal receptors on paraffin sections in breast cancer. Update 1999. Group for Evaluation of Prognostic Factors using Immunohistochemistry in Breast Cancer (GEFPICS-FNCLCC)]. *Ann Pathol*. 1999;19(4):336-343.
 20. Remmele W, Stegner HE. [Recommendation for uniform definition of an immunoreactive score (IRS) for immunohistochemical estrogen receptor detection (ER-ICA) in breast cancer tissue]. *Pathologe*. 1987;8(3):138-140.
 21. Brandis A, Mirzai S, Tatagiba M, Walter GF, Samii M, Ostertag H. Immunohistochemical detection of female sex hormone receptors in meningiomas: correlation with clinical and histological features. *Neurosurgery*. 1993;33(2):212-217; discussion 217-218.
 22. Hsu DW, Efird JT, Hedley-Whyte ET. Progesterone and estrogen receptors in meningiomas: prognostic considerations. *J Neurosurg*. 1997;86(1):113-120. doi:10.3171/jns.1997.86.1.0113
 23. Roser F, Nakamura M, Bellinzona M, Rosahl SK, Ostertag H, Samii M. The prognostic value of progesterone receptor status in meningiomas. *J Clin Pathol*. 2004;57(10):1033-1037. doi:10.1136/jcp.2004.018333

24. Tung L, Mohamed MK, Hoeffler JP, Takimoto GS, Horwitz KB. Antagonist-occupied human progesterone B-receptors activate transcription without binding to progesterone response elements and are dominantly inhibited by A-receptors. *Mol Endocrinol.* 1993;7(10):1256-1265. doi:10.1210/mend.7.10.8123133
25. Connaghan-Jones KD, Heneghan AF, Miura MT, Bain DL. Thermodynamic analysis of progesterone receptor–promoter interactions reveals a molecular model for isoform-specific function. *Proc Natl Acad Sci U S A.* 2007;104(7):2187-2192. doi:10.1073/pnas.0608848104
26. Bernat AL, Oyama K, Hamdi S, et al. Growth stabilization and regression of meningiomas after discontinuation of cyproterone acetate: a case series of 12 patients. *Acta Neurochir.* 2015;157(10):1741-1746. doi:10.1007/s00701-015-2532-3
27. Gil M, Oliva B, Timoner J, Maciá MA, Bryant V, de Abajo FJ. Risk of meningioma among users of high doses of cyproterone acetate as compared with the general population: evidence from a population-based cohort study. *Br J Clin Pharmacol.* 2011;72(6):965-968. doi:10.1111/j.1365-2125.2011.04031.x
28. Abedalthagafi M, Bi WL, Aizer AA, et al. Oncogenic PI3K mutations are as common as AKT1 and SMO mutations in meningioma. *Neuro Oncol.* 2016;18(5):649-655. doi:10.1093/neuonc/nov316
29. Yesilöz Ü, Kirches E, Hartmann C, et al. Frequent AKT1E17K mutations in skull base meningiomas are associated with mTOR and ERK1/2 activation and reduced time to tumor recurrence. *Neuro Oncol.* 2017. doi:10.1093/neuonc/nox018
30. Kuroi Y, Matsumoto K, Shibuya M, Kasuya H. Progesterone Receptor Is Responsible for Benign Biology of Skull Base Meningioma. *World Neurosurg.* 2018;118:e918-e924. doi:10.1016/j.wneu.2018.07.100
31. Carroll RS, Zhang J, Black PM. Expression of estrogen receptors alpha and beta in human meningiomas. *J Neurooncol.* 1999;42(2):109-116.
32. Speirs V, Malone C, Walton DS, Kerin MJ, Atkin SL. Increased expression of estrogen receptor beta mRNA in tamoxifen-resistant breast cancer patients. *Cancer Res.* 1999;59(21):5421-5424.
33. Goodwin JW, Crowley J, Eyre HJ, Stafford B, Jaeckle KA, Townsend JJ. A phase II evaluation of tamoxifen in unresectable or refractory meningiomas: a Southwest Oncology Group study. *J Neurooncol.* 1993;15(1):75-77.
34. Moguilewsky M, Pertuiset BF, Verzat C, Philibert D, Philippon J, Poisson M. Cytosolic and nuclear sex steroid receptors in meningioma. *Clin Neuropharmacol.* 1984;7(4):375-381.

35. Lesch KP, Engl HG, Gross S. Androgen receptor binding activity in meningiomas. *Surg Neurol.* 1987;28(3):176-180.
36. Zhao XY, Ly LH, Peehl DM, Feldman D. Induction of androgen receptor by 1alpha,25-dihydroxyvitamin D3 and 9-cis retinoic acid in LNCaP human prostate cancer cells. *Endocrinology.* 1999;140(3):1205-1212. doi:10.1210/endo.140.3.6561
37. Olsen NJ, Viselli SM, Fan J, Kovacs WJ. Androgens accelerate thymocyte apoptosis. *Endocrinology.* 1998;139(2):748-752. doi:10.1210/endo.139.2.5729
38. Chen J, Chen G. Expression of androgen receptor in meningiomas. *J Tongji Med Univ.* 2001;21(2):140-142.
39. Westwick HJ, Shamji MF. Effects of sex on the incidence and prognosis of spinal meningiomas: a Surveillance, Epidemiology, and End Results study. *J Neurosurg Spine.* 2015;23(3):368-373. doi:10.3171/2014.12.SPINE14974
40. Nagashima G, Aoyagi M, Wakimoto H, Tamaki M, Ohno K, Hirakawa K. Immunohistochemical detection of progesterone receptors and the correlation with Ki-67 labeling indices in paraffin-embedded sections of meningiomas. *Neurosurgery.* 1995;37(3):478-482; discussion 483. doi:10.1227/00006123-199509000-00016
41. Gibelli N, Zibera C, Butti G, et al. Hormonal modulation of brain tumour growth: a cell culture study. *Acta Neurochir (Wien).* 1989;101(3-4):129-133.
42. Solero CL, Fornari M, Giombini S, et al. Spinal meningiomas: review of 174 operated cases. *Neurosurgery.* 1989;25(2):153-160.
43. Schaller B. Spinal meningioma: relationship between histological subtypes and surgical outcome? *J Neurooncol.* 2005;75(2):157-161. doi:10.1007/s11060-005-1469-4
44. Matsushima N, Maeda M, Takamura M, Matsubara T, Taki W, Takeda K. MRI findings of atypical meningioma with microcystic changes. *J Neurooncol.* 2007;82(3):319-321. doi:10.1007/s11060-006-9285-z

FIGURE LEGENDS

Figure 1. Illustrations of tissue-microarray staining intensities (from 0 to 3+) in meningiomas. X20

Figure 2. Histopathology and hormonal receptor status of the 3 clinical groups: intracranial meningiomas (left part), meningiomas developed on cyproterone acetate (CPA) (middle part) and spinal meningiomas (right part). Data are shown for all patient samples for which tissue-microarray and immunohistochemistry were performed. Panel A: patient demographic data. Panel B: clinical classification. Panel C: histopathological findings. Panel D: hormonal receptor status.

Figure 3. Hormonal receptor patterns for each clinical group. The left column shows diagrams summarizing the expression profile of hormonal receptors for intracranial meningiomas (A), meningiomas developed on cyproterone acetate (CPA) (B) and spinal meningiomas (C). The receptor status was determined by a semiquantitative scoring scale with respect to staining intensity (graded as: 0, absent; 1, weak; 2, moderate; and 3, strong). The right column shows hematoxylin and eosin stain sections of most frequent components in each group of meningiomas: (A) meningothelial, characterized by sheets, whorls or syncytia of neoplastic cells which have round or oval centrally located nuclei and dispersed chromatin, smooth nuclear profiles and small indistinct nucleoli. (B) microcystic, with extracellular spaces, scattered throughout the meningioma substrate and (C) psammomatous, rich in psammoma bodies, in calcospherites and whose the stroma may contain an amyloid substance. x20

Table 1. Radio-clinical evolution of meningiomas in patients exposed to high dose cyproterone acetate (CPA) after CPA discontinuation.

Table 2. Clinical information and histopathological data on patients in the intracranial group (I), in the cyproterone acetate (CPA) group (C) and in the spinal group (S).

Table 3. Distribution of clinical and histopathological characteristics of meningiomas according to their receptor status: androgen receptor (AR), estrogen receptor (ER) and progesterone receptor (PR).

Figure 1.

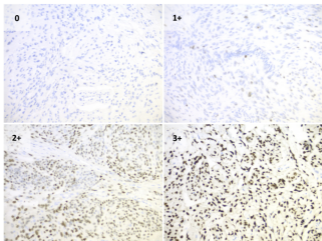


Figure 2.

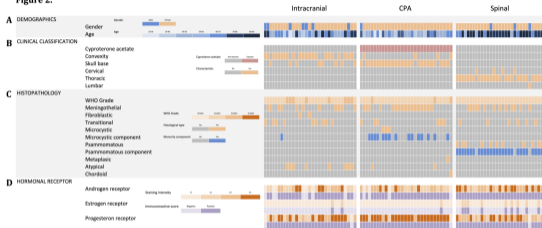


Figure 3.

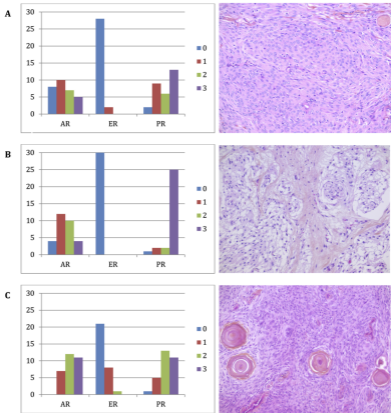


Table 1.

	Radio-clinical evolution after CPA discontinuation		
	Decline	Stable	Improvement
High dose CPA exposure >10 years	0	8	18
High dose CPA exposure <10 years	0	1	3

Table 2.

Analysis variable	Category	CPA		Intracranial		P(C/I)	Spinal		P(S/I)	P(C/S)
		N	%	N	%		N	%		
Female		29	97%	23	77%	0.052	27	90%	0.299	0.612
Topography										
	Skull base	26	87%	8	27%	<0.0001	0	0%		
	Convexity	4	13%	22	73%		0	0%		
	Cervical						4	13%		
	Thoracic						25	83%		
	Lumbar					1	3%			
Grade 2		3	10%	8	27%	0.181	0	0%	0.0046	0.237
Histology						0.026			<0.0001	0.0005
	Meningothelial	17	57%	11	37%		13	43%		
	Fibroblastic	0	0%	2	7%		0	0%		
	Transitional	6	20%	9	30%		6	20%		
	Microcystic	3	10%	0	0%		0	0%		
	Psammomatous	0	0%	0	0%		11	37%		
	Metaplastic	1	3%	0	0%		0	0%		
	Chordoid	1	3%	0	0%		0	0%		
	Atypical	2	7%	8	27%		0	0%		
	Total	30	100%	30	100%		30	100%		
Microcystic component		15	50%	1	3%	<0.0001	0	0%	1	<0.0001
Psammomatous component		0	0%	0	0%	1	27	90%	<0.0001	<0.0001
AR						0.550			0.005	0.029
	0	4	13%	8	27%		0	0%		
	1+	12	40%	10	33%		7	23%		
	2+	10	33%	7	23%		12	40%		
	3+	4	13%	5	17%		11	37%		
ER						1			0.042	0.0012
	0	29	97%	28	93%		21	70%		
	1+	1	3%	2	7%		9	30%		
	2+	0	0%	0	0%		0	0%		
	3+	0	0%	0	0%		0	0%		
PR						0.010			0.145	0.0002
	0	1	3%	2	7%		1	3%		
	1+	2	7%	9	30%		5	17%		
	2+	2	7%	6	20%		14	47%		
	3+	25	83%	13	43%		10	33%		

Table 3.

Analysis variable	Category	N	AR+		P	ER+		P	PR+		P
			N	%		N	%		N	%	
Gender					0,037			0,348			0,072
	Female	79	71	90%		12	15%		77	97%	
	Male	11	7	64%		0	0%		9	82%	
Topography					0,524			0,124			0,293
	Skull base	34	31	91%		2	6%		34	100%	
	Other	56	47	84%		10	18%		52	93%	
Grade					0,161			0,348			0,072
	1	79	70	89%		12	15%		77	97%	
	2	11	8	73%		0	0%		9	82%	
Histology					0,163			0,301			0,107
	Meningothelial	41	37	90%		4	10%		40	98%	
	Fibroblastic	2	2	100%		0	0%		2	100%	
	Transitional	21	17	81%		4	19%		20	95%	
	Microcystic	3	2	67%		0	0%		3	100%	
	Psammomatous	11	11	100%		4	36%		11	100%	
	Metaplastic	1	1	100%		0	0%		1	100%	
	Chordoid	1	0	0%		0	0%		0	0%	
	Atypical	10	8	80%		0	0%		9	90%	
Microcystic component					0,999			0,115			0,999
	Absent	74	64	86%		12	16%		70	95%	
	Present	16	14	88%		0	0%		16	100%	
Psammomatous component					0,015			0,0007			0,312
	Absent	63	51	81%		3	5%		59	94%	
	Present	27	27	100%		9	33%		27	100%	