



HAL
open science

Ritonavir associated maculopathy– multimodal imaging and electrophysiology findings

Roxane Bunod, Alexandra Miere, Olivia Zambrowski, Pierre-Marie Girard, Laure Surgers, Eric H. Souied

► **To cite this version:**

Roxane Bunod, Alexandra Miere, Olivia Zambrowski, Pierre-Marie Girard, Laure Surgers, et al.. Ritonavir associated maculopathy– multimodal imaging and electrophysiology findings. *American Journal of Ophthalmology Case Reports*, 2020, 19, pp.100783. <10.1016/j.ajoc.2020.100783>. <hal-03491254>

HAL Id: hal-03491254

<https://hal.science/hal-03491254v1>

Submitted on 22 Aug 2022

HAL is a multi-disciplinary open access archive for the deposit and dissemination of scientific research documents, whether they are published or not. The documents may come from teaching and research institutions in France or abroad, or from public or private research centers.

L'archive ouverte pluridisciplinaire **HAL**, est destinée au dépôt et à la diffusion de documents scientifiques de niveau recherche, publiés ou non, émanant des établissements d'enseignement et de recherche français ou étrangers, des laboratoires publics ou privés.



Distributed under a Creative Commons CC BY-NC 4.0 - Attribution - Non-commercial use - International License

1 Keywords: maculopathy; HIV; antiretroviral medication; ritonavir; multimodal imaging

2

3 Summary statement:

4 We describe the case of a patient 47 year-old HIV patient presenting with bilateral symmetric

5 macular atrophy. Both multimodal imaging, functional testing of the retina and history of drug

6 exposure are consistent with ritonavir associated maculopathy.

7

8

9

10

11

12

13

14

15

16

17

18

19

20

21

22

23

24

25

26

27

28

29

30

31

32

33

34

35

36

37

38

1 **Abstract**

2 Purpose: To report the case 47-year-old patient presenting with severe maculopathy
3 associated with long-term ritonavir treatment.

4 Methods: Observational case report of one patient and literature review.

5 Results: A 47 year-old Caucasian man presented with progressive bilateral vision loss for the
6 past 5 years. His medical history included Human Immunodeficiency Virus (HIV) and
7 Hepatitis C Virus (HCV) coinfection since 1992. He was treated by highly active
8 antiretroviral therapy for 24 years including 4 years of didanosine treatment and 18 years of
9 ritonavir treatment. Bilateral extensive macular atrophy with foveal sparing on the left eye
10 and absence of midperipheral/peripheral retina involvement was confirmed on multimodal
11 imaging and functional testing including swept-source OCT angiography and
12 electroretinography.

13 Conclusion: Ritonavir associated maculopathy is a scarcely described medication-associated
14 retinopathy. In this case, an extensive macular atrophy (with complete loss of photoreceptor,
15 RPE and choriocapillaris layers) and subsequent cone-rod dysfunction appeared after 18 years
16 of ritonavir exposure.

17
18
19
20
21
22
23
24
25

1 **Introduction**

2

3 Ritonavir is an antiretroviral drug widely used since 1996 for the treatment of human
4 immunodeficiency virus (HIV) infection. It belongs to the class of protease inhibitors that
5 prevent viral replication by blocking the cleavage of viral protein precursors. Because of its
6 inhibition effect on major cytochrome P450 isoforms (CYP3A4, CYP2D6), ritonavir is now
7 used in combination as a pharmaceutic enhancer / booster in highly active antiretroviral
8 therapy. The major side effects are hepatotoxicity, digestive functional disturbances,
9 lipohypertrophy syndrome and the risk of drug interactions due to cytochrome inhibition.
10 Rare cases of retinopathy have been reported in literature since 2011 with heterogeneous
11 phenotypes ranging from macular atrophy, intra retinal cysts, macular telangiectasia¹ to
12 retinitis pigmentosa-like presentation². We report a case of severe maculopathy, defined by
13 structural and functional outer retinal and choriocapillaris disturbances, in an HIV infected
14 patient with 18 years ritonavir exposition.

15

16 **Case Report**

17 A 47-year-old Caucasian male, with a medical history of HIV and Hepatitis C virus (HCV)
18 infection, presented in the Creteil University Eye Hospital complaining of long standing
19 bilateral loss of vision. He reported a progressive visual loss starting 5 years before. He was
20 diagnosed with HIV and HCV in 1992 following abnormal liver function tests and received
21 antiretroviral therapy since 1994.

22 Table 1 summarizes the antiretroviral treatment taken by the patient since 1994. During this
23 period, the patient was exposed to didanosine for 4 years and to ritonavir for 18 years.

24 The patient had switched to dolutegravir plus etravirine treatment two months before the first
25 ophthalmologic examination.

26 Last CD4+ count was 425/mm³ and HIV plasma viral load was undetectable (below 20

1 copies/ml). Liver aspartate transaminase (AST) and alanine transaminase (ALT) were normal
2 at last follow up. The patient neither had family history of ocular disease nor other medical
3 condition. Neither did he have a history of deafness, renal dysfunction or diabetes. Testing for
4 tuberculosis and syphilis were negative. The patient had no history of HIV retinopathy or
5 Cytomegalovirus (CMV) retinitis.

6 The patient has never received Pentosan Polysulfate Sodium (PPS) treatment but reported the
7 use of various recreational psychoactive drugs. Namely, he took gamma hydroxybutyrate
8 (GHB) every week from 2009 to 2012, and then inhaled cocaine on a monthly basis from
9 2012 to 2014. In 2010 he started to take intravenously 4-methylethylcathinone (4-MEC) (Slam
10 practices) several times per month and increased the rate of injections to three times weekly
11 from 2012 to 2014 before reducing injections to once monthly until 2016 when he stopped
12 completely.

13 On examination, his best corrected visual acuity (BCVA) was 20/50 on the right eye and
14 20/25 on the left eye. The anterior segment examination on both eyes was unremarkable, with
15 no signs of inflammation. Fundus examination revealed, on both eyes, an extensive area of
16 macular atrophy; the optic nerve, retinal vessels, vitreous and retinal mid- and extreme-
17 periphery were normal without vitreous cells or evidence of prior uveitis or retinitis (figure 1).

18 Infrared reflectance imaging (IR) demonstrated well demarcated, polylobulated
19 hyperreflective macular atrophy converging with peripapillary atrophy. Multiple
20 hyperreflective dots were noted on IR images within the atrophic lesions. On fundus blue
21 laser autofluorescence (FAF), symmetric hypoautofluorescent extensive areas of retinal
22 pigment epithelium (RPE) atrophy were noted, surrounded by a circumferential ring of
23 speckled hyperautofluorescence pattern reaching the temporal arcades (figure 2).

24 Spectral domain optical coherence tomography (SD-OCT, Spectralis, Heidelberg
25 Engineering, Heidelberg, Germany) revealed complete RPE and outer retinal atrophy

1 (cRORA)³ accompanied by outer retinal tubulations (ORT). On the left eye, foveal sparing
2 was noted, with the preservation of the ellipsoid zone. Enhanced depth imaging SD-OCT
3 coupled with IR allowed the colocalization of the hyperreflective dots in IR with choroidal
4 angular hyporefective cavities, suggestive for choroidal caverns⁴ (figure 3). A window
5 defect, characterized by well demarcated hyperfluorescent areas corresponding to outer retinal
6 and RPE atrophy were observed on fluorescein angiography (FA). A heterogeneous
7 hyperfluorescent speckled pattern surrounding the atrophic areas overlapped with the
8 hyperautofluorescent speckle pattern seen on FAF (figure 2). Indocyanine green angiography
9 showed macular hypofluorescent lesions, corresponding to the atrophic areas, with
10 visualization of large choroidal vessels. Widefield swept-source optical coherence
11 tomography angiography (SS-OCTA, PlexElite, Zeiss, Dublin, CA) revealed a large macular
12 area of choriocapillaris alterations on both eyes (figure 4). The 6x6 mm SS-OCTA showed a
13 well demarcated area of choriocapillaris alteration, revealed by the lack of decorrelation
14 signal, allowing visualization of large choroidal vessels.

15 Besides structural exams, the patient underwent a series of functional tests, including color
16 vision, Goldman and Humphrey visual fields and electrophysiology exams (ffERG and
17 mfERG). Full-field ERG (Moncolor system, Metrovision, Perenchies, France) and multifocal
18 ERG (mfERG, Espion Diagnosys LLC, Lowell, MA) were recorded accordingly to 2015
19 ISCEV standards with DTL electrodes in mydriasis. Reduced color discrimination in the
20 tritan axis was found on Roth 28-Hue Test. Both Goldman and Humphrey visual fields
21 demonstrated a bilateral central scotoma (figure 5). However, on the left eye, an isle of
22 preserved retinal sensitivity was noted in the foveal area, corresponding to the preserved
23 ellipsoid zone observed on structural SD-OCT. The full field electroretinogram (ffERG)
24 demonstrated a moderated cone-rod dysfunction, associated with an increased flicker delay.
25 Furthermore, multifocal ERG (mfERG) responses are non-discernible from the background

1 noise with a complete loss of foveal peak. Predominantly on his left eye, non-systematized
2 focal responses are observed corresponding to the preserved ellipsoid zone area seen on SD-
3 OCT. Electrophysiological findings, with retinal dysfunction, were consistent with the
4 structural disturbances seen in this patient (Supplementary material).

5

6 **Discussion**

7 We report here the case of an HIV positive patient with a long standing loss of vision
8 secondary to bilateral macular atrophy. While HIV retinopathy, opportunistic infections and
9 unusual malignancy are the main causes of retinal complications, drug toxicity has to be
10 considered as a potential cause. Indeed, HIV patients tend to be exposed to multiple
11 medications such as clofazamine, zidovudine, didanosine or ritonavir for which associated
12 retinopathies have been reported.

13 The patient was exposed to didanosine for 4 years, ritonavir for 18 years but also to 4-
14 methylethylcathinone (4-MEC) for 6 years. 4-MEC are synthetic cathinones that have
15 recently emerged and became a popular recreational drug⁵. A spectrum of adverse effects has
16 been reported by consumers but, to the best of our knowledge, no retinal toxicity has yet been
17 described. Conversely, several case reports have described didanosine retinal toxicity in HIV
18 positive patients⁶. Even though didanosine toxicity generates chorioretinal atrophy and
19 degeneration, it classically involves the retinal midperiphery. In the present case, the lack of
20 midperipheral choriocapillaris loss was not consistent with didanosine toxicity (figure 4).

21 The first case series reporting retinal abnormalities in HIV positive patients treated by
22 ritonavir was published in 2011 by Roe et al and described three patients exhibiting various
23 degrees of bilateral macular RPE atrophy, accompanied by macular telangiectasia, cystic
24 spaces and parafoveal intraretinal crystals¹. It is interesting to note that these three patients
25 had a history of liver dysfunction, as is the case with our patient which had HIV and HCV

1 coinfection. As studies in humans have demonstrated that ritonavir is primarily eliminated by
2 the hepatobiliary system, it is possible that the liver dysfunction in these patients may have
3 reduced ritonavir elimination and caused increased circulating drug levels. Among the three
4 patients, a large area of complete outer retina and RPE atrophy with foveal sparing
5 comparable to our patient has been observed in the patient having had the longer exposure to
6 ritonavir (5 years). Biancardi et al. reported another case of macular patchy RPE atrophy
7 surrounded, on FAF, by a speckle autofluorescent pattern, similar to our patient⁷.

8 Electrophysiological features of ritonavir associated maculopathy described in a patient
9 having received ritonavir for seven years also demonstrated a slightly reduced ffERG for both
10 eyes and bilateral maculopathy on mfERG⁸. These functional findings are comparable with
11 the electrophysiology exams of our patient.

12 There were no clinical argument for hereditary maculopathies such as Maternally Inherited
13 Diabetes and Deafness (MIDD), Mitochondrial Encephalomyopathy with Lactic Acidosis and
14 Stroke-like episodes (MELAS), Stargardt disease, Cone-Rod dystrophy, Pattern dystrophy or
15 Central Areolar Choroidal Dystrophy (CACD). However, a limit of our study is the absence
16 of genetic testing for hereditary maculopathies.

17 Ritonavir toxicity has been studied in animal model⁹. With treatment duration up to 6
18 months, the main target organs were the liver and the eyes. The corollary of these animal
19 models was the assumption that retinal degeneration and/or retinal pigment epithelium
20 hypertrophy were related to phospholipidosis. Amorphous granular inclusion bodies,
21 characteristic of phospholipidosis, were found on electron micrographs in the retina of mice,
22 rats and dogs. This phenomenon may be in relation with the enzymatic regulation of
23 cholesterol and lipogenic pathways by ritonavir. It has been suggested that intra retinal
24 crystals correspond to phospholipidosis phenomenon⁸. There were no crystal deposits on our
25 patient imaging but this finding seems to be inconstant throughout ritonavir associated

1 retinopathy in literature, notably absent in cases with extensive atrophy. Another hypothesis
2 regarding ritonavir toxicity is related to the anti-angiogenic effect of ritonavir demonstrated in
3 vitro RPE cell-lines¹⁰. Given that, vascular endothelial growth factor, a known neurotrophic
4 agent, inhibition by ritonavir may explain RPE degeneration.

5

6 In conclusion, although ritonavir associated maculopathy is very uncommon, literature
7 suggests that the natural history of this maculopathy consists of early stage crystalline
8 deposits, RPE degeneration, degenerative cystic spaced and, finally, extensive atrophy, such
9 as our patient. However, further studies are necessary in order to prove a mechanism of
10 toxicity.

11

12

1 **References**

2 1. Roe RH, Jumper JM, Gualino V, et al. Retinal pigment epitheliopathy, macular
3 telangiectasis, and intraretinal crystal deposits in HIV-positive patients receiving ritonavir.
4 *Retina (Philadelphia, Pa)*. 2011;31(3):559-565. doi:10.1097/IAE.0b013e3181f0d2c4
5
6 2. Papavasileiou E, Younis S, Zygoura V, Quijano C, Jackson TL. RITONAVIR-
7 ASSOCIATED TOXICITY MIMICKING RETINITIS PIGMENTOSA IN AN HIV-
8 INFECTED PATIENT ON HIGHLY ACTIVE ANTIRETROVIRAL THERAPY. *Retin*
9 *Cases Brief Rep*. 2017;11(4):306-309. doi:10.1097/ICB.0000000000000350
10
11 3. Holz FG, Sadda SR, Staurenghi G, et al. Imaging Protocols in Clinical Studies in
12 Advanced Age-Related Macular Degeneration: Recommendations from Classification of
13 Atrophy Consensus Meetings. *Ophthalmology*. 2017;124(4):464-478.
14 doi:10.1016/j.ophtha.2016.12.002
15
16 4. Querques G, Costanzo E, Miere A, Capuano V, Souied EH. Choroidal Caverns: A
17 Novel Optical Coherence Tomography Finding in Geographic Atrophy. *Investigative*
18 *Ophthalmology & Visual Science*. 2016;57(6):2578. doi:10.1167/iovs.16-19083
19
20 5. Smith PR, Cole R, Hamilton S, West K, Morley SR, Maskell PD. Reporting Two
21 Fatalities Associated with the Use of 4-Methylethcathinone (4-MEC) and a Review of the
22 Literature. *J Anal Toxicol*. 2016;40(7):553-560. doi:10.1093/jat/bkw061
23
24 6. Haug SJ, Wong RW, Day S, et al. DIDANOSINE RETINAL TOXICITY. *Retina*
25 *(Philadelphia, Pa)*. 2016;36 Suppl 1:S159-S167. doi:10.1097/IAE.0000000000001267
26
27 7. Biancardi AL, Curi ALL. Retinal Toxicity Related to Long-term Use of Ritonavir.
28 *Retina (Philadelphia, Pa)*. 2016;36(1):229-231. doi:10.1097/IAE.0000000000000695
29
30 8. Faure C, Paques M, Audo I. Electrophysiological features and multimodal imaging in
31 ritonavir-related maculopathy. *Documenta Ophthalmologica*. 2017;135(3):241-248.
32 doi:10.1007/s10633-017-9612-z
33
34 9. European Medicines Agency. Scientific discussion for the approval of Norvir.
35 [http://www.ema.europa.eu/docs/en_GB/
36 document_library/EPAR_Scientific_Discussion/human/000127/WC500028725.pdf](http://www.ema.europa.eu/docs/en_GB/document_library/EPAR_Scientific_Discussion/human/000127/WC500028725.pdf).
37
38 10. Vadlapatla RK, Vadlapudi AD, Pal D, Mukherji M, Mitra AK. Ritonavir inhibits HIF-
39 1 α -mediated VEGF expression in retinal pigment epithelial cells in vitro. *Eye (Lond)*.
40 2014;28(1):93-101. doi:10.1038/eye.2013.240
41
42
43
44
45

1 **Table 1. Antiretroviral treatment since 1994**

Start of the treatment	End of the treatment	Treatment duration (months)	Antiretroviral treatment
10/8/1994	1/18/1995	12	zidovudine
10/18/1995	8/2/1996	9	didanosine, zidovudine
8/13/1996	10/16/1996	2	stavudine
10/16/1996	10/15/1997	12	lamivudine, stavudine
10/15/1997	9/28/1998	11	indinavir, lamivudine, stavudine
9/28/1998	7/27/1999	10	lamivudine, nelfinavir, stavudine
7/27/1999	2/22/2000	7	amprenavir, didanosine, nevirapine, stavudine
2/22/2000	11/7/2002	32	amprenavir, didanosine, nevirapine, ritonavir
11/7/2002	6/28/2005	32	lopinavir/ritonavir, tenofovir, nevirapine
6/28/2005	1/14/2016	128	lopinavir/ritonavir, tenofovir
1/14/2016	9/20/2018	32	darunavir, ritonavir
9/20/2018	...	2	dolutegravir, etravirine

2

3

4 **Figures Legends**

5 **Figure 1. Ultra widefield retinal photographs of the right (A) and left (B) eye show**

6 extensive areas of macular atrophy and normal optic nerve, retinal vessels, vitreous and retinal
7 mid- and extreme-periphery.

8

9 **Figure 2. Multimodal imaging of the right (A, C, E, G) and left (B, D, F, H) eye of the**
10 **patient.**

11 A, B. Infrared reflectance imaging (IR) demonstrating well demarcated hyperreflective
12 macular atrophy associated with multiple hyperreflective dots.

13 C, D. Fundus autofluorescence (FAF) showing symmetric hypoautofluorescent extensive
14 areas of RPE atrophy surrounded by a circumferential ring of speckled hyperautofluorescence
15 pattern reaching the temporal arcades.

16 E, F. On FA, a window defect, corresponding to outer retinal and RPE atrophy surrounded by
17 a heterogeneous hyperfluorescent speckled pattern.

18 G, H. Indocyanine green angiography showing macular hypofluorescent atrophic areas, with
19 visualization of large choroidal vessels.

1
2
3
4
5
6
7
8
9
10
11
12
13
14
15
16
17
18
19
20
21
22
23
24
25

Figure 3. Spectral domain Optical coherence tomography (SD-OCT) of the right (A, C,) and left (B, D) eyes of the patient.

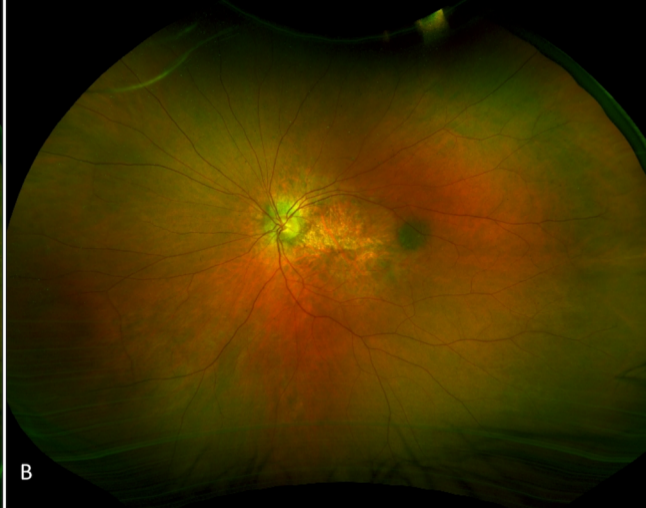
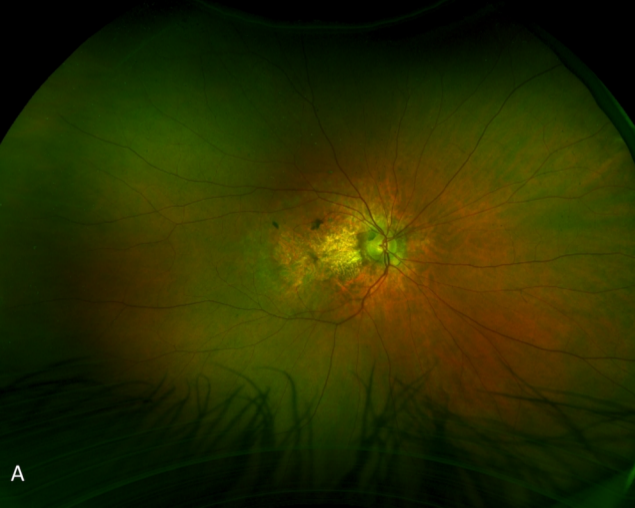
SD-OCT revealing complete RPE and outer retinal atrophy (cRORA) accompanied by ORT. Note the foveal sparing on the left eye with a persistent ellipsoide zone (white star). C, D. Enhanced depth imaging SD-OCT coupled with IR allowed the colocalization of the hyperreflective dots in IR with choroidal angular hyporefective cavities, suggestive for choroidal caverns (white arrows).

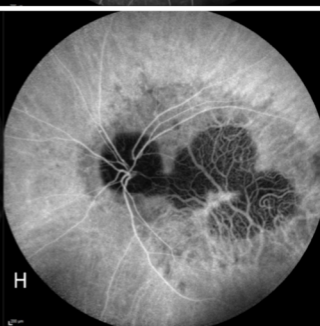
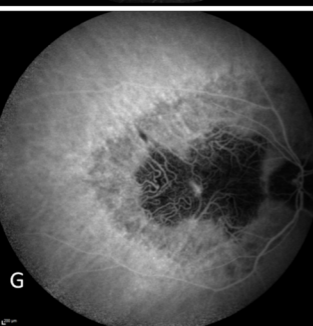
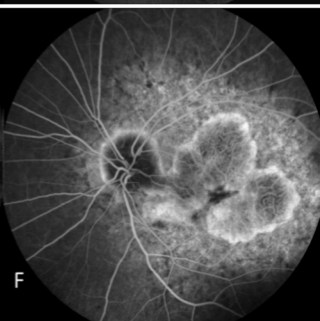
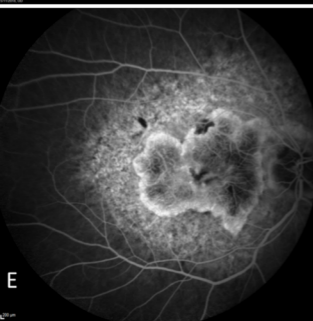
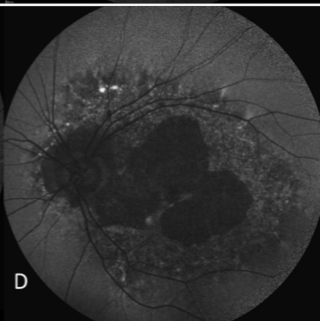
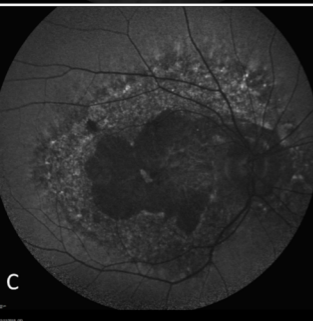
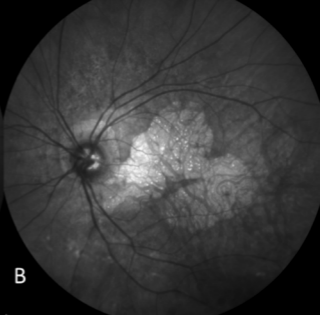
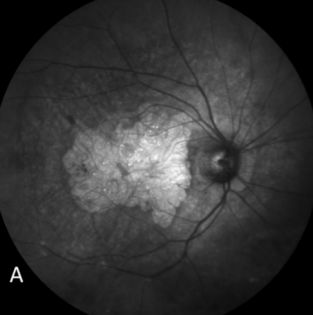
Figure 4. Optical coherence tomography angiography (OCTA) of the right (A, C, E) and left (B, D, F) eye of the patient.

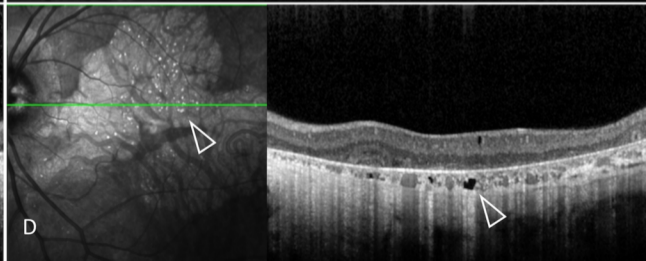
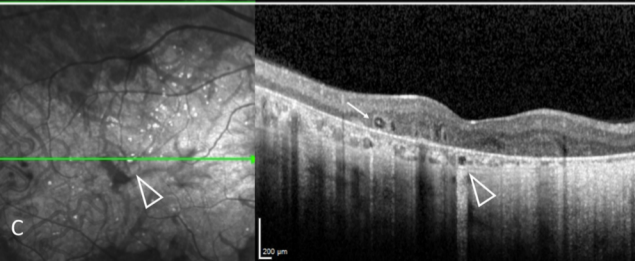
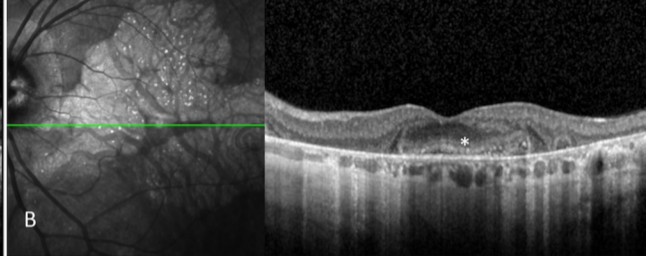
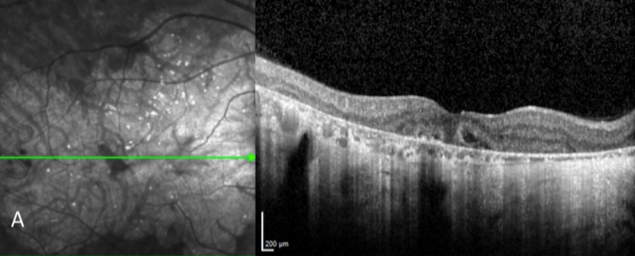
A, B. Widefield swept-source optical coherence tomography angiography (SS-OCTA) revealed a large area of choriocapillaris alterations on both eyes. C. 6x6 mm SS-OCTA showed a well demarcated area of choriocapillaris alteration, revealed by the lack of decorrelation signal (pink dotted line), allowing visualization of large choroidal vessels. D. Note the foveal sparing, with preserved choriocapillaris, on the left eye (green line) and the lack of retinal midperiphery alteration. E, F. Corresponding B-scan showing automatic choriocapillaris segmentation.

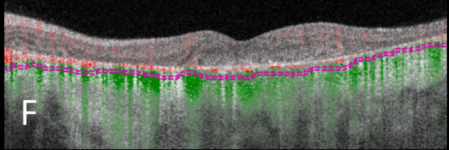
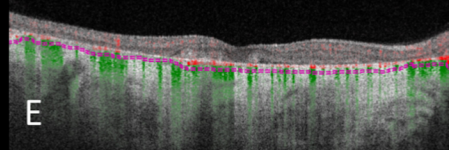
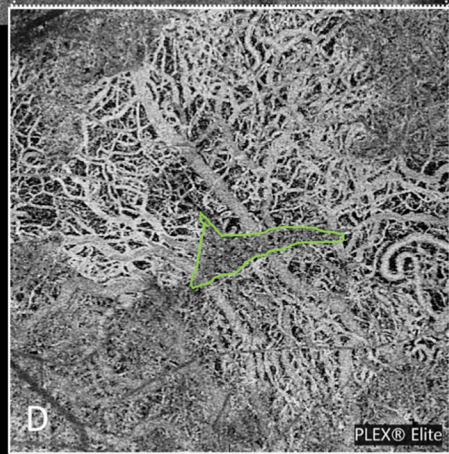
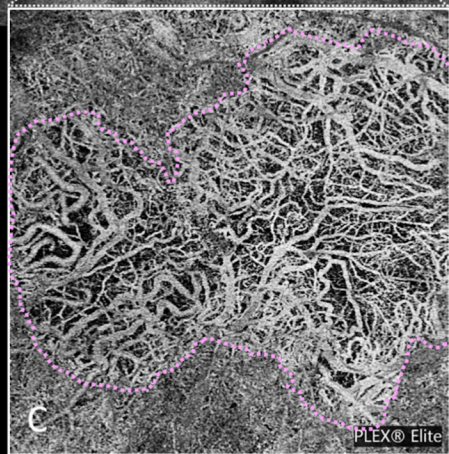
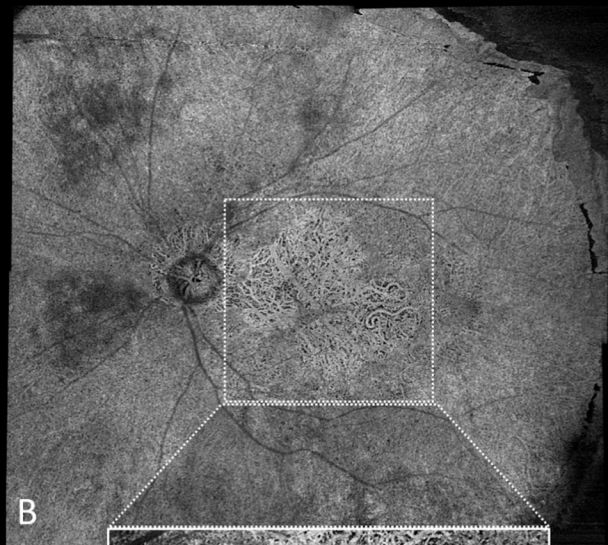
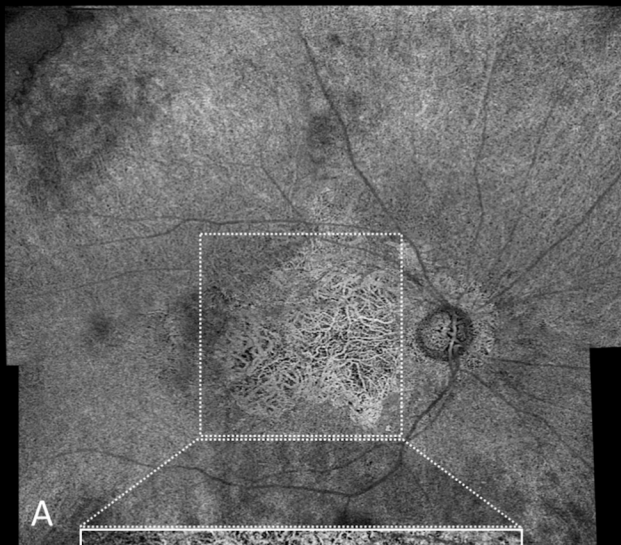
Figure 5. Visual fields of the left (A, C, E) and right (B, D, F) eye of the patient.

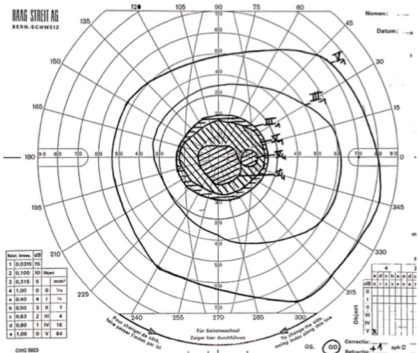

A, B. Goldman visual field. C, D. 24-2 Humphrey visual field. E, F. 10-2 Humphrey visual field. Visual fields showed a bilateral central scotoma with a preserved fixation point on the left eye.





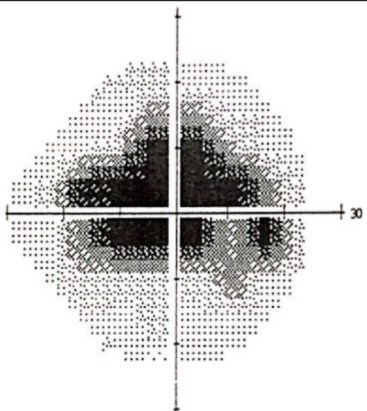
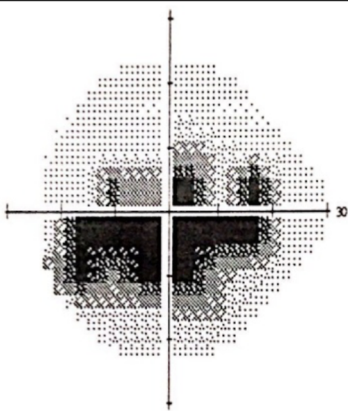








A

B



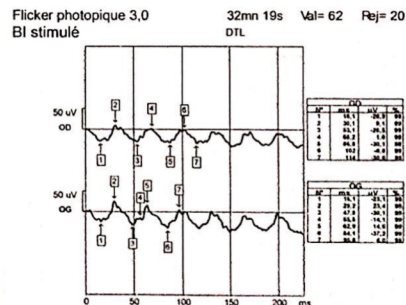
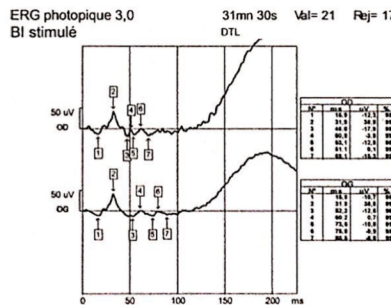
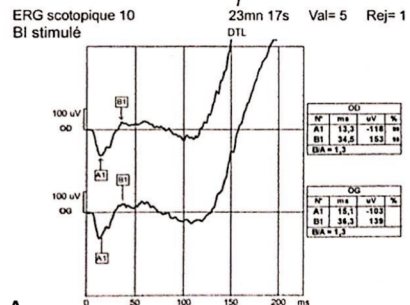
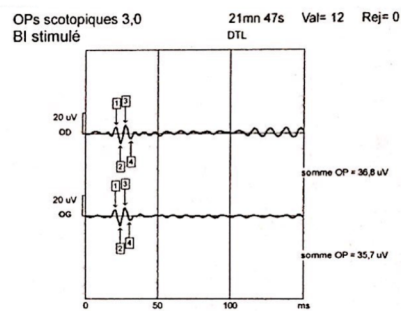
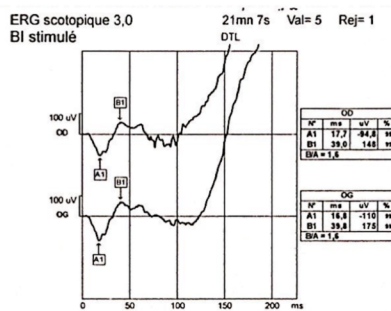
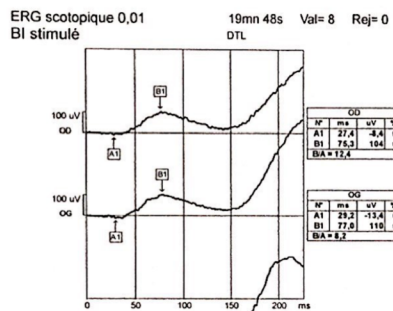
C

D




E


F



A



B



C