



HAL
open science

Clitoral reduction: Technical note

C. Uzan, F. Marchand, M. Schmidt, J.P. Meningaud, B. Hersant

► To cite this version:

C. Uzan, F. Marchand, M. Schmidt, J.P. Meningaud, B. Hersant. Clitoral reduction: Technical note. *Annales de Chirurgie Plastique Esthétique*, 2020, 65, pp.e7 - e13. <10.1016/j.anplas.2019.10.002>. <hal-03491232>

HAL Id: hal-03491232

<https://hal.science/hal-03491232v1>

Submitted on 22 Aug 2022

HAL is a multi-disciplinary open access archive for the deposit and dissemination of scientific research documents, whether they are published or not. The documents may come from teaching and research institutions in France or abroad, or from public or private research centers.

L'archive ouverte pluridisciplinaire HAL, est destinée au dépôt et à la diffusion de documents scientifiques de niveau recherche, publiés ou non, émanant des établissements d'enseignement et de recherche français ou étrangers, des laboratoires publics ou privés.



Distributed under a Creative Commons CC BY-NC 4.0 - Attribution - Non-commercial use - International License

CLITORAL REDUCTION : technical note

Clitoridoplastie de réduction : note technique

Uzan C. MD, Marchand F. MD, PHD, Schmidt M. MD, Meningaud JP. MD, PHD, Hersant B. MD, PHD.

Department of Maxillofacial and Plastic & Reconstructive Surgery Henri Mondor Hospital
51 avenue du Maréchal de Lattre de Tassigny
Créteil 94010, France

Tel: 33 1 49 81 25 31 Fax: 33 1 49 81 25 32

Introduction

There is little known about Plastic and reconstructive surgery techniques of the clitoris. The plastic surgeon might be confronted to manage cases of mutilation that are very frequent but also cases of hypertrophy which are rather rare (the most common cause; congenital adrenal hyperplasia has a prevalence of 1 out of 15,000 births) [1]. These two types of surgeries have one thing in common, which is the release of the clitoral root by cutting the suspensory ligament of the clitoris.

Clitoral hypertrophy (CH) is defined as the abnormal increase in clitoral size. In adults, one of the cut-off values that is used is a clitoral index (length x width of the glans) greater than 35 mm². CH may be a sign of hyperandrogenism, responsible for the virilization of the external genitalia. Clitoral hypertrophy is a genital malformation that can be either congenital or acquired. In congenital forms the most common cause is adrenal hyperplasia, Fraser syndrome is much rarer (a rare clinical entity defined by cryophthalmia and syndactyly). Acquired forms may be of endocrine origin (polycystic ovary syndrome, hyperthecosis, adrenal or ovarian tumours, exogenous exposure to androgens, hyperprolactinemia, hypothyroidism, Cushing's syndrome), caused by benign or malignant tumours; (neurofibroma, hemangioma, sarcoma, leiomyoma) and cysts (epidermal). [2]

Idiopathic clitoral hypertrophies are identified after eliminating all secondary causes. A complete assessment is needed to treat the cause of clitoridomegaly. Clitoral hypertrophy is often increased or unmasked during sexual arousal with the appearance of a true vulvar appendage in erection. This is often accompanied by a hypertrophy of the clitoral hood which can cause psychological suffering with a severe impact on the quality of sexual life, causing these patients to request a reduction surgery. [3,4,5,6]

The majority of patients are operated on during childhood. The optimal age of treatment remains controversial [7]. However, rather rarely we are also confronted with requests from adult women, in cases where the first surgery was not sufficient or in cases of idiopathic clitoral hypertrophies with late onset. [8]

Historically, treatment of CH consisted of an amputation of erectile bodies. [9] Before any surgery, the etiology must be first identified and treated.

The body of the clitoris is formed by the merging of the two cavernous bodies on the median line which are inserted on the ischio-pubic branches. It presents as elbow-shaped, bend down and back: the root of the clitoris, and a free bulging part: the glans of the clitoris (only the external and visible part). [10,11]. It is vascularized by the cavernous and dorsal arteries of the clitoris (branches of the pudendal arteries) and the clitoral branches of the pudendal arteries.

The veins of the clitoris drain towards the internal and external pudendal veins.

The innervation is multiple: in its pillars the plexuses are coming from the cavernous nerve and in its body, and on the dorsal surface runs the dorsal nerve of the clitoris, which is the terminal branch of the pudendal nerve [12]. There is a separate neurovascular pedicle on the dorsal side of the clitoral body located at 12 o'clock (cranially).

Current techniques consist of a resection of the glans and cavernous bodies in the longitudinal direction by a ventral approach to spare the neurovascular pedicle as according to Paniel's technique. [13]

The objective of this surgery is to partially reduce the body and the clitoral glans without altering its function.

Clitoral hypertrophies are very often associated with a hypertrophy of the clitoral hood and an associated expansion of it. In order to obtain a satisfactory result, it is important to perform a chevron incision of the hood if necessary. In case of an associated hypotrophy of the labia majora which the majority of patients present on clinical examination, the volume may be moderately increased by using a lipofilling technique. This allows the closure of the vulva, an improvement of the fleshy appearance and the local trophicity and will contribute to achieving an optimal aesthetic result.

In this paper we will present and discuss two cases where we used a technique of partial ventral reduction of the clitoris without dissection of the neurovascular pedicle together with a chevron plasty of the clitoral hood and lipofilling of the labia majora.

Clinical Case 1

We present a case of a 31-year-old female patient with Turner syndrome who had vaginoplasty at birth and surgery during adolescence.

Clinically, she shows a clitoral hypertrophy with a hypertrophy of the associated clitoral hood, as well as a hypotrophy of the labia majora. (Figure 1)

Her preoperative workup consisted of a clitoral ultrasound that eliminated the differential diagnosis of a cyst. She is currently taking Climen to compensate for her estrogen deficiency, while her surgical treatment consisted of a reduction of the clitoris and the hood, and lipofilling of the labia majora.

Clinical Case 2

The second case is a 28-year-old patient who has a hypertrophy of the clitoris and the clitoral hood as well as a hypotrophy of the labia majora of an unknown cause. The hormonal status, the ultrasound and MRI of the clitoris and abdominopelvis were found to be normal apart from the CH. The same surgical technique as described above was also performed in this case.

The immediate operative follow-up was satisfactory with a follow-up of over one year for the 1st patient and two years for the 2nd patient. Both patients expressed great satisfaction postoperatively, especially regarding the quality of sexual life. Direct stimulation of the clitoris during sexual activity did not cause pain or functional discomfort.

Surgical Technique

Installation:

Under general anesthesia, the patient is placed in a gynaecological position, and the vagina is disinfected with betadine to obtain a sterile surgical field. The placement of a urinary catheter is not required if there haven't been any sequelae from a previous surgery that have modified the anatomical relationships or having caused fibrosis, making dissection difficult.

Incisions:

The incision drawings are made with a sterile dermatographic pen before infiltration.

The infiltration is done with 1% xylocaine adrenaline in the subcutaneous plane along the future incision lines. The glans is put in traction with a suture which facilitates the dissection. The incision is circumferential in the balanopreputial sulcus or 3 mm more distally to preserve

the preputial skin which is sometimes required for the reconstruction.

Dissection:

The dissection which must preserve the pedicle is performed in the subcutaneous plane with scissors to remove the clitoral hood of the body down to the level of the root of the clitoris. The skin is retracted upwards towards the clitoral base exposing the dorsal fascia of the clitoris. This dissection must remain exclusively subcutaneous and superficial in order not to damage the dorsal pedicle of the clitoris. (Figure 2, 3)

Section of the Suspensory Ligament:

The suspensory ligament of the clitoris is divided directly on the pubic symphysis, allowing the lowering and anteversion of the clitoral root. (Figure 4)

Resection of Cavernous Bodies:

The resection is performed with an electrocautery, longitudinal in the axis of the clitoral body and involves the ventral part (1/3 or 1/2) of the cavernous body and the glans. (Figure 5, 6). Hemostasis is performed progressively and exclusively with bipolar forceps.

Plication and Fixation:

The clitoral flap is folded over itself with a plication bringing it back to the plane of the symphysis pubis. The flap is then fixed to the pre-pubic plane by separate sutures (Vicryl 4.0) giving it a normal length.

Closing:

A circumferential suture of the clitoral hood skin at the base of the clitoris is performed by separate sutures with Vicryl 4.0. The excess skin of the clitoral hood can either be resected or used to reconstruct the labia minora if they are hypotrophic.

Resection of the Clitoral Hood:

A chevron plasty with a V-Y closure of the dorsal side of the hood is performed to provide a normal clitoral cover. (Figure 7)

It is important to avoid the excessive resection of the clitoral hood which may lead to the exposition of the clitoris. This could result in postoperative pain.

Lipofilling of the labia majora:

Each side of the donor zone (inner aspect of the thighs or under the umbilicus) is infiltrated with about 40 cc of diluted adrenaline (1 mg/L).

The fat harvesting is performed with a closed system using a syringe (Colemann Technique). The fat is always rinsed and filtered in a closed system and is not centrifuged.

The fat injection is carried by a cannula using a single orifice placed 2 cm above the vaginal fourchette to minimise scarring. Lipofilling is carried out in a retrograde fashion using 10 cc syringes. Afterwards the donor side is massaged immediately to allow for a homogeneous distribution of the fat. (Figure 8)

The immediate postoperative view and at 3 months is satisfactory. (Figures 9, 10)

Post-Operative Care

Level I analgesics are often sufficient.

Daily cleaning is necessary with mild soap and water as well as the placement of sterile compresses to protect against rubbing with undergarments.

We recommend pausing sexual intercourse and bathing for three weeks.

Discussion

Clitoral surgery must respond to a complex demand: aesthetics, function and identity. Reduction clitoridoplasty has evolved considerably over the past 30 years, from amputation to dissection of the neurovascular pedicle to current techniques that preserve it.

Some spare the ventral and dorsal pedicles, others even perform this surgery under the microscope. [14]

Historically, surgeries were associated with loss of clitoral sensitivity or neurological pain often corresponding to dorsal nerve neuroma in the amputated area [7, 15, 16].

It seems, however, that the majority of findings concerning ventral resections as described in our article result in preservation of clitoral sensitivity and sexual function.

Sensitivity appears to be the same for patients who had clitoral reduction by ventral resections and those who were not operated on. [17] This was confirmed by our patients who were able to resume sexual intercourse including the use of the clitoris without embarrassment, or mechanical or neurological pain.

Partial resection as well as the degree of initial deformity directly influence the postoperative results regarding the sensitivity of the clitoris (especially when sparing the vascular pedicles) as well as sexual satisfaction. [15]

Surgery should be done simultaneously with other procedures if the morphological analysis shows a hypertrophy of the clitoral hood and/or hypotrophy of the labia majora, which has been the case in all our patients. Surgery is often performed together with lipofilling of the labia majora which gives excellent aesthetic results as it allows to cover the labia minora and clitoris, resembling the "normal" anatomy with a fleshy and closed aspect of the vulva.

However, there is little data on the long-term outcome of this surgery.

An objective assessment to rate the improvement of sexual quality of life has not been carried out yet. However, sexual satisfaction is obviously not only related to the postoperative anatomical result, but also to sexual identity, self-esteem, the relationship to others and to one's own body which are complex parameters to measure in patients with a disease or a congenital chronic malformation. The care of these patients should therefore be multidisciplinary and begin in teenagehood.

There may also be dysmorphophobia or a distortion of the perception of reality by these patients that must be reassured. The patient's own perception of their genitals is not correlated with the medical examination [6].

Genital plastic surgery is delicate, this is why we work in collaboration with our colleagues the gynaecologists and psychiatrists to secure the overall care of these patients.

Conclusion

Clitoral hypertrophy is a clinical sign that requires a search for an underlying pathology.




Differential diagnoses need to be ruled out and in case of an atypical clinical presentation, further clinical investigations such as imaging studies have to be carried out to find the cause of the hyperandrogenism. Although this type of surgery is rare in adult women and requires high precision, the plastic surgeon has all the therapeutic arsenal to treat these patients.

The objective of this procedure is to satisfy the aesthetic demand of the patient and preserve the sensory function of this organ. The combined techniques of clitoral reduction with plasty of the clitoral hood and lipofilling of the labia majora appear to be satisfactory in our patients.

References

- [1] Kaefer M, Rink RC. Treatment of the Enlarged Clitoris. *Frontiers in Pediatrics* [Internet]. 28 août 2017 [cité 16 janv 2019];5. Disponible sur: <http://journal.frontiersin.org/article/10.3389/fped.2017.00125/full>
- [2] Masson V, Fiquet François C, Rausky J, Mazouz Dorval S, Revol M. Clitoridomégalie dans le cadre un kyste épidermoïde géant : à propos d'un cas. *Annales de Chirurgie Plastique Esthétique*. avr 2014;59(2):140-3.
- [3] Lloyd J, Crouch NS, Minto CL, Liao L-M, Creighton SM. Female genital appearance: 'normality' unfolds. *BJOG: An International Journal of Obstetrics & Gynaecology*. mai 2005;112(5):643-6.
- [4] Gastaud F, Bouvattier C, Duranteau L, Brauner R, Thibaud E, Kuttén F, Bougnères P 2007 Impaired sexual and reproductive outcomes in women with classical forms of congenital adrenal hyperplasia. *J Clin Endocrinol Metab* 92:1391–1396
- [5] Morgan JF, Murphy H, Lacey JH, Conway G 2005 Long term psychological outcome for women with congenital adrenal hyperplasia: cross sectional survey. *BMJ* 330:340–341; discussion 341
- [6] Wisniewski AB, Migeon CJ, Malouf MA, Gearhart JP 2004 Psychosexual outcome in women affected by congenital adrenal hyperplasia due to 21-hydroxylase deficiency. *J Urol* 171:2497–2501
- [7] Minto CL, Liao LM, Woodhouse CR, Ransley PG, Creighton SM 2003 The effect of clitoral surgery on sexual outcome in individuals who have intersex conditions with ambiguous genitalia: a cross-sectional study. *Lancet* 361:1252–1257
- [8] Reifsnyder JE, Stites J, Bernabé KJ, Galan D, Felsen D, Poppas DP. Nerve Sparing Clitoroplasty is an Option for Adolescent and Adult Female Patients with Congenital Adrenal Hyperplasia and Clitoral Pain following Prior Clitoral Recession or Incomplete Reduction. *Journal of Urology*. avr 2016;195(4 Part 2):1270-4.
- [9] Lean WL, Hutson JM, Deshpande AV, Grover S. Clitoroplasty: past, present and future. *Pediatric Surgery International*. 21 mars 2007;23(4):289-93.
- [10] Baskin LS, Erol A, Li YW, Liu WH, Kurzrock E, Cunha GR. Anatomical studies of the human clitoris. *J Urol*.1999;162:1015
- [11] O'Connell HE, Sanjeevan KV, Hutson JM. Anatomy of the clitoris. *J Urol* (2005) 174:1189. doi:10.1097/01.ju.0000173639.38898.cd
- [12] Pauls RN. Anatomy of the clitoris and the female sexual response: Clitoral Anatomy and Sexual Function. *Clinical Anatomy*. avr 2015;28(3):376-84.
- [13] Arfi A, Lousquy R, Chevrot A, Haddad B, Paniel BJ, Touboul C. Ambiguïté sexuelle : comment je fais... une réduction clitoridienne ? *Gynécologie Obstétrique Fertilité & Sénologie*. févr 2017;45(2):119-21
- [14] Murakami M, Akira S, Tsuboi N, et al. Microscope-assisted reduction clitoroplasty used to treat two patients with clitoromegaly. *J Nippon Med Sch*. 2010;77(1):35–9
- [15] Crouch NS, Minto CL. Genital sensation after feminizing genitoplasty for congenital adrenal hyperplasia: a pilot study. *BJU INTERNATIONAL*. 2004;4.
- [16] Rangescroft L; British Association of Paediatric Surgeons Working Party on the Surgical Management of Children Born with Ambiguous Genitalia 2003 Surgical management of ambiguous genitalia. *Arch Dis Child* 88:799–801

[17] Nordenström A, Frisé L, Falhammar H, Filipsson H, Holmdahl G, Janson PO, et al. Sexual Function and Surgical Outcome in Women with Congenital Adrenal Hyperplasia Due to *CYP21A2* Deficiency: Clinical Perspective and the Patients' Perception. The Journal of Clinical Endocrinology & Metabolism. 1 août 2010;95(8):3633-40.

	<p>Figure 1 : Pre-operative</p>
	<p>Figure 2 : Subcutaneous dissection of the clitoris</p>
	<p>Figure 3 : Incision in the balanopreputial sulcus and subcutaneous dissection</p>

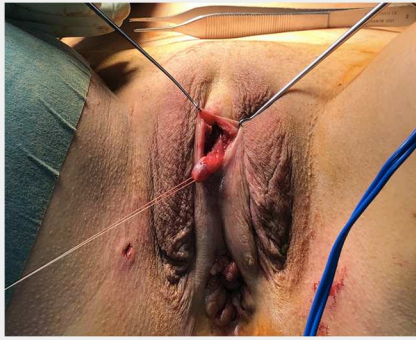


Figure 4 : Liberation and lowering of the clitoral body

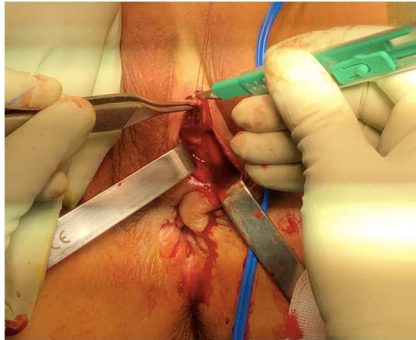


Figure 5 : Resection of the ventral part of the clitoral body

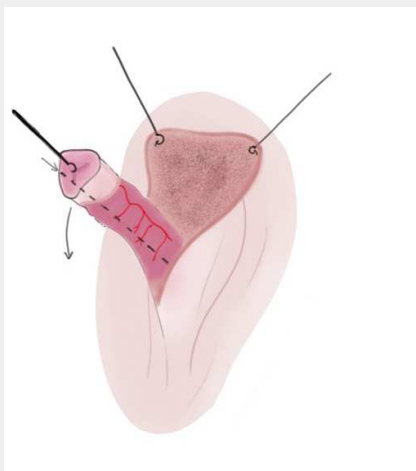


Figure 6 : Resection of the ventral part of the clitoral body

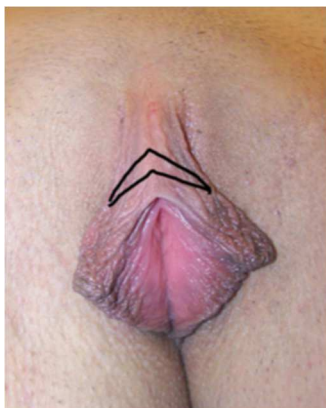

Figure 7 : Chevron plasty of the clitoral hood

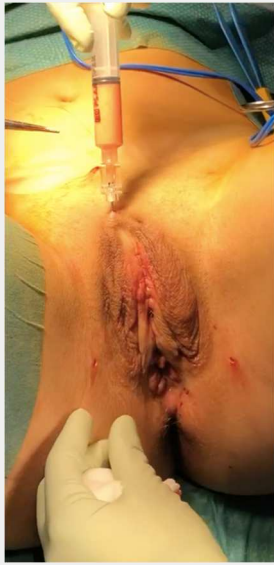

Figure 8 : Lipofilling of the labia majora

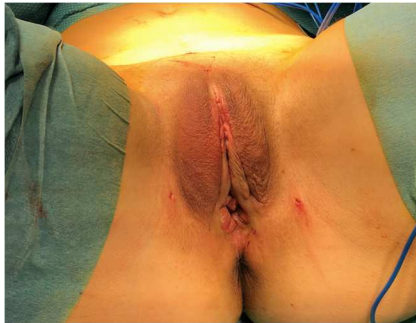

Figure 9 : immediate post operative result



Figure 10 : post operative result after 3 months