



**HAL**  
open science

## Imaging of appendicitis: Tips and tricks

Benjamin Monsonis, Caroline Mandoul, Ingrid Millet, Patrice Taourel

► **To cite this version:**

Benjamin Monsonis, Caroline Mandoul, Ingrid Millet, Patrice Taourel. Imaging of appendicitis: Tips and tricks. *European Journal of Radiology*, 2020, 130, pp.109165. 10.1016/j.ejrad.2020.109165 . hal-03491229

**HAL Id: hal-03491229**

**<https://hal.science/hal-03491229>**

Submitted on 18 Jul 2022

**HAL** is a multi-disciplinary open access archive for the deposit and dissemination of scientific research documents, whether they are published or not. The documents may come from teaching and research institutions in France or abroad, or from public or private research centers.

L'archive ouverte pluridisciplinaire **HAL**, est destinée au dépôt et à la diffusion de documents scientifiques de niveau recherche, publiés ou non, émanant des établissements d'enseignement et de recherche français ou étrangers, des laboratoires publics ou privés.



Distributed under a Creative Commons Attribution - NonCommercial 4.0 International License

Title page

# Imaging of appendicitis: tips and tricks

Benjamin Monsonis<sup>a</sup>, Caroline Mandoul<sup>a</sup>, Ingrid Millet<sup>a</sup>, Patrice Taourel<sup>a</sup>

<sup>a</sup> Radiology Department, CHU Lapeyronie, 371 avenue du doyen Gaston Giraud,  
34295 Montpellier, France

**Corresponding author:**

Patrice Taourel, MD, PhD,  
Radiology Department, CHU Lapeyronie, 371 avenue du doyen Gaston Giraud,  
34295 Montpellier, France.  
Tel.: +33 467 338 601; Fax: + 33 467 338 949;  
E-mail: p-taourel@chu-montpellier.fr.

# Imaging of appendicitis: tips and tricks

**Abstract:** Acute appendicitis is one of the most common surgical emergencies worldwide. Over the past 30 years, imaging has become central to the diagnosis of appendicitis, reducing both negative appendicectomy rate and healthcare expenses. Appendicitis can be challenging in many ways for radiologists with various clinical presentations, complications and differential diagnoses. The aim of this review is to present a step-by-step reasoning with key findings, tips and tricks leading to the diagnosis of appendicitis and its complications.

The first steps are with the use of the appropriate imaging modality (US, CT and MRI) to locate the appendix in abdominal cavity and to identify the features of appendicitis and its complications through specific imaging signs.

The next steps are to eliminate an unusual morphology of the appendix that may simulate acute appendicitis and to recognize an unusual imaging presentation of appendicitis.

Then, to corroborate the diagnosis of appendicitis, the last step is to rule out any differential diagnoses mainly from the genitourinary and gastrointestinal tracts.

Following these steps can help to accurately diagnose appendicitis and its complications.

## Key words

Appendicitis / Appendicitis imaging / Appendicitis complications / Appendicitis diagnosis

## Abbreviations

CT: computed tomography / MRI: Magnetic Resonance Imaging / US: ultrasound Imaging.

This research did not receive any specific grant from funding agencies in the public, commercial, or not-for-profit sectors.

Acute appendicitis is the most frequent cause of nontraumatic acute abdominal pain that requires emergency surgery. Diagnosing acute appendicitis is challenging when relying only on clinical and laboratory findings. Indeed, both rates of histologically normal appendix after appendicectomy and of complicated appendicitis were high before routine use of accurate diagnostic imaging techniques. Over the past 30 years, the use of ultrasound (US) and computed tomography (CT) have led to a more reliable preoperative diagnosis of appendicitis along with a better assessment of the related complications and detection of differential diagnosis. This led to reducing both negative appendicectomy rate and healthcare expenses. Indeed, normal appendicectomy rates ranged from 3.2% to 36.8% in high volume centres according to the place of imaging (US, CT or none) in the local diagnostic strategy [1]. Van Rossem et al, shown in 2016 that in the Netherlands, preoperative imaging was conducted in 99.5% of patients with suspected appendicitis resulting in a normal appendicectomy rate of 3.2% whereas in the UK, preoperative imaging was performed in only 32.8% of patients with a higher normal appendicectomy rate of 20.6% [2]. However, despite those major imaging-related improvements, appendicitis and its complications are still sometimes misdiagnosed. The aim of the review is to give key findings, tips and tricks for diagnosing appendicitis and its complications according to the following steps: 1/ spot the appendix, 2/ identify the features of appendicitis, 3/ recognize false positive diagnoses of appendicitis while knowing the potential false negatives, 4/ look for complications of appendicitis, 5/ rule out any disease that can clinically or radiologically mimic appendicitis.

### 1. Spot the appendix

The vermicular appendix is a wormlike, conic diverticulum of the cecum. It arises from the posteromedial wall of the cecum caudally to the ileocecal junction. Identification of the latter is paramount as it constitutes a major landmark in abdominal imaging, regardless of the imaging technique used (Figure 1) [3]. The normal appendix appears as a blind-ended, gut pattern, aperistaltic tubular structure. Its wall is thinner than 3 mm for a diameter around 6 mm. Its average length is 8-10 cm but with short forms ranging from 5 to 8 cm and long forms measuring up to 35 cm [3]. The volume of the appendicular lumen is approximately 1 ml with a daily mucus production of 3 to 4 ml [3].



The appendix is an intraperitoneal organ. Unlike the right colon, it is not fixed to the posterior parietal peritoneum by a meso and is thus free, only linked to the adjacent colon by the mesoappendix. Its location in relation to the cecum may therefore vary: mediocecal, laterocecal, retrocecal anterior to psoas-iliacus muscle, subcecal or prececal (Figure 2) [3]. Furthermore, depending on the variable location of the cecum itself and the variable length of the appendix, it may be located in various places within the abdomen: right lower quadrant, which constitutes the most common location, subhepatic, mesoceliac or even within a hernia. In rare cases of malrotation, the ileocecal complex is found in the left lower quadrant.

The variability of its location explains a more challenging identification of the appendix with US than with CT. According to a meta-analysis of 2018, normal appendixes were more often shown by CT than by US or MRI, with an overall detection rate of normal appendixes of 84%, 71% and 69% respectively [4].

However, following some precise rules can help identifying a normal appendix at US. A targeted sonography of the right iliac fossa using a high-resolution linear probe (7.5 – 14 MHz) [2] should be performed to locate the cecum and the last ileal loop. In case of non-visualization of the ileocecal complex in right iliac fossa, it is necessary to search for all kinds of malposition, the most common being malrotation, subhepatic cecum, situs inversus and mobile cecum. Once the ileocecal complex found, the next step is to search for a non-peristaltic blind digestive structure 2-3 cm below the ileocecal valve. In case of a pelvic location, a significant repletion of the bladder is helpful, as it often leads to elevating the appendix more superficially, thus more accessible to the probe. Usually, a pelvic appendix will be seen contiguous to the external iliac vessels. If feasible, transvaginal US can be useful in women, providing a closer look to pelvic structures. [2]. Mobilizing the patient is also often helpful, especially in case of gas inflation of the cecum and/or retrocecal position of the appendix. A 3-step patient positioning protocol (supine position / left posterior oblique position / 2nd look supine position) has been reported to increase the appendix detection rate from 30% in the initial supine to 44% in left posterior oblique position and to 53% with the 2nd look [5].

On CT, one should follow the colon, from the rectum to the right colon, to locate the ileocecal complex. Two to 3 cm below should lie the vermiform appendix. Usually, the linear

shape of the gas content of the appendix helps identifying it (Figures 3, 4, 5). Not visualizing the appendix with CT is rare, occurring in less than 10% of the cases, with a very short appendix and a small amount of intra-abdominal fat as limiting factors [6].

Sometimes, the appendix is not seen because of its absence, either due to a previous surgery including appendectomy that the patient is not aware of (ovarian surgery or early childhood surgery for example), or to a rare but possible condition that is agenesis of the appendix. Finally, the appendix can be hidden, either inside an intussusception of the ileocecal complex, especially in children, or in presence of an appendiceal neoplasm with mucinous dilatation.

The optimal CT protocol in case of a suspicion of acute appendicitis is still controversial. The main discussed issues include the use of intravenous contrast media, focused or non-focused CT and low-dose CT [7]. Regarding the latter, two main studies have demonstrated that low-dose CT (defined as dose divided by 2 in the first study and by 4 in the second) was equivalent to the standard one for the diagnosis of acute appendicitis (Figure 6) [8], [9]. Oral and/or rectal opacification is considered unnecessary by the majority of authors since it improves neither sensitivity nor specificity [10].

In our institution, US is the first-line examination for children, young patients, thin patients of all ages and pregnant women, on a systematic basis. CT is only performed as first line for the rest of the population. If appendicitis can be neither diagnosed nor ruled out at US, CT is the usual second line imaging technique to be performed, except for pregnant women that are exclusively imaged with Magnetic Resonance Imaging (MRI). Our CT protocol has been designed to be quick and reliable. We perform a direct acquisition at the portal phase after contrast-media injection, without any intraluminal contrast, exploring the whole volume of the abdomen. Unenhanced CT is performed only in case of contraindication for contrast media following the ESUR (European Society of Urogenital Radiology) guidelines, such as contrast agent allergy, renal insufficiency or myeloma [11]. For MRI, we proposed a simple and fast protocol including T1, T2 and T2 fat-suppression breathhold sequences (transverse and coronal planes) and diffusion in case of suspicion of complicated appendicitis.

## 2. Identify the features of appendicitis

US, CT and MRI are very reliable tools for the diagnosis of acute appendicitis. Graded-compression sonography shows a sensitivity of 86% and specificity of 81% according to a meta-analysis of 14 studies [12]. CT has a higher diagnostic performance, with a sensitivity and specificity of 91 % and 90 % respectively [2]. The MRI diagnostic values are also excellent with a sensitivity and specificity ranging from 85% to 100% and from 93% to 100% respectively, depending on the series [2].

Most of the main signs of appendicitis are common to all three imaging modalities.

### a/ Appendiceal inflammatory wall thickening

Measurement of the appendix wall should be performed on slices perpendicular to the major axis of the appendix, being careful not to include the intraluminal content. A thickening of the appendix wall should be described for a wall thicker than 3 mm, regardless of the technique used. In questionable cases, when the thickening is moderate, searching for an inflammatory pattern of the appendix wall often comes in handy:

- At US, Color flow Doppler may increase sensitivity [13] by showing hyperemia of the wall (figure 7). However, this is a poorly specific sign since recent technological improvements in color Doppler imaging have made it possible to visualize wall vascularization in a normal appendix. Otherwise, it must be noted that persistence of visualization of appendiceal wall layers indicates a non-necrotic early stage of acute appendicitis whereas loss of wall stratification implies gangrenous stage with necrotic lesions.
- At CT, presence of a hyper-enhancement of the appendix wall is a feature of inflammation and must be looked for by narrowing the window width (Figure 8).
- At MRI, the inflammatory wall of the appendix appears hypointense in T1 and hyperintense in T2. Diffusion-weighted sequences may also be of help, since a restricted diffusion in the appendiceal wall is a reliable indicator of acute inflammation (figure 9) [2].

Of note, an asymmetric reactional hyperemic thickening of the cecal wall close to the appendiceal base can be seen in case of appendicitis. It sometimes reduces the cecal lumen to an arrowhead shape that points to the appendix. This should not be confused with a primary colic inflammatory or tumoral disease (Figure 10).

#### b/ Dilatation of the appendix

Measurement of the appendix diameter must be performed on slices perpendicular to the major axis of the appendix:

- At US, the cut-off is a diameter  $> 6$  mm with grading compression technique [14]. The appendix is non-compressible and appears round when compression is applied (Figure 11).
- At CT or MRI, because of the lack of compression, the cut-off is  $\geq 10$  mm or between 6-10 mm with at least one other abnormal finding (wall thickening, wall hyperenhancement or fat stranding) (Figure 12) [14].

Evaluating the appendix content is useful for the diagnosis of appendicitis. A liquid appendix content is more often associated with appendicitis. On the contrary, a gaseous content is less likely to be associated with appendicitis. Presence of a stercolith is not always pathological. However, in an acute appendicitis setting, its presence is associated with complications because of the obstruction caused on the appendicular lumen. In such cases the surgeon should be informed, to make sure the infected stercolith is removed during surgery [15]. At CT, a narrow window provides a higher contrast to discriminate low density stercoliths from mucinous thick content of the appendix.

#### c/ Peri appendicular fat stranding

Identifying a peri appendicular fat stranding is trickier and more subjective on US or on MRI than on CT. Fat stranding appears hyperechoic on US, dense on CT and hyperintense on T2-weighted MRI sequence. A useful tip to identify subtle peri-appendicular fat stranding is to compare it with the fat located elsewhere in the abdominal cavity. Other findings of

inflammation of the right lower quadrant such as right peritoneal fascia thickening or mesoappendix thickening may be identified at CT or MRI but hardly at US.

#### d/ Mesenteric lymph nodes

Normal mesenteric lymph nodes measure usually less than 5 mm in short-axis [16]. During appendicitis, enlarged mesenteric lymph nodes of the right lower quadrant are frequently observed secondarily to the inflammatory process. In such cases, lymph nodes are moderately enlarged and surrounded by mesenteric inflammatory changes. However, lymphadenopathies are not always present in case of appendicitis.

Otherwise, lymphadenopathies greater than 1cm short-axis or presenting a necrotic center are uncommon. Their presence should lead to search for a malignant digestive or hematologic pathology [16].

3. Recognize false positive diagnoses of appendicitis and know the potential false negative.

Although US and CT are reliable techniques for diagnosing appendicitis, there still are false positives and false negatives. False negatives occur in mild appendicitis, localized partial appendicitis or conversely in some complicated appendicitis when the structure of the appendix is no longer recognizable. False positives occur when a neighbouring disease is responsible for the presence of one or more of the cardinal findings described in appendicitis.

#### a/ False negatives

- Tip appendicitis: acute appendicitis may begin with a luminal obstruction occurring at a distance from its orifice, so the inflammation may only be limited to the tip of the appendix with normal appearance of its base and body [17]. In case of a missed tip appendicitis, the infection can then spread to the whole appendix and get complicated. Even if the mean appendiceal length is around 9 cm, it is not unusual to see a long appendix, sometimes more than 20 cm [18]. Visualization of a normal portion of the

appendix is thus not sufficient to rule out the diagnosis of acute appendicitis. It is essential to explore the whole appendix, from base to tip, especially with US. Further evaluation with CT should be considered when the appendix is incompletely analysed at US in clinically suspicious patients. Sometimes, in early tip appendicitis, imaging features can be discordant with the normal macroscopic appearance of the appendix at surgery. However, one third of the apparently normal appendixes at surgery show inflammatory changes on pathologic examination, thus recommending to proceed with the appendectomy in such cases [19] (figure 13).

- Stump appendicitis: inflammation can occur on the remnant appendiceal tissue following an incomplete removal of the appendix. The risk of stump appendicitis is significant if the remnant appendix tissue is larger than 5mm. It usually occurs years to decades after the primary surgery. On a large series of 3130 appendectomies, only 5 (0.15%) stump appendicitis were diagnosed (18). Although stump appendicitis is very rare, it must be kept in mind that a previous appendectomy does not completely exclude the possibility of appendicitis [20].
- Abscess in the right lower quadrant: in some cases of very advanced appendicitis responsible for an abscess, the appendix itself is so altered that it is no longer possible to distinguish it. Although other digestive diseases such as a perforated cecal cancer, a perforated inflamed diverticulum or cecal ischemia may be responsible for the abscess, a complicated appendicitis should be the first diagnostic to be considered given its prevalence. The presence of a stercolith within the collection is quasi-pathognomonic, even if a dropped gallstone or a fecalith from a perforated diverticulum is also possible.

#### b/ False positives

Other causes of wall thickening or dilatation of the appendix can lead to false positives.

A thickening of the appendiceal wall may be consecutive to inflammatory reaction of the appendix in response to neighbour inflammation, or to involvement of the appendix by an inflammatory disease or a tumour.

- Reactive inflammation of the appendix: Abdominal or pelvic inflammatory or infectious disease can be responsible for a contiguous inflammation of the appendix. Thorough assessment of the whole bowel is paramount to rule out any other cause

of inflammation. For instance, a sigmoid diverticulitis may be responsible for a thickening of the appendiceal wall in patients with a sigmoid loop located in the right lower quadrant. Likewise, involvement of the right fallopian tube in a pelvic inflammatory disease may lead to a thickening of the appendiceal wall.

- Inflammatory bowel disease: Crohn disease may affect the appendix with chronic inflammatory changes appearing as a circumferential transmural wall thickening with a preserved mural stratification associated with inflamed non-compressible fat surrounding the ileum but without any peri appendiceal fat stranding [21]. As Crohn disease can involve any segment of the gastrointestinal tract, associated colon or ileum involvement is often present, with circumferential wall thickening, fat thickening, fistulas or abscess. A chronic inflammatory affection of the appendix should thus be diagnosed when facing chronic wall thickening of other parts of the digestive tract with an absence of fat stranding around the appendix [14].
- Appendiceal tumor: when the clinical presentation is not typical of an acute appendicitis, an isolated thickening of the appendiceal wall should lead to consider the diagnosis of appendiceal tumor. Other findings suggestive of an appendiceal tumor include a diameter > 15 mm, linear wall calcifications and the presence of a soft-tissue mass [22], [23] (figures 14, 15). The most common appendiceal tumors are epithelial neoplasms (adenoma, low and high-grade appendiceal mucinous neoplasms (LAMN / HAMN), mucinous adenocarcinoma, colonic-type adenocarcinoma and goblet cell carcinoma) and neuroendocrine tumors.
- Appendiceal endometriosis: In the general population, appendiceal endometriosis affects 0.4%-1% of women whereas its prevalence among patients with endometriosis is 4%-22%. It can account for various unspecific clinical presentations, chronic cyclic pelvic pain being the most typical. The diagnosis is challenging at imaging. On US, appendiceal endometriosis appears as a nodular hypoechoic thickening of the body or the tip of the appendix [24]. The diagnosis can also be suspected with MRI, with the appendix appearing spontaneously hyperintense in T1 and T1 fat-suppressed sequences, in keeping with a hemorrhagic signal [25]. On CT, it can be seen as an enhanced wall nodule without any specific features.

Dilatation of the appendix is not specific for appendicitis, even with a  $\geq 10$  mm cut-off. Other causes of appendix dilatation include:

- Appendiceal mucocele: Accumulation of mucus leading to a distended appendix. The cause can be non-tumoral, due to a chronic obstruction, or tumoral, with benign and malignant neoplasms [26] (figure 16). In particular, in some mucosecreting pathologies such as cystic fibrosis, the appendix can show chronic retention. Hence, knowledge of the patient's medical history is paramount.
- Retention due to obstruction of the appendiceal lumen by a tumor
- Appendiceal lumen dilatation due to mechanical large bowel obstruction (figure 17)

#### 4. Look for the complications of appendicitis

Pre-operative assessment of the possible complications of appendicitis is necessary as it impacts patient management. For example, medical treatment can be considered as a therapeutic option in some non-complicated cases. Severe complications can lead to electing laparotomy over laparoscopy as surgical approach. Percutaneous drainage of appendiceal abscesses can be necessary prior to surgery.

Main complications are as follows:

- Perforation: Paradoxically, at a more advanced stage appendiceal dilatation can cause thinning of the appendiceal wall associated with possibly transmural ulcers and focal or diffuse necrosis, leading to porosity. The presence of air outside the appendix is a classical finding of perforated appendicitis. A tip to identify perforation in the absence of extra-luminal air is to carefully look for an interruption of the wall, either using colour flow Doppler or on enhanced CT: focal loss of vascularization or enhancement suggests perforation. Presence of stercolith outside the appendix is pathognomonic of perforation. Thus, when a stercolith is seen, assessment of its position regarding the appendix lumen is necessary by searching for a peripheral wall surrounding it. (figure 18).
- Phlegmon and abscess: Without appropriate treatment, the inflammation extends around the appendix, especially in case of perforation, leading to unbounded and non-specific inflammation of soft tissue called phlegmon. If untreated, the phlegmon



is walled-off by peripheral granulation tissue and becomes an abscess. An appendiceal abscess shows a peripheral enhanced wall on CT or a peripheral hyperemic ring with colour Doppler on US (figure 19, 20, 21). A careful analysis of the outline of the infiltration in search of a wall is thus necessary since abscesses may need percutaneous drainage prior to surgery.

- Pylephlebitis: infectious thrombophlebitis of the mesenteric vein and/or the portal circulation, possibly leading to hepatic abscess. A close examination of the liver and portal and mesenteric circulations is paramount when facing abdominal infectious diseases.
- Small bowel obstruction. Four main causes exist in a context of appendicitis:
  - o Inflammation can be irritative to small bowel and lead to nonmechanical obstruction secondary to inhibition of peristalsis with agglutination of the small bowel loops. It is the most common mechanism of obstruction in appendicitis.
  - o Ileitis secondarily to inflammation can be responsible of a mechanical obstruction.
  - o The constitution of a peri appendiceal inflammatory mass can lead to the entrapment of the distal ileum and result in a mechanical obstruction.
  - o Fibrous adhesions can be a cause of small bowel obstruction, more often several years after the appendicitis [14].

## 5. Differential diagnoses

Various pathologies of the gastrointestinal and genitourinary tracts can induce an acute right sided pain similar to acute appendicitis. The main differential diagnoses can often be suspected clinically such as urinary infections, with the help of bacterial urine exam. In addition, most of them are easily recognizable at imaging, particularly with CT, such as renal colic. However, some pathologies are trickier to diagnose even with the appropriate imaging examination, mimicking appendicitis on both clinical presentation and imaging features. The main confusing pathologies with appendicitis are presented in the table 1.

**Conclusion**

Nowadays, diagnosing appendicitis is entirely the role of the radiologist in daily practice. Although it may seem trivial at first sight, several pitfalls must be avoided in order to allow adequate management and improve patient's outcome. Thoroughly following the several aforementioned steps is helpful to accurately diagnose appendicitis and its complications, from the simplest to the most challenging case.

	<b>Population</b>	<b>Frequency</b>	<b>Cause</b>	<b>Imaging features</b>	<b>Tips and tricks</b>	<b>Pitfalls</b>
--	-------------------	------------------	--------------	-------------------------	------------------------	-----------------

<b>Mesenteric adenitis [14]</b>	Young adult / Children	Most common differential diagnosis	Virus or bacteria (Yersinia / Salmonella) with contaminated food	Enlarged lymphatic nodes	Inflammatory nodes without signs of appendicitis or digestive wall thickening	
<b>Epiploic appendagitis [27]</b>	All ages	Rare, 0,3-1% of suspected appendicitis	Torsion and inflammation of an epiploic appendage	Fat attenuated mass usually contiguous to the colon with attenuation rim	Fat attenuated mass: pathognomonic	Hardly recognizable in US being fat inside fat
<b>Infectious terminal ileitis [21]</b>	Young adults / Children	Frequent	Virus, bacteria (Yersinia / Salmonella...) or parasite with contaminated food	Wall thickening of the ileum > 5 mm with node enlargement and perdigestive fat stranding	Visualization of peristalsis of the last ileal loop to differentiate from the aperistaltic appendix	Confusion between last ileal loop and appendix
<b>Cecal diverticulitis [28]</b>	Adult asian population is more concerned (only 5% on European and North American populations)	Rare	Infection of a predisposal diverticulum (congenital and solitary)	Pericecal inflammatory changes centered on a diverticulum with cecal thickening and fat stranding	Fat stranding centered on the right colon	Confusion between a cecal diverticulum and the appendix. The appendix is longer.
<b>Acute pelvic inflammatory diseases [29]</b>	Premenopausal women	Frequent (4% of women in the US)	Sexually transmitted disease (Neisseria gonorrhoeae and Chlamydia tracomatis)	Fat stranding in the pelvic area with tubal dilatation and possible abscess	Appendix < 7 mm and left tubal diameter > 10 mm: PID	Confusion between fallopian tube and appendix / appendix inflammation due to pelvic infection
<b>Meckel's diverticulitis [30]</b>	2% of population with Meckel's diverticula	Rare	Infection of a predisposal Meckel's diverticula (main complication)	Blind appendix-like structure with inflammatory changes	Normal appendix associated with a 2nd tubular blind structure	Confusion between Meckel's diverticula and appendix
<b>Cecal cancer</b>	Elderly population	Rare	Adenocarcinoma	Irregular enhanced thickening of the cecum	Nodular malignant involvement of the peritoneum or lymphadenopathies	Appendicitis due to obstruction by a cecal tumor

Table 1: Confusing differential diagnoses of appendicitis.

## Bibliography

- [1] C. C. van Rossem *et al.*, « Diagnosing acute appendicitis: surgery or imaging? », *Colorectal Dis.*, vol. 18, n° 12, p. 1129-1132, déc. 2016, doi: 10.1111/codi.13470.
- [2] M. Karul, C. Berliner, S. Keller, T. Tsui, et J. Yamamura, « Imaging of Appendicitis in Adults », *RöFo - Fortschritte Auf Dem Geb. Röntgenstrahlen Bildgeb. Verfahr.*, vol. 186, n° 06, p. 551-558, avr. 2014, doi: 10.1055/s-0034-1366074.
- [3] V. Schumpelick, B. Dreuw, K. Ophoff, et A. Prescher, « APPENDIX AND CECUM », *Surg. Clin. North Am.*, vol. 80, n° 1, p. 295-318, févr. 2000, doi: 10.1016/S0039-6109(05)70407-2.
- [4] D. W. Kim *et al.*, « Visibility of Normal Appendix on CT, MRI, and Sonography: A Systematic Review and Meta-Analysis », *Am. J. Roentgenol.*, vol. 211, n° 3, p. W140-W150, sept. 2018, doi: 10.2214/AJR.17.19321.
- [5] S. T. Chang, R. B. Jeffrey, et E. W. Olcott, « Three-Step Sequential Positioning Algorithm During Sonographic Evaluation for Appendicitis Increases Appendiceal Visualization Rate and Reduces CT Use », *Am. J. Roentgenol.*, vol. 203, n° 5, p. 1006-1012, nov. 2014, doi: 10.2214/AJR.13.12334.
- [6] Y.-T. Jan, F.-S. Yang, et J.-K. Huang, « Visualization Rate and Pattern of Normal Appendix on Multidetector Computed Tomography by Using Multiplanar Reformation Display », *J. Comput. Assist. Tomogr.*, vol. 29, n° 4, p. 446-451, juill. 2005, doi: 10.1097/01.rct.0000164668.03767.53.
- [7] P. Taourel, S. Méringaud « Acute appendicitis », Book: *CT of the acute abdomen*, p. 143-181, 2011, Springer.
- [8] H. Seo *et al.*, « Diagnosis of Acute Appendicitis With Sliding Slab Ray-Sum Interpretation of Low-Dose Unenhanced CT and Standard-Dose IV Contrast-Enhanced CT Scans », *Am. J. Roentgenol.*, vol. 193, n° 1, p. 96-105, juill. 2009, doi: 10.2214/AJR.08.1237.
- [9] K. Kyuseok *et al.*, « Low-Dose Abdominal CT for Evaluating Suspected Appendicitis », *N Engl J Med*, p. 10, 2012.
- [10] K. Hekimoglu, U. M. Yildirim, E. Karabulut, et M. Coskun, « Comparison of combined oral and iv contrast-enhanced versus single iv contrast-enhanced mdct for the detection of acute appendicitis », *J. Belg. Soc. Radiol.*, vol. 94, n° 5, p. 278, mai 2011, doi: 10.5334/jbr-btr.664.
- [11] on behalf of the Contrast Media Safety Committee of European Society of Urogenital Radiology (ESUR) *et al.*, « Contrast induced nephropathy: updated ESUR Contrast Media Safety Committee guidelines », *Eur. Radiol.*, vol. 21, n° 12, p. 2527-2541, déc. 2011, doi: 10.1007/s00330-011-2225-0.
- [12] A. Bhangu, K. Søreide, S. Di Saverio, J. H. Assarsson, et F. T. Drake, « Acute appendicitis: modern understanding of pathogenesis, diagnosis, and management », *The Lancet*, vol. 386, n° 10000, p. 1278-1287, sept. 2015, doi: 10.1016/S0140-6736(15)00275-5.
- [13] D. Gaitini *et al.*, « Diagnosing Acute Appendicitis in Adults: Accuracy of Color Doppler Sonography and MDCT Compared with Surgery and Clinical Follow-Up », *Am. J. Roentgenol.*, vol. 190, n° 5, p. 1300-1306, mai 2008, doi: 10.2214/AJR.07.2955.
- [14] N. Pinto Leite, J. M. Pereira, R. Cunha, P. Pinto, et C. Sirlin, « CT Evaluation of Appendicitis and Its Complications: Imaging Techniques and Key Diagnostic Findings », *Am. J. Roentgenol.*, vol. 185, n° 2, p. 406-417, août 2005, doi: 10.2214/ajr.185.2.01850406.
- [15] M. S. Khan, M. T. H. Siddiqui, N. Shahzad, A. Haider, M. B. H. Chaudhry, et R. Alvi, « Factors Associated with Complicated Appendicitis: View from a Low-middle Income Country », *Cureus*, mai 2019, doi: 10.7759/cureus.4765.
- [16] B. C. Lucey, J. W. Stuhlfaut, et J. A. Soto, « Mesenteric Lymph Nodes Seen at Imaging: Causes and Significance », *RadioGraphics*, vol. 25, n° 2, p. 351-365, mars 2005, doi: 10.1148/rg.252045108.
- [17] H. Mazeh, I. Epelboym, J. Reinherz, A. J. Greenstein, et C. M. Divino, « Tip appendicitis: clinical implications and management », *Am. J. Surg.*, vol. 197, n° 2, p. 211-215, févr. 2009, doi: 10.1016/j.amjsurg.2008.04.016.

- [18] H. Laraqui, M. Lamgari, M. Essarghini, et A. Zentar, « An unusual presentation of appendicitis: a 23 cm long appendix in Morocco », p. 4.
- [19] A. W. Phillips, A. E. Jones, et K. Sargen, « Should the Macroscopically Normal Appendix be Removed During Laparoscopy for Acute Right Iliac Fossa Pain When No Other Explanatory Pathology is Found? »: *Surg. Laparosc. Endosc. Percutan. Tech.*, vol. 19, n° 5, p. 392-394, oct. 2009, doi: 10.1097/SLE.0b013e3181b71957.
- [20] E. Dikicier *et al.*, « Stump appendicitis: a retrospective review of 3130 consecutive appendectomy cases », *World J. Emerg. Surg.*, vol. 13, n° 1, p. 22, déc. 2018, doi: 10.1186/s13017-018-0182-5.
- [21] S. DiLauro et N. F. Crum-Cianflone, « Ileitis: When It is Not Crohn's Disease », *Curr. Gastroenterol. Rep.*, vol. 12, n° 4, p. 249-258, août 2010, doi: 10.1007/s11894-010-0112-5.
- [22] P. J. Pickhardt, A. D. Levy, C. A. Rohrmann, et A. I. Kende, « Primary Neoplasms of the Appendix Manifesting as Acute Appendicitis: CT Findings with Pathologic Comparison », *Radiology*, vol. 224, n° 3, p. 775-781, sept. 2002, doi: 10.1148/radiol.2243011545.
- [23] P. J. Pickhardt, A. D. Levy, C. A. Rohrmann, et A. I. Kende, « Primary Neoplasms of the Appendix: Radiologic Spectrum of Disease with Pathologic Correlation », *RadioGraphics*, vol. 23, n° 3, p. 645-662, mai 2003, doi: 10.1148/rg.233025134.
- [24] L. P. Chamié, D. M. F. R. Ribeiro, D. A. Tiferes, A. C. de Macedo Neto, et P. C. Serafini, « Atypical Sites of Deeply Infiltrative Endometriosis: Clinical Characteristics and Imaging Findings », *RadioGraphics*, vol. 38, n° 1, p. 309-328, janv. 2018, doi: 10.1148/rg.2018170093.
- [25] J. K. Moulder, M. T. Siedhoff, K. L. Melvin, E. G. Jarvis, K. A. Hobbs, et J. Garrett, « Risk of appendiceal endometriosis among women with deep-infiltrating endometriosis », *Int. J. Gynecol. Obstet.*, vol. 139, n° 2, p. 149-154, nov. 2017, doi: 10.1002/ijgo.12286.
- [26] L. M. Leonards, A. Pahwa, M. K. Patel, J. Petersen, M. J. Nguyen, et C. M. Jude, « Neoplasms of the Appendix: Pictorial Review with Clinical and Pathologic Correlation », *RadioGraphics*, vol. 37, n° 4, p. 1059-1083, juill. 2017, doi: 10.1148/rg.2017160150.
- [27] A. C. van B. Vriesman et J. B. C. M. Puylaert, « Epiploic appendagitis and omental infarction: pitfalls and look-alikes », *Abdom. Imaging*, vol. 27, n° 1, p. 20-28, janv. 2002, doi: 10.1007/s00261-001-0056-1.
- [28] T.-C. Chiu *et al.*, « Right-Sided Colonic Diverticulitis: Clinical Features, Sonographic Appearances, and Management », *J. Med. Ultrasound*, vol. 25, n° 1, p. 33-39, mars 2017, doi: 10.1016/j.jmu.2016.10.007.
- [29] K. El Hentour, I. Millet, E. Pages-Bouic, F. Curros-Doyon, N. Molinari, et P. Taourel, « How to differentiate acute pelvic inflammatory disease from acute appendicitis ? A decision tree based on CT findings », *Eur. Radiol.*, vol. 28, n° 2, p. 673-682, févr. 2018, doi: 10.1007/s00330-017-5032-4.
- [30] J. Lequet, B. Menahem, A. Alves, A. Fohlen, et A. Mulliri, « Meckel's diverticulum in the adult », *J. Visc. Surg.*, vol. 154, n° 4, p. 253-259, sept. 2017, doi: 10.1016/j.jviscsurg.2017.06.006.

Illustrations

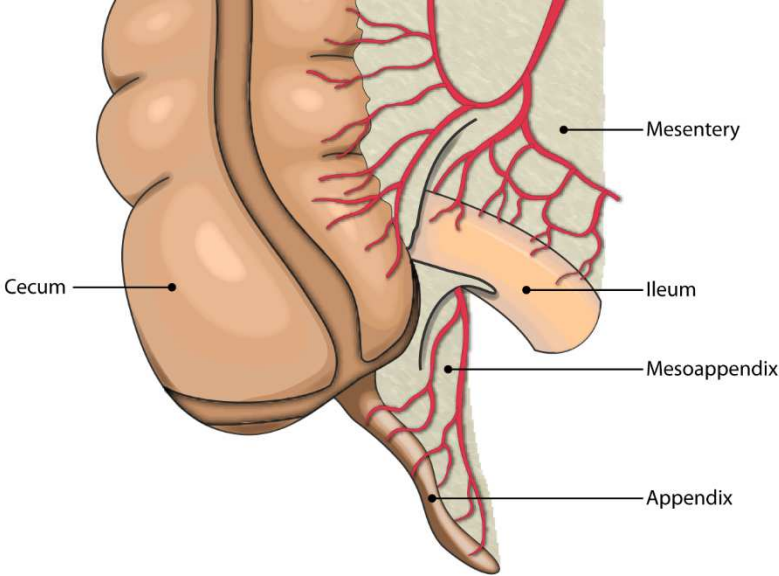


Figure 1: Anterior schematic view of the ileocecal complex

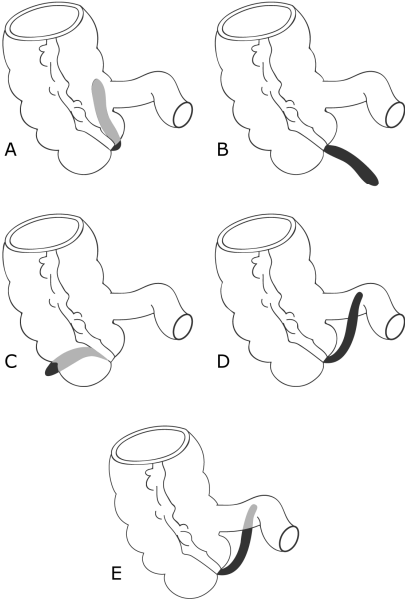
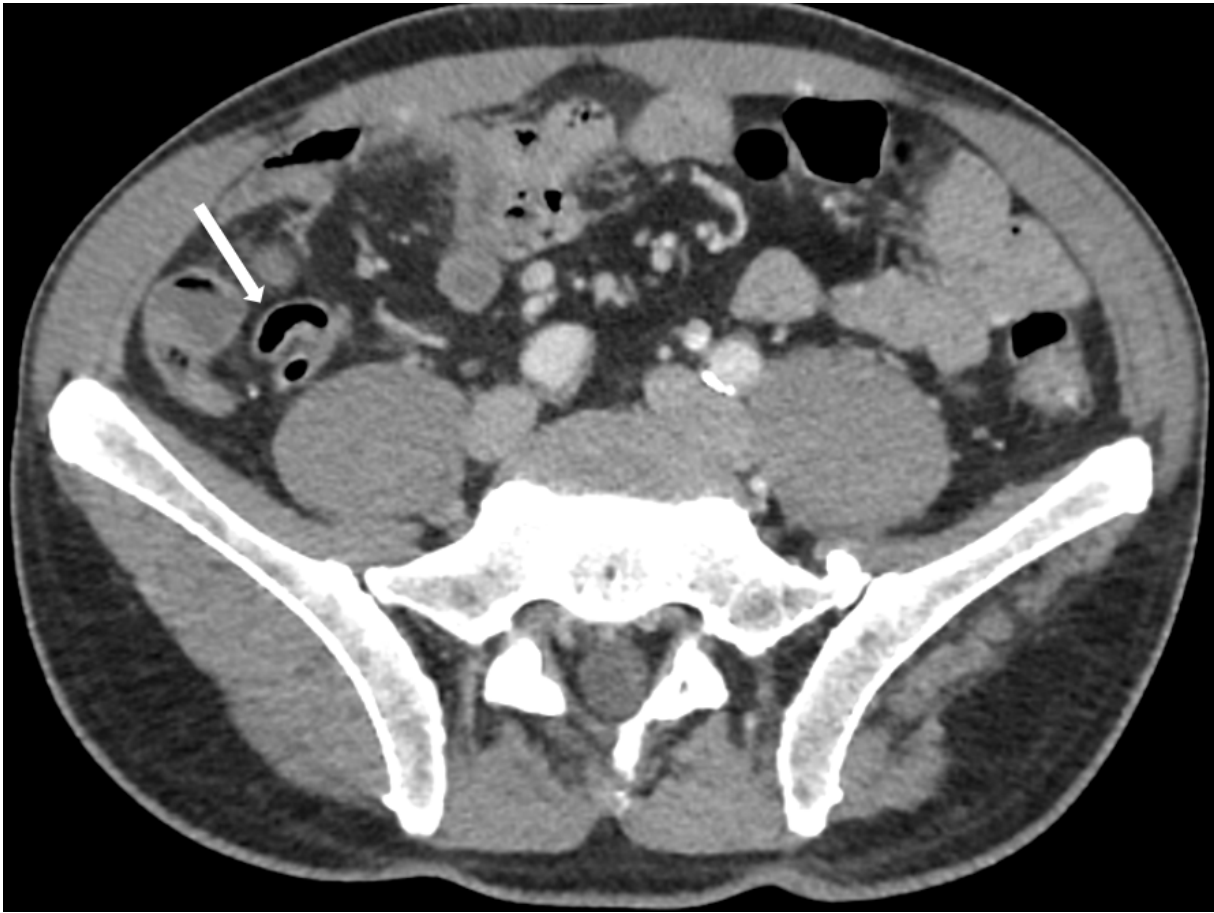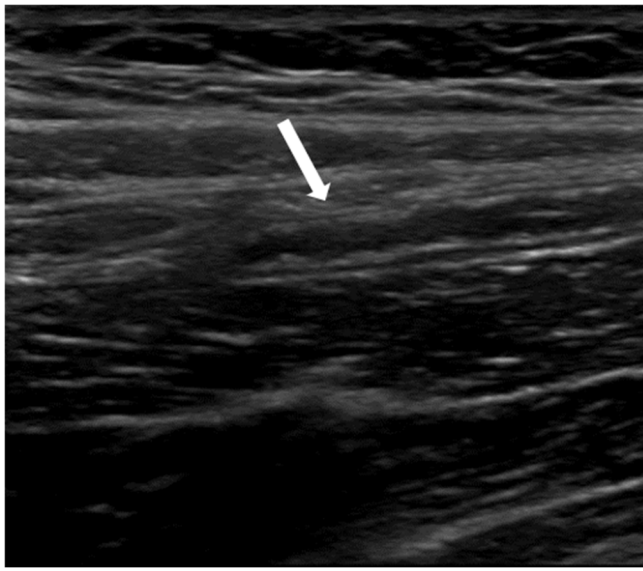
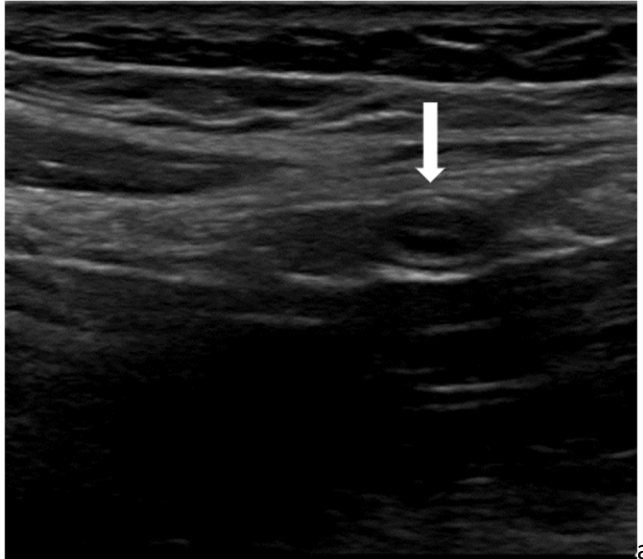


Figure 2: Schematic positions of the appendix and their prevalence: A: Retrocecal ascending (65%). B: Pelvic (31%). C: Retrocecal transverse (2.5%). D: Paracecal ascending preileal (1%). E: Paracecal ascending postileal (0.5%).

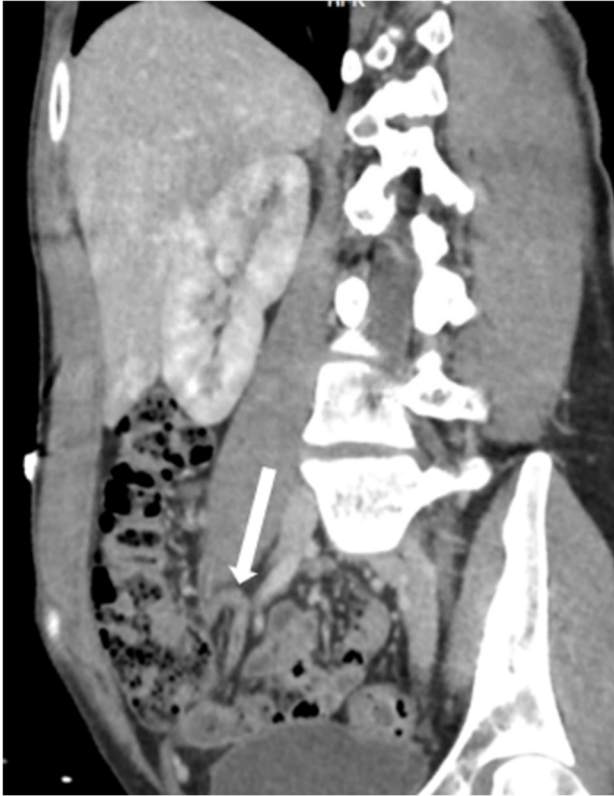


**Figure 3:** Axial enhanced portal phase CT showing a normal appendix with tubular shape of its gaseous content (arrow)

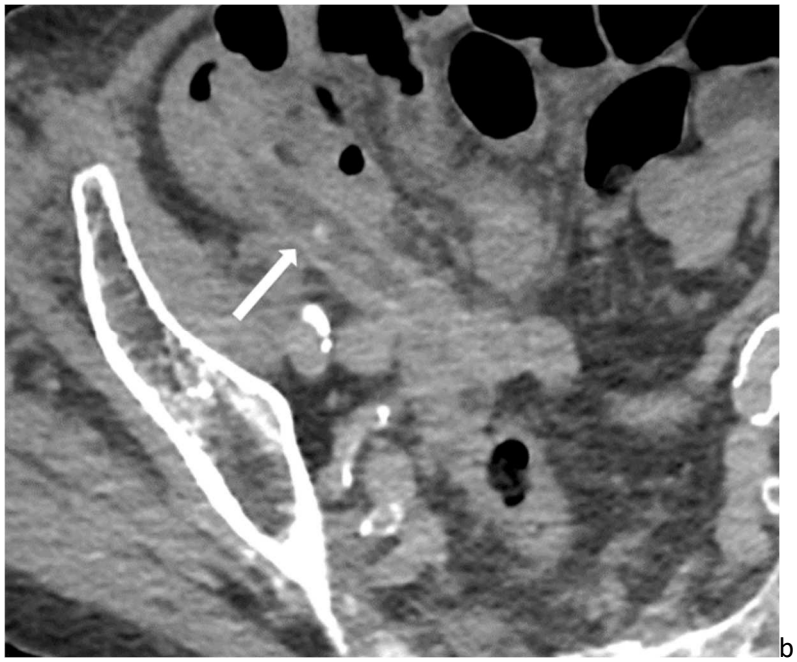
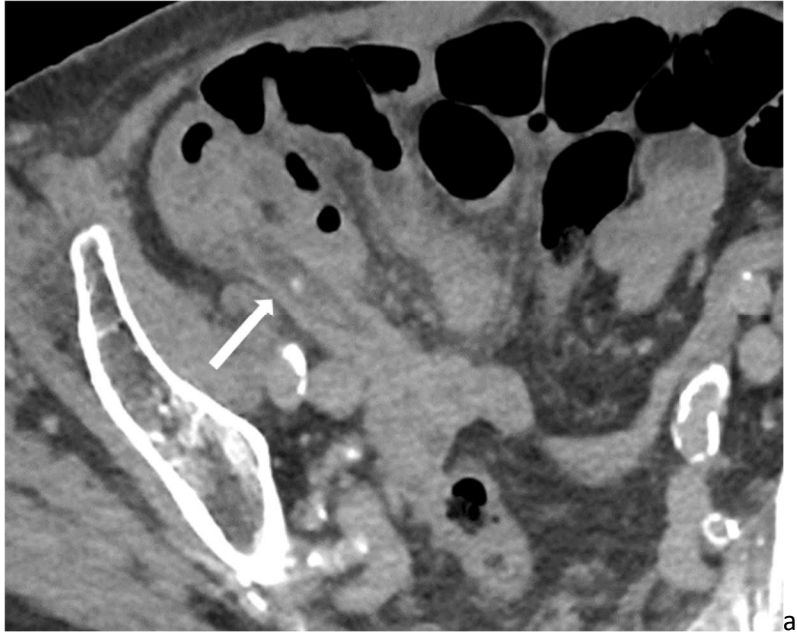


**Figure 4:** Ultrasound of a normal appendix (arrows) in transversal (a) and longitudinal plane (b).

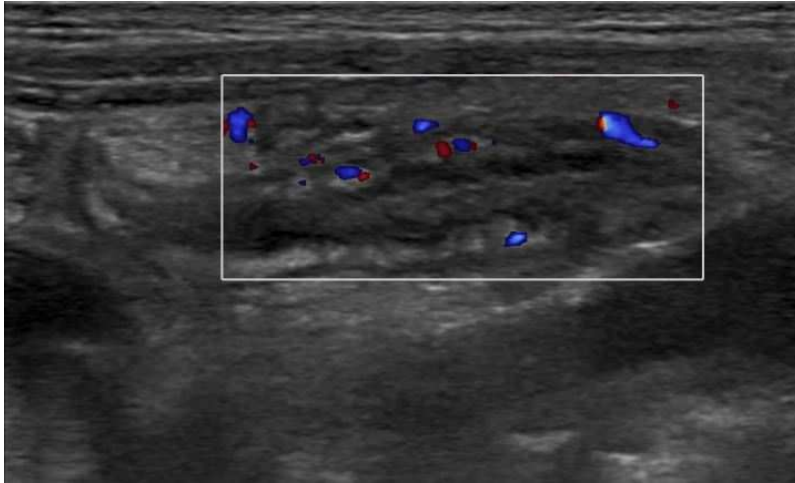




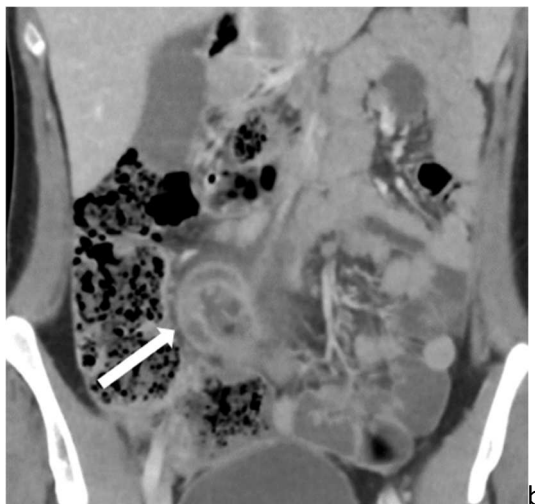
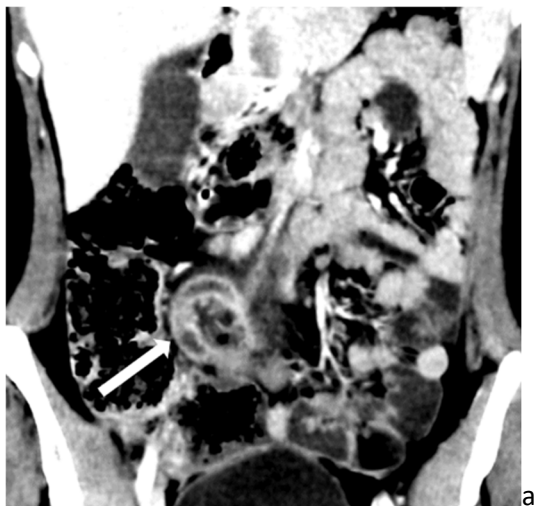**Figure 5:** Enhanced portal phase CT showing a normal appendix (arrow) in sagittal reconstruction.



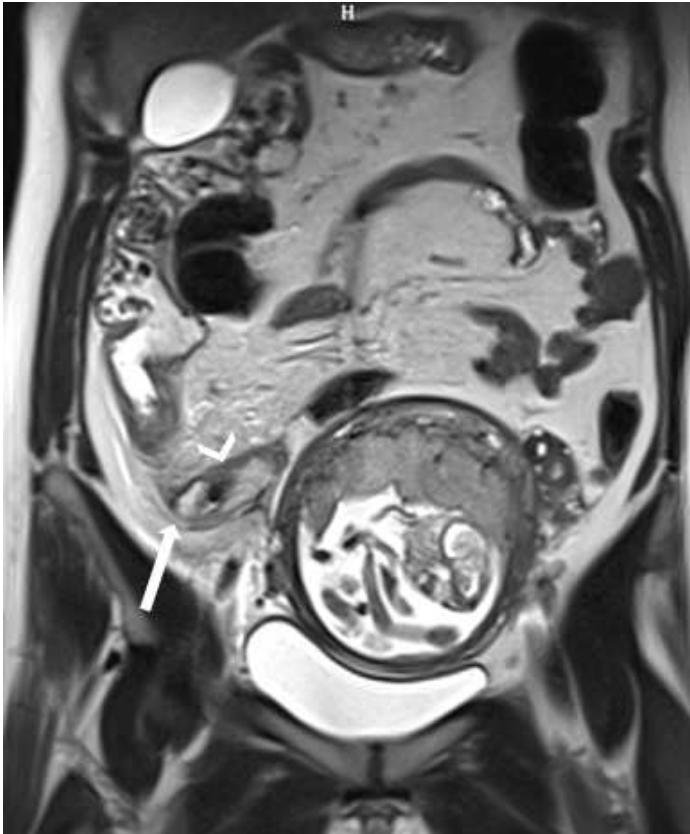
**Figure 6:** Acute appendicitis (arrow) with regular CT dose (a) and low dose (b) (half of the regular dose).



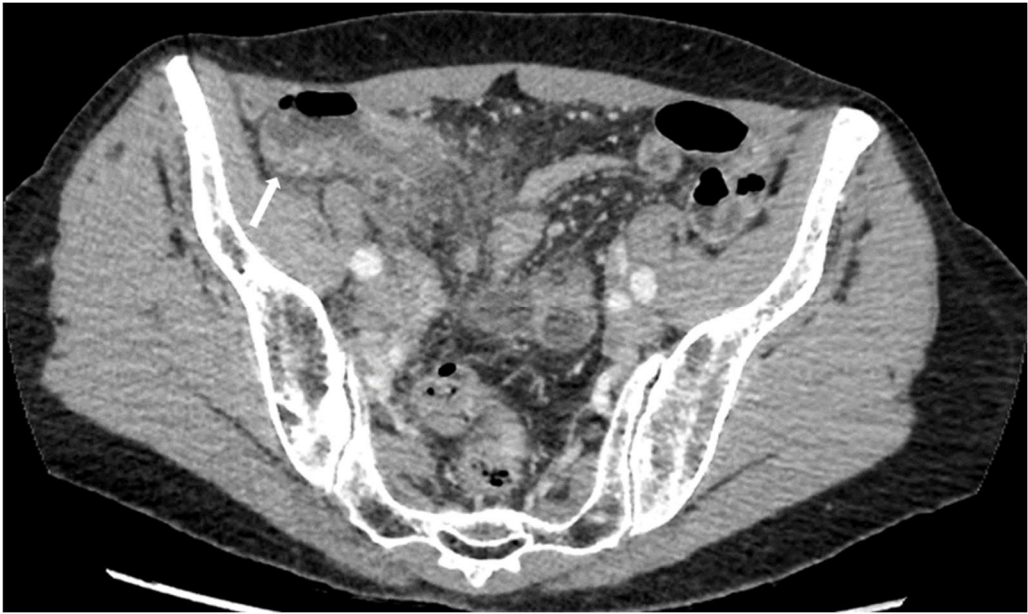**Figure 7:** Appendicitis with mural hyperemia on color doppler imaging.



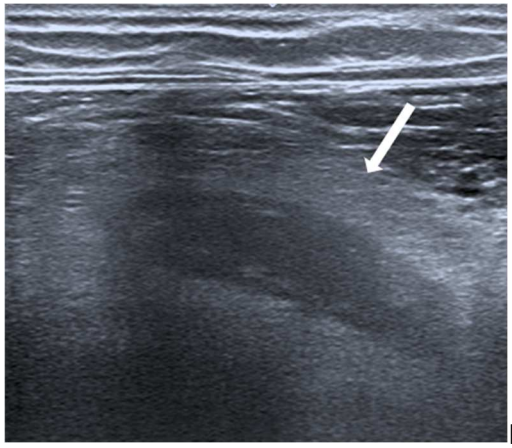
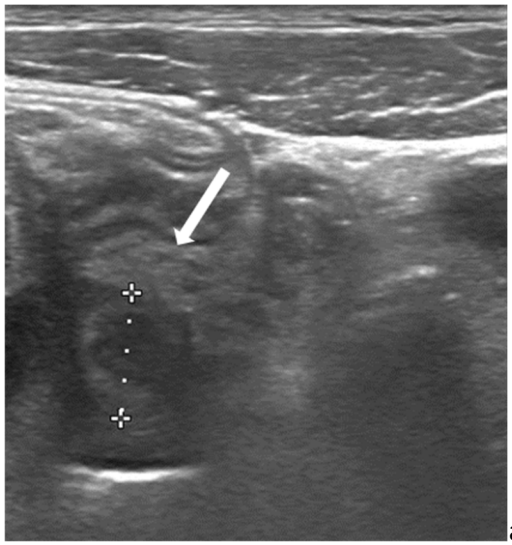
**Figure 8:** Enhanced portal phase CT on coronal reconstruction showing acute appendicitis (arrows) with narrowed window width (100/50)(a) versus usual window width for abdominal exploration (400/40)(b). Hyper-enhancement of the appendiceal wall is more obvious using a narrow width.



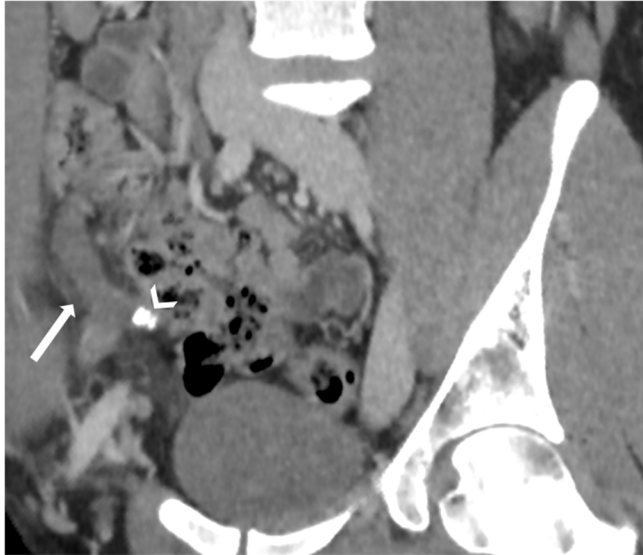
**Figure 9:** MRI of a pregnant woman with appendicitis (arrow) and marked fat stranding (arrowhead).



**Figure 10:** Axial enhanced CT showing thickening of the colic wall (arrow) in reaction to appendicitis.

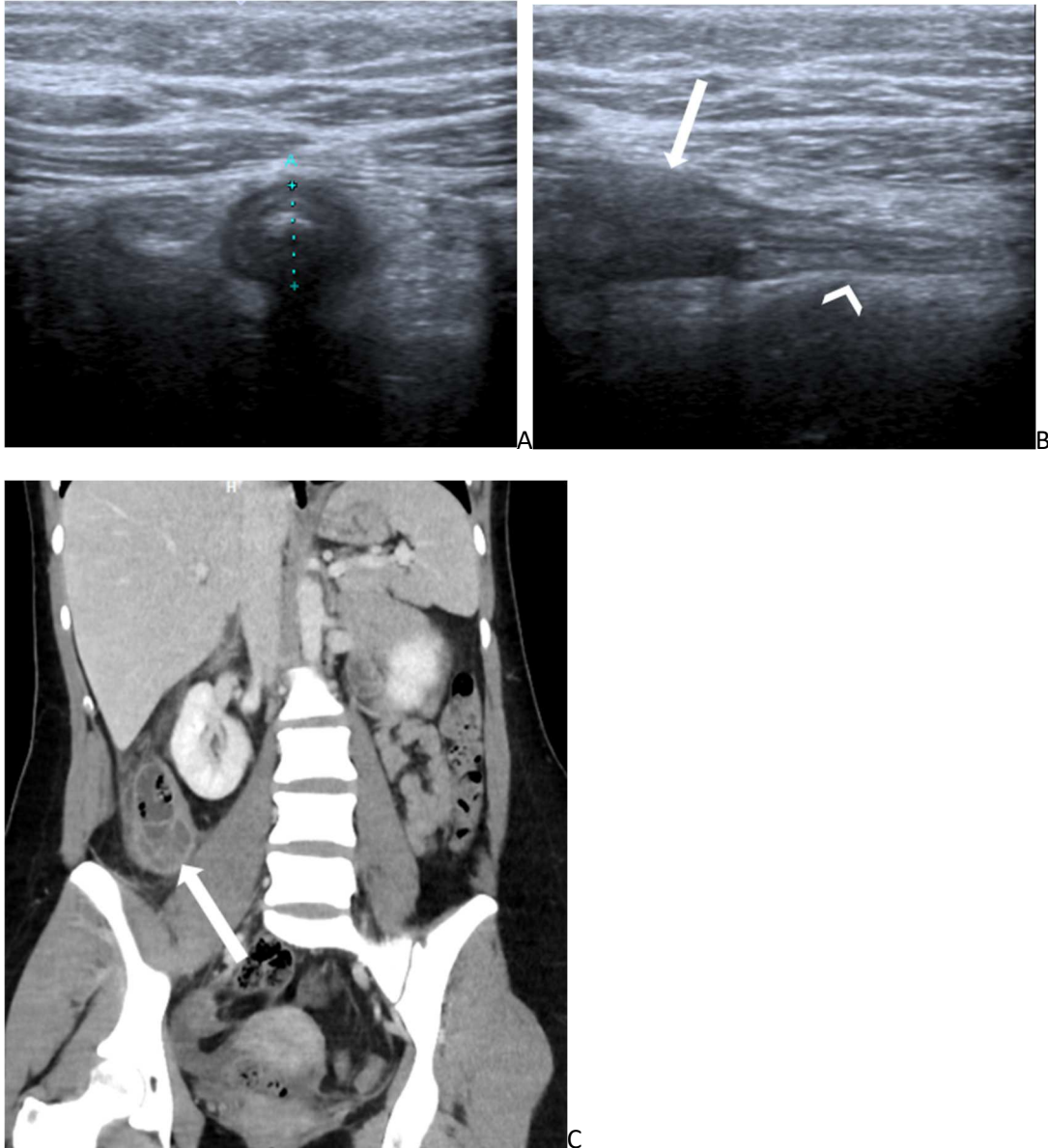


**Figure 11:** Acute appendicitis at ultrasound in axial (a) and longitudinal plane (b), with a diameter of 12 mm (clippers) and fat stranding (arrow).

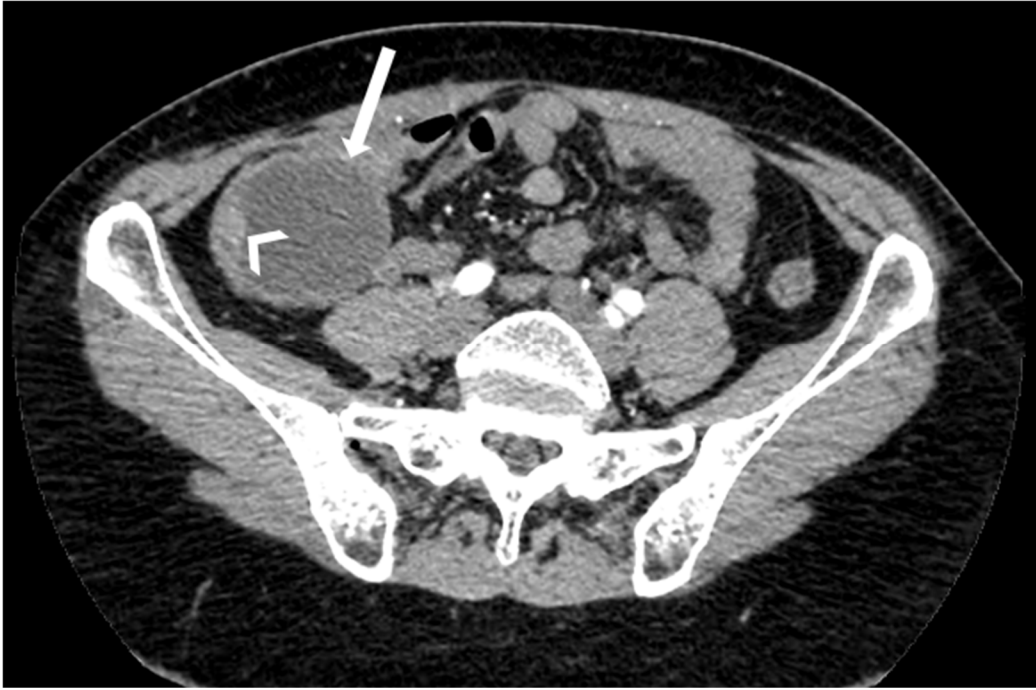

**Figure 12:** Coronal reconstruction of an enhanced portal phase CT showing acute appendicitis: enlarged appendix (12 mm) and fat stranding (arrow). A stercolith can be seen at the base of the appendix (arrowhead).



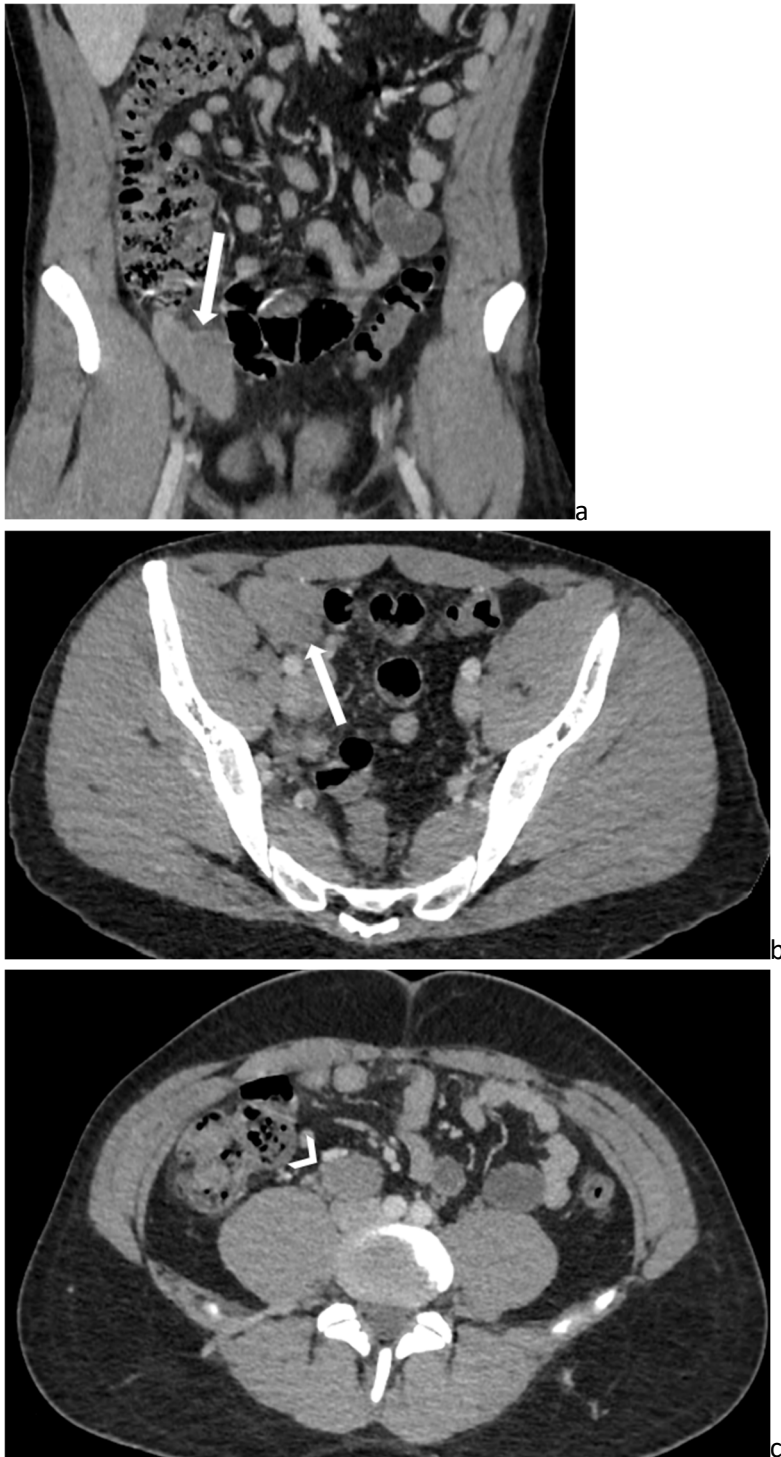

**Figure 13:** Young women of 19 y/o with acute right lower quadrant pain. A-B: US showed a tip appendicitis with dilatation of the tip (arrow on A and B) and fat stranding surrounding the tip without abnormalities of the rest of the appendix (arrowhead) (a: US axial, b: US longitudinal). Based on the US results, emergency surgery was performed the following hours. The surgeon concluded to a normal appendix and decided not to proceed with the appendectomy. One week later, the patient came back to the Emergency Room with worsened symptoms: the enhanced CT (c: coronal reconstruction of the enhanced CT) performed in emergency showed a perforated appendix with periappendicular abscess (arrow on C).

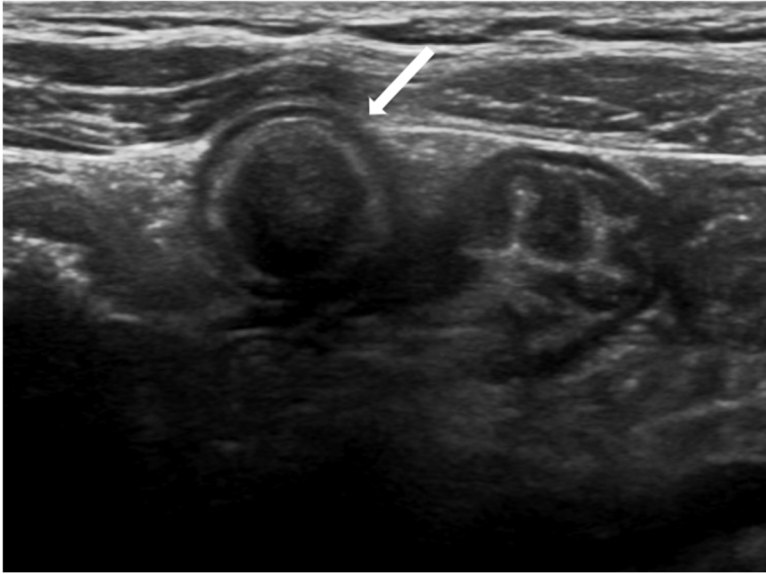


**Figure 14:** Axial enhanced CT showing appendiceal mucocele (arrow) with adenoma (not visible) and carcinoid tumor (arrowhead).

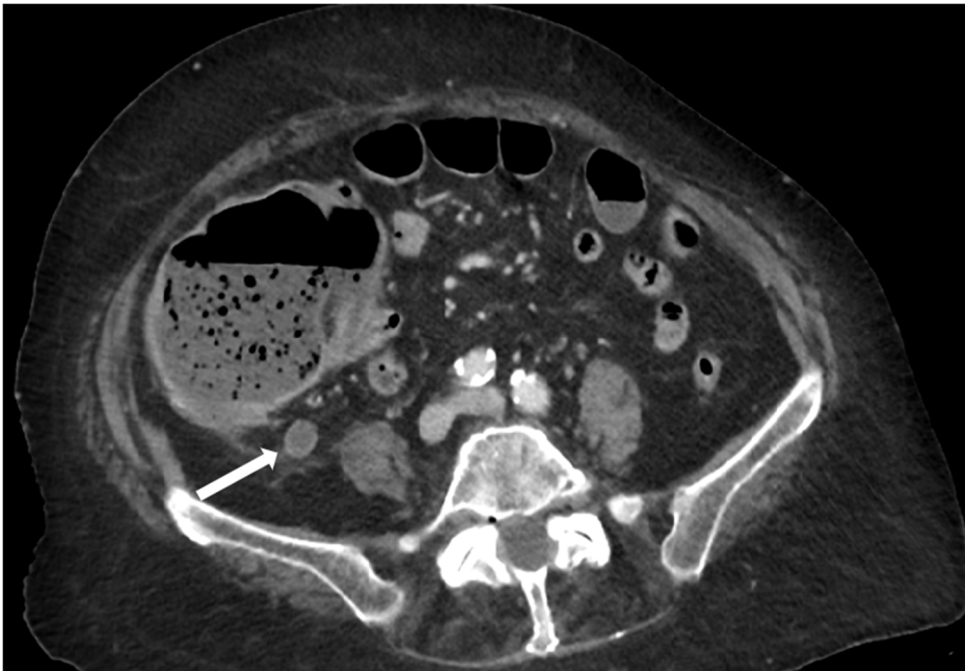




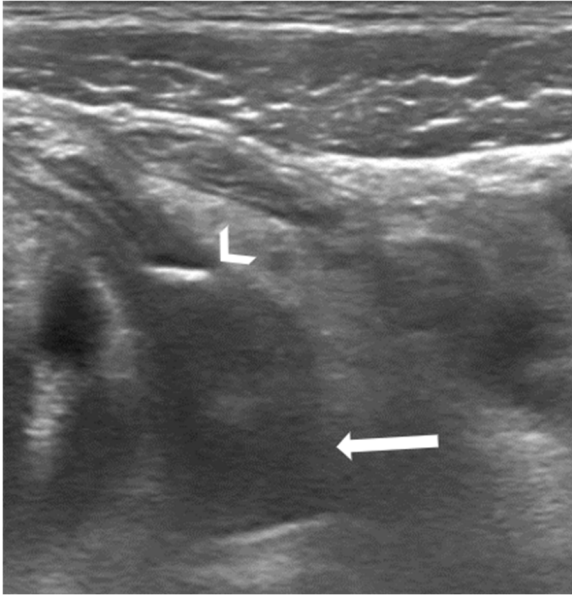
**Figure 15:** Enhanced CT in coronal reconstruction (a) and axial plane (b and c) of a 20 years-old patient with a soft-tissue mass of the appendix (arrow) with pathologic retroperitoneal node (arrowhead) (c): appendiceal type B lymphoma.



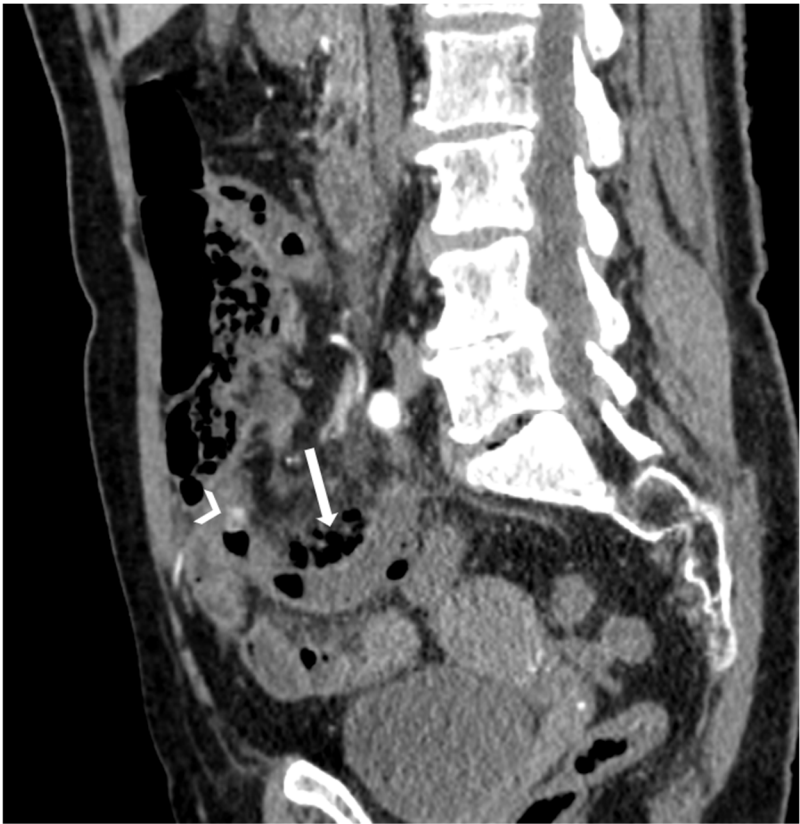**Figure 16:** Ultrasound showing an appendiceal mucocele (arrow) filled with mucus of a patient suffering from cystic fibrosis.



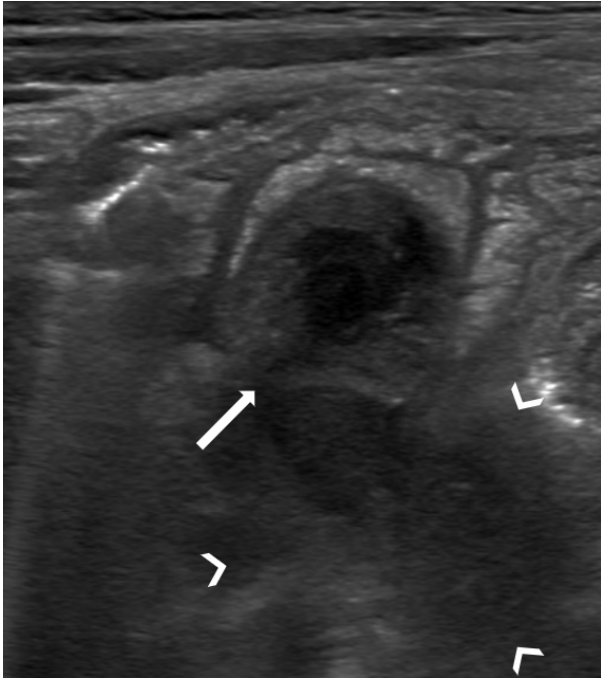**Figure 17:** Axial enhanced CT showing appendix dilatation without appendicitis due to large bowel obstruction (arrow: appendix 11 mm).



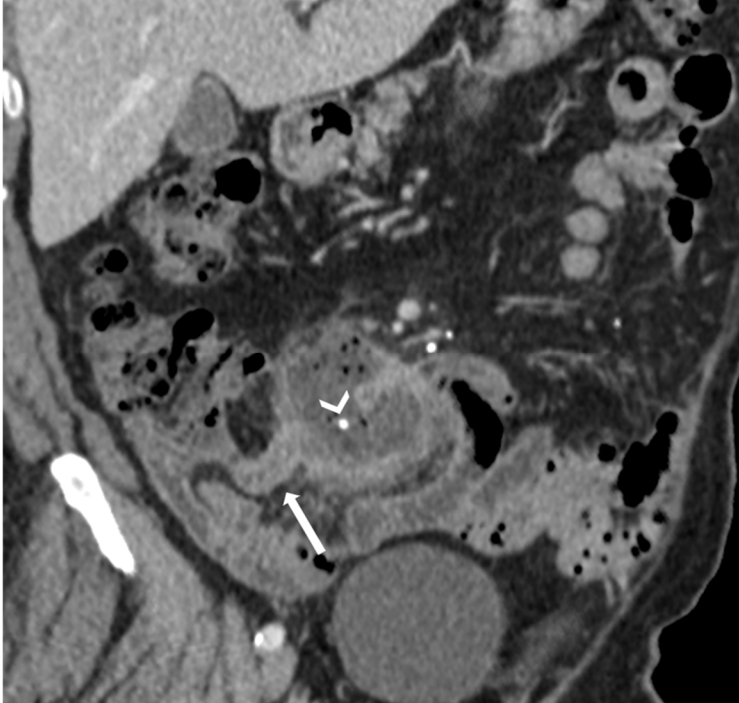
**Figure 18:** Ultrasound showing acute appendicitis with phlegmon (arrow) and appendicolith (arrowhead).



**Figure 19:** Sagittal reconstruction of an enhanced CT showing perforated acute appendicitis with extra-digestive gas (arrow) and stercolith at the base (arrowhead).



**Figure 20:** Ultrasound showing acute appendicitis with perforation (arrow: interruption of the wall) and abscess in formation (arrowheads).



**Figure 21:** Coronal reconstruction of an enhanced CT showing acute appendicitis (arrow) complicated with an abscess containing a stercolith (arrowhead).