



HAL
open science

A rare parotid tumor

C.A. Righini, C. Colombe, H. Gil

► **To cite this version:**

C.A. Righini, C. Colombe, H. Gil. A rare parotid tumor. *European Annals of Otorhinolaryngology, Head and Neck Diseases*, 2020, 137, pp.233 - 234. <10.1016/j.anorl.2020.01.004>. <hal-03491039>

HAL Id: hal-03491039

<https://hal.science/hal-03491039v1>

Submitted on 22 Aug 2022

HAL is a multi-disciplinary open access archive for the deposit and dissemination of scientific research documents, whether they are published or not. The documents may come from teaching and research institutions in France or abroad, or from public or private research centers.

L'archive ouverte pluridisciplinaire **HAL**, est destinée au dépôt et à la diffusion de documents scientifiques de niveau recherche, publiés ou non, émanant des établissements d'enseignement et de recherche français ou étrangers, des laboratoires publics ou privés.



Distributed under a Creative Commons CC BY-NC 4.0 - Attribution - Non-commercial use - International License

What is your diagnosis?

A rare parotid tumor

Christian Adrien RIGHINI ^{1,2,3*}, Cindy COLOMBE ¹⁻², Hugo GIL ¹

1: Service Hospitalo-Universitaire d'ORL et Chirurgie cervico-faciale, CHU de Grenoble – Alpes (CHUGA), France

2: Faculté de médecine, Universités des Alpes, Grenoble, France

3: UGA/UMR/CNRS 5309/Inserm 1209, Institut Albert Bonniot, Grenoble, France

*** Corresponding author:**

Professor Christian RIGHINI (MD-PhD)

Service HU d'ORL et CCF, CHU de Grenoble-Alpes (CHUGA)

Phone: +33-4/76/76/56/93; Fax: +33-4/76/76/51/20

e-mail: CRighini@chu-grenoble.fr

Case report

A 58-year-old man with no notable history consulted for a right parotid mass that had been present for 6 months and that had rapidly increased in size over the previous 2 months. Physical examination revealed a hard, tender mass with a long axis of 3.5 cm situated in the superior part of the parotid compartment, attached to deep planes, not adherent to the skin, with no facial palsy or enlarged lymph nodes. Examination of the pharynx, right external auditory canal and right tympanum was normal. MRI revealed a well circumscribed mass in contact with the masseter muscle, presenting a low-intensity signal on T1- and T2-weighted sequences, with gadolinium enhancement (Figure 1A), a descending plateau perfusion curve and a relative apparent diffusion coefficient (rADC) < 1. Fine-needle aspiration cytology was not contributive. The patient underwent parotidectomy with facial nerve dissection, with *en bloc* resection of the tumour that was adherent to the masseter muscle. Frozen section histological examination reported adenocarcinoma. Resection of the deep lobe of the parotid gland and right level IIA, IIB, III and IV lymph node dissection were also performed during the same procedure. The postoperative course was uneventful. Definitive histological examination concluded on a diagnosis of a rare tumour (Figure 1B-C-D) with no lymph node involvement. Adjuvant radiotherapy was administered.

What is your diagnosis?

Answer:

This tumour was a high-grade oncocytic mucoepidermoid carcinoma.

Salivary gland tumours represent 3 to 6% of all head and neck tumours and 80% of salivary gland tumours arise in the parotid glands, 10 to 17% of which are malignant. Mucoepidermoid carcinoma (MEC) is the most common malignant epithelial tumour (20%) [1]. Three subgroups of MEC are distinguished: low-grade, high-grade and intermediate-grade (30%) [2]. The mean age at diagnosis is 57 years, with no sex predominance, with a large proportion (78%) of tumours in Caucasian populations [3]. In the presence of a high mitotic index (Ki-67 immunolabelling: 80%), perineural invasion and a large number of intravascular emboli (Figure 1D), this case of MEC was classified in the high-grade subgroup. It also corresponded to the oncocytic variant. Only 12 cases of oncocytic MEC, comprising only 1 case of high-grade oncocytic MEC, have been reported in the literature, while all other cases were low-grade MEC [4-6].

The oncocytic component is characterized by a solid, compact architecture arranged in lobules, cords and trabeculae, mainly composed of polyhedral cells with abundant granular eosinophilic cytoplasm with a round, central and highly nucleolated nucleus (Figure 2B). It comprises rare, scattered goblet cells outlined by Alcian Blue (Figure 2C). Immunohistochemistry reveals diffuse nuclear positivity to proteins P63 and P40 and membrane positivity to protein CK7. Molecular biology reveals the presence of a rearrangement of the MAML2 gene, a transcription gene [6]. This histological variant constitutes a major diagnostic trap for pathologist due to the presence of oncocytic cells that can immediately and wrongly suggest a benign lesion. The presence of signs of malignancy (non-encapsulated tumour, invasion of muscles and adjacent fat, invasion of the facial nerve, presence of vascular emboli and/or perineural invasion), allows correction of the diagnosis

and must therefore be meticulously investigated, as these features may sometimes be very rare and scattered within the tumour, especially in the presence of a large oncocytic component, as in this case.

Treatment consists of radical parotid gland surgery (total parotidectomy with preservation of the facial nerve in the very great majority of cases) associated with ipsilateral level II, III, and IV lymph node dissection in a cN0 neck, followed by radiotherapy adapted to histoprognostic data.

In addition to the histological characteristics of the tumour, prognostic factors include the patient's age (poor prognosis for patients older than 60 years), tumour size, and the presence of histologically invaded lymph nodes. The mean 5-year recurrence-free survival is 60%. The main causes of treatment failure are local relapse and distant metastases [1, 2].

Conflict of interest: none

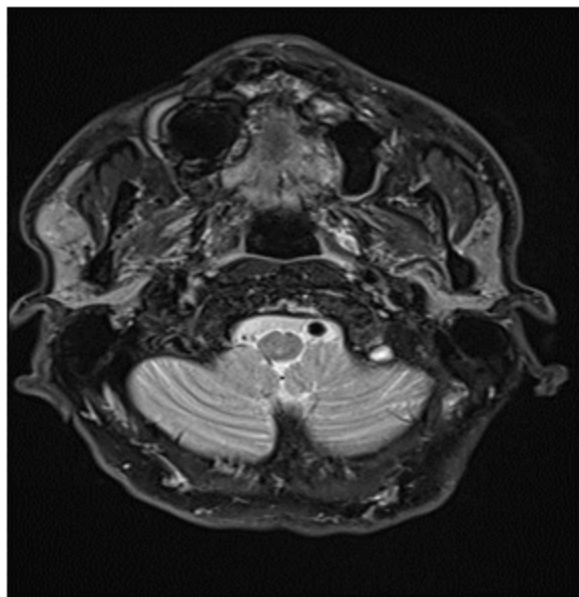
References

- 1) Stryjewska-Makuch C, Kolebacz B, Janik MA, Wolnik A. Increase in the incidence of parotid gland tumors in the years 2005-2014. *Otolaryngol Pol*, 2017; 71: 1-6.
- 2) Chen MM, Roman SA, Sosa JA, Judson BL. Histologic grade as prognostic indicator for mucoepidermoid carcinoma: a population-level analysis of 2400 patients. *Head Neck* 2014; 36: 158-62.
- 3) Rajasekaran K, Stubbs V, Chen J, et al. Mucoepidermoid carcinoma of the parotid gland: A national cancer database study. *Am J Otolaryngol* 2018; 39: 321-6.
- 4) Jahan-Parwar B, Huberman RM, Donovan DT, Schwartz MR, Ostrowski ML. Oncocytic mucoepidermoid carcinoma of the salivary glands. *Am J Surg Pathol* 1999; 23: 523-9.
- 5) Brannon RB, Willard CC. Oncocytic mucoepidermoid carcinoma of parotid gland origin. *Oral Surg Oral Med Oral Pathol Oral Radiol Endod* 2003; 96: 727-33.
- 6) Weinreb I, Seethala RR, Perez-Ordóñez B, Chetty R, Hoschar AP, Hunt JL. Oncocytic mucoepidermoid carcinoma: clinicopathologic description in a series of 12 cases. *Am J Surg Pathol* 2009; 33: 409-16.

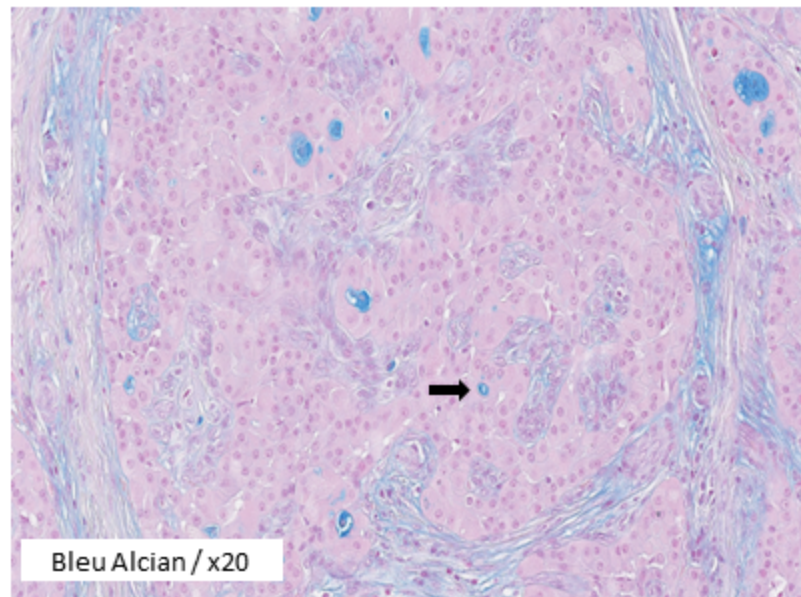
Figure 1:

A: Gadolinium-enhanced MRI, T1-weighted sequence; B: histological section, HES x 20 (polyhedral cells); C: Histological section, Alcian blue (goblet cells); D: histological section, HES x 20 (perineural invasion).

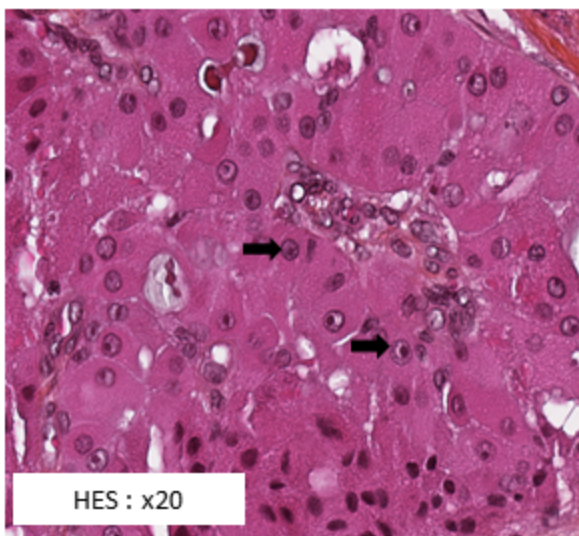
A



C



B



D

