



HAL
open science

Unilateral cochleovestibular nerve compression syndrome in a patient with bilateral IAC osteoma

P. Reynard, E. Ionescu, A. Karkas, A. Ltaeif-Boudrigua, H. Thai-Van

► **To cite this version:**

P. Reynard, E. Ionescu, A. Karkas, A. Ltaeif-Boudrigua, H. Thai-Van. Unilateral cochleovestibular nerve compression syndrome in a patient with bilateral IAC osteoma. *European Annals of Otorhinolaryngology, Head and Neck Diseases*, 2020, 137 (3), pp.213 - 216. 10.1016/j.anorl.2019.12.004 . hal-03491038

HAL Id: hal-03491038

<https://hal.science/hal-03491038>

Submitted on 22 Aug 2022

HAL is a multi-disciplinary open access archive for the deposit and dissemination of scientific research documents, whether they are published or not. The documents may come from teaching and research institutions in France or abroad, or from public or private research centers.

L'archive ouverte pluridisciplinaire **HAL**, est destinée au dépôt et à la diffusion de documents scientifiques de niveau recherche, publiés ou non, émanant des établissements d'enseignement et de recherche français ou étrangers, des laboratoires publics ou privés.



Distributed under a Creative Commons Attribution - NonCommercial 4.0 International License

Unilateral cochleovestibular nerve compression syndrome in a patient with bilateral IAC osteoma

Reynard P (1,2,3)*, Ionescu E (2,3), Karkas A (4), Ltaeif-Boudrigou A (5), Thai-Van H (1,2,3).

1 Claude Bernard Lyon 1 University, Lyon, France.

2 Department of Audiology and Otoneurological Evaluation, Civil Hospitals of Lyon, Lyon, France.

3 Hearing institute, Paris, U1120

4 Department of otorhinolaryngology, Centre hospitalo-universitaire of Saint Etienne, Saint Priest-en-Jarez, France.

5 Department of Radiology, Civil Hospitals of Lyon, Lyon, France.

Conflicts of Interest: none.

Source of Funding: none.

* Address correspondence to

Dr Pierre REYNARD e-mail: pierre.reynard@hotmail.fr Mobile: 0668511252

ABSTRACT

Introduction: Osteomas of the internal auditory canal are rarely reported in the literature. Patients may complain of disabling symptoms of dizziness, hearing loss, and vestibular dysfunction. We report the case of a patient with bilateral osteomas of the internal auditory canal (IAC) associated with bilateral neurovascular compression mainly affecting the right cochleovestibular nerve (VIII) and right anterior inferior cerebellar artery (AICA).

Observation: This 75-year-old woman patient complained of disabling paroxysmal vertigo, typewriter tinnitus and hearing loss of the right ear. Temporal bone computed tomography showed bilateral osteoma arising from the posterior superior wall of the IAC. MRI sequences of the right VIII demonstrated compression by the right AICA against the inferior wall of the narrowed IAC. Treatment with oxcarbazepine allowed marked and lasting improvement of the patient's symptoms.

Conclusion: To our knowledge, this is the first description of an ipsilateral neurovascular compression syndrome of the VIII secondary to the presence of an osteoma narrowing the IAC.

Key-Words

Bilateral osteoma; conducted auditory internal; vestibular paroxysmia; neurovascular compression.

INTRODUCTION

Osteomas of the internal auditory canal (IAC) are benign bone tumours, rarely observed in this site. The main differential diagnosis is exostosis, which does not contain any bone marrow, is often multiple and bilateral, and has a large implantation base [1]. Symptoms can include vertigo, sensorineural hearing loss, tinnitus or hemifacial palsy or spasm [1]. The term vestibular paroxysmia (VP) was coined by Brandt et al. [2] to describe brief and intense vertigo generated by compression-induced dysfunction (ephaptic transmission) of the cochleovestibular nerve (VIII), crossed by a vessel in the cerebellopontine angle. We report the case of a woman with bilateral IAC osteomas and hearing loss of the right ear associated with bilateral earache, and brief vertigo when rapidly turning the head. The characteristics of the ear pain corresponded to the clinical criteria of nervus intermedius (Wrisberg) neuralgia [3], the vertigo corresponded to Brandt's criteria [2] for VP and MRI revealed neurovascular compression (NVC) between the cochleovestibular nerve and the right anterior inferior cerebellar artery.

Since the first description of bilateral IAC osteoma by Vrabec et al. [4], only three similar cases have been reported in the literature [1, 5], and none of these published cases comprised associated NVC at the same site.

Case report

A 75-year-old woman with no otoneurological history attended our department with recent onset of hearing loss of the right ear associated with ipsilateral "typewriter" tinnitus, and bilateral paroxysmal ear pain radiating to the retroauricular region, that was worsened by palpation. She also described very brief episodes of severe vertigo. Otoneurovestibular clinical examination was normal, with no signs of vestibular deficit, or facial nerve dysfunction. Pure-tone audiometry revealed unilateral right nerve deafness with a mean

hearing loss of 60 dB, and speech audiometry was severely impaired on the right (speech reception threshold at 100 dB), but only slightly altered on the left (Fig. 1). However, auditory brainstem responses (clicks) demonstrated normal and symmetrical conduction times at 90 dB HL. Vestibular assessment by videonystagmography (Synapsis - Marseille) showed an isolated deficit of 25% on caloric tests on the right side. The Video Head Impulse Test (Otometrics, Denmark) showed a normal gain of the vestibulo-ocular reflex for the 3 pairs of semicircular canals. Vestibular-evoked myogenic potentials showed normal bilateral thresholds at 95dB HL. Computed tomography (CT; Fig. 2) demonstrated bilateral calcified opacities in the temporal bone, in the posterior superior part of the IAC, typical of osteomas. MRI of the IAC demonstrated bilateral hypointense images on T1- and T2-weighted sequences. On the T1-weighted 3D sequence, the porus of the IAC appeared to be narrowed (opening width: 2.2 mm on the right and 2.4 mm on the left), with a normal value of about 7 mm [6]. The anteroposterior diameters of the IAC were subnormal (normal: 4 mm, [6]). On the MRI fusion sequence (Gadolinium-enhanced T1 3D and T2 RH Drive, Philips Healthcare, Amsterdam, Netherlands), the right cochleovestibular nerve and the inferior part of the right facial nerve appeared to be compressed between the AICA and the inferior wall of the right IAC (Fig. 3). On the left side, only the inferior part of the facial nerve appeared to be compressed by the left AICA.

On the basis of these clinical and radiological findings, a diagnosis of right cochleovestibular nerve compression syndrome in a narrowed IAC due to osteoma was proposed. Bilateral nervus intermedius neuralgia secondary to compression was also suspected.

Treatment with oxcarbazepine (150 mg morning and evening for one month) was proposed. Vestibular symptoms gradually improved and tinnitus completely resolved. On completion of treatment, follow-up pure-tone audiometry showed almost normal thresholds in the right ear (Fig. 1), and speech audiometry was also almost normal. One year after tapering medical

treatment, the patient no longer presented any cochleovestibular symptoms, but continued to complain of less severe retroauricular pain.

DISCUSSION

According to the International Classification of Vestibular Disorders (ICVD) criteria of Barany's classification [7], this patient presented clinical signs strongly suggestive of right cochleovestibular neurovascular compression. Imaging confirmed the presence of bilateral osteomas in the porus of the IAC. On the right side, the osteoma appeared to have gradually altered the local anatomy by narrowing the IAC, predisposing to neurovascular compression of the right cochleovestibular nerve by the AICA. Auditory brainstem response (ABR) was normal in this patient, with no electrophysiological arguments in favour of NVC. According to De Ridder et al. ABR can be normal for the first few years of the disease, at the early stages of nerve demyelination and desynchronization [8]. Improvement of tinnitus and vestibular paroxysmia in response to low-dose antiepileptic drugs, as in our patient, has been well documented in the literature [2, 9]. Levine et al. reported a series of six patients with typewriter tinnitus in a context of probable NVC, which was improved by carbamazepine [10] a neuronal membrane stabilizer. In our patient, oxcarbazepine therapy appeared to have induced resolution of tinnitus on the right side, with marked ipsilateral improvement of hearing thresholds on pure-tone audiometry and a normal intelligibility score on speech audiometry, which could constitute an additional aetiological argument in favour of NVC. Retroauricular pain was only partially relieved by treatment and may correspond to secondary nervus intermedius neuralgia. Lietin et al. reported hemifacial spasm associated with an osteoma of the IAC [11]. As our patient did not present any hemifacial spasm, the compression may have more particularly involved the nervus intermedius. However, a nervus

intermedius lesion is difficult to confirm radiologically, as this small calibre nerve adherent to the vestibular nerve is almost impossible to detect by currently available MRI techniques, in contrast with the other cranial nerves involved in NVC [12]. To our knowledge, this is the first description of a case with symptomatic, ipsilateral neurovascular compression syndrome of the cochleovestibular nerve and nervus intermedius, secondary to the presence of a osteoma narrowing the IAC.

Conflicts of interest: none

REFERENCES

- [1] Schutt CA, Guo JN, Bagwell KA, Bulsara KR, Malhotra A, Michaelides E. Bilateral osteomas and exostoses of the internal auditory canal. *Am J Otolaryngol*. 2015;36:583-6.
- [2] Brandt T, Strupp M, Dieterich M. Vestibular paroxysmia: a treatable neurovascular cross-compression syndrome. *J Neurol*. 2016;263:0–6.
- [3] The International Classification of Headache Disorders (ICHD) 3rd edition, <https://www.ichd-3.org/13-painful-cranial-neuropathies-and-other-facial-pains/13-3-nervus-intermedius-facial-nerve-neuralgia/13-3-1-classical-nervus-intermedius-neuralgia/>.
- [4] Vrabec JT, Lambert PR, Chaljub G. Osteoma of the internal auditory canal. *Arch Otolaryngol Head Neck Surg*. 2000;126:895-8.
- [5] Gerganov VM, Samii A, Paterno V, Stan AC, Samii M. Bilateral osteomas arising from the internal auditory canal: case report. *Neurosurgery*. 2008;62:528-9.
- [6] Marques SR, Ajzen S, D Ippolito G, Alonso L, Isotani S, Lederman H. Morphometric analysis of the internal auditory canal by computed tomography imaging. *Iran J Radiol*. 2012;9:71-8.
- [7] Strupp M, Lopez-Escamez JA, Kim JS, Straumann D, Jen J, Carey J et al. Vestibular paroxysmia: Diagnostic criteria Consensus document of the Committee for the Classification of Vestibular Disorders of the Bárány Society. (<http://www.jvr-web.org/ICVD.html>). *J Vestib Res*. 2016;26:409-15.
- [8] De Ridder D, Heijneman K, Haarman B, van der Loo E. Tinnitus in vascular conflict of the eighth cranial nerve: a surgical pathophysiological approach to ABR changes. *Prog Brain Res*. 2007;166:401-11.
- [9] Russell D, Baloh RW. Gabapentin responsive audiovestibular paroxysmia. *J Neurol Sci*. 2009;281:99-100.
- [10] Levine RA. Typewriter tinnitus: a carbamazepine-responsive syndrome related to auditory nerve vascular compression. *ORL J Otorhinolaryngol Relat Spec*. 2006;68:43-6.
- [11] Liétin B, Bascoul A, Gabrillargues J, Crestani S, Avan P, Mom T, Gilain L. Osteoma of the internal auditory canal. *Eur Ann Otorhinolaryngol Head Neck Dis*. 2010;127:15-9.

[12] Inoue T, Shima A, Hirai H, Suzuki F, Matsuda M. Nervus Intermedius Neuralgia Treated with Microvascular Decompression: A Case Report and Review of the Literature. *NMC Case Rep J.* 2017 Jun 8;4(3):75-8.

Figures

FIG. 1. Audiométrie tonale sur l'oreille droite avant (A) et après traitement par oxcarbazépine (C). Audiométrie vocale avant traitement par oxcarbazépine (B).

FIG. 2. TDM crânienne dans un plan sagittal (A-B), axial (C-D), et coronal (E-F) montrant l'ostéome bilatéral des CAI (flèches noires), mesurant 0,58cm à gauche (fig D, F) et 0,7 cm à droite (fig C,E). Diamètre d'ouverture du CAI au porus: 2,2 mm à droite, 2,4mm à gauche (A-B, flèches vertes). Les diamètres antéropostérieurs sont normaux.

IG. 3. IRM des CAI. A : T2 Drive haute résolution (HR) en coupe axiale; B-E : séquences fusion (3D T1 avec injection gadolinium et T2 HR drive), en coupe axiale (B) montrant la compression du nerf facial gauche et du VIII droit dans les CAI au niveau des porus (flèches blanches). Dans le plan sagittal (C) le VIII droit (flèche blanche pointillée) est comprimé contre la paroi inférieure du CAI, dans un porus sténosé, par l'AICA droite (flèches blanches) diminution de la visibilité du LCR autour des structures vasculonerveuses.. Coupes coronales droite (D) et gauche (E), contact et effet de masse sur le NCV droit (D) et les fibres inférieures du nerf facial gauche (E) par l'ACAI droite et gauche respectivement (flèches blanches). Diamètre du CAI dans le porus droit: 2.4mm (D).

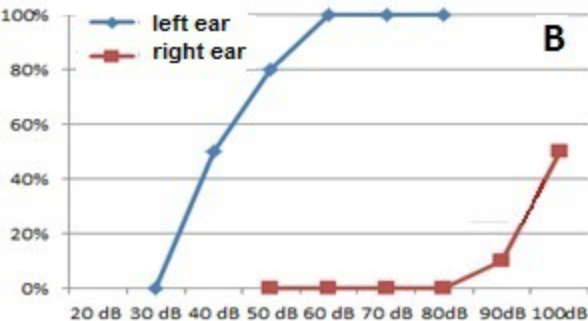
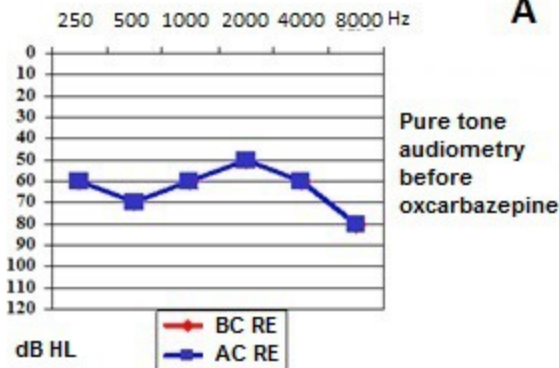
LEGENDS

Fig. 1. Right ear: pure-tone audiometry before (A) and after treatment with oxcarbazepine (C). Speech audiometry before treatment with oxcarbazepine (B).

Fig. 2. Head CT scan, sagittal (A-B), axial (C-D), and coronal (E-F) sections showing bilateral IAC osteomas (black arrows), measuring 0.58 cm on the left (Fig. D,F) and 0.7 cm

on the right (Fig. C,E). Diameter of the IAC meatus at the porus: 2.2 mm on the right, 2.4 mm on the left (A-B, green arrows). Anteroposterior diameters are normal.

Fig. 3. MRI of the IAC. A: T2 high-resolution (HR) DRIVE sequence; B-E: fusion (gadolinium-enhanced 3D T1 and T2 RH DRIVE) sequences. Compression of the left facial nerve (VII) and right cochleovestibular nerve (VIII) in the porus of the IAC in axial plane (A,B) (white arrows). Sagittal plane (C): the right VIII (dotted white arrow) is compressed against the inferior wall of the IAC, by the right AICA (white arrows) with decreased visibility of the CSF around neurovascular structures. Coronal plane (D,E): contact and mass effect on the right VIII (D) and inferior fibres of the left VII (E) by the left and right AICA, respectively (white arrows). Diameter of the IAC in the right porus: 2.4 mm (D).

A**C**