



HAL
open science

Total trapeziectomy for osteoarthritis of the trapeziometacarpal joint: Clinical and radiological outcomes in 21 cases with minimum 10-year follow-up

Ziad Abdallah, Marc Saab, Thomas Amouyel, Elvire Guerre, Christophe Chantelot, Nadine Sturbois-Nachef

► To cite this version:

Ziad Abdallah, Marc Saab, Thomas Amouyel, Elvire Guerre, Christophe Chantelot, et al.. Total trapeziectomy for osteoarthritis of the trapeziometacarpal joint: Clinical and radiological outcomes in 21 cases with minimum 10-year follow-up. *Orthopaedics & Traumatology: Surgery & Research*, 2020, 106, pp.775 - 779. 10.1016/j.otsr.2020.02.008 . hal-03490683

HAL Id: hal-03490683

<https://hal.science/hal-03490683v1>

Submitted on 22 Aug 2022

HAL is a multi-disciplinary open access archive for the deposit and dissemination of scientific research documents, whether they are published or not. The documents may come from teaching and research institutions in France or abroad, or from public or private research centers.

L'archive ouverte pluridisciplinaire **HAL**, est destinée au dépôt et à la diffusion de documents scientifiques de niveau recherche, publiés ou non, émanant des établissements d'enseignement et de recherche français ou étrangers, des laboratoires publics ou privés.



Distributed under a Creative Commons Attribution - NonCommercial 4.0 International License

Original article

Total trapeziectomy for osteoarthritis of the trapeziometacarpal joint: clinical and radiological outcomes in 21 cases with minimum 10-year follow-up

Ziad **Abdallah**^{a,b*}, Marc **Saab**^{a,b}, Thomas **Amouyel**^{a,c}, Elvire **Guerre**^{a,b}, Christophe **Chantelot**^{a,d}, Nadine **Sturbois-Nachet**^{a,b}

a: CHU Lille, Université Lille–Nord-de-France, F-59000 Lille, France

b: Service d'Orthopédie B, Hôpital Salengro, CHU de Lille, Place de Verdun, 59037
Lille cedex, France

c: Service d'Orthopédie A, Hôpital Salengro, CHU de Lille, Place de Verdun, 59037
Lille cedex, France

d: Service de Traumatologie, Hôpital Salengro, CHU de Lille, Place de Verdun, 59037
Lille cedex, France

***Corresponding author:** Ziad Abdallah, Chirurgie Orthopédique et Traumatologique, CHU de Lille, Hôpital Salengro, Place de Verdun, 59037 Lille cedex, France

Telephone: +33(0)3 20 44 67 05

Fax: +33(0)3 20 44 67 71

E-mail: ziad.g.abdallah@gmail.com

ABSTRACT

Introduction: Trapeziectomy is a technique of choice for osteoarthritis of the trapeziometacarpal joint, but few studies have assessed long-term radiological and clinical outcome in total trapeziectomy, mean follow-up being rather between 2 and 6 years in most cases. The main aim of the present study was to assess loss of trapezium space height at a minimum 10 years' follow-up. Secondary endpoints comprised functional outcome at the same follow-up.

Hypothesis: There is systematic loss of trapezium space height, with discrepancy between radiological and clinical results, beyond 10 years' follow-up.

Material Methods: Sixteen patients were retrospectively reassessed at a mean 13.8 years' follow-up (range, 10-17.8 years), for 21 total trapeziectomies. Criteria for the main endpoint comprised trapezium space height (TSH) and trapezium space ratio (TSR = TSH/ thumb P1 phalanx length). Secondary endpoint criteria comprised pain, Kapandji opposition and retropulsion scores, active abduction, dynamometric parameters (key-pinch, tip-pinch and grip strength compared to the contralateral side), QuickDASH and satisfaction.

Results: Mean TSH and TSR were respectively 3.7 mm (range, 0.5-6.1) and 0.14 (0.02-0.25) at last follow-up. Ranges of motion were conserved, with mean Kapandji score of 9.3 (6-10), Kapandji retropulsion score of 2.8 (1-4) and active abduction of 43° (30-45°). Strength measurements were comparable to contralateral values except for key-pinch, which was significantly weaker on the operated side (4.8kg (1.5-8.5kg) versus 5.5kg (1.5-8kg); $p=0.041$). Mean QuickDASH was 23.5 (0-68.2), and overall satisfaction on VAS was 9.5/10 (6-10). Statistical testing confirmed the absence of correlation between radiological and clinical criteria.

Discussion: Despite systematic trapezium space height loss, functional results were satisfactory and stable at a mean follow-up of 13.8 years. There was no correlation between radiological and clinical criteria in the long term.

Level of evidence

IV, single-center retrospective study.

Key-words: *Trapeziectomy, ligamentoplasty, interposition, trapezium space height, scaphometacarpal contact*

Abbreviations:

LRTI: Ligament reconstruction and tendon interposition

IT: Interposition tendinoplasty

TSH: Trapezium space height

TSR: Trapezium space ratio

1. Introduction

Trapeziometacarpal osteoarthritis is the second most frequent location of degenerative hand joint disease after the distal interphalangeal joint. Several surgical procedures are possible for its management, of which the two main ones are: trapeziectomy and prosthetic arthroplasty.

Gervis [1] was the first to describe simple total trapeziectomy. To avoid 1st metacarpal proximal migration, complementary procedures to trapeziectomy are possible, either to fill the trapezium compartment [2-5], or to stabilize the base of the first metacarpal by ligament reconstruction, with or without tendon interposition [6-10]. Loss of trapezium space height (TSH) impairs strength and induces instability according to some authors [11–13], although others find no correlation between such collapse and functional results [14–16]. Outcome of total trapeziectomy in the long term, however, is unclear [17–19], mean follow-up ranging between 2 and 6 years depending on the report

The main aim of the present study was to assess TSH loss at a minimum follow-up of 10 years. Secondary objectives were to assess functional outcomes and to study the correlation between radiological and clinical criteria at last follow-up. Our hypothesis was that a constant loss of TSH with radio-clinical discrepancy would be observed at more than 10 years.

2. Material and Methods

2.1 Patients

Patients undergoing total trapeziectomy (4 surgeons) between January 2000 and December 2009 were included, the criteria being primary trapeziometacarpal osteoarthritis and a minimum 10 years' follow-up. Exclusion criteria comprised secondary trapeziectomy and history of trauma in the thumb column.

2.2 Surgery

The approach was dorsolateral, centered on the trapeziometacarpal joint. The radial nerve sensory branches and radial artery were located and retracted. After capsulotomy, the trapezium was progressively released after locating the palmar flexor carpi radialis (FCR); longitudinal osteotomy was generally associated to facilitate extraction. Associated procedures comprised tendon interposition (TI) and ligament reconstruction with FCR tendon interposition (LRTI).

In TI [20], the first dorsal compartment was incised and then opened longitudinally in its entirety. A palmar hemi-tendinous strip of abductor pollicis longus (APL) was harvested, keeping its distal attachment, and sectioned as close as possible to its myotendinous junction. The entire palmaris longus (PL) tendon was harvested through two small transverse antebrachial incisions. The APL strip, keeping its distal attachment with the first metacarpal, was tied to the PL to form a tendon "anchovy", fixed by X-points to the PDS 3/0 and then placed in the trapezium lodge.

In LRTI, following Burton and Pellegrini [9], after resecting the metacarpal base transversally to its axis, a 10-12 cm radial FCR hemi-strip was harvested by 3 successive antebrachial incisions, conserving the distal attachment and releasing it from the myotendinous junction, and placed inside the trapezium space. A bone tunnel was created from the intramedullary canal of the 1st metacarpal base to the radial cortex using a 3.5 mm drill.

The 1st metacarpal was pulled distally and placed in abduction in the scaphoid axis, taking care that its base was aligned with that of the 2nd metacarpal, and temporarily fixed by a longitudinal K-wire. An FCR hemi-strip was passed in-out through the bone tunnel and sutured to itself (PDS 3/0) then introduced in the trapezial space as a tendon “anchovy”.

2.3 Assessment

Demographic data (age at surgery and at last follow-up, gender, dominant side) and surgical data (time to treatment, date of surgery, side, associated procedures) were collected.

To address the main endpoint, osteoarthritis was staged following Eaton and Littler [21]. TSH and TSR (TSR = TSH/P1: Figure 1) were measured on Kapandji lateral views [22], preoperatively, early postoperatively (1-3 months) and at last follow-up. Cases of radiographic scaphometacarpal contact were noted.

To address the secondary endpoints, pain (on visual analog scale (VAS) and location), any deformity, Kapandji opposition and retropulsion scores, active abduction (between 1st and 3rd metacarpal), metacarpophalangeal extension, Jamar® dynamometric assessment of strength (tip-pinch, key-pinch and grip), QuickDASH and overall satisfaction on VAS were assessed.

2.4 Statistical analysis

On SPSS Statistics software v20 (IBM Inc.), qualitative data were reported as number and percentage, and continuous quantitative data as mean and range. Distribution normality was checked graphically and on Shapiro-Wilk test. The Wilcoxon test was used to compare mean early postoperative and last follow-up TSH and TSR values and dynamometric values versus the contralateral side. The Mann-Whitney test was used to compare progression in TSH and TSR in total trapeziectomy with LRTI versus IT. The significance threshold was set at 0.05. Spearman correlation tests were performed between radiological and clinical variables.

3. Results

Fifty-three of the 67 patients undergoing total trapeziectomy were included, 16 of whom (21 trapeziectomies), all right-handed, were followed up. Mean follow-up was 13.8 years (range, 10-17.8 years). Table 1 shows demographic and surgical data.

Preoperative Eaton-Littler grading [21] showed 3/21 cases of stage II, 9/21 of stage III and 9/21 of stage IV. Early postoperative TSH was 5.6 mm (range, 3.8-8), compared to 3.7 mm (0.5-6.1) at last follow-up (p=0.002): i.e., 29% loss (Table 2); TSR was 0.21 (0.15-0.29) and 0.14 (0.05-0.25), respectively (p=0.001), compared to a normal value of 0.47 [23], without significant difference according to LRTI versus TI (respectively p=0.173 and p=0.392) (Table 3). Three of the 21 cases showed scaphometacarpal contact, all in LRTI, including 1 with emergence of a neo-joint at 17.8 years (Figure 3).

Table 4 shows functional results. Sixteen of the 21 hands were asymptomatic, 5 were painful (mean VAS 1.4/10 (range, 0-4) resting and 4.4/10 (2-6) in everyday activity). Pain was located at the scaphometacarpal space in 3 cases (2 with radiographic scaphometacarpal contact) and related to de Quervain tendinitis in 2, both in LRTI. There were 2 cases of reducible Z-thumb. There were no correlations between radiological and clinical criteria at last follow-up (Table 5).

4. Discussion

The present series exhibited systematic TSH loss, with 3 total collapses, at >10 years' follow-up. However, there were no correlations between radiological and clinical results, and functional results were satisfactory.

TSH loss between the early postoperative period and last follow-up was 29%, comparable to the 27% at 6.5 years reported by Ferrière et al. [24]. Pomares et al. [19] reported TSH of 6.5 mm postoperatively and 3.6 mm at 13 years. Burton and Pellegrini [9] reported 11% height loss at 2 years, and Yang et al. [15] 21% at 2.7 years. The present findings for TSR were similar to those of Heyworth et al. [25], who found $TSR = 0.14$ (range, 0.02-0.25) at 9 years; Kadiyala et al. [22] reported 0.27 at 2 years. Le Viet et al. [26], reporting annual radiographic follow-up, found 0.5 mm/year TSH loss, progressively stabilizing at 3.1 mm at 5 years: height loss seemed to occur during the first years, then stabilized. In the present study, TSH loss was 32% in LRTI and 23% in TI. This difference was statistically non-significant due to lack of power and difference in numbers between groups. Nevertheless, greater TSH loss in LRTI was also reported by Stussi et al. [27]: 40% in LRTI and 29% in TI at 2.6 years; they explained this outcome by loss of suspension sling tension due to traction, accelerating trapezial space collapse. Pomares et al. [19], on the other hand, found no such significant difference at 13 years' follow-up.

In the present study, functional results were satisfactory, uncorrelated with TSH loss or TSR, similarly to the literature [3,6,10,12,15,18–20,24]. Only key-pinch was significantly weaker in the operated hand in the present series. Vandenbroucke et al. [28] found systematically impaired key-pinch postoperatively. Moineau et al. [29] attributed this loss of strength to metacarpophalangeal hyperextension due to trapezial space collapse. Le Viet et al. [26] found significantly greater postoperative strength with greater TSH. Most authors, however, found no correlation between TSH and key-pinch strength [11,16,18,27,30]. There were 3 cases of major trapezial space collapse in the present series, including 1 with scaphometacarpal neo-joint, the other 2 showing a small residual interosseous space. Camus [31] and Dell [32] accounted for this by persistence of a fibrous layer between the two bones despite progressive disappearance of the tendinous interposition.

The present study had certain limitations. The retrospective design entailed loss of information, notably in immediate postoperative data. Sample size was small, notably for comparison between stabilization techniques. Even so, the results agreed with those of larger studies, which found no functional superiority for any one technique [17,33–35].

5. Conclusion

TSH loss was systematic in the present series of total trapeziectomies, whatever the associated tendon procedures. Even so, despite a mean follow-up of 13 years, the rate of scaphometacarpal contact was low. Functional results were paradoxically satisfactory, in discordance with radiographic findings, thereby showing the enduring reliability of the procedure.

Disclosure of interest:

None of the authors have conflicts of interest to disclose in relation to the present study.

Funding:

None.

Author contributions:

ZA, MS and NS: study design and development. ZA: data extraction and first draft. ZA, MS, NS, TA, EG and CC: data analysis and interpretation. All authors contributed to critical revision of content and read and approved the final version.

Consent:

All patients were informed of the purpose of the consultation and provided written consent.

Figure legends

Figure 1: Kapandji lateral view:

- a. Trapezial space height (TSH) is the perpendicular distance between the tangents to the proximal tip of the 1st metatarsal and distal tip of the scaphoid
- b. Trapezial space ratio (TSR) is the ratio of TSH to thumb P1 length

Figure 2: Flowchart

Figure 3: Results for patient n° 14 at 17.8 years' follow-up of left trapeziectomy with LRTI.

- a. Kapandji lateral view at last follow-up
- b. Kapandji score: 9/10
- c. Active abduction: 40°

Patient	Gender	Age at surgery (years)	Follow-up (years)	Associated procedure	Operated side
1	F	51	11.9	LRTI	Left
2	F	62	13.9	TI	Right
3	F	43	12.5	TI	Right
4	M	50	16.8	LRTI	Right
5	F	40	16.9	LRTI	Right
6	M	51	17.1	LRTI	Left
6	M	58	10.8	LRTI	Right
7	F	68	19	LRTI	Right
7	F	72	14.7	LRTI	Left
8	F	65	11	TI	Left
9	F	57	10	TI	Left
10	F	43	16.2	LRTI	Left
11	M	61	17	LRTI	Right
11	M	63	15.3	LRTI	Left
12	F	66	11	LRTI	Left
12	F	67	10	LRTI	Right
13	M	44	16.3	LRTI	Right
14	F	52	17.8	LRTI	Left
15	F	58	10	LRTI	Right
15	F	58	10	LRTI	Left
16	F	63	12.7	TI	Right
Total	F=12	---	---	LRTI=16	Right=11
	M=4			TI=5	Left=10
Mean	---	56.8	13.8	---	---

Table 1: Patient and surgery data (LRTI: ligament reconstruction with tendon interposition; TI: tendon interposition)

	Postoperative	Follow-up \geq 10 years	Δ	<i>p</i>
TSH (mm)	5.6 (3.8-8)	3.7 (0.5-6.1)	29%	0.002
TSR	0.21 (0.15-0.29)	0.14 (0.02-0.25)	30%	0.001

Δ : mean decrease from postoperative to \geq 10 year values

Table 2: radiographic assessment of trapezial space height (TSH) and trapezial space ratio (TSR) postoperatively and at \geq 10 years' follow-up

	LRTI	TI	<i>p</i>	Total
Number of surgeries	16	5		21
Postoperative TSH (mm)	5.6 (3.8-8)	5.4 (4-6.5)	---	5.6 (3.8-8)
TSH ≥ 10 years (mm)	3.5 (0.5-5.4)	4.3 (2.2-6.1)	0.173	3.7 (0.5-6.1)
Δ TSH (%)	32%	23%	---	29%
Postoperative TSR	0.21 (0.15-0.29)	0.20 (0.16-0.21)	---	0.21 (0.15-0.29)
TSR ≥ 10 years	0.14 (0.02-0.25)	0.15 (0.09-0.17)	0.392	0.14 (0.02-0.25)
Δ TSR	0.7	0.5	---	0.6

Δ: mean decrease from postoperative to ≥10 year values

Table 3: Comparison of trapezial space height (TSH) and trapezial space ratio (TSR) according to associated LRTI (ligament reconstruction with tendon interposition) or TI (tendon interposition)

	Operated side	Non-operated side	<i>p</i>
Pain – Yes	5/21	---	---
Pain - No	16/21	---	---
Kapandji	9.3 (6-10)	9.9 (9-10)	---
Kapandji inverted	2.8 (1-4)	3.3 (2-4)	---
Tip pinch (kg)	3.6 (1-8)	3.9 (1-6)	0.145
Key pinch (kg)	4.8 (1.5-8.5)	5.5 (1.5-8)	0.041
Fist (kg)	24.0 (8-44)	22.5 (12-50)	0.812
Abduction M1-M3 (°)	43.0 (30-45)	41.8 (30-45)	---
Extension MP (°)	18.3 (0-30)	12.5 (0-30)	---
QuickDASH	23.5 (0-68.2)	---	---
VAS overall satisfaction	9.5 (6-10)	---	---

Table 4: Functional assessment at ≥ 10 years. M1-M3: 1st and 3rd metacarpal; MP: metacarpophalangeal joint; VAS: visual analog scale

		QuickDASH	Key-pinch (kg)	Tip-pinch (kg)
TSH at 10 years (mm)	ρ	0.124	0.187	0.226
TSR at 10 years	ρ	0.355	0.089	0.132
Δ TSH	ρ	0.083	-0.243	-0.282
Δ TSR	ρ	0.070	-0.222	-0.209

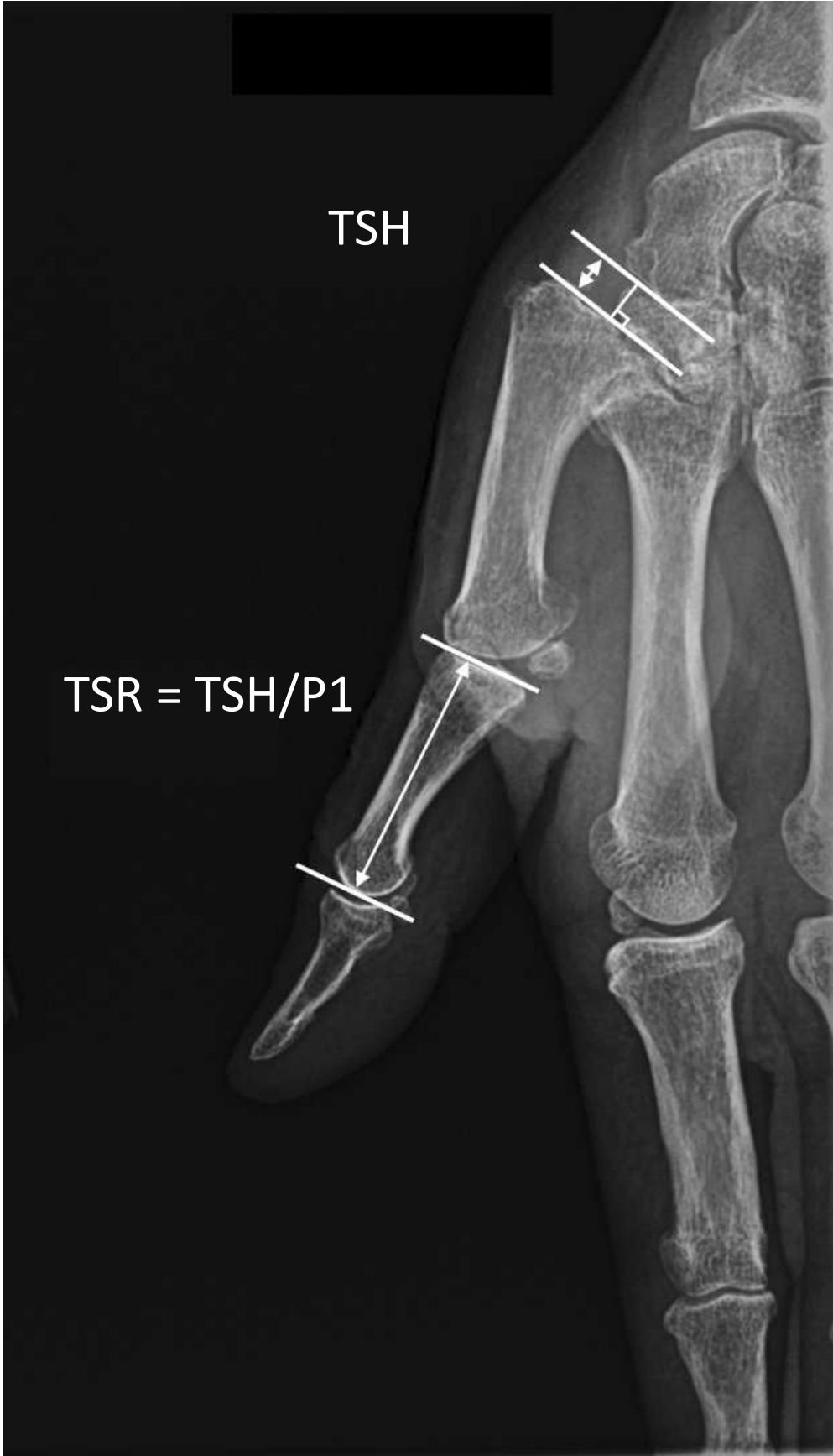Table 5: Spearman correlation between radiologic and clinical criteria. $\rho = 1$ indicates a perfect linear relation; 0 indicates no linear relation.

References

1. Gervis WH. Excision of the trapezium for osteoarthritis of the trapezio-metacarpal joint. *Postgrad Med J* 1948;24:262–4.
2. Dell PC, Muniz RB. Interposition arthroplasty of the trapeziometacarpal joint for osteoarthritis. *Clin Orthop* 1987;220:27–34.
3. Menon J, Schoene HR, Hohl JC. Trapeziometacarpal arthritis—Results of tendon interpositional arthroplasty. *J Hand Surg* 1981;6:442–6.
4. Swanson AB. Disabling Arthritis at the Base of the Thumb: Treatment by resection of the trapezium and flexible (silicone) implant arthroplasty. *J Bone Joint Surg Am.* 1972;53:456-71.
5. Obert L, Gallinet D, Lepage D, Kantelip B, Lerais J-M, Vidal C, et al. Évaluation de la greffe de cartilage costal en chirurgie de membre supérieur. *Rev Chir Orthop* 2008;94:64
6. Kleinman WB, Eckenrode JF. Tendon suspension sling arthroplasty for thumb trapeziometacarpal arthritis. *J Hand Surg* 1991;16:983–91.
7. Sigfusson R, Lundborg G. Abductor pollicis longus tendon arthroplasty for treatment of arthrosis in the first carpometacarpal joint. *Scand J Plast Reconstr Surg Hand Surg.* 1991;25:73–7.
8. Weilby A. Surgical treatment of osteoarthritis of the carpo-metacarpal joint of the thumb. Indications for arthrodesis, excision of the trapezium, and alloplasty. *Scand J Plast Reconstr Surg* 1971;5:136–41.
9. Burton RI, Pellegrini VD. Surgical management of basal Joint arthritis of the thumb. Part II. Ligament reconstruction with tendon interposition arthroplast. *J Hand Surg* 1986;11:324–32.
10. Moineau G, Richou J, Gérard R, Nen DL. Trapézectomies et ligamentoplasties de suspension au Gore-Tex ® : résultats préliminaires sur 43 arthroses trapézométacarpiennes. *Chirurgie de la main* 2008;27:146-153
11. Gray KV, Meals RA. Hematoma and Distraction Arthroplasty for Thumb Basal Joint Osteoarthritis: Minimum 6.5-Year Follow-Up Evaluation. *J Hand Surg* 2007;32:23–9.
12. Degeorge B, Dagneaux L, Andrin J, Lazerges C, Coulet B, Chammas M. Do trapeziometacarpal prosthesis provide better metacarpophalangeal stability than trapeziectomy and ligamentoplasty? *Orthop Traumatol Surg Res* 2018;104:1095–100.
13. Ebelin M, Hoet F, Schernberg F, Foucher G, Leviet D. Les trapézectomies Résultats de l'étude multicentrique (96 cas). *Ann Chir Main Memb Supér* 1990;9:176–9.
14. Tomaino MM, Pellegrini VD, Burton RI. Arthroplasty of the basal joint of the thumb. Long-term follow-up after ligament reconstruction with tendon interposition. *J Bone Joint Surg Am* 1995;77:346–55.

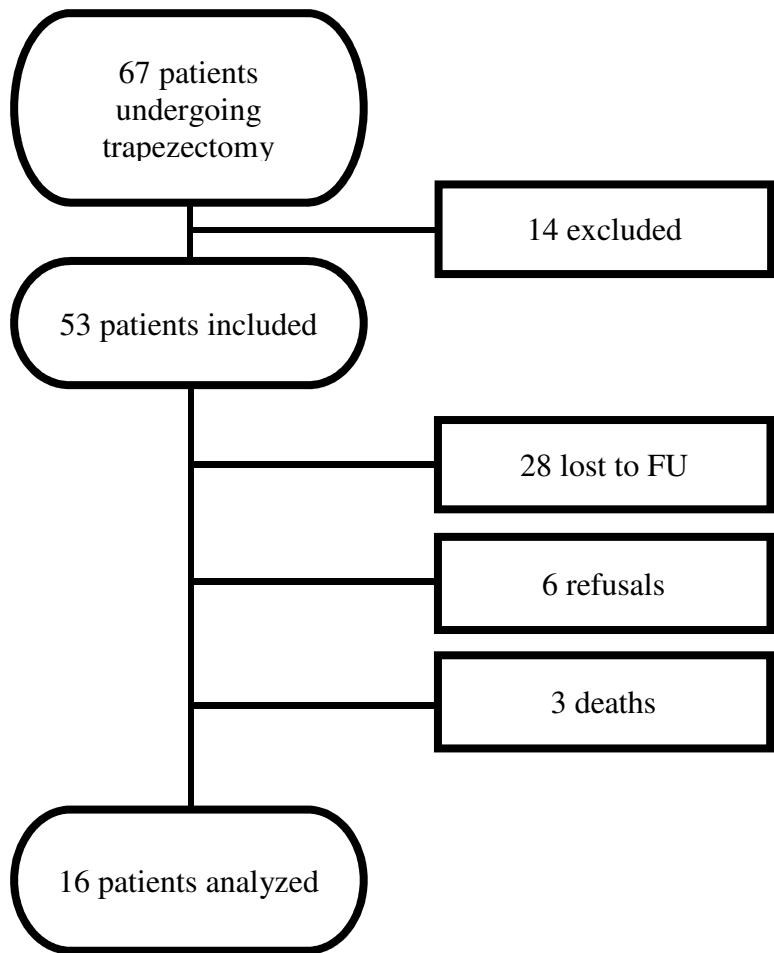
15. Yang SS, Weiland AJ. First metacarpal subsidence during pinch after ligament reconstruction and tendon interposition basal joint arthroplasty of the thumb. *J Hand Surg* 1998;23:879–83.
16. Downing ND, Davis TRC. Trapezial space height after trapeziectomy: Mechanism of formation and benefits. *J Hand Surg* 2001;26:862–8.
17. Vinycomb T, Crock J. Trapeziectomy with ligament reconstruction and tendon interposition: a minimum 10-year follow-up. *Hand Surg* 2013;18:365–8.
18. Illarramendi AA, Boretto JG, Gallucci GL, De Carli P. Trapeziectomy and Intermetacarpal Ligament Reconstruction With the Extensor Carpi Radialis Longus for Osteoarthritis of the Trapeziometacarpal Joint: Surgical Technique and Long-Term Results. *J Hand Surg* 2006;31:1315–21.
19. Pomares G, Delgrande D, Dap F, Dautel G. Minimum 10-year clinical and radiological follow-up of trapeziectomy with interposition or suspensionplasty for basal thumb arthritis. *Orthop Traumatol Surg Res* 2016;102:995–1000.
20. Thompson, J.S. Surgical treatment of trapeziometacarpal arthrosis. *Adv Orthop Surg* 1986;10:105–120.
21. Eaton RG, Littler JW. Ligament reconstruction for the painful thumb carpometacarpal joint. *J Bone Joint Surg Am* 1973;55:1655–66.
22. Kadiyala RK, Gelberman RH, Kwon B. Radiographic assessment of the trapezial space before and after ligament reconstruction and tendon interposition arthroplasty. *J Hand Surg Edinb Scotl* 1996;21:177–81.
23. Lins RE, Gelberman RH, McKeown L, Katz JN, Kadiyala RK. Basal joint arthritis: Trapeziectomy with ligament reconstruction and tendon interposition arthroplasty. *J Hand Surg* 1996;21:202–9.
24. Ferrière S, Mansat P, Rongièrès M, Mansat M, Bonneville P. Trapézectomie totale avec tendinoplastie de suspension et d'interposition dans le traitement de la rhizarthrose : résultats à 6,5 ans de recul moyen. *Chirurgie de la Main* 2010;29:26-22
25. Heyworth BE, Jobin CM, Monica JT, Crow SA, Lee JH, Rosenwasser MP. Long-Term Follow-Up of Basal Joint Resection Arthroplasty of the Thumb With Transfer of the Abductor Pollicis Brevis Origin to the Flexor Carpi Radialis Tendon. *J Hand Surg* 2009;34:1021–8.
26. Le Viet DT, Kerboull L, Lantieri LA, Collins DE. Stabilized resection arthroplasty by an anterior approach in trapeziometacarpal arthritis: Results and surgical technique. *J Hand Surg* 1996;21:194–201.
27. Stussi JD, Dap F, Merle M. Étude rétrospective de 69 rhizarthroses primitives opérées par trapézectomie totale suivie dans 34 cas de tendinoplastie d'interposition et dans 35 cas de suspensioplastie. *Chir Main* 200;19:116–27.

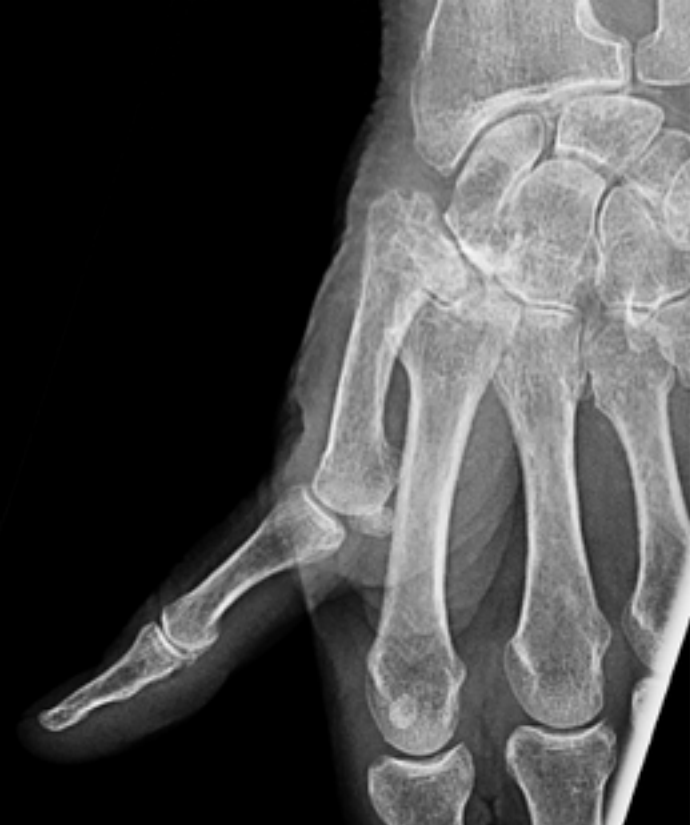28. Vandenbroucke J, De Schrijver F, De Smet L, Fabry G. Simple trapezectomy for treatment of trapeziometacarpal osteoarthritis of the thumb. *Clin Rheumatol* 1997;16:239–42.
29. Moineau G, Richou J, Liot M, Le Nen D. Prognostic factors for the recovery of hand function following trapeziectomy with ligamentoplasty stabilisation. *Orthop Traumatol Surg Res* 2009;95(5):352–8.
30. Gangopadhyay S, McKenna H, Burke FD, Davis TRC. Five- to 18-year follow-up for treatment of trapeziometacarpal osteoarthritis: a prospective comparison of excision, tendon interposition, and ligament reconstruction and tendon interposition. *J Hand Surg* 2012;37:411–7.
31. Camus E, Farez E, Rtaimate M, Millot F, Bouretz J-Cl. Traitement chirurgical de la rhizarthrose par trapézectomie-interposition-ligamentoplastie. *Chir Main* 2000;19:36–43.
32. Dell PC, Brushart TM, Smith RJ. Treatment of trapeziometacarpal arthritis: Results of resection arthroplasty. *J Hand Surg* 1978;3:243–9.
33. Vermeulen GM, Slijper H, Feitz R, Hovius SER, Moojen TM, Selles RW. Surgical management of primary thumb carpometacarpal osteoarthritis: a systematic review. *J Hand Surg* 2011;36:157–69.
34. Kriegs-Au G, Petje G, Fojtl E, Ganger R, Zachs I. Ligament reconstruction with or without tendon interposition to treat primary thumb carpometacarpal osteoarthritis. A prospective randomized study. *J Bone Joint Surg Am* 2004;86:209–18.
35. Davis TRC, Brady O, Dias JJ. Excision of the trapezium for osteoarthritis of the trapeziometacarpal joint: a study of the benefit of ligament reconstruction or tendon interposition. *J Hand Surg* 2004;29:1069–77.



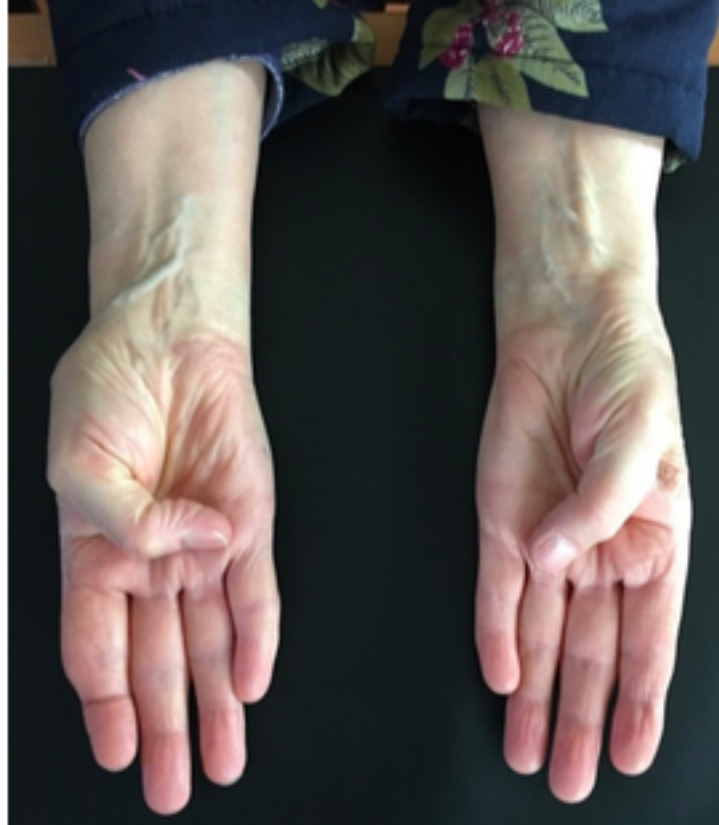TSH

TSR = TSH/P1

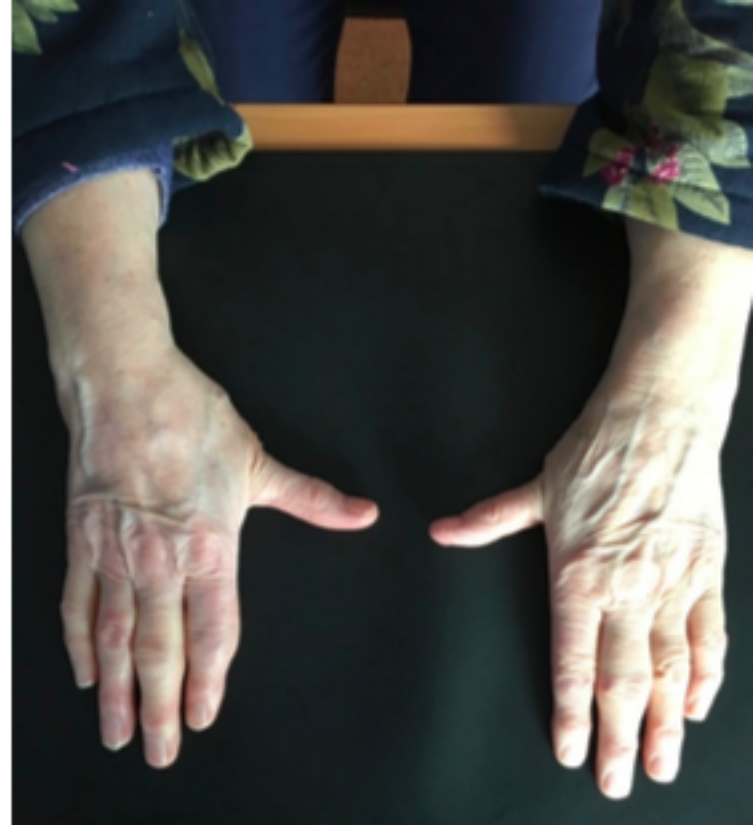



a.



b.



c.