



HAL
open science

Cushing's syndrome: Treatment and new therapeutic approaches

Amandine Ferriere, Antoine Tabarin

► **To cite this version:**

Amandine Ferriere, Antoine Tabarin. Cushing's syndrome: Treatment and new therapeutic approaches. *Best Practice and Research: Clinical Endocrinology and Metabolism*, 2020, 34, pp.101381 -. <10.1016/j.beem.2020.101381>. <hal-03490271>

HAL Id: hal-03490271

<https://hal.science/hal-03490271v1>

Submitted on 3 Jun 2022

HAL is a multi-disciplinary open access archive for the deposit and dissemination of scientific research documents, whether they are published or not. The documents may come from teaching and research institutions in France or abroad, or from public or private research centers.

L'archive ouverte pluridisciplinaire HAL, est destinée au dépôt et à la diffusion de documents scientifiques de niveau recherche, publiés ou non, émanant des établissements d'enseignement et de recherche français ou étrangers, des laboratoires publics ou privés.



Distributed under a Creative Commons CC BY-NC 4.0 - Attribution - Non-commercial use - International License

Cushing's syndrome: treatment and new therapeutic approaches

Amandine Ferriere¹, Antoine Tabarin^{1,2}

¹Service d'endocrinologie, diabétologie et maladies métaboliques. CHU de bordeaux. Avenue Magellan 33600 PESSAC

² INSERM and University of Bordeaux, Neurocentre Magendie, U1215

Address : Service d'endocrinologie, diabétologie et maladies métaboliques. CHU de bordeaux. Avenue Magellan 33600 PESSAC.

Email address : amandine.ferriere@chu-bordeaux.fr; antoine.tabarin@chu-bordeaux.fr

Telephone: +33 557656078

Fax number: +33 557656529

Corresponding author:

Antoine Tabarin: antoine.tabarin@chu-bordeaux.fr

Abstract (110 words)

Overt Cushing's syndrome is a severe condition responsible for multiple comorbidities and increased mortality. Effective treatment is essential to reduce mortality, improve comorbidities and long-term quality of life. Surgical resection of the causal lesion(s) is generally the first-line and most effective treatment to normalize cortisol secretion. Adjunctive symptomatic treatments of co-morbidities are often necessary both during the active phase of the disease and for persisting co-morbidities after cessation of hypercortisolism. Second-line treatments include various pharmacological treatments, bilateral adrenalectomy, and radiotherapy of corticotroph tumors. The choice of these treatments is complex, must be performed in a multidisciplinary expert team to be individualized for each patient, and use a shared decision-making approach.

Key Words:

Cushing's syndrome, Cushing's disease, intense hypercortisolism, surgery, pituitary radiotherapy, bilateral adrenalectomy, anticortisolic drugs

Issues in the treatment of Cushing's syndrome (CS) – relative importance of specific and symptomatic treatments

Chronic glucocorticoid excess results in numerous co-morbidities that impair quality of life and increased mortality [1]. Cardiovascular disease and infections are the most frequent causes of deaths in relation with Cushing's syndrome [1,2]. Normalization of cortisol production is the most-efficient way to improve and cure hypercortisolism-related comorbidities. However, a long delay may be needed before establishing a definitive etiological diagnosis and performing curative treatment. Moreover, curative treatment is not always feasible in patients with unresectable causative tumor or an occult-ACTH secreting lesion. In these cases, symptomatic treatment of comorbidities (such as hypertension and diabetes mellitus) is mandatory while waiting for the beneficial effects of specific treatments [3]. Symptomatic treatments and prevention of complications such as thromboembolism and infections are also of paramount importance in the context of intense hypercortisolism, a life-threatening condition in the short term, that is often due to ectopic ACTH-secreting tumors [3].

Elsewhere, recent studies have shown that complications, including diabetes, hypertension, impaired glucose tolerance, cognitive deficits, and others, may persist following cure of CS [4,5]. Similarly, despite being cured, patients with a history of Cushing's disease (CD) may carry a residual increased mortality rate and patients with persistent diabetes and hypertension are particularly at risk [6,7]. Therefore, the treatment of persistent co-morbidities after cure is an important therapeutic aspect.

One current emerging key point is that the duration of exposure to cortisol excess may play a major role in the persistence of comorbidities and life-expectancy after cessation of CS [8]. This suggests that the rapidity of intervention to control hypercortisolism is of paramount importance. However, this is sometimes incompatible with the time necessary to establish the etiological diagnosis of CS, but rapidity is mandatory in the context of life-threatening, intense hypercortisolism.

Symptomatic treatment of Cushing's syndrome: the example of hypertension

Hypertension is a prevalent cardiovascular risk factor in CS, affecting up to 85% of adults and 74% of pediatric patients [9–11]. The pathophysiology of hypertension during chronic hypercortisolism is complex and multifactorial involving the activation of the mineralocorticoid receptor by cortisol excess, activation of the renin-angiotensin-aldosterone system, facilitation of the hypertensive effect of catecholamines and alteration of vasoregulatory systems [10]. During intense hypercortisolism, the capacity of the renal enzyme 11 β -hydroxysteroid dehydrogenase type 2 that converts cortisol to cortisone is overwhelmed, triggering enhanced cortisol binding to the mineralocorticoid receptor. This results in a state of apparent mineralocorticoid excess characterized by increased tubular sodium reabsorption associated with intravascular volume expansion; and increased urinary loss of potassium with hypokalemia.

As mentioned above normalization of cortisol production is the mainstay treatment of hypertension. However, antihypertensive treatment is mandatory during the diagnosis workup and while waiting for the effect of specific treatments. Algorithms, based on pathophysiological mechanisms, have been proposed for the treatment of hypertension in Cushing's syndrome [9]. Angiotensin II receptor blockers or angiotensin-converting enzyme inhibitors may be initiated as first-line treatments since the renin-angiotensin system is upregulated in Cushing's syndrome. Spironolactone alone or in combination with other agents is indicated in the presence of hypokalemia and should be administered by IV route at high dosage with potassium supplementation in the presence of profound hypokalemia associated with intense hypercortisolism [12]. When blood pressure remains uncontrolled with these medications, add-on calcium channel blockers followed by add-on alpha-blockers should be considered.

Control of hypercortisolism usually improves hypertension but blood pressure does not always normalize. Persistent hypertension has been reported in up to half previously hypertensive patients in remission [1,9,10]. This may also be the case in up to 20% of pediatric patients [11]. The natural

history of hypertension following cure of CS and the time-course of remission are not well known but common experience shows that there is an important variability among patients in how long it takes for symptoms to resolve. Some studies suggest that transient hypertension may persist for more than 8 months following cure of CS [13]. Consequently, antihypertensive therapy should be reevaluated with an attempt to reduce the number and/or dose of medications both in the early and mid-term post-operative periods. Importantly, a longer duration of hypertension before treatment seems to be associated with lack of remission, possibly because of vascular remodeling [1,9,10]. This observation provides a supplementary argument supporting an active treatment of hypertension before obtaining the control of hypercortisolism with specific treatments.

Specific treatment of Cushing's syndrome

In the vast majority of cases, CS is due to autonomously adrenocorticotrophic hormone (ACTH)- or cortisol-secreting tumor(s). Resection of these "primary" tumors is therefore considered in the first instance. Various secondary options are available when excision of the responsible tumor is not feasible and significant advances in the development of "anticortisolic drugs" have been made during the last decades (**Figure 1**). However, the treatment of CS remains notably complex and, in a recent survey, despite multiple treatments, biochemical control was still not achieved in up to 30% of patients in a large multicenter cohort [14]. Treatment of CS, therefore, requires a dedicated expert team headed by a dedicated endocrinologist.

This review will focus on the various therapeutic options in adults depending on the etiology of overt CS.

I- Treatment of Cushing's disease (CD)

CD is the most common cause of CS and is due to an inappropriate and autonomous secretion of ACTH by a pituitary corticotroph adenoma.

I-1) Surgery is the cornerstone of CD treatment

Surgical removal of the pituitary adenoma, by a transsphenoidal approach and performed by an expert surgeon, is the only therapeutic option that can offer definitive cure with a low rate of adverse effects and is the first-line treatment for CD. Since most pituitary adenomas are microadenomas, the ideal surgery is selective adenectomy that preserves normal pituitary function. In patients in whom no adenoma is identified peroperatively, several options are possible amongst which partial/subtotal hypophysectomy, *e.g.* removal of 2/3 of the lateral and posterior pituitary tissue, appears to be the best compromise between a high success rate and low rate of surgery-related hypopituitarism. In experienced hands, the immediate remission rate varies from 81 to 89% for microadenomas and is lower for macroadenomas (<67% in most series, [15]). A major point of debate is whether to perform surgery in patients in whom no pituitary adenoma is identified by magnetic resonance imagery (MRI). Several groups, including ours, favor surgery once the diagnosis of CD is definitively established using bilateral inferior petrosal sinus sampling [16,17]. Several authors have clearly demonstrated that the eye of the surgeon is far better than that of MRI and that the success of surgery does not differ according to the results of MRI [17]. Based on a subset of series that found a reduced rate of cure when MRI was negative, other groups have suggested alternative approaches such as control of hypercortisolism using pharmacological agents and a regular follow-up with pituitary MRI [3]. In our opinion, even if the rate of surgical success may be slightly reduced in patients with negative MRI, according to the literature surgery still offers a 70–90% success rate [17] and, importantly, all other therapeutic options remain possible in patients in whom surgery fails. Apart from transient post-operative hyponatremia, complications occur in less than 5% of cases. However, deep vein thrombosis and pulmonary thromboembolism are frequent after pituitary surgery for CD, and anticoagulation therapy with low-molecular-weight heparin during the postoperative period is recommended [3,18]. The occurrence of hypopituitarism is correlated with

the extent of surgery and, in a recent meta-analysis, the mean frequency of partial hypopituitarism was 6.6% and 20.2% patients who had undergone selective adenomectomy or partial hypophysectomy, respectively [19].

Following successful surgery, patients will experience transient corticotroph insufficiency lasting several weeks to months, due to the prolonged exposure of normal corticotrophs to glucocorticoid excess. Measurement of plasma cortisol in the early post-operative phase is therefore crucial and corticotrophic insufficiency is the most widely recognized early marker of remission of the disease, while a simple “normalization” of cortisol values is associated with a risk of recurrence [20,21]. In a very limited number of cases, corticotroph insufficiency may occur after several weeks so that careful re-assessment of endocrine status three months following surgery is mandatory. Importantly, corticotroph insufficiency may not occur in patients treated preoperatively with anticortisolic agents since prolonged normalization of cortisol levels will result in disinhibition of normal pituitary corticotrophs. The acute changes in cortisol levels following successful surgery are sometimes associated with a transient deterioration of the patient’s general condition including symptoms such as fatigue, myalgia, lack of energy, and symptoms of depression that are currently interpreted as a “withdrawal syndrome”. Elsewhere, and despite the occurrence of corticotroph insufficiency, 10 to 20% of patients may experience recurrence of the disease, sometimes more than 10 years after successful surgery [20]. Therefore, life-long follow-up is recommended for patients with CD.

I-2) Alternatives to surgery

Pituitary surgery is sometimes not feasible (such as in patients in very bad condition), not always successful or not always long-lasting. In this situation, second-line treatments include a second pituitary surgery, pituitary radiotherapy (XRT), “anticortisolic drugs” and bilateral adrenalectomy (BLA). Each of these modalities has pros and cons and that there is no “one size fits all” treatment. The choice of second line treatment varies according to multiple parameters including the severity of

hypercortisolism, tumoral status, medical history, concomitant medications, efficacy profile, patient's perspectives (wish for fertility), availability, and cost of treatments [3]. Indeed, a shared decision-making with the patient and an expert multidisciplinary team is recommended. In the specific situation of recurrence of CD following a period of remission, a second pituitary surgery may be performed based on the common observation that adenomas usually recur at the same location, a finding that suggests that microscopic residual adenomatous corticotrophs remained at the adenoma margin. However, the rate of success following a second surgery may be lower than initial surgery, while the prevalence of complications (mainly hypopituitarism) increases [22].

I-2-1) Radiation therapy (XRT)

XRT is mainly used as a second-line treatment. As its anti-secretory effects may take several months or years to occur, it is necessary to ensure firstly that a medical treatment with "anticortisol drugs" is efficient and well-tolerated before planning XRT. The main procedures are conventional fractionated radiation therapy (CRT) and stereotactic radiosurgery (SRS), including gamma knife radiosurgery. In recent years, SRS has become the modality of choice for small adenoma tumors located in the sellar and parasellar regions whereas, CRT remains indicated for patients with large sized tumors, extrasellar extension, or proximity to the optic nerves/chiasm, the latter being a contraindication for SRS.

In a recent meta-analysis of major series [23], the remission rate of CS after CRT was roughly similar to that achieved by SRS (mean, 67.5% vs 65.8%; range, 46%–86% vs 26.7%-100%, respectively), with a mean time to remission ranging from 7.5 to 40 months. Recurrence occurred in 8.2 and 8.4% of patients after CRT and SRS respectively. Tumor control was noted in 88 to 98% of patients. The great variability in the results of XRT can be explained by the use of debatable criteria for remission and by the limited cohort size. Using combined stringent criteria, including regression of the clinical symptoms, persistently normal urinary free cortisol (UFC), and normal morning plasma

cortisol concentrations after a low-dose dexamethasone test, Estrada *et al.* found a remission rate of 83%, six to 60 months after CRT [24]. In a recent multicenter study including 278 patients treated with gamma-knife radiosurgery, control of hypercortisolism, based on UFC normalization, was obtained in 80% of cases and a recurrence rate of 18% was observed over the long term [25].

Hypopituitarism is the most common side effect of XRT and is more frequent with CRT compared to SRS (38.4% *vs* 29.7%, [23]). Conversely, cranial neuropathy occurs almost exclusively with SRS (1.5% of patients [23]). With regard to vascular injury and neurocognitive impairment, long-term data are still lacking and studies aimed at differentiating the sequelae of long-term exposure to cortisol excess *versus* the adverse effects of XRT are clearly needed. No radiation-induced tumors were observed among SRS or CRT series on long-term follow-up [23].

To conclude, XRT is often indicated if the oncogenic characteristics of the corticotroph adenoma are an issue (growing macroadenomas, large-sized post-surgical remnants). Good indications for SRS are well-visualized small adenoma remnants. Due to the frequent occurrence of hypopituitarism, indications for XRT should be carefully considered in young women who are hoping to fall pregnant.

I-2-2) Medical treatment

Pharmacological treatment may be indicated mainly 1) in preparation for pituitary surgery, in patients with a poor clinical condition; 2) as first-line treatment in non-operable patients; 3) as adjuvant treatment in case of surgical failure or recurrence; and 4) while waiting for complete effectiveness of pituitary XRT to manifest.

Several considerations should be emphasized concerning “anticortisolic drugs”. Firstly, all available medications are contraindicated or not recommended in pregnant women. Secondly, no drug has 100% potency but all may induce adrenal insufficiency. This may be considered a

“desirable” effect but careful monitoring is necessary to prevent, or anticipate, acute adrenal failure. Thirdly, fluctuations in cortisol production is the rule in CS [26]. Consequently, and aside from true escape phenomenon, variations in the degree of control of hypercortisolism due to variable hormonogenesis may occur. As continuous biochemical monitoring is impossible, it is important to compare the results of biochemical markers with a detailed clinical examination. Fourthly, all drugs may be used in association to increase the potency of the anticortisolic effect and/or reduce the dosage of a given drug and limit its associated side effects. The most commonly used combination involves various steroidogenesis inhibitors [12,27] acting on different enzymes on the one hand (**Figure 2**), and pasireotide with cabergoline and ketoconazole [28] on the other hand. Lastly, two main treatment strategies can be employed: a “titration strategy” that adapts the dose of the drugs to a biochemical marker of hypercortisolism such as UFC or, more rarely, a “block and replace” strategy that associates relatively high-doses of “anticortisolic drugs” to block cortisol secretion associated with hydrocortisone supplementation. There are no comparative data indicating the superiority of one strategy over the other. Additionally, it should be kept in mind that normalization of UFC is not synonymous with restoration of the physiological secretion of cortisol, and a disruption of the circadian rhythm of cortisol often persists in patients with normalized UFC, as demonstrated by persistently elevated late-night salivary cortisol (LNSC, [29]). The deleterious impact of elevated midnight cortisol has previously been demonstrated [30] and recent studies suggest that symptoms of hypercortisolism, such as weight gain and hypertension, are better controlled in patients with both normalized UFC and midnight cortisol than in those with normalized UFC only (*submitted*). The long-term use of “anticortisolic drugs” alone in patients is therefore questionable and some expert teams consider that medical treatment should be a bridging treatment used before a therapeutic option that ensures definitive cessation of hypercortisolism such as XRT or BLA.

“Anticortisolic drugs” can be classified according to their therapeutic target (**Table 1**).

I-2-2-1) Pituitary-directed drugs

These drugs target cell receptors that may be expressed by corticotroph adenomatous cells. From a pathophysiological perspective, the inhibition of adenomatous ACTH secretion is ideal however, in practice, the effectiveness of pituitary-directed drugs remains moderate and the rate of control of hypercortisolism is lower than that obtained with steroidogenesis inhibitors. To date there are no predictive factors of their effectiveness so that a “trial an error” approach is needed. Pituitary-directed drugs may induce shrinkage of tumor remnants and are an option when there are concerns about the oncogenic characteristics of the pituitary tumor.

Somatostatin analogs

Pasireotide is a multireceptor-targeted somatostatin analog with a high binding affinity for the somatostatin receptor (SSTR)-5, that is expressed in approximately 30% of corticotroph adenomas [31]. Administered twice daily via the subcutaneous route, in a large double blind randomized trial involving 162 patients, pasireotide was able to reduce UFC within one month in a majority of these patients and achieve normalization of UFC after three months in 26% [32]. Normalization of UFC was achieved more frequently in patients with mild hypercortisolism. No escape from the drug was demonstrated during follow-up studies. In a second large trial with a long-acting release version of pasireotide administered monthly via intramuscular injection, approximately 40% of patients with hypercortisolism of moderate intensity showed normalization of UFC [33]. A significant shrinkage of the adenoma was observed in roughly half of the patients with evaluable tumors.

The main adverse effect of pasireotide is the occurrence of hyperglycemia in about 75% of patients which appears as soon as 15 days after the introduction of the drug. This side-effect is independent of the control of hypercortisolism and is secondary to the inhibition of insulin and incretins secretion. Careful monitoring of hyperglycemia is therefore mandatory and active first-line treatment using metformin and glucagon like peptide-1 agonists, or dipeptidyl peptidase-4 antagonists, may be warranted.

Dopamine agonist

Cabergoline is a dopamine agonist which targets the type 2 dopamine receptor (D2R) that is expressed in approximately 60% of corticotroph adenomas [34]. In a French retrospective survey, normalization of UFC was observed in 40% of 53 patients treated with cabergoline in monotherapy in the short-term, and in 28% of patients in the long-term [35]. The median dosage to control UFC was 2.5mg/week. This observation, together with reports that corticotroph insufficiency can occur during cabergoline treatment, suggests that some corticotroph adenomas may be exquisitely sensitive to the drug. The delay of action of cabergoline has not been specifically studied but, in a short-term prospective study including 20 patients [36], cabergoline failed to control hypercortisolism, a finding that suggest that the cortisol-lowering effect of cabergoline may be a slow process. In some cases of corticotroph macroadenomas an antitumor effect has been noted. The benefits of cabergoline include its low cost, its oral route of administration and its good tolerance.

I-2-2-2) Adrenal-directed drugs

Ketoconazole

Ketoconazole, inhibits the enzymes CYP17A1, CYP11A1, and CYP11B1. It is used orally with two administrations per day giving daily doses ranging from 400mg to 1200mg. For optimal absorption, the presence of gastric acidity is necessary. Concomitant use of proton pump inhibitors may therefore reduce its effectiveness. Small size studies suggest that the nadir of cortisol is obtained after 2-3 days of treatment [37].

The largest study using ketoconazole in the treatment of CD is a retrospective French survey involving 200 patients [38]. Normalization of UFC was obtained in 49% of patients with an average dose of ketoconazole of 600mg/day. This low dosage suggests that under-titration was frequent and that the efficacy of ketoconazole may have been underestimated. Escape from treatment is rare and

occurs in less than 20% of cases. The main side effect is major cytolytic hepatitis, that is unrelated to the drug dosage, which occurs in only 2.5% to 5.5% of patients [38], usually during the first two months of treatment, and is reversible with decreased dosage or withdrawal of the drug. Other common adverse effects are gastrointestinal intolerance, male hypogonadism and gynecomastia, secondary to the inhibition of testicular steroidogenesis that occurs at lower doses than those required to inhibit cortisol production. Its exact prevalence is unknown, but this adverse effect suggests the drug should be preferentially used in women. Importantly, ketoconazole is a potent inhibitor of CYP3A4 and thus may increase the availability of drugs metabolized through this enzyme. A detailed analysis of the patient's drug profile is mandatory before engaging treatment with ketoconazole as well as close monitoring and dose adjustments of associated drugs.

Metyrapone

Metyrapone is an inhibitor of the CYP11B1, CYP11B2, and CYP17A1A enzymes, notable for its rapid onset of action since the nadir of cortisol levels following a single dose are obtained in approximately two hours [39].

A large retrospective UK survey [40] reported normalization of either UFC or average of multiple daily plasma cortisol measurements, in approximately 50% of patients. The average dose of metyrapone in this study was only 1350mg/day, indicating a probable insufficient dose titration and an underestimation of treatment efficacy. Nausea and abdominal discomfort are the most frequent side effects of the drug. Metyrapone causes the accumulation of steroids that are upstream to the blockade, such as aldosterone precursors, and this can lead to edema, hypokalemia and hypertension at high dosages of the drug, as well as accumulation of androgens responsible for hirsutism and acne. The dramatic increase in the immediate cortisol precursor 11-deoxycortisol, which is structurally similar to cortisol, interferes with many commercial cortisol immunoassays leading to an overestimation of cortisol levels. It is therefore important to monitor the cortisol response using more specific laboratory methods, such as mass spectrometry.

Mitotane

Mitotane is an adrenolytic drug that inhibits multiple steroidogenic enzymes, including 11 β -hydroxylase, and inhibits P450 side-chain cleavage [41]. In addition, Mitotane has a direct toxic effect on adrenocortical mitochondria and induces cellular necrosis that can lead to a “chemical adrenalectomy”. Mitotane has a long half-life due to its accumulation in adipose tissue, but adrenal insufficiency may be reversible after several months or years of cessation of treatment. Since Mitotane is a potent enzyme inducer (CYP3A4), the required doses of hydrocortisone supplementation should be increased by approximately one third in some patients.

A lower dosage of Mitotane is required in the treatment of CD as compared to treatment of adrenocortical carcinoma (ACC). However, the anticortisolic effect of Mitotane is delayed to a median of six months and, consequently, it is unsuited to situations requiring rapid control of cortisol hypersecretion [42]. In a single center retrospective study, control of CD was achieved in 72% of patients with a mean dose of Mitotane of 2.6g/day [42].

Mitotane leads to an increase in cortisol-binding-protein levels and therefore an increase in plasma cortisol concentrations. Cortisol monitoring should thus be performed by measurement of UFC or LNSC.

The main limitation of Mitotane is the frequency of adverse effects including gastrointestinal disorders, asthenia, rashes, neurological disturbances, increased liver enzymes, hypercholesterolemia and isolated thyrotropic insufficiency. Although being better-tolerated than at the higher dosages used for the treatment of ACC, 30% of patients may discontinue treatment due to intolerance [42]. Lastly, Mitotane is a potent teratogen and is contraindicated during pregnancy.

I-2-2-2) Glucocorticoid receptor-directed drugs

Mifepristone (RU 486).

Mifepristone is a glucocorticoid receptor antagonist. The SEISMIC study evaluated the effect of mifepristone monotherapy in 50 patients, who were treated for at least 30 days, and found an improvement in glucose tolerance and hypertension in 60% and 38% of patients, respectively [43]. In the long-term safety extension study, a beneficial effect on weight-loss persisted for an additional two years in patients who remained on therapy [44].

Adverse effects of mifepristone include nausea and fatigue (possibly indicative of adrenal insufficiency), metrorragia, and endometrial thickening in 20% of patients that are secondary to its associated action on the progesterone receptor. Importantly, by blocking the glucocorticoid receptor, mifepristone raises the secretion of ACTH and consequently increases cortisol concentrations. This increased cortisol may exceed the capacity of the renal 11-HSD enzyme to inactivate cortisol leading to a state of apparent mineralocorticoid excess, including hypokalemia and arterial hypertension secondary to the activation of the mineralocorticoid receptor by circulating cortisol and is seen in one third of patients. Additionally, cases of growth of the remnant corticotroph adenoma have also been described in CD.

One complication of treatment with mifepristone is due to the persistence of increased plasma/urinary cortisol and plasma ACTH concentrations, despite a reduced access to cortisol for target tissues. Consequently, the evaluation of efficacy is exclusively based on clinical symptoms and intermediate biochemical markers such as blood glucose while blood and urinary measurements of cortisol are useless.

1-2-3) Bilateral adrenalectomy (BLA)

BLA is currently performed using a laparoscopic approach that has reduced the mortality rate to close to zero in patients with CD, when they are operated in expert center [45]. The major advantage

of BLA is its unequalled ability to immediately control hypercortisolism. Furthermore, its efficacy is permanent in almost all patients. The major drawback of BLA is the requirement for a life-long glucocorticoid and mineralocorticoid supplementation and the risk of adrenal crisis that occurs at a similar rate to that observed in adrenal insufficiency resulting from other causes [45]. Patient education is therefore of primary importance after BLA. That said, major improvements in clinical symptoms and quality of life have been reported in the majority of patients although there has been no comparison with the results of pituitary surgery and XRT/pharmacological strategies [46]. The risk of Nelson's syndrome has been dramatically reduced with the availability of pituitary MRI. Indeed, the term "corticotroph tumor progression" is more appropriate, since the growth rate is usually slow and a manageable increase in size can be detected early by pituitary MRI follow-up. This may occur in 10 to 40% of patients [46]. Importantly, some studies suggest that corticotroph tumor progression may occur as early as one year after BLA and that the prevalence may "plateau" after seven years [47]. XRT may be used as curative treatment while preventive XRT after adrenalectomy is debatable, and has not yet been validated. Currently there is no firmly established predictive factor for corticotroph tumor progression, however, BLA should be considered cautiously in young patients and patients with aggressive pituitary tumors.

The place of BLA amongst second line therapies is open to debate. It is obligatory in young women after surgical failure and who wish to become pregnant, given the teratogenicity of available drugs. It is usually proposed if medical treatment or XRT are not well-tolerated or are ineffective. Otherwise, BLA is often considered as a last option, a strategy that may be harmful in some patients. Whether the improvement in long-term morbidity, quality of life and mortality is different than with other strategies, such as long-lasting medical treatment, remains an important open question given the imperfect nature of other treatments mentioned above [46].

II- Treatment of ectopic ACTH syndrome (EAS)

EAS is rare but is frequently a severe condition due to the intensity of hypercortisolism that is responsible for numerous life-threatening comorbidities in the short-term (severe hypertension, major hyperglycemia and hypokalemia, phlebitis and pulmonary thromboembolism, steroid psychosis and vulnerability to infections including opportunistic pathogens). Consequently, EAS should be considered as an endocrine emergency, requiring an emergency response both in terms of diagnostic procedures and therapeutic interventions. From a therapeutic perspective, both curative treatment and symptomatic treatments of co-morbidities are of primary importance in the short-term, including preventive anticoagulation and treatment with sulfamethoxazole-trimethoprim [3]. Etiological treatment consists of the surgical removal of the ectopic ACTH-secreting tumor. In the presence of intense hypercortisolism and severe CS, control of hypercortisolism prior to surgery may be a safe strategy. In this situation, rapid-acting steroidogenesis inhibitors such as ketoconazole and metyrapone are commonly used, alone or in association at high-doses. In a retrospective series of 14 patients with intense EAS, association of high-doses of metyrapone and ketoconazole induced a decrease in median UFC from 40 to three times the upper limit of normal (ULN) after one week of treatment, with 50% of patients having normal UFC values [12]. Etomidate, commonly used in anesthesia, efficiently inhibits 11- β hydroxylase and induces a dramatic reduction in cortisol levels within 48-72 hours [48]. Given intravenously, this drug can be particularly useful if the oral route is impossible, as may be the case in steroid psychosis, but it may necessitate hospitalisation in an intensive care unit. Excision of the ectopic tumor (EAT) may be impossible in patients with metastatic disease. In this situation, control of hypercortisolism may rely on “anticortisolic drugs” as mentioned above or on BLA. However, a recent meta-analysis has emphasized that BLA carries significant surgical mortality in patients with severe CS due to EAS, despite the advent of laparoscopic surgery [45]. Preparation for surgery with “anticortisolic drugs” may then be a safe strategy. Apart from non-specific chemotherapies for unresectable metastatic tumors, a number of medications have been used to control ACTH-secretion. Several reports acknowledge a dramatic inhibition of ACTH-secretion, enabling a sustained control of hypercortisolism, using tyrosine kinase inhibitor therapy in

EAS secondary to medullary thyroid cancer. This antisecretory effect was observed in the absence of an antitumoral effect [49]. The somatostatin analogs octreotide and lanreotide have shown short- and medium-term efficacy in small series and case reports but the control of hypercortisolism is often partial and transient [50]. In a recent series of severe EAS, the D2R agonist cabergoline induced long-term control of the hypercortisolism in three out of nine cases [51]. One specific situation is occult EAS, a situation in which the EAT becomes radiologically detectable and resectable after months or years of follow-up. In this situation, which is associated with an excellent prognosis assuming that hypercortisolism is efficiently controlled, BLA would be of concern since it will induce a definitive adrenal insufficiency. As an alternative, some authors have proposed controlling hypercortisolism in the short to midterm with steroidogenesis inhibitors and then combining this treatment with the long-lasting drug mitotane. After several months, mitotane could be used as monotherapy, inducing efficient control of hypercortisolism, while waiting for the EAT to be identified and removed [27].

III- Treatment of unilateral adrenal tumors

Cure of CS due to adrenal adenomas is usually straightforward in expert hands, using minimally invasive laparoscopic surgery performed by either anterior or postero-lateral route [52].

ACC may be responsible for CS (in 50-70% of cases), sometimes associated with hypersecretion of other steroids. Cortisol excess is a negative prognostic factor in ACC and is associated with worse overall survival [53]. Surgery with radical intent, when feasible, is the only treatment allowing potential cure of ACCs and its associated CS. For ACC patients with locally advanced or metastatic disease, combined anticortisolic agents are used with mitotane treatment as described previously [3]. Debulking surgery, significantly reducing tumor volume and cortisol secretory mass, may be indicated in patients with severe hypercortisolism or hypercortisolism that is poorly controlled with pharmacological treatments [54].

IV- Treatment of primary bilateral macronodular adrenal hyperplasia (PBMH)

In PBMH, hypercortisolism may be secondary to the aberrant stimulation of the adrenal cortex by ligands that activate abnormal receptors expressed by cortical cells that are coupled to the intracellular machinery of the ACTH receptor. Aberrantly expressed receptors include receptors for glucose-dependent-insulinotropic-peptide (GIP), luteinizing hormone (LH), vasopressin or β 2adrenergic receptors [55]. Pharmacological treatments inhibiting the secretion of aberrant ligands or blocking these abnormal receptors directly have been used in this instance (somatostatin analogs to reduce GIP secretion, betablockers for β 2adrenergic receptors...). However, this approach only produces control of hypercortisolism in a small number of patients and, in most cases, only transiently [55]. Thus, the standard treatment for HMBS has been BLA with its resulting drawback of definitive adrenal insufficiency.

Since the intrinsic steroidogenic capacity of adenomatous cells in PBMH is limited, reducing the secretory mass by unilateral adrenalectomy has been shown to be an effective treatment, inducing normalization of UFC in the majority of patients and transient corticotroph insufficiency in a significant number of these [56]. Careful follow-up should be planned to check for recurrence. Further studies are warranted comparing the long-term prognosis between patients operated by unilateral adrenalectomy with residual mild alteration in cortisol secretion and adrenal insufficient patients treated by BLA [57].

V- Primary Pigmented Nodular Adrenocortical Disease (PPNAD)

As a general rule, BLA is the recommended surgical approach for PPNAD treatment in the case of the involvement of both adrenal glands. However, unilateral adrenalectomy can be a successful therapeutic approach for selected patients with PPNAD with a mild phenotype [58].

VI-News drugs in CS and perspectives

IV-1) New drugs in CS

In recent years, new therapeutic options have started to surface, some of which are being currently evaluated in phase III studies:

Osilodrostat

Osilodrostat is a steroidogenesis inhibitor that is a more potent inhibitor of CYP11B2 and CYP11B1 than metyrapone or ketoconazole in human adrenocortical cells and has a prolonged half-life compared to metyrapone.

In a 22 week, open-label, prospective, phase II study (LINC-1) [29], osilodrostat, given orally to 19 patients with CD, was able to normalize UFC in 79% of patients. Adverse events were observed in 95% of patients but were mainly grade 1-2 nausea, diarrhea and asthenia. Evidently, increases in the production of steroids upstream of the pharmacological blockade, such as androgens, were observed resulting in hirsutism and/or acne. Adrenal insufficiency was also observed but should be considered as a desirable effect, reflecting the potency of the drug in the context of the treatment of CS.

The results of a relatively complex phase 3 study (LINC-3), involving a randomized arm with withdrawal of the drug after a titration period in more than 100 patients with CD, have been recently presented [59]. Fifty-three percent of patients had normalized UFC at the end of the 12 weeks titration period and, as expected, the number of patients with controlled UFC was significantly greater in patients who continued treatment compared to those who were switched to the placebo group (86 vs 29% respectively). The most common adverse effects reported in the osilodrostat group were nausea (11%), anemia (8%), arthralgia (8%) and headache (8%). Therefore, based on prospective and well-designed studies, olisodrostat seems to be a promising treatment for CS.

Levoketoconazole

While ketoconazole comprises a racemic mix of two enantiomers (an L-form and a D-form), levoketoconazole (COR-003) is a pure L-enantiomer that may be able to deliver effective cortisol blockade at hypothetically lower doses and with minimal rate of hepatic dysfunction.

Levoketoconazole have been investigated in a single-arm, open-label, multicenter phase III study [60] in 94 patients, mostly with CD. The response rate was 49% in the 39 patients whose initial UFC was between two and less than five time the ULN. A major increase in liver enzymes was reported in 3% of patients but was reversible, without clinical sequelae, when the treatment was stopped. These results are quite similar to those obtained with racemic ketoconazole. Future studies may provide more data on the benefits of this new drug and confirm its place in the therapeutic arsenal for CS.

Relacorilant

Relacorilant is a selective GR antagonist with no interaction with the progesterone receptor. In a phase II study, 130 patients with CD and T2D or hypertension were enrolled. Fifty percent achieved better glycemic control after 22 weeks of treatment. Sixty-four percent of patients with hypertension in the high-dose cohort exhibited reduced blood pressure associated with improvements in hypercoagulopathy, insulin resistance, and mood. No progesterone receptor-related adverse events or instances of drug-induced hypokalemia were observed (<https://pituitary.org/news/latest-news-and-articles/corcept-therapeutics-launches-website-supporting-phase-3-trial-of-relacorilant-in-patients-with-cushing-s-syndrome>). Relacorilant is now undergoing a phase III double-blind, placebo-controlled, randomized-withdrawal study to assess its safety and efficacy in CS ([NCT03697109](https://clinicaltrials.gov/ct2/show/study/NCT03697109)).

IV-2) Potential future pharmacological developments

The recent discovery of somatic mutations in the ubiquitin specific protease 8 (USP8) gene in almost half of the cases of corticotroph adenomas [61], has brought new insights on the importance of epidermal growth factor receptor (EGFR) and its downstream signaling pathways to the pathophysiology of CD. Inhibition of ACTH secretion, a reduction in tumor size and clinical improvement were observed in animal models that were treated with gefitinib, an EGFR tyrosine kinase inhibitor. This discovery has potential therapeutic implications and warrants further investigation.

Roscovitine is an orally bioavailable competitive inhibitor of cyclin-dependent kinases, enzymes involved in triggering cell cycle progression. Roscovitine was found to have a profound inhibitory action on pro-opio-melanocortin in zebrafish, murine and human corticotroph cells, and, *in vivo*, on ACTH levels in xenografted mice [62]. Roscovitine is currently in a phase II clinical trial in patients with CD (NCT03774446).

ACTH receptor-MC2R antagonists may reduce cortisol levels without the side-effects of steroidogenesis inhibitors. One particular compound, IRC-274, has been observed in an *in vivo* study, to reduce circulating corticosterone levels (<https://www.crinetics.com/wp-content/uploads/2019/03/ENDO2019-ACTH-FINAL.pdf>).

Finally, new combinations of existing drugs that may exert synergistic effects are also an interesting option in order to increase efficacy while lowering drug dosage and reducing side-effects. Based on these observations, chimeric molecules that bind to both SSTR and D2R with high affinity are currently under development [63].

Practice points:

- Despite the advent of numerous “anticortisolic drugs”, pituitary surgery remains the first line therapeutic option in Cushing’s disease.
- Comorbidities associated with Cushing’s syndrome can persist after biochemical remission of hypercortisolism, and their treatment is a key point in patient care.
- Long-term morbidity and mortality of patients with Cushing’s disease is associated with the duration of exposure to cortisol excess: prompt normalization of cortisol secretion is mandatory to reverse the morbidity and, possibly, reduce the mortality rate
- The management of Cushing’s syndrome requires a multidisciplinary and individualized approach taking into account the etiology of Cushing’s syndrome, the severity of hypercortisolism, the medical history, concomitant medications, patient perspectives and wishes (including plans for pregnancy).
- Intense hypercortisolism is a life-threatening condition and a therapeutic emergency.
- Due to a significant recurrence rate, lifelong monitoring is mandatory after remission of Cushing’s disease following pituitary surgery.
- Normalization of UFC using drug treatments is not synonymous with restoration of normal physiological function of the pituitary-adrenal axis. The criteria for pharmacological control of hypercortisolism need to be questioned.

Research agenda

- To identify the best follow-up strategy in order to diagnose early recurrence in patients in remission of Cushing's disease following pituitary surgery.
- Identify biochemical and tissue markers to quantify individual cortisol exposure and accurately monitor patients for titration of dosage of medical therapies.
- Evaluate the feasibility and efficacy of "block and replace" strategies with pharmacological treatment of Cushing's disease after failure of surgery
- Compare the respective long-term impact of pharmacological therapies versus bilateral adrenalectomy in patients with surgical failure/relapse of Cushing's disease.
- Evaluate new medical therapies that are in development.
- Define efficient therapeutic approaches to improve cognitive defects and quality of life in patients with a history of Cushing's syndrome.

REFERENCES

- [1] *Feelders RA, Pulgar SJ, Kempel A, Pereira AM. The burden of Cushing's disease: clinical and health-related quality of life aspects. *European Journal of Endocrinology* 2012; 167: 311–26.
- [2] Valassi E, Tabarin A, Brue T *et al.* High mortality within 90 days of diagnosis in patients with Cushing's syndrome: results from the ERCUSYN registry. *European Journal of Endocrinology* 2019; 181: 461–72.
- [3] *Nieman LK, Biller BMK, Findling JW *et al.* Treatment of Cushing's Syndrome: An Endocrine Society Clinical Practice Guideline. *The Journal of Clinical Endocrinology & Metabolism* 2015; 100: 2807–31.
- [4] Broersen LHA, Andela CD, Dekkers OM *et al.* Improvement but No Normalization of Quality of Life and Cognitive Functioning After Treatment of Cushing Syndrome. *The Journal of Clinical Endocrinology and Metabolism* 2019; 104: 5325–37.
- [5] Webb SM, Valassi E. Morbidity of Cushing's Syndrome and Impact of Treatment. *Endocrinology and Metabolism Clinics of North America* 2018; 47: 299–311.
- [6] Andela CD, van Haalen FM, Ragnarsson O *et al.* MECHANISMS IN ENDOCRINOLOGY: Cushing's syndrome causes irreversible effects on the human brain: a systematic review of structural and functional magnetic resonance imaging studies. *European Journal of Endocrinology* 2015; 173: R1-14.
- [7] *Clayton RN, Jones PW, Reulen RC *et al.* Mortality in patients with Cushing's disease more than 10 years after remission: a multicentre, multinational, retrospective cohort study. *Lancet Diabetes & Endocrinology* 2016; 4: 569–76.
- [8] Lambert JK, Goldberg L, Fayngold S *et al.* Predictors of Mortality and Long-term Outcomes in Treated Cushing's Disease: A Study of 346 Patients. *The Journal of Clinical Endocrinology & Metabolism* 2013; 98: 1022–30.
- [9] Pivonello R, Isidori AM, De Martino MC *et al.* Complications of Cushing's syndrome: state of the art. *Lancet Diabetes Endocrinology* 2016; 4: 611–29.

- [10] Isidori AM, Graziadio C, Paragliola RM *et al.* The hypertension of Cushing's syndrome: controversies in the pathophysiology and focus on cardiovascular complications. *Journal of Hypertension* 2015; 33: 44–60.
- [11] Lodish MB, Sinaii N, Patronas N *et al.* Blood pressure in pediatric patients with Cushing syndrome. *The Journal of Clinical Endocrinology & Metabolism* 2009; 94: 2002–8.
- [12] ***Corcuff J-B, Young J, Masquefa-Giraud P *et al.* Rapid control of severe neoplastic hypercortisolism with metyrapone and ketoconazole. *European Journal of Endocrinology* 2015; 172: 473–81.**
- [13] Sippel RS, Elaraj DM, Kebebew E *et al.* Waiting for change: symptom resolution after adrenalectomy for Cushing's syndrome. *Surgery* 2008; 144: 1054–60.
- [14] Geer EB, Shafiq I, Gordon MB *et al.* BIOCHEMICAL CONTROL DURING LONG-TERM FOLLOW-UP OF 230 ADULT PATIENTS WITH CUSHING DISEASE: A MULTICENTER RETROSPECTIVE STUDY. *Endocrine Practice* 2017; 23: 962–70.
- [15] Broersen LHA, Biermasz NR, van Furth WR *et al.* Endoscopic vs. microscopic transsphenoidal surgery for Cushing's disease: a systematic review and meta-analysis. *Pituitary* 2018; 21: 524–34.
- [16] Salenave S, Gatta B, Pecheur S *et al.* Pituitary Magnetic Resonance Imaging Findings Do Not Influence Surgical Outcome in Adrenocorticotropin-Secreting Microadenomas. *The Journal of Clinical Endocrinology & Metabolism* 2004; 89: 3371–6.
- [17] ***Cristante J, Lefournier V, Sturm N *et al.* Why we should still treat by neurosurgery patients with Cushing's disease and a normal or inconclusive pituitary MRI. *The Journal of Clinical Endocrinology & Metabolism* 2019.**
- [18] Wagner J, Langlois F, Lim DST *et al.* Hypercoagulability and Risk of Venous Thromboembolic Events in Endogenous Cushing's Syndrome: A Systematic Meta-Analysis. *Frontiers in Endocrinology* 2018; 9: 805.

- [19] ***Pivonello R, De Leo M, Cozzolino A, Colao A. The Treatment of Cushing's Disease. *Endocrine Reviews* 2015; 36: 385–486.**
- [20] Patil CG, Prevedello DM, Lad SP *et al.* Late recurrences of Cushing's disease after initial successful transsphenoidal surgery. *The Journal of Clinical Endocrinology & Metabolism* 2008; 93: 358–62.
- [21] Ferriere A, Cordoc'h C, Tabarin A. Encyclopedia of Endocrine Diseases - Evaluation and follow-up of patients with Cushing's disease after pituitary surgery. vol. 1. second. academic Press-Elsevier; 2018.
- [22] Patil CG, Veeravagu A, Prevedello DM *et al.* Outcomes after repeat transsphenoidal surgery for recurrent Cushing's disease. *Neurosurgery* 2008; 63: 266–70; discussion 270-271.
- [23] Ironside N, Chen C-J, Lee C-C *et al.* Outcomes of Pituitary Radiation for Cushing's Disease. *Endocrinology and Metabolism Clinics of North America* 2018; 47: 349–65.
- [24] Estrada J, Boronat M, Mielgo M *et al.* The long-term outcome of pituitary irradiation after unsuccessful transsphenoidal surgery in Cushing's disease. *The New England Journal of Medicine* 1997; 336: 172–7.
- [25] ***Mehta GU, Ding D, Patibandla MR *et al.* Stereotactic Radiosurgery for Cushing Disease: Results of an International, Multicenter Study. *The Journal of Clinical Endocrinology & Metabolism* 2017; 102: 4284–91.**
- [26] Petersenn S, Newell-Price J, Findling JW *et al.* High variability in baseline urinary free cortisol values in patients with Cushing's disease. *Clinical Endocrinology* 2014; 80: 261–9.
- [27] Kamenický P, Droumaguet C, Salenave S *et al.* Mitotane, Metyrapone, and Ketoconazole Combination Therapy as an Alternative to Rescue Adrenalectomy for Severe ACTH-Dependent Cushing's Syndrome. *The Journal of Clinical Endocrinology & Metabolism* 2011; 96: 2796–804.
- [28] Feelders RA, de Bruin C, Pereira AM *et al.* Pasireotide Alone or with Cabergoline and Ketoconazole in Cushing's Disease. *The New England Journal of Medicine* 2010; 362: 1846–8.

- [29] Fleseriu M, Pivonello R, Young J *et al.* Osilodrostat, a potent oral 11 β -hydroxylase inhibitor: 22-week, prospective, Phase II study in Cushing's disease. *Pituitary* 2016; 19: 138–48.
- [30] Terzolo M, Bovio S, Pia A *et al.* Midnight serum cortisol as a marker of increased cardiovascular risk in patients with a clinically inapparent adrenal adenoma. *European Journal of Endocrinology* 2005; 153: 307–15.
- [31] Hofland LJ, van der Hoek J, Feelders R *et al.* The multi-ligand somatostatin analogue SOM230 inhibits ACTH secretion by cultured human corticotroph adenomas via somatostatin receptor type 5. *European Journal of Endocrinology* 2005; 152: 645–54.
- [32] Colao A, Petersenn S, Newell-Price J *et al.* A 12-month phase 3 study of pasireotide in Cushing's disease. *The New England Journal of Medicine* 2012; 366: 914–24.
- [33] ***Lacroix A, Gu F, Gallardo W *et al.* Efficacy and safety of once-monthly pasireotide in Cushing's disease: a 12 month clinical trial. *The Lancet Diabetes & Endocrinology* 2018; 6: 17–26.**
- [34] Pivonello R, Ferone D, de Herder WW *et al.* Dopamine Receptor Expression and Function in Corticotroph Pituitary Tumors. *The Journal of Clinical Endocrinology & Metabolism* 2004; 89: 2452–62.
- [35] ***Ferriere A, Cortet C, Chanson P *et al.* Cabergoline for Cushing's disease: a large retrospective multicenter study. *European Journal of Endocrinology* 2017; 176: 305–14.**
- [36] Burman P, Edén-Engström B, Ekman B *et al.* Limited value of cabergoline in Cushing's disease: a prospective study of a 6-week treatment in 20 patients. *European Journal of Endocrinology* 2016; 174: 17–24.
- [37] Mccance DR, Hadden DR, Kennedy L *et al.* CLINICAL EXPERIENCE WITH KETOCONAZOLE AS A THERAPY FOR PATIENTS WITH CUSHING'S SYNDROME. *Clinical Endocrinology* 1987; 27: 593–9.
- [38] ***Castinetti F, Guignat L, Giraud P *et al.* Ketoconazole in Cushing's Disease: Is It Worth a Try? *The Journal of Clinical Endocrinology & Metabolism* 2014; 99: 1623–30.**

- [39] Monaghan PJ, Owen LJ, Trainer PJ *et al.* Comparison of serum cortisol measurement by immunoassay and liquid chromatography-tandem mass spectrometry in patients receiving the 11 -hydroxylase inhibitor metyrapone. *Annals of Clinical Biochemistry* 2011; 48: 441–6.
- [40] ***Daniel E, Aylwin S, Mustafa O *et al.* Effectiveness of Metyrapone in Treating Cushing's Syndrome: A Retrospective Multicenter Study in 195 Patients. *The Journal of Clinical Endocrinology & Metabolism* 2015; 100: 4146–54.**
- [41] Hescot S, Seck A, Guerin M *et al.* Lipoprotein-Free Mitotane Exerts High Cytotoxic Activity in Adrenocortical Carcinoma. *The Journal of Clinical Endocrinology & Metabolism* 2015; 100: 2890–8.
- [42] Baudry C, Coste J, Bou Khalil R *et al.* Efficiency and tolerance of mitotane in Cushing's disease in 76 patients from a single center. *European Journal of Endocrinology* 2012; 167: 473–81.
- [43] Fleseriu M, Biller BMK, Findling JW *et al.* Mifepristone, a Glucocorticoid Receptor Antagonist, Produces Clinical and Metabolic Benefits in Patients with Cushing's Syndrome. *The Journal of Clinical Endocrinology & Metabolism* 2012; 97: 2039–49.
- [44] Fein HG, Vaughan TB, Kushner H *et al.* Sustained weight loss in patients treated with mifepristone for Cushing's syndrome: a follow-up analysis of the SEISMIC study and long-term extension. *BMC Endocrine Disorders* 2015; 15.
- [45] ***Ritzel K, Beuschlein F, Mickisch A *et al.* Clinical review: Outcome of bilateral adrenalectomy in Cushing's syndrome: a systematic review. *The Journal of Clinical Endocrinology & Metabolism* 2013; 98: 3939–48.**
- [46] Guerin C, Taieb D, Treglia G *et al.* Bilateral adrenalectomy in the 21st century: when to use it for hypercortisolism? *Endocrine-Related Cancer* 2016; 23: R131–42.
- [47] Assié G, Bahurel H, Coste J *et al.* Corticotroph Tumor Progression after Adrenalectomy in Cushing's Disease: A Reappraisal of Nelson's Syndrome. *The Journal of Clinical Endocrinology & Metabolism* 2007; 92: 172–9.

- [48] Preda VA, Sen J, Karavitaki N, Grossman AB. Etomidate in the management of hypercortisolaemia in Cushing's syndrome: a review. *European Journal of Endocrinology* 2012; 167: 137–43.
- [49] Baudry C, Paepegaey A-C, Groussin L. Reversal of Cushing's syndrome by vandetanib in medullary thyroid carcinoma. *The New England Journal of Medicine* 2013; 369: 584–6.
- [50] Ruzniewski P, Girard F, Benamouzig R *et al.* Long acting somatostatin treatment of paraneoplastic Cushing's syndrome in a case of Zollinger-Ellison syndrome. *Gut* 1988; 29: 838–42.
- [51] Ilie MD, Raverot V, Tronc F *et al.* Cabergoline in severe ectopic or occult Cushing's syndrome. *European Journal of Endocrinology* 2019; 181: K1–9.
- [52] Henry J-F, Defechereux T, Raffaelli M *et al.* Complications of Laparoscopic Adrenalectomy: Results of 169 Consecutive Procedures. *World Journal of Surgery* 2000; 24: 1342–6.
- [53] Berruti A, Fassnacht M, Haak H *et al.* Prognostic Role of Overt Hypercortisolism in Completely Operated Patients with Adrenocortical Cancer. *European Urology* 2014; 65: 832–8.
- [54] Gaujoux S, Mihai R, joint working group of ESES and ENSAT. European Society of Endocrine Surgeons (ESES) and European Network for the Study of Adrenal Tumours (ENSAT) recommendations for the surgical management of adrenocortical carcinoma. *British Journal of Surgery* 2017; 104: 358–76.
- [55] Ghorayeb NE, Bourdeau I, Lacroix A. Multiple aberrant hormone receptors in Cushing's syndrome. *European Journal of Endocrinology* 2015; 173: M45–60.
- [56] ***Debillon E, Velayoudom-Cephise F, Salenave S *et al.* Unilateral Adrenalectomy as a First-Line Treatment of Cushing's Syndrome in Patients With Primary Bilateral Macronodular Adrenal Hyperplasia. *The Journal of Clinical Endocrinology & Metabolism* 2015; 100: 4417–24.**

- [57] Osswald A, Quinkler M, Di Dalmazi G *et al.* Long-Term Outcome of Primary Bilateral Macronodular Adrenocortical Hyperplasia After Unilateral Adrenalectomy. *The Journal of Clinical Endocrinology & Metabolism* 2019; 104: 2985–93.
- [58] Kyrilli A, Lytrivi M, Bouquegneau MS *et al.* Unilateral Adrenalectomy Could Be a Valid Option for Primary Nodular Adrenal Disease: Evidence From Twins. *Journal of the Endocrine Society* 2019; 3: 129–34.
- [59] Biller BM, Newell-Price J, Fleseriu M *et al.* (LINC 3). OR16-2 Osilodrostat Treatment in Cushing’s Disease (CD): Results from a Phase III, Multicenter, Double-Blind, Randomized Withdrawal Study. *Journal of the Endocrine Society* 2019; 3.
- [60] Fleseriu M, Pivonello R, Elenkova A *et al.* Efficacy and safety of levoketoconazole in the treatment of endogenous Cushing’s syndrome (SONICS): a phase 3, multicentre, open-label, single-arm trial. *The Lancet Diabetes & Endocrinology* 2019.
- [61] Reincke M, Sbiera S, Hayakawa A *et al.* Mutations in the deubiquitinase gene USP8 cause Cushing’s disease. OR16-2 Osilodrostat Treatment in Cushing’s Disease (CD): Results from a Phase III, Multicenter, Double-Blind, Randomized Withdrawal Study *Nature Genetics* 2015; 47: 31–8.
- [62] Liu N-A, Jiang H, Ben-Shlomo A *et al.* Targeting zebrafish and murine pituitary corticotroph tumors with a cyclin-dependent kinase (CDK) inhibitor. *Proceedings of the National Academy of Sciences* 2011; 108: 8414–9.
- [63] Rocheville M. Receptors for Dopamine and Somatostatin: Formation of Hetero-Oligomers with Enhanced Functional Activity. *Science* 2000; 288: 154–7.

LEGENDS OF FIGURES AND TABLES

Table 1: Main characteristics of pharmacological treatments of Cushing's syndrome

Figure 1: Therapeutic targets in Cushing's disease

Figure 2: Site of action of steroidogenesis inhibitors

Pituitary-directed drugs

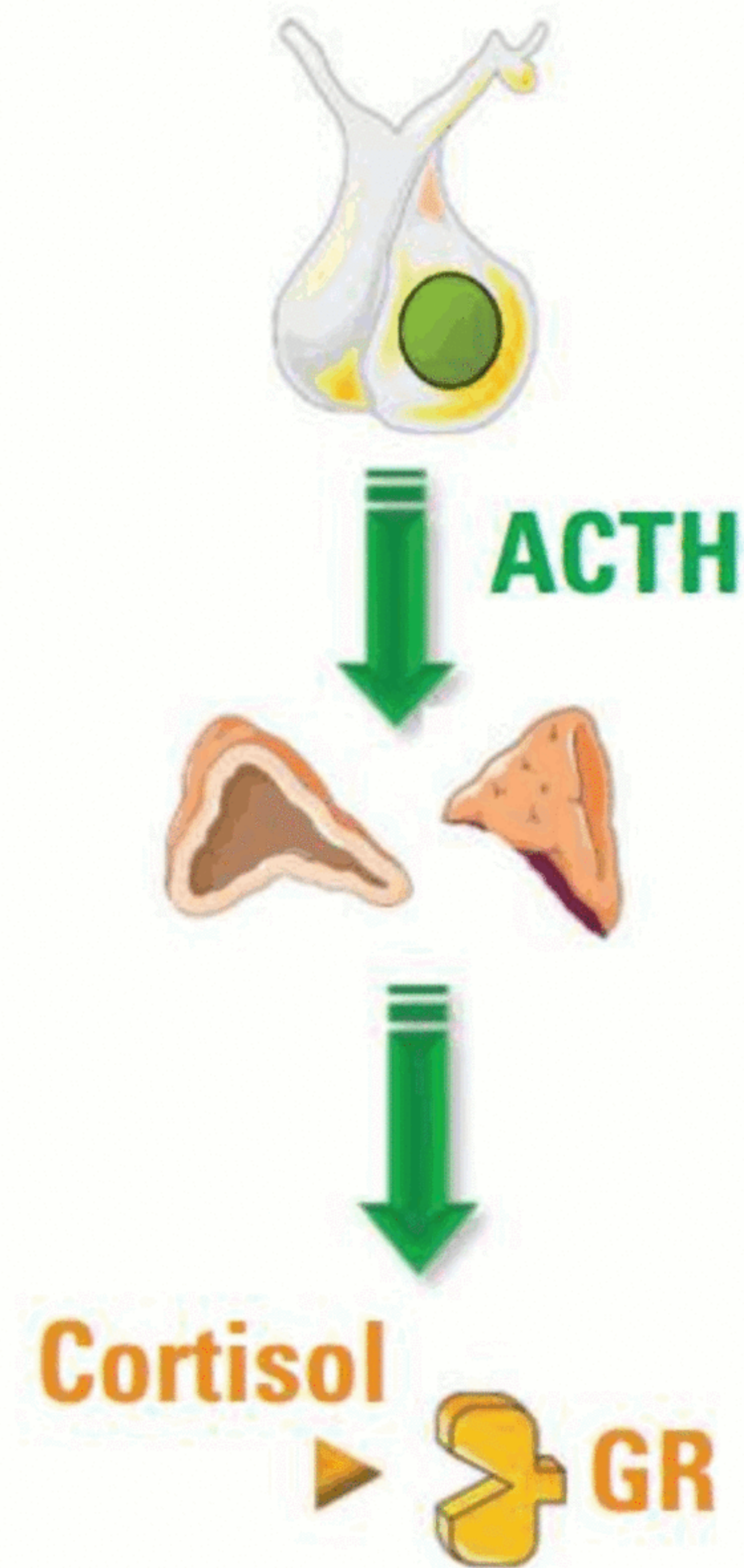
- Somatostatin analog: Pasireotide
- Dopamine agonist: Cabergoline

Adrenal-directed drugs

- Steroidogenesis inhibitors
(ketoconazole, metyrapone, etc...)
- Adrenolytic drug : Mitotane

Glucocorticoid receptor-directed drugs

- Mifepristone



Pituitary surgery

Pituitary radiotherapy

Bilateral adrenalectomy

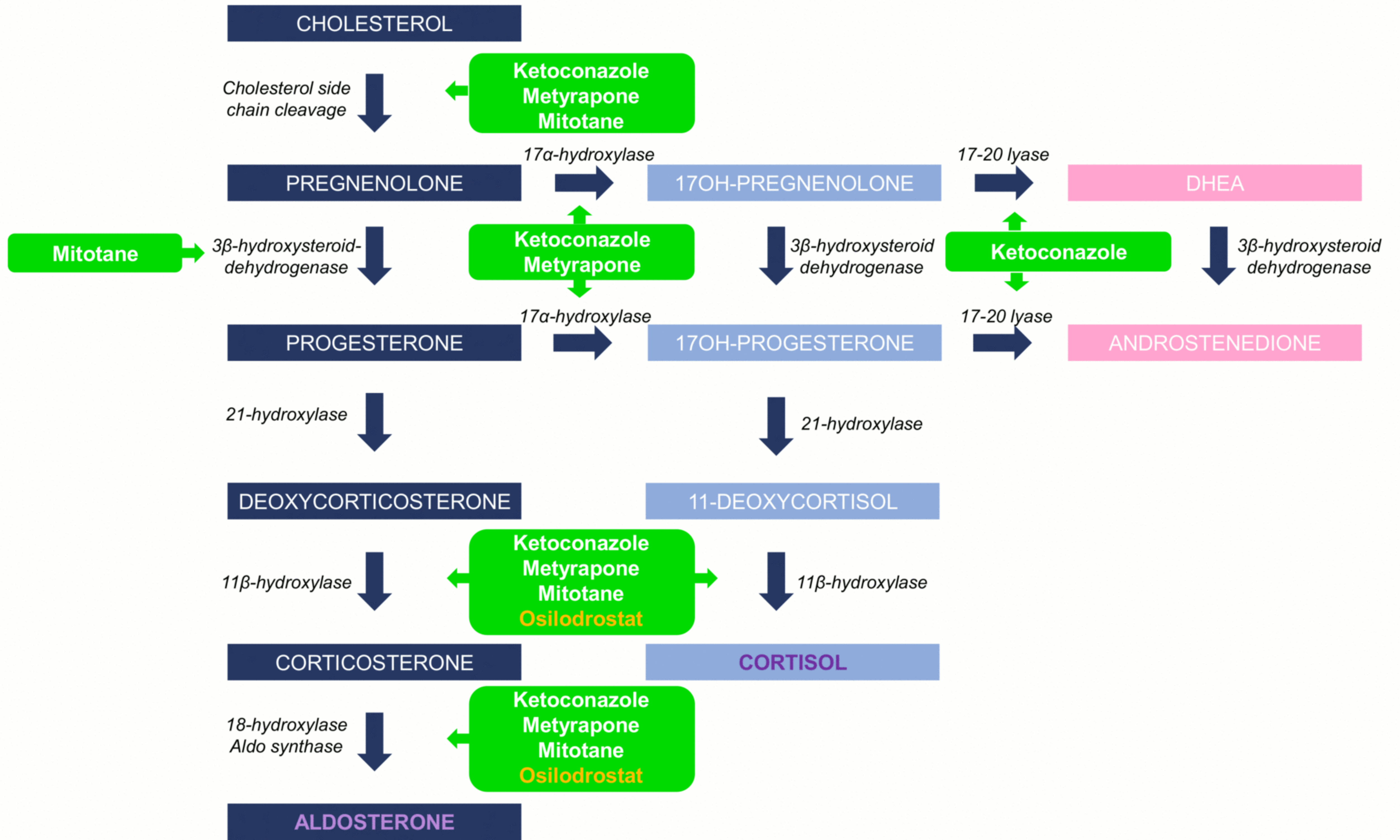


Table 1: Medical treatment of CS

Target	Drugs	Efficiency	Time of action	Main Adverse effects	Evidence/Comments
Pituitary-directed drugs	Pasireotide	26-40%	Within 1 month	Frequent hyperglycemia, diarrhea, gallstones	Evidence from double blind randomized studies Long-acting form (monthly injection) Works better in mild/moderate hypercortisolism Possible adenoma shrinkage
	Cabergoline	28-40%	≥ 1 month ?	Well tolerated (asthenia, nausea)	Retrospective studies and limited cohorts Low-cost treatment Possible adenoma shrinkage
Adrenal-directed drugs	Ketoconazole	> 50%	2-3 days	Cytolytic hepatitis (severe < 5%) , gastrointestinal disorders, hypogonadism and gynecomastia	Retrospective studies Numerous drug interactions Preferred in woman over metyrapone
	Metyrapone	> 50%	Few hours	Hirsutism, acne, hypokalemia and hypertension at high dosage	Retrospective studies Multiple pills in 3-4 daily intakes Issue in cortisol measurements for monitoring Preferred in men over ketoconazole
	Mitotane	75%	≥ 3 Months	Numerous : gastrointestinal disorders, asthenia, neurological disorders...	Retrospective studies with few patients Frequent withdrawal for intolerance Adrenal insufficiency
Glucocorticoid receptor-directed drug	Mifepristone	38-60%	Days	Nausea, asthenia, metrorragia, hypokaliemia	Open prospective study /limited endpoints Biochemical monitoring with cortisol impossible