



**HAL**  
open science

## Practice of stereoelectroencephalography (sEEG) in drug-resistant epilepsy: Retrospective series with surgery and thermocoagulation outcomes

J.-L. Méreaux, V. Gilard, F. Le Goff, N. Chastan, N. Magne, E. Gerardin, D. Maltête, A. Lebas, S. Derrey

### ► To cite this version:

J.-L. Méreaux, V. Gilard, F. Le Goff, N. Chastan, N. Magne, et al.. Practice of stereoelectroencephalography (sEEG) in drug-resistant epilepsy: Retrospective series with surgery and thermocoagulation outcomes. *Neurochirurgie*, 2020, 66, pp.139 - 143. 10.1016/j.neuchi.2019.12.014 . hal-03490238

HAL Id: hal-03490238

<https://hal.science/hal-03490238v1>

Submitted on 16 Jun 2022

**HAL** is a multi-disciplinary open access archive for the deposit and dissemination of scientific research documents, whether they are published or not. The documents may come from teaching and research institutions in France or abroad, or from public or private research centers.

L'archive ouverte pluridisciplinaire **HAL**, est destinée au dépôt et à la diffusion de documents scientifiques de niveau recherche, publiés ou non, émanant des établissements d'enseignement et de recherche français ou étrangers, des laboratoires publics ou privés.



Distributed under a Creative Commons Attribution - NonCommercial 4.0 International License

## Title page

Practice of stereoelectroencephalography (sEEG) in drug-resistant epilepsy: retrospective series with surgery and thermocoagulation outcomes

Authors: Jean-Loup Méreaux\*<sup>1</sup>, Vianney Gilard\*<sup>1</sup>, Floriane Le Goff<sup>2,3</sup>, Nathalie Chastan<sup>3</sup>, Nicolas Magne<sup>4</sup>, Emmanuel Gerardin<sup>4</sup>, David Maltête<sup>2</sup>, Axel Lebas<sup>3</sup>, Stéphane Derrey<sup>1</sup>

<sup>1</sup>Department of Neurosurgery, Rouen University Hospital, 76000 Rouen, Normandy, France

<sup>2</sup>Department of Neurology, Rouen University Hospital, 76000 Rouen, Normandy, France

<sup>3</sup>Department of Neurophysiology, Rouen University Hospital, 76000 Rouen, Normandy, France

<sup>4</sup>Department of Radiology, Rouen University Hospital, 76000 Rouen, Normandy, France

\*These authors contributed equally to the study

Corresponding author: Jean-Loup Méreaux – Department of Neurosurgery, Rouen University Hospital, France – 1 Rue de Germont, 76031 Rouen Cedex, France – Telephone +33 232 888 042 – Fax +33 232 888 426 – [jeanloup.mereaux@gmail.com](mailto:jeanloup.mereaux@gmail.com)

### **Highlights**

- sEEG helped to locate the epileptogenic zone in 92% of cases
- sEEG complications were rare (6%) but could be major, with one death due to hematoma
- Thermocoagulation reduced the frequency of seizures in 88% of cases
- Three months after surgical resection, 61% of patients were seizure-free

Méreaux

**Abbreviations:**

AED, anti-epileptic drugs;

EEG-HR, electroencephalography high resolution;

EZ, epileptogenic zone;

ILAE, International League Against Epilepsy;

MEG, magneto-encephalography;

MRI, magnetic resonance imaging;

sEEG, stereoelectroencephalography;

SUDEP, sudden unexpected death from epilepsy

**Abstract*****Objective***

The aim of this study was to determine the success rate of sEEG in locating the epileptogenic zone (EZ) in patients with pharmaco-resistant epilepsy. Secondary objectives were to analyze sEEG-related morbidity and outcomes for post-sEEG thermocoagulation and cortical resection.

***Methods***

Data were collected on 49 sEEGs from 46 consecutive patients between 2010 and 2018. Following sEEG, either resective or palliative surgery with vagus nerve stimulation was performed. In 8 patients, EZ thermocoagulation was performed before EEG leads were withdrawn. Outcomes were collected based on the Engel and ILAE outcome scales.

***Results***

sEEG was contributive in 45 of 49 recordings, with a success rate of 92% in locating the EZ. Minor complications, such as transient neurologic deficit and electrode implantation failures, occurred in 6%. One major complication occurred, with death due to atypical late hematoma. Thermocoagulation was performed in 8 patients and stopped or significantly reduced seizure frequency in 7 (88%). Outcome of surgical resection (n=33) was good, with 20 (61%) seizure-free patients and 32 (97%) with definite improvement.

***Conclusions***

Our findings suggest that sEEG is an effective technique for EZ location in patients with drug-resistant epilepsy. sEEG was contributive in up to 92% of patients, allowing thermocoagulation and/or surgical resection that resulted in seizure-freedom in two-thirds and seizure-reduction in one-third of cases. This study highlights the need for strict selection of implantation candidates, with strong initial hypothesis as to EZ location.

**Keywords:** epileptogenic zone; resective surgery; epilepsy surgery; thermocoagulation

## **Résumé**

### ***Objectifs***

Le but de ce travail était de déterminer le taux de succès de la sEEG pour localiser la zone épileptogène (ZE) chez des patients avec une épilepsie pharmaco-résistante. Les objectifs secondaires étaient d'analyser la morbidité de la sEEG et les résultats des thermocoagulations et des résections corticales post sEEG.

### ***Méthodes***

Les données de 49 sEEGs réalisés chez 46 patients consécutifs entre 2010 et 2018 ont été récupérées. Suite aux sEEGs, une chirurgie de résection ou une chirurgie palliative avec stimulation du nerf vague pouvaient être réalisées. Chez 8 patients, une thermocoagulation de la ZE a été effectuée avant le retrait des électrodes de sEEG. Les résultats étaient évalués par rapport aux échelles d'Engel et de l'ILAE.

### ***Résultats***

La sEEG a été contributive dans 45 des 49 enregistrements avec un taux de succès de 92 % pour localiser la ZE. Des complications mineures, comme des déficits neurologiques transitoires et des échecs d'implantation d'électrode, sont survenues dans 6 % des cas. Une complication majeure est survenue avec un décès dû à un hématome différé atypique. Des thermocoagulations ont été faites chez 8 patients avec un arrêt ou une réduction significative des crises chez 7 patients (88 %). Suite aux résections chirurgicales (n = 33), les résultats étaient bons avec 20 (61 %) patients libres de crises et 32 (97%) avec une amélioration notable.

### ***Conclusions***

Nos résultats suggèrent que la sEEG est une technique efficace pour localiser la ZE chez les patients atteints d'épilepsie pharmaco-résistante. La sEEG était contributive pour 92 % des patients permettant de proposer une thermocoagulation et/ou une chirurgie de résection de la ZE permettant une disparition des crises épileptiques chez presque deux tiers et une réduction de fréquence pour le tiers restant. Cette étude souligne la nécessité d'une sélection stricte des patients à implanter et d'une hypothèse initiale rigoureuse concernant la localisation de la ZE.

## ***1. Introduction***

Epilepsy is a severe neurological disorder with incidence of 50/100,000/year<sup>1</sup> and prevalence of 5-8/1,000 in Europe<sup>2,3</sup>. It is associated with increased morbidity and mortality, including sudden unexpected death from epilepsy (SUDEP)<sup>4</sup>. Despite the diversity of anti-epileptic (AE) drugs available, 10% to one-third of epilepsy cases are drug-resistant<sup>5,6</sup>, defined by the International League Against Epilepsy (ILAE) as “the failure of two tolerated, appropriately chosen and used antiepileptic drug schedules whether as monotherapies or in combination to achieve sustained seizure freedom”<sup>7</sup>. In this context, surgical resection of the epileptogenic zone (EZ) can be proposed<sup>8</sup>. Locating the EZ may require invasive techniques such as stereoelectroencephalography (sEEG) or sub-dural grids if non-invasive investigations fail. sEEG consists in stereotactic implantation of deep intracerebral electrodes based on a clinical, radiological and electrophysiological hypothesis of EZ location. The usual indications for sEEG are<sup>9,10</sup>:

- no visible anatomical lesion on radiological imaging;
- radio-electro-clinical discordance;
- lesion visible but clinical or electrical evidence suggesting that the EZ is larger than the lesion;
- large lesion partly extending in an eloquent cortical area, but with clinical and/or electrical evidence that partial excision could be effective;
- clinical or EEG suspicion of involvement of highly functional deep structures.

The objective of the procedure is to obtain an extremely accurate cartography of the EZ and neighboring functional structures and their relations with the EZ, and seizure escape routes. sEEG requires expertise, and has been performed since 2010 in our center. The primary objective of this study was to determine the success rate of sEEG in locating the EZ.



Secondary objectives were to analyze sEEG-related morbidity, and outcome of any thermocoagulation and/or surgical resection based on the Engel and ILAE outcome scales<sup>11,12</sup>.

## ***2. Material and Methods***

### ***2.1 Population and Indications***

Patients were referred to the neurosurgery department of our tertiary care center for intractable epilepsy. Prior to sEEG, each case was discussed in a national multidisciplinary consultation meeting. Information on the goals and risks of the sEEG procedure was given, with special focus on the possibility of intracranial hematoma. Informed consent was sought and obtained from patients or (for children) legal representatives. The study was approved by the local review board (n° E2019-35). During the study period (November 2010 – June 2018) 49 sEEGs were performed in 46 consecutive patients (mean age,  $25 \pm 12$  years; M/F sex ratio, 0.84), with 585 implanted electrodes. Fourteen (30%) patients were children under 16 years of age. Mean disease duration was  $14 \pm 7$  years, with mean onset age of  $14 \pm 11$  years. Seizure frequency was daily in 22 patients (48%), weekly in 22 (48%), and monthly in 2(4%). The sEEG aimed to explore the temporal lobe (31 of the 49 cases), or the frontal (14), occipital (9), insular (9) or rolandic (4) lobe. Exploration was unilateral in 33 cases and bilateral in 16, with a mean  $12 \pm 2$  electrodes. A lesion was found on MRI-scan in 20 patients (43%).

### ***2.2 Technique of sEEG electrode implantation***

Under general anesthesia after placement of a Leksell frame, 1.5T or 3T magnetic resonance imaging (MRI) was performed using 3D-T1-weighted gadolinium-enhanced sequences (Avento 1.5 Tesla, Siemens, Erlangen, Germany), stereotactic CT-scan and multislice CT angiography (MCTA) (Optima 660, GE Healthcare, Milwaukee, WI). MRI was acquired in

the axial plane with: 256x256 matrix, FOV 256x256 mm, and section thickness of 1 mm, for a spatial resolution of 1x1x1. MCTA was acquired in the axial plane with: 512x512 matrix, FOV 270x270 mm, section thickness of 0.625 mm, and 0.4 reconstruction interval. The injection rate was 3.5 mL/s of 50 ml contrast agent pulsed by 50 mL saline. Bolus tracking by aortic arch enhancement was used as reference. Volumes of interest were displayed as both arterial and venous contrast opacification. At the end of the pipeline, the processed data were loaded in the stereotactic planning software (Framelink<sup>R</sup> 5.0, Stealth-Station<sup>R</sup>, Medtronic, MN). For each electrode, using MRI and MCTA data, a trajectory (orthogonal or double obliquity) was planned, avoiding sulci and cortical vessels. The rest of the procedure, with electrode implantation in the operating room, has been previously described<sup>13</sup>. Since December 2016, depth electrode implantation (n=10 patients) has been performed with robotic stereotactic system guidance (ROSA®; Medtech Zimmer Biomet); surgical procedure (Figure 1) remains unchanged by robotic assistance except that frameless imaging acquisition and surgical planning are performed several days before implantation.

### **3. Results**

#### **3.1 sEEG outcomes**

sEEG outcomes are summarized in Figure 2. After a mean recording time of  $7 \pm 3$  days (range, 3-13 days), sEEG helped to locate the EZ in 45 of 49 recordings: i.e., success rate of 92%. Multifocal EZs were found in 8 patients. One patient underwent two sEEGs, to better define the EZ before surgical resection, and another patient underwent a second sEEG after surgery for new onset of seizures. There was no difference between children (15 sEEGs, 31%) and adults (34 sEEGs, 69%) in terms of sEEG success.

There was 1 major complication, with death due to subdural and intra-parenchymal hematoma. We reported this unusual observation, with onset of delayed hematoma more than

1 week after lead implantation<sup>14</sup>. Two patients showed transient complications: confusion (n=1), and behavioral, visuospatial and language symptoms (n=1). During sEEG recording, electrode dysfunction occurred in 6/585 electrodes (1%), including 1 broken electrode surgically removed under local anesthesia at end of recording.

### ***3.2 Thermocoagulation and surgical resection***

sEEG recording enabled 8 thermocoagulations (16%)<sup>15,16</sup>, which were suggested by the neurophysiologist using the first sEEG results. Thermocoagulation was performed when i) the EZ was located in a functional area (language area, most often), ii) when the EZ was very large, and/or iii) to test the main hypothesis with the aim of predicting the result of the cortectomy. Thermocoagulation reduced seizure frequency in 7 patients (88%), with no seizures at 2 years' follow-up in 3 patients; 3 patients showed a 50% decrease, and 1 patient showed transient 50% reduction only for a few months, with seizure frequency finally unchanged.

There was no morbidity due to thermocoagulation. Thirty-three surgical resections were performed: 24 cortectomies, 3 lesionectomies and 6 associated cortectomies-lesionectomies. Three surgeries were pending at the time of writing, including 1 not performed due to absence of seizures after thermocoagulation. Postoperative complications comprised 2 (6%) transient diplopias, 1 (3%) permanent paresis of the lower limb with deep sensory disorder (cortectomy of the sensory and motor paracentral lobule) and 1 (3%) scar infection. Pathology results were normal in 18 cases (55%). Pathological diagnoses comprised: 4 dysembryoplastic neuroepithelial tumors (DNET), 3 post-traumatic lesions, 2 hippocampal scleroses, 1 cortical dystrophy, 1 tuberous sclerosis of Bourneville, 1 inflammatory lesion, 1 toxoplasmosis and 2 low-grade gliomas (grades I and II). The grade I astrocytoma was an unexpected anatomopathological result, as the patient's history and the radiological features were very

suggestive of a DNET. The grade II patient had previously undergone oncological surgery for low-grade glioma in the right cingulum; during follow-up, the patient showed drug-resistant epilepsy that became very disabling, although tumor size was unchanged; revision therefore consisted in epileptic surgery, with prior sEEG. At a mean follow-up of  $34 \pm 27$  [1-85] months, 25 patients were classified as Engel class I, including 20 (61%) who were seizure-free with Engel class IA or ILAE Outcome Scale 1. Outcomes were favorable (Engel class I to III; ILAE Outcome Scale 1 to 4) in 32 (97%) patients, with significant seizure reduction. One patient showing transient decrease in daily seizure frequency had no long-term benefit from surgery (Engel class IV; ILAE Outcome Scale 5 to 6); seizure recurrence was due to a contralateral rolandic EZ and was partially improved by vagus nerve stimulation. Anti-epileptic treatment was decreased in 20 (61%) patients, with no recurrence at more than 1 year's follow-up. Eight patients had less than 1 year's follow-up, either because their operation was too recent (n=5) or because they were lost to follow-up (n=3). Palliative surgery with vagus nerve stimulation was performed in 2 patients, 1 for surgery failure and 1 for multifocal epilepsy.

#### ***4. Discussion***

The present study reports a high success rate of sEEG in localizing the EZ (92%) in a consecutive series of 49 sEEG recordings in 46 patients. Surgery was possible in 36 (80%) of these patients. Our results are concordant with literature data. A meta-analysis published in 2018 reported that sEEG had a mean success rate of 92%<sup>17</sup>. Two prospective studies showed that EZ resection was achieved in 79.9-87% of cases<sup>18,19</sup>. Localizing an EZ depends on the cerebral lobes involved, the presence of a lesion visible on MRI and the accuracy of the hypothesis based on prior evaluation and clinical analysis of seizures<sup>9</sup>. The EZ is more

difficult to localize in frontal lobe epilepsy because of its large size, the complexity of neural networks involved in seizures with many escape neural pathways, the diversity of clinical ictal patterns and the poor contribution of ictal and interictal EEG correlates<sup>9,20</sup>.

We found a 6% rate of sEEG-related morbidity per procedure, with 1 (2%) major event (death)<sup>14</sup>. This result is similar to that reported in a series of 215 procedures<sup>21</sup> but higher than in a larger series of 525 procedures<sup>22</sup>. In our series, there was a very low complication rate per electrode (0.51%). A systematic review and meta-analysis published in 2016 reported a slightly higher rate (1.3%) of surgical complications per electrode related to sEEG insertion and monitoring<sup>23</sup>. The two main complications described in the literature are hemorrhage, at 1.81/1,000 implanted electrodes (1% per sEEG procedure) and infection (0.8% per sEEG procedure)<sup>23</sup>. Permanent neurologic deficit is reported as 0.6% of pooled prevalence<sup>23</sup>. It has been shown that sEEG was associated with lower mortality (0.2 vs 0.4%) and morbidity (4.8 vs 15.5%) than subdural grids<sup>24</sup>.

Despite its low rate, intracranial hemorrhage is the most feared complication, with risk of death (half of reported deaths). Following previously reported intracranial bleeding, CT angiography was added to our preoperative radiological work-up, to reduce risk of hemorrhage. Although arteriography is the gold standard<sup>13,25</sup>, CT angiography is an interesting complement to MRI for visualization of blood vessels, including those in the insular lobe, which is frequently targeted in sEEG and known for its dense vascularization<sup>9</sup>. Obviously, antiplatelets and anticoagulants may be stopped before surgery to prevent bleeding<sup>26</sup>. Valproic acid has a controversial effect on hemostasis<sup>27,28</sup> and there is no evidence for withdrawing this treatment before sEEG or epilepsy surgery<sup>29,30</sup>.

Before performing sEEG, a very comprehensive preoperative work-up, including video EEG, 3T-MRI and PET-scan, is systematically performed, while high-resolution EEG (EEG-HR)

and magneto-encephalography (MEG) are discussed on a case-by-case basis. Current perspectives include the development of MEG and EEG-HR and the use of 7T high-field MRI<sup>31</sup>, not performed in our center.

In the present series, thermocoagulation was performed in 8 patients between 2015 and 2018, with good seizure control in 7 (88%). However, interpretation of these results is limited by short follow-up and the small sample. In larger series<sup>32,33</sup>, 18% to 25% of patients were initially seizure-free. Others found significant seizure improvement in 28.1% to 48.7% of patients<sup>32,33</sup>. A 2018 meta-analysis of 296 patients from 6 retrospective studies showed a pooled seizure-free rate of 23% (95% CI, 8-50%) and a responder rate of 58% (95% CI, 36-77%), but with large heterogeneity<sup>34</sup>. Efficacy was greater in the occipital region, in periventricular nodular heterotopies, and in case of lesions versus normal MRI<sup>32,34,35</sup>.

Complications related to thermocoagulation are rare, with reported rates of 2.2-7.3%<sup>32,33</sup>. In a recent meta-analysis, the main complication was permanent neurologic deficit, in 2.5% of cases (95% CI 1.2-5.3%)<sup>34</sup>. However, neurologic deficit can be predicted from sEEG and electrical stimulation ahead of thermocoagulation<sup>34</sup>. A recent systematic review and meta-analysis found no hemorrhagic complications attributed to thermocoagulation<sup>34</sup>. Others reported use of thermocoagulation to predict the efficacy of epilepsy surgery, with positive predictive value of 93%<sup>36</sup>. These data suggest that stereo-electroencephalography-guided radiofrequency thermocoagulation could be an effective option in drug-resistant epilepsy, above all when surgery is risky or impossible.

Resective surgery is a validated treatment for drug-resistant epilepsy<sup>37,38</sup>. In our 8-year experience, 80% of contributive sEEGs to locate the EZ enabled resective surgery, representing 74% of all 49 sEEGs. Surgery provided a 61% rate of seizure-freedom and 97% rate of benefit on the Engel classification. In a 2015 literature review on resective epilepsy

surgery, between 34% and 74% (median, 62.5%) of patients were reported as being seizure-free<sup>39</sup>. According to a meta-analysis, 47% of all sEEG patients who underwent resective surgery remained seizure-free<sup>17</sup>. Outcomes were similar in children and in adults<sup>39</sup>. In the literature, efficacy depends on resection region, with better results in temporal lobes (66% seizure free) and poor results in frontal lobes (27%)<sup>40</sup>. Other factors for better outcome comprise presence of structural lesions, particularly hippocampal sclerosis and benign tumors, seizure without loss of consciousness, complete or extensive lesion resection, prolonged febrile seizures, and long-term postoperative seizure freedom<sup>39</sup>. Factors for negative outcome comprise preoperative generalized tonic-clonic seizures, infantile spasms or tonic seizures, and intracranial electroencephalographic monitoring. Gender, age and side of resection were not associated with seizure outcome<sup>39</sup>. Discontinuation of antiepileptic medication was reported in 25-28% of patients<sup>39</sup>. Surgical complications may occur (12%) but decrease with time, as shown in Tebo's literature review<sup>41</sup>. Perioperative mortality is low (0.1% to 0.5%)<sup>39</sup>, and higher in extratemporal surgery (1.2%)<sup>42</sup>. Medical complications, such as cerebrospinal fluid leakage, aseptic meningitis, infection, hemorrhage and hydrocephalus, have been reported<sup>39,42</sup>. Minor and major neurologic complications occur in 10.9% and 4.7% of patients, respectively. The most common complication is visual field defect, occurring mainly in temporal lobe resection and classified as minor in 12.9% and major in 2.1% of cases<sup>42</sup>. The majority of complications are minor or temporary.

The present study was limited by retrospective data collection, a relatively low number of patients with more than 1 year's follow-up after surgery, and the heterogeneous population including both children and adults. Nevertheless, it allowed us to analyze and report our 8 years' experience in sEEG and epilepsy surgery, with outcomes concordant with the data in the literature.

### ***5. Conclusions***

sEEG is an effective technique to localize the epileptogenic zone in patients with drug-resistant epilepsy when first-line non-invasive techniques have failed. sEEG helped to localize the epileptogenic zone in nearly all of our patients on the basis of a hypothesis based on the clinical-radio-electroencephalographic data of phase I assessment. sEEG enabled thermocoagulation and/or surgical resection in up to 92% of patients, resulting in seizure-freedom in two-thirds and seizure-reduction in one-third. This study highlights the need for strict patient selection and a rigorous initial hypothesis as to the epileptogenic zone, in order to optimize sEEG success rate.



**Acknowledgments**

The authors are grateful to Nikki Sabourin-Gibbs, Rouen University Hospital, for her help in editing the manuscript.

**Funding**

This research did not receive any specific grant from funding agencies in the public, commercial, or non-profit sectors.

**Disclosure of Conflicts of Interest**

We have no conflicts of interest.

**Ethical Publication Statement**

We confirm that we have read the Journal's position on issues involved in ethical publication and affirm that this report is consistent with those guidelines.

## References

1. Ngugi AK, Kariuki SM, Bottomley C, et al. Incidence of epilepsy: A systematic review and meta-analysis. *Neurology*. 2011; 77(10):1005–12.
2. Forsgren L, Beghi E, Oun A, et al. The epidemiology of epilepsy in Europe - a systematic review. *Eur J Neurol*. 2005; 12(4):245–53.
3. Fernández-Suárez E, Villa-Estébanez R, Garcia-Martinez A, et al. Prevalence, type of epilepsy and use of antiepileptic drugs in primary care. *Rev Neurol*. 2015; 60(12):535–42.
4. Tomson T, Nashef L, Ryvlin P. Sudden unexpected death in epilepsy: current knowledge and future directions. *Lancet Neurol*. 2008; 7(11):1021–31.
5. Jallon P. Epidemiology of drug-resistant epilepsies. *Rev Neurol (Paris)*. 2004; 160 Spec No 1:5S22–30.
6. Mann MW, Pons G. La pharmacorésistance des épilepsies partielles : épidémiologie, mécanismes, pharmacogénétique, perspectives thérapeutiques. *Neurochirurgie*. 2008; 54(3):259–64.
7. Kwan P, Arzimanoglou A, Berg AT, et al. Definition of drug resistant epilepsy: Consensus proposal by the ad hoc Task Force of the ILAE Commission on Therapeutic Strategies: Definition of Drug Resistant Epilepsy. *Epilepsia*. 2009; 51(6):1069–77.
8. Sheng J, Liu S, Qin H, et al. Drug-Resistant Epilepsy and Surgery. *Curr Neuropharmacol*. 2018; 16(1):17–28.
9. Iida K, Otsubo H. Stereoelectroencephalography: Indication and Efficacy. *Neurol Med Chir (Tokyo)*. 2017; 57(8):375–85.
10. Cossu M, Chabardès S, Hoffmann D, et al. Explorations préchirurgicales des épilepsies pharmacorésistantes par stéréo-électro-encéphalographie : principes, technique et complications. *Neurochirurgie*. 2008; 54(3):367–73.
11. Engel J Jr. Outcome with respect to epileptic seizures. In: *Surgical Treatment of the Epilepsies*. 2nd Edition. Raven Press; 1993. p. 615.
12. Commission on Neurosurgery of the International League Against Epilepsy (ILAE) 1997-2001: Wieser HG, Blume WT, et al. Proposal for a New Classification of Outcome with Respect to Epileptic Seizures Following Epilepsy Surgery. *Epilepsia*. 2008; 42(2):282–6.
13. Gilard V, Proust F, Gerardin E, et al. Usefulness of multidetector-row computerized tomographic angiography for the surgical planning in stereoelectroencephalography. *Diagn Interv Imaging*. 2016; 97(3):333–7.
14. Derrey S, Lebas A, Parain D, et al. Delayed intracranial hematoma following stereoelectroencephalography for intractable epilepsy: Case report. *J Neurosurg Pediatr*. 2012; 10(6):525–8.
15. Guenot M, Isnard J, Ryvlin P, et al. SEEG-guided RF Thermocoagulation of Epileptic Foci: Feasibility, Safety, and Preliminary Results. *Epilepsia*. 2004; 45(11):1368–74.
16. Guenot M, Isnard J. La thermocoagulation multiple de foyers épileptogènes guidée par la SEEG (thermo-SEEG). *Neurochirurgie*. 2008; 54(3):441–7.
17. Garcia-Lorenzo B, Del Pino-Sedeño T, Rocamora R, et al. Stereoelectroencephalography for Refractory Epileptic Patients Considered for Surgery: Systematic Review, Meta-Analysis, and Economic Evaluation. *Neurosurgery*. 2018; .
18. Serletis D, Bulacio J, Bingaman W, et al. The stereotactic approach for mapping epileptic networks: a prospective study of 200 patients: Clinical article. *J Neurosurg*. 2014; 121(5):1239–46.
19. Cardinale F, Rizzi M, Vignati E, et al. Stereoelectroencephalography: retrospective analysis of 742 procedures in a single centre. *Brain*. 2019; 142(9):2688–704.

20. Bartolomei F, Chauvel P. Seizure symptoms and cerebral localization : frontal and rolandic seizures. In: *Intractable Focal Epilepsy*. Saunders. London: Oxbury JM, Polkey CE, Duchowny M; 2000. p. 55–62.
21. Cossu M, Cardinale F, Castana L, et al. Stereoelectroencephalography in the Presurgical Evaluation of Focal Epilepsy: A Retrospective Analysis of 215 Procedures. *Neurosurgery*. 2005; 57(4):706–18.
22. Bourdillon P, Ryvlin P, Isnard J, et al. Stereotactic Electroencephalography Is a Safe Procedure, Including for Insular Implantations. *World Neurosurg*. 2017; 99:353–61.
23. Mullin JP, Shriver M, Alomar S, et al. Is SEEG safe? A systematic review and meta-analysis of stereo-electroencephalography-related complications. *Epilepsia*. 2016; 57(3):386–401.
24. Yan H, Katz JS, Anderson M, et al. Method of invasive monitoring in epilepsy surgery and seizure freedom and morbidity: A systematic review. *Epilepsia*. 2019; 60(9):1960–72.
25. Gilard V, Proust F, Lebas A, et al. Analyse prospective de l'apport de l'angioscanner cérébral pour la planification des trajectoires de stéréo-électro-encéphalographie. *Neurochirurgie*. 2013; 59(6):233.
26. DeWald TA, Washam JB, Becker RC. Anticoagulants. *Neurosurg Clin N Am*. 2018; 29(4):503–15.
27. Gidal B, Spencer N, Maly M, et al. Valproate-mediated disturbances of hemostasis: relationship to dose and plasma concentration. *Neurology*. 1994; 44(8):1418–22.
28. Zighetti ML, Fontana G, Lussana F, et al. Effects of chronic administration of valproic acid to epileptic patients on coagulation tests and primary hemostasis. *Epilepsia*. 2015; 56(5):e49–52.
29. Guénot M, Lebas A, Devaux B, et al. Surgical technique. *Neurophysiol Clin*. 2018; 48(1):39–46.
30. Ward MM, Barbaro NM, Laxer KD, et al. Preoperative valproate administration does not increase blood loss during temporal lobectomy. *Epilepsia*. 1996; 37(1):98–101.
31. Zijlmans M, Zweiphenning W, van Klink N. Changing concepts in presurgical assessment for epilepsy surgery. *Nat Rev Neurol*. 2019; 15(10):594–606.
32. Cossu M, Fuschillo D, Casaceli G, et al. Stereoelectroencephalography-guided radiofrequency thermocoagulation in the epileptogenic zone: a retrospective study on 89 cases. *J Neurosurg*. 2015; 123(6):1358–67.
33. Guénot M, Isnard J, Catenox H, et al. SEEG-guided RF-thermocoagulation of epileptic foci: A therapeutic alternative for drug-resistant non-operable partial epilepsies. In: Pickard JD, Akalan N, Benes V, et al., editors. *Advances and Technical Standards in Neurosurgery* [Internet]. Vienna: Springer Vienna; 2011 [cited 2018]. p. 61–78. Available from: [http://link.springer.com/10.1007/978-3-7091-0179-7\\_4](http://link.springer.com/10.1007/978-3-7091-0179-7_4)
34. Bourdillon P, Cucherat M, Isnard J, et al. Stereo-electroencephalography-guided radiofrequency thermocoagulation in patients with focal epilepsy: A systematic review and meta-analysis. *Epilepsia* [Internet]. 2018 [cited 2018]; . Available from: <http://doi.wiley.com/10.1111/epi.14584>
35. Bourdillon P, Devaux B, Job-Chapron A-S, et al. SEEG-guided radiofrequency thermocoagulation. *Neurophysiol Clin*. 2018; 48(1):59–64.
36. Bourdillon P, Isnard J, Catenox H, et al. Stereo electroencephalography-guided radiofrequency thermocoagulation (SEEG-guided RF-TC) in drug-resistant focal epilepsy: Results from a 10-year experience. *Epilepsia*. 2017; 58(1):85–93.
37. Wiebe S, Blume WT, Girvin JP, et al. A randomized, controlled trial of surgery for temporal-lobe epilepsy. *N Engl J Med*. 2001; 345(5):311–8.
38. Engel J, Wiebe S, French J, et al. Practice parameter: temporal lobe and localized neocortical resections for epilepsy: report of the Quality Standards Subcommittee of the

- American Academy of Neurology, in association with the American Epilepsy Society and the American Association of Neurological Surgeons. *Neurology*. 2003; 60(4):538–47.
39. Jobst BC, Cascino GD. Resective Epilepsy Surgery for Drug-Resistant Focal Epilepsy: A Review. *JAMA*. 2015; 313(3):285.
  40. Téllez-Zenteno JF, Dhar R, Wiebe S. Long-term seizure outcomes following epilepsy surgery: a systematic review and meta-analysis. *Brain*. 2005; 128(5):1188–98.
  41. Tebo CC, Evins AI, Christos PJ, et al. Evolution of cranial epilepsy surgery complication rates: a 32-year systematic review and meta-analysis: A review. *J Neurosurg*. 2014; 120(6):1415–27.
  42. Hader WJ, Tellez-Zenteno J, Metcalfe A, et al. Complications of epilepsy surgery-A systematic review of focal surgical resections and invasive EEG monitoring. *Epilepsia*. 2013; 54(5):840–7.

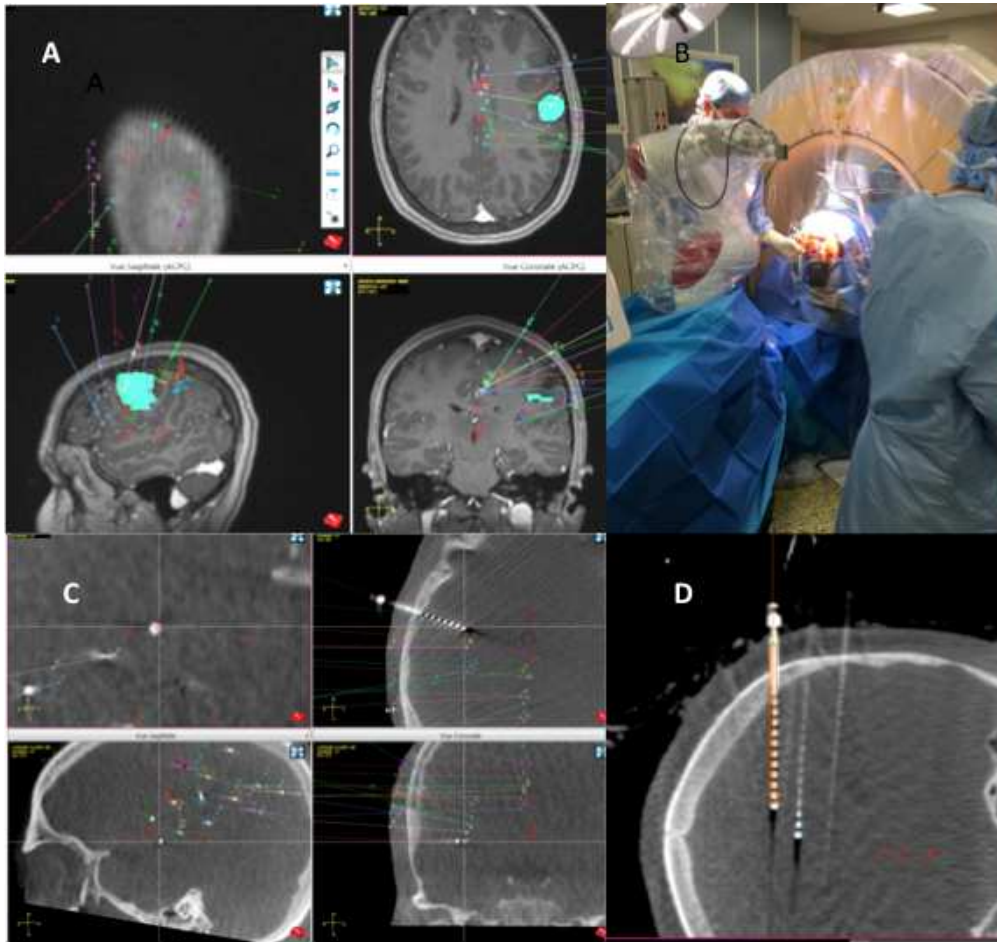
**Figures**

Figure 1: sEEG procedure. A, surgical planning for 10 intracranial electrodes around a left frontal lesion; B, surgery performed with robot-assistance technology (Rosa, Zimmer-Biomet) and 3D-intraoperative imaging system (O-arm, Medtronic); C, intraoperative localization lead control; D, view along the lead and comparison with planned trajectory (in orange).

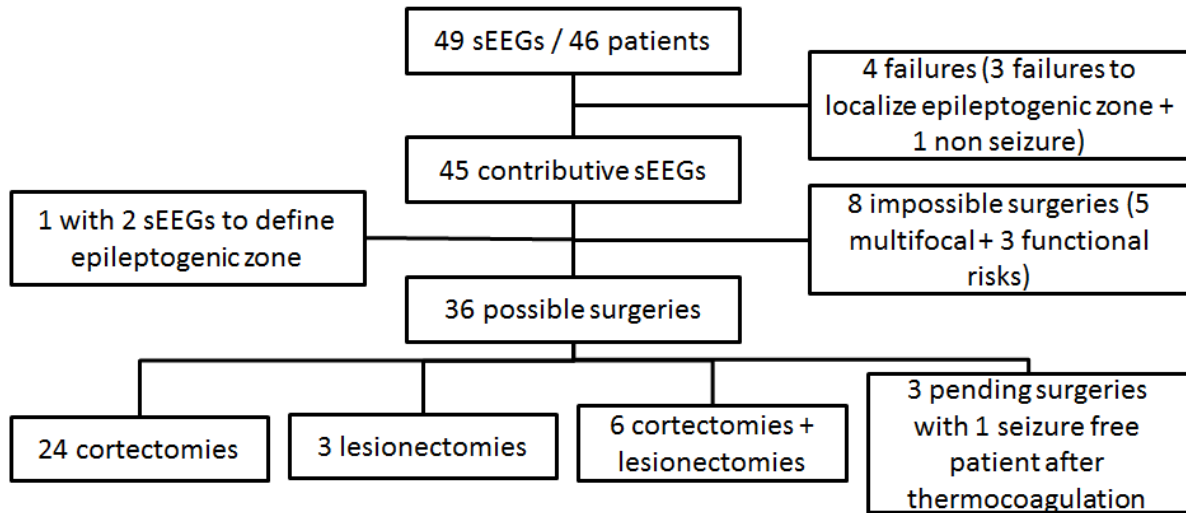


Figure 2: Flowchart of sEEG outcomes.