



HAL
open science

Long-term complications of minimally-open anterolateral interbody fusion for L5-S1

F. Abed Rabbo, Z. Wang, T. Sunna, N. Newman, F. Zairi, G. Boubez, D. Shedid

► **To cite this version:**

F. Abed Rabbo, Z. Wang, T. Sunna, N. Newman, F. Zairi, et al.. Long-term complications of minimally-open anterolateral interbody fusion for L5-S1. *Neurochirurgie*, 2020, 66, pp.85 - 90. 10.1016/j.neuchi.2019.12.010 . hal-03490237

HAL Id: hal-03490237

<https://hal.science/hal-03490237>

Submitted on 20 May 2022

HAL is a multi-disciplinary open access archive for the deposit and dissemination of scientific research documents, whether they are published or not. The documents may come from teaching and research institutions in France or abroad, or from public or private research centers.

L'archive ouverte pluridisciplinaire **HAL**, est destinée au dépôt et à la diffusion de documents scientifiques de niveau recherche, publiés ou non, émanant des établissements d'enseignement et de recherche français ou étrangers, des laboratoires publics ou privés.



Distributed under a Creative Commons Attribution - NonCommercial 4.0 International License

Long term complications of minimally-open anterolateral interbody fusion for L5-S1

ABED RABBO Francis (1), WANG Zhi MD (2), MD, SUNNA Tarek MD (4), NEWMAN Nicholas (2), ZAIRI Fahed MD (3), BOUBEZ Ghassan MD (2), SHEDID Daniel MD (5)

1. Service de Neurochirurgie. Centre Hospitalo-Universitaire (CHU) de Clermont Ferrand, France
2. Service d'Orthopédie, Centre Hospitalier de l'Université de Montréal (CHUM), Canada
3. Service de Neurochirurgie, Hôpital privé Le Bois, Lille, France
4. Division of Neurosurgery, American University of Beirut Medical Center, Lebanon
5. Service de Neurochirurgie. Centre Hospitalier de l'Université de Montréal (CHUM), Canada

Affiliations and adresses :

Service de Neurochirurgie, CHU de Clermont-Ferrand 58, Rue Montalembert, 63000 Clermont-Ferrand

Service d'Orthopédie. Centre Hospitalier de l'Université de Montréal (CHUM) 1000, rue St-Denis, Bureau E-368, 3^è étage, Montréal QC H2X 0C1 Canada

Service de Neurochirurgie, Ramsay Général de Santé, Hôpital privé Le Bois, 59000 Lille, France

Division of Neurosurgery, American University of Beirut Medical Center, P.O.Box: 11-0236
Riad El Solh Beirut 1107 2020, Beirut, Lebanon

Service de Neurochirurgie, Centre Hospitalier de l'Université de Montréal (CHUM)
1000, rue St-Denis, Bureau E-368, 3^è étage, Montréal QC H2X 0C1 Canada

Corresponding author:

Francis ABED RABBO

Email: francis.ar@gmail.com

Postal address: Service de Neurochirurgie,
CHU de Clermont-Ferrand 58, Rue Montalembert,
63000 Clermont-Ferrand - France

2
3 **Abstract:**

4
5 **Background:** Multiple surgical techniques and approaches exist to obtain lumbar interbody fusion. Antero-
6 lateral (Oblique) is a relatively recent technique. Controversy exists for its use at the L5-S1 level. We performed
7 this study in order to show the safety and efficacy of this technique. The aim of this study was to report the long-
8 term complications and fusion rates of minimally-open (mini-open) anterolateral interbody fusion at the L5-S1
9 level.

10 **Methods:** We retrospectively analyzed all patients who underwent mini-open anterolateral interbody fusion for
11 L5-S1 level in our department. The data collected were the following: age, sex, surgical indication, acute (less
12 than four weeks) and long-term complications (> 3 months), fusion at six months and length of follow-up.

13 **Results:** Seventeen patients (8M/9F) underwent mini-open anterolateral interbody fusion at L5-S1. The mean
14 age was 64.5 years. The surgical indication was scoliosis in 10 cases, flat back in 4 cases, and spondylolisthesis
15 in 3 cases. All patients underwent a complementary posterior procedure that included fixation. Mean blood loss
16 was 252.9 mL for the anterior procedure. Eight acute and minor complications occurred (anemia, delirium, and
17 psoas paresis). Two acute complications required surgical intervention (cage displacement and hematoma). Long
18 term complications were observed in 2 cases and included proximal junction kyphosis and non-union. The fusion
19 rate was evaluated at 88%. The mean follow-up period was 28.3 months.

20 **Conclusions:** Mini-open anterolateral interbody fusion at the L5 S1 level is safe and results in fusion at the same
21 rate as anterior interbody fusion. Most acute complications are minor and resolve spontaneously.

22
23 **Keywords:** L5-S1 level, spondylolisthesis, scoliosis, mini-open anterolateral interbody fusion, long-term
24 complications.

27 **Introduction**

28

29 The surgical treatment of scoliosis, degenerative disc disease and spondylolisthesis is based on lumbar fusion.
30 Lumbar interbody fusion (LIF) can be obtained via three approaches: Posterior, anterior and lateral. Posterior
31 approaches include posterior LIF (PLIF) and transforaminal LIF (TLIF). Most surgeons are familiar with these
32 posterior approaches. They allow instrumentation and fusion in one surgical stage [1–3].

33

34 Anterior approach (Anterior LIF or ALIF) is a retroperitoneal approach that allows the best possible
35 visualization of the intervertebral disc. Therefore, larger and more lordotic cages can be employed. However,
36 ALIF poses a risk of injury to the superior hypogastric plexus and to the great vessels (aorta, vena cava). Lesions
37 to the superior hypogastric plexus is another approach-related risk of ALIF that may cause retrograde ejaculation
38 in men and dyspareunia in women [4].

39

40 Lateral approaches include Direct LIF (DLIF) and anterolateral or Oblique LIF (OLIF). DLIF is a retroperitoneal
41 trans-psoas approach that poses a risk to the lumbar plexus [5]. OLIF is a retroperitoneal pre-psoas approach that
42 was previously described in 2012 [6]. OLIF allows access to the intervertebral disc through a window limited by
43 the psoas medially and the aorta and common iliac artery laterally [7]. At the L5-S1 level, the common iliac vein
44 and the ilio-lumbar vein must be protected. Silvestre *et al.* [6] advised against the OLIF L5-S1 approach due to
45 its high vascular risk and the obstruction caused by the iliac crest. Based on current literature, there are only a
46 few case studies describing OLIF L5-S1 used in lumbar degenerative pathology. We described, in a previous
47 article [8], a surgical corridor passing between the psoas and the great vessels for L5-S1. The ilio-lumbar vein
48 must be ligated before retracting the common iliac vein. In another study [8], we reported the preliminary results
49 and complications of our technique. The objective of this present study is to report the long-term complications
50 of L5-S1 OLIF.

51 **Materials and methods:**

52 A retrospective study of all adult patients (≥ 18 yrs) who underwent a mini-open anterolateral interbody fusion at
53 L5-S1 since 2013 was performed. Mini-open anterolateral interbody fusion L5-S1 was either done separately or
54 in association with other levels.

55

56 All patients gave their informed consent to undergo the procedure after a thorough explanation of the risks and
57 benefits of the surgery. Ethics Committee approval was obtained to perform the study. The approval code was
58 CER 19.102 – MJB.

59
60 The collected data were as follows: Demographics (age and sex), pathology leading to surgical indication, the
61 type of procedure, the association with posterior fixation, the operating time, American Society of
62 Anesthesiologist (ASA) score, blood loss, length of hospital stay, acute complications (<1 month) and long-term
63 complications (>6 months).

64
65 Radiological data collected were pelvic incidence, sacral slope, pelvic tilt, preoperative and post-operative L5-S1
66 lordosis, preoperative and postoperative lumbar lordosis and sagittal vertical axis as well as the fusion rates
67 according to the Lenke classification [9].

68

69 Surgical technique

70 The technique was thoroughly detailed in our previous article [8].

71

72 The patient is placed in the right lateral decubitus position with the left hip flexed (psoas relaxation). The
73 approach was performed using the synframe retractor (Synthes®). A skin incision of 4-5 cm long was made
74 anterior to the anterior superior iliac spine at the level of the lateral radioscopic projection of L5 S1. The muscles
75 of the abdominal wall are then identified. The muscle layers (external oblique, internal oblique and transverse
76 muscle) are opened by separating the muscles' fibers without cutting them. After dissecting and opening the
77 abdominal muscles, the peritoneum is exposed. It was dissected and shifted following the interior aspect of the
78 abdominal wall. Then the retroperitoneal space was reached. The psoas was found laterally and the iliac vessels
79 medially. It is important to gently dissect the fat at the L5-S1 level. This fat contains the ilio-lumbar vein that
80 arises from the superior aspect of the common iliac vein and receives the lateral lumbar venous collaterals from
81 the abdominal wall. There are important variations in the anatomy of the vein. [10] In some cases, the ilio-
82 lumbar vein receives direct collaterals from the vena cava. The ilio-lumbar vein must first be located and then
83 ligated. Once this vein is ligated and cut, the retraction of the iliac vein can be performed safely. An appropriate
84 working window is then developed between the psoas laterally and the iliac vessels medially. The ureter is
85 shifted anteriorly along with the peritoneum. The level is verified by fluoroscopy. The synframe retractor is then

86 installed. After proper discectomy, a cage of proper size is inserted under fluoroscopy (Cougar Synthes®) filled
87 with acellular cancellous bone that is previously soaked with the patient's blood. No bone morphogenetic
88 proteins (BMP) were used.

89
90 All patients underwent posterior instrumentation: percutaneous or open if a Smith Peterson osteotomy was
91 required to achieve the desired lumbar lordosis.

93 Statistical analysis

94 The statistical analysis was performed using Microsoft Excel ®.

96 **Results:**

97 General Clinical Data (Table 1)

98 Seventeen patients (8 males and 9 females) underwent mini-open anterolateral interbody fusion at L5-S1 in our
99 center. The mean population age was 64.5 yrs (45-77yrs). The patients suffered from scoliosis in 10 cases, flat
100 back in 4 cases, and spondylolisthesis in 3 cases. They presented central and foraminal stenosis that required
101 decompression that presented with neurological claudication. Moreover, some patients presented an unbalanced
102 spine that caused severe back pain and thus required correction. All these patients underwent a multiple level
103 OLIF. Two patients presented an isolated lytic spondylolisthesis that was treated by OLIF at L5 S1. All patients
104 underwent a posterior fixation by pedicle screws. The posterior fixation was performed during the same surgical
105 time in twelve patients.

106
107 Two radiological case-reports are presented in figure 1 and 2.

108
109 The mean length of hospital stay was 11 days (2-24 days). Six patients went to a rehabilitation center after
110 surgery. Long hospital stays were related to the delays of admission in rehabilitation centers (mean delay for
111 admission in these centers was 19 days).

112

113 Procedure data (Table 1)

114 The mean blood loss was 252.9 mL (100 to 650 mL). The mean overall operating time was 283.5 minutes (105-
115 480 minutes). The mean operating time per level was 102.2 minutes (52-300 minutes). The mean ASA score was
116 2.3 (1-3).

117

118 Complications (Table 1)

119 Acute complications

120 Ten patients presented acute complications of various origins. Only two patients presented OLIF-related
121 complications that required re-operation (cage displacement and infected hematoma). Minor OLIF-related
122 complications included psoas paresis (3 patients) and ileus (1 patient). No ureteral lacerations occurred in our
123 series. Other minor complications included anemia (2 patients), pain (1 patient), screw misplacement without
124 any neurological or visceral complications (1 patient), post-operative delirium (1 patient), and, pulmonary
125 atelectasis (1 patient).

126

127 Late complications

128 Two patients presented late complications. The first patient (patient n°3) presented a proximal junction kyphosis
129 associated with a non-union in L5-S1. The second patient (patient n°13) presented a non-union in L5-S1 with
130 screw loosening.

131 The mean follow-up period was 28.3 months (6-59 months)

132 The remaining 15 patients presented excellent evolution with regression of pain and improvement of their
133 walking distance and their ability to walk upright.

134

135 Radiological data

136 Fusion rates (Table 1)

137 The fusion rate was evaluated at 88% (grade A of Lenke Classification).

138 Angular data (Table 2)

139 OLIF was effective at restoring the lordosis at L5-S1 level. The mean lordotic Cobb angle gain was measured as
140 6° (1°-13°).

141

142 The surgery was successful in restoring lumbar lordosis in all patients thus improving the global sagittal balance.

143 The mean gain of lordosis was 15.9° (0°-49°).

144

145 **Discussion:**

146

147 OLIF is a relatively novel technique that allows anterior access to the lumbar spine using a surgical window
148 between the psoas laterally and the great vessels (aorta and vena cava, iliac vessels) medially [7]. Therefore, it
149 minimizes the risk of injury to the lumbar plexus and the great vessels. Since the patient is installed in a lateral
150 position, the peritoneal sac easily reclines due to gravity. OLIF provides excellent access to the intervertebral
151 disc with minimal risk. Moreover, in case of failed back surgery syndrome and inadequate foraminal
152 decompression, OLIF is an excellent choice that permits indirect decompression without revision of the
153 posterior site [11].

154

155 At L5-S1 level, OLIF can be challenging due 1.) to the prominence of the iliac crest and ilium, and, due 2.) to
156 the difficulty of shifting the iliac vessels [6]. Silvestre *et al.* [6] advised against OLIF L5-S1 in favor of either
157 anterior or posterior approaches. ALIF at L5-S1 may require less mobilization of the great vessels depending on
158 the anatomy of the bifurcation of the aorta and vena cava. In patients requiring multiple LIF (kyphoscoliosis,
159 scoliosis with coronal imbalance), OLIF L5-S1 is interesting since it allows fusion of the entire lumbar spine
160 through one incision and a single procedure. In order to circumvent the difficulties described by Silvestre *et al.*
161 [6], we developed a new technique that allows safe retraction of the iliac vessels. In order to safely retract the left
162 common iliac vein, the ilio-lumbar vein must be dissected and ligated. This vein is present in the retroperitoneal
163 fat on the lateral aspect of the L5-S1 disc [8]. Therefore, the surgical window in our technique remains the same
164 as for other levels: between the iliac vessels medially and the psoas laterally.

165

166 Most articles [12–15] that describe their experience with OLIF at L5-S1 level, use a surgical corridor medial to
167 the iliac vessels. Some authors [14] tilt the table so the patient becomes almost supine or dorsal decubitus. In our
168 opinion, these authors do not use a true OLIF surgical corridor but a modified ALIF corridor for L5-S1.

169 Consequently, comparing their results to ours should be interpreted with caution. We found only one study [4]
170 that employs the same surgical corridor or approach as ours.

171
172 Reported acute complications of OLIF are minor and rare [6, 16]. Silvestre *et al.* [6] reported the largest cohort
173 study of OLIF. The most common complication was incisional pain (2.2%), followed by sympathetic chain
174 injury (1.7%) [6]. There was no reported abdominal herniation or lesions to the superior hypogastric plexus.
175 Their study only included 6 patients with L5-S1 OLIF. The number of patients with OLIF at L5–S1 was small
176 due to the difficulty in retracting the iliac vein and iliolumbar vein. Chang *et al.* [17], reported a case with a
177 ventral dural tear due to trial cage misplacement that required a posterior approach to repair it. Chung *et al.* [4],
178 who employed a surgical corridor lateral to the iliac vessels, reported no acute complications after mini-open
179 anterolateral interbody fusion for L5-S1 for six patients.

180 In our series, we reported acute minor complications in 8 patients. Psoas paresis regressed completely within 3
181 months. Other minor complications (anemia, delirium and pain) regressed with adequate treatment within one
182 week.

183 Two patients had severe acute complications that required surgical intervention. Secondary cage displacement
184 caused a severe nerve root compression in one patient. An acute infected hematoma caused pyelonephritis due to
185 obstruction of the ureter in another patient. These two patients had a good late evolution.

186
187 Reported late complications are primarily related to sagittal imbalance that causes strain on the posterior
188 fixation and non-union of the arthrodesis. In our series, we reported two cases of non-union that required
189 surgical revision.

190 Our fusion rate was evaluated at 88% (grade A of Lenke classification [9]). This fusion rate was concordant
191 with the values reported in the literature (84-100%) [16]. Moreover, this fusion rate is similar to the fusion rates
192 without BMP of L5-S1 ALIF 93.1% (range, 77.2%–98.2%), but slightly lower than L5-S1 TLIF 99.3% (range,
193 96.7%–99.8%) [18]. This comparison of fusion rates should be interpreted with caution because of the small
194 number of cases in our series. It is important to emphasize that we achieved a high fusion rate using only bone
195 substitutes that were soaked in autologous blood. This technique was also employed by Silvestre *et al.* [6].

196 Reported mean follow-up of OLIF using a surgical corridor lateral to the iliac vessels is less than 18 months [4,
197 6]. Our mean follow-up period was 28,3 months (6-59 months). The follow-up period in our series remain the
198 longest published to date.

199

200 Reported blood loss for OLIF varied from 67.8 to 260 mL and duration from 55 to 145 minutes [16]. In our
201 series, blood loss is concordant with that reported in the literature. However, our operating time is above
202 published time. This may be explained by the important anatomical variation of the location of the ilio-lumbar
203 vein that increased the dissection time.

204

205 Hospital length of stay was reported at 7.1 ± 3.5 day by Silvestre *et al.* [6]. Our mean hospital length of stay was
206 11 days (2-24 days). This high hospital length of stay may be explained by performing posterior fixation in two
207 separate surgical time in twelve patients as well as by the delays of obtaining admission to a rehabilitation
208 center.

209

210 This study has a few limitations. Since it was a retrospective study, it was difficult to quantify the pain and
211 walking distance improvement with validated functional scores or pain scales. Moreover, the study was purely
212 descriptive since there was not any control group (patients who underwent PLIF/TLIF or ALIF).

213 However, this series consolidates the idea that OLIF remains a safe and effective way to treat lumbar pathologies
214 even for the L5-S1 level. Since the population of this study is small, further studies are required to fully ascertain
215 long term results and complication of mini-open anterolateral interbody fusion for L5-S1 level.

216

217 **Conclusion:**

218 This is the first study, to our knowledge, to report late results and complications of mini-open anterolateral
219 interbody fusion at L5-S1 using a lateral corridor to the iliac vessels. Also, it has the longest follow-up period yet
220 to be reported for this approach. Our study further proves the safety and efficacy of mini-open anterolateral
221 interbody fusion for L5-S1 level.

222

223 **Conflicts of interests:**

224

225 Dr. Francis Abed Rabbo, Dr. Tarek Sunna, Dr. Fahed Zairi, Dr. Zhi Wang, Dr. Nicholas Newman and Dr.
226 Ghassan Boubez declare that they have no conflicts of interest.

227

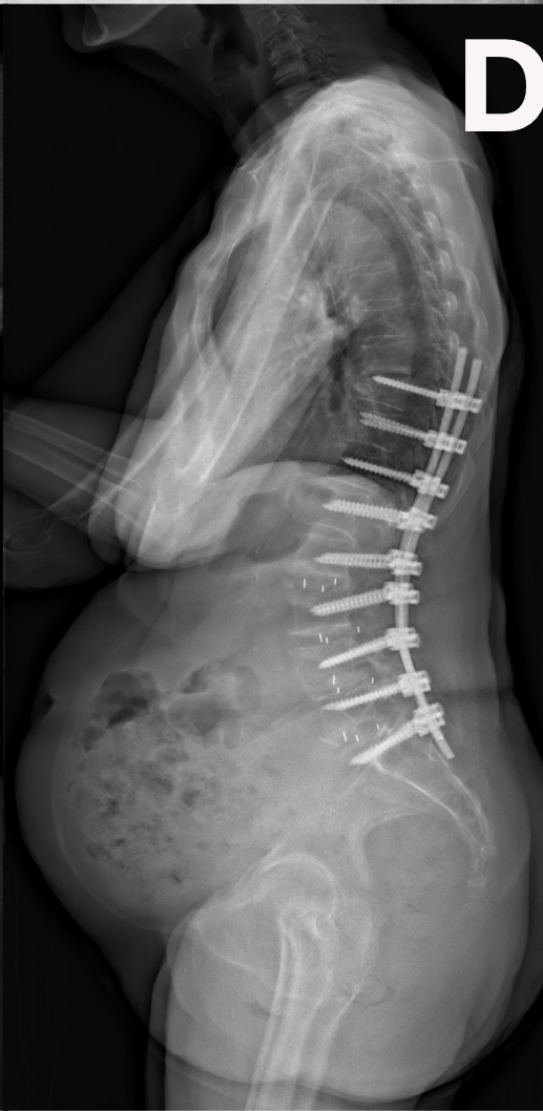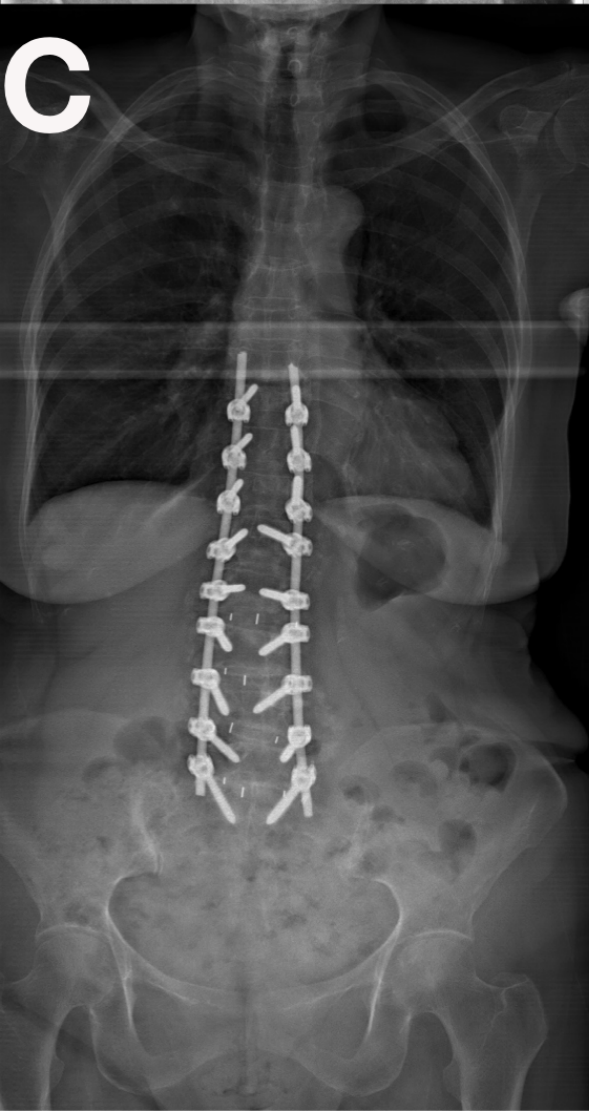
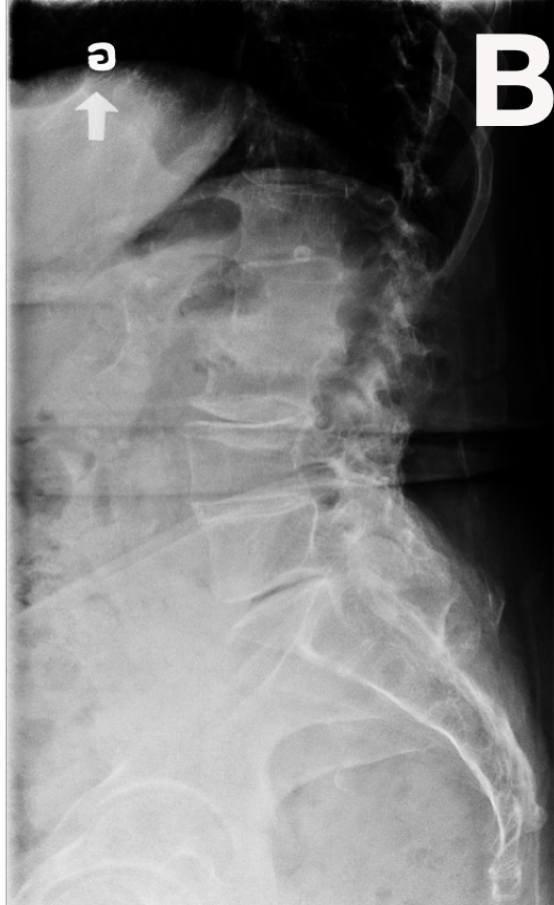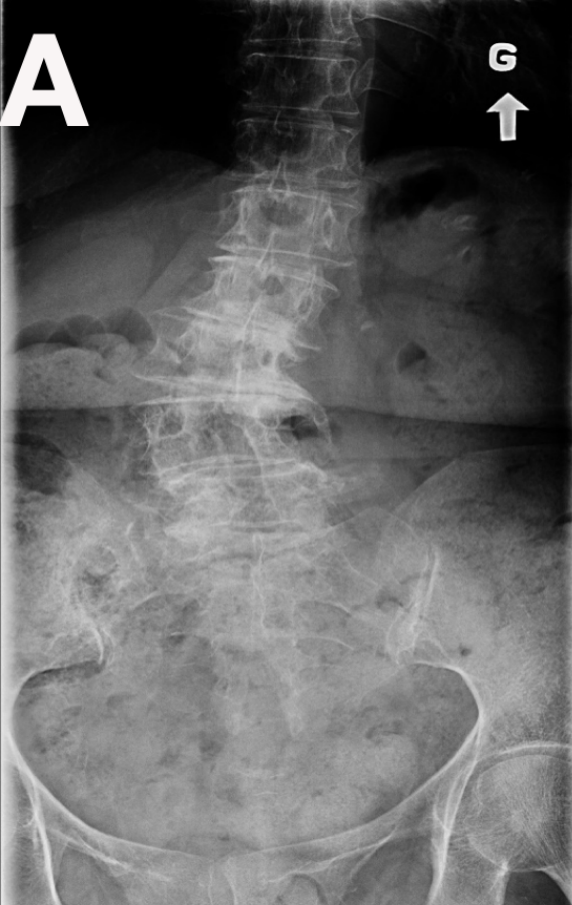228 Dr. Daniel Shedid is a consultant for Depuy Synthes, receives fellowship support from Medtronic and Depuy
229 Synthes.
230

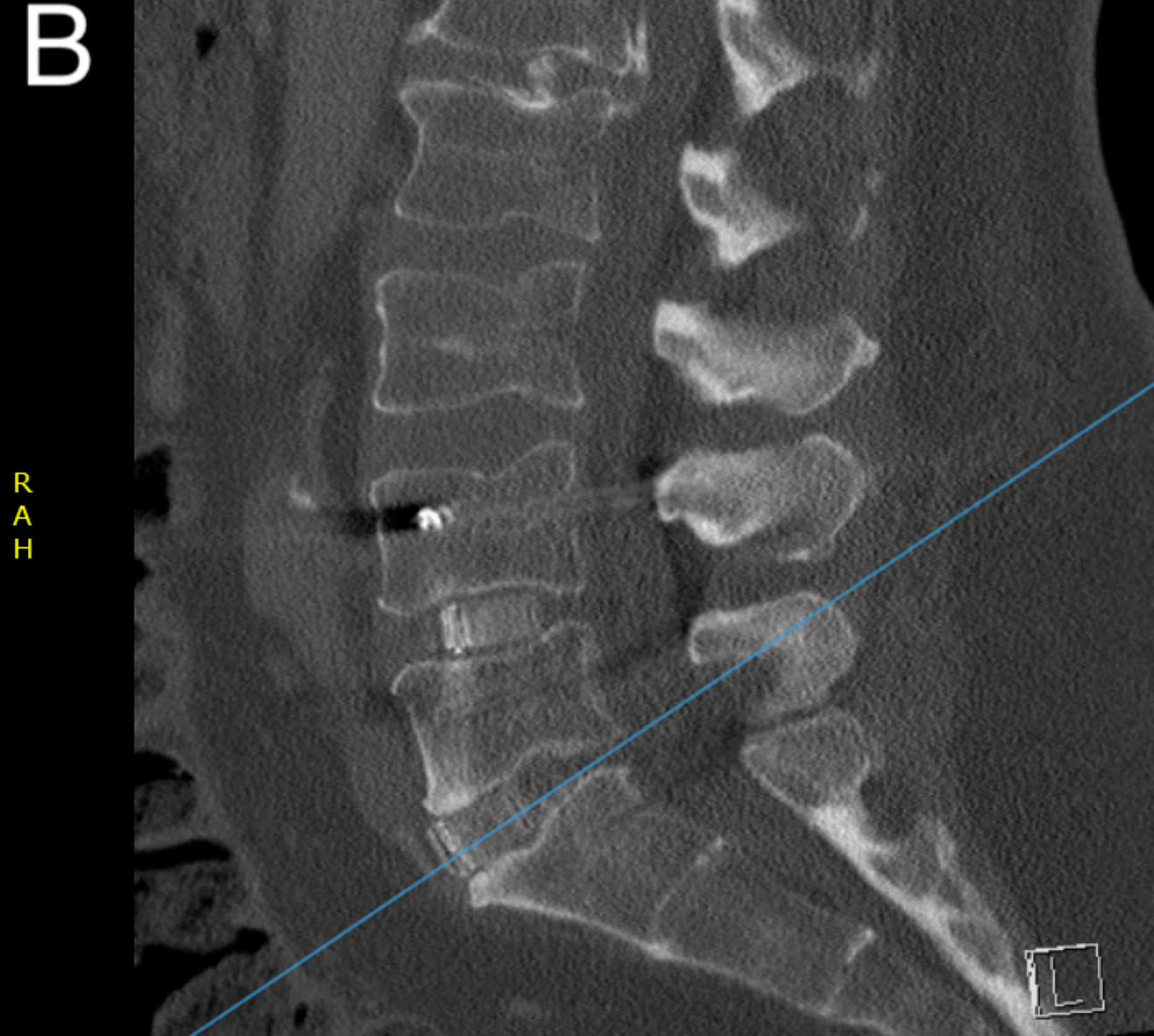
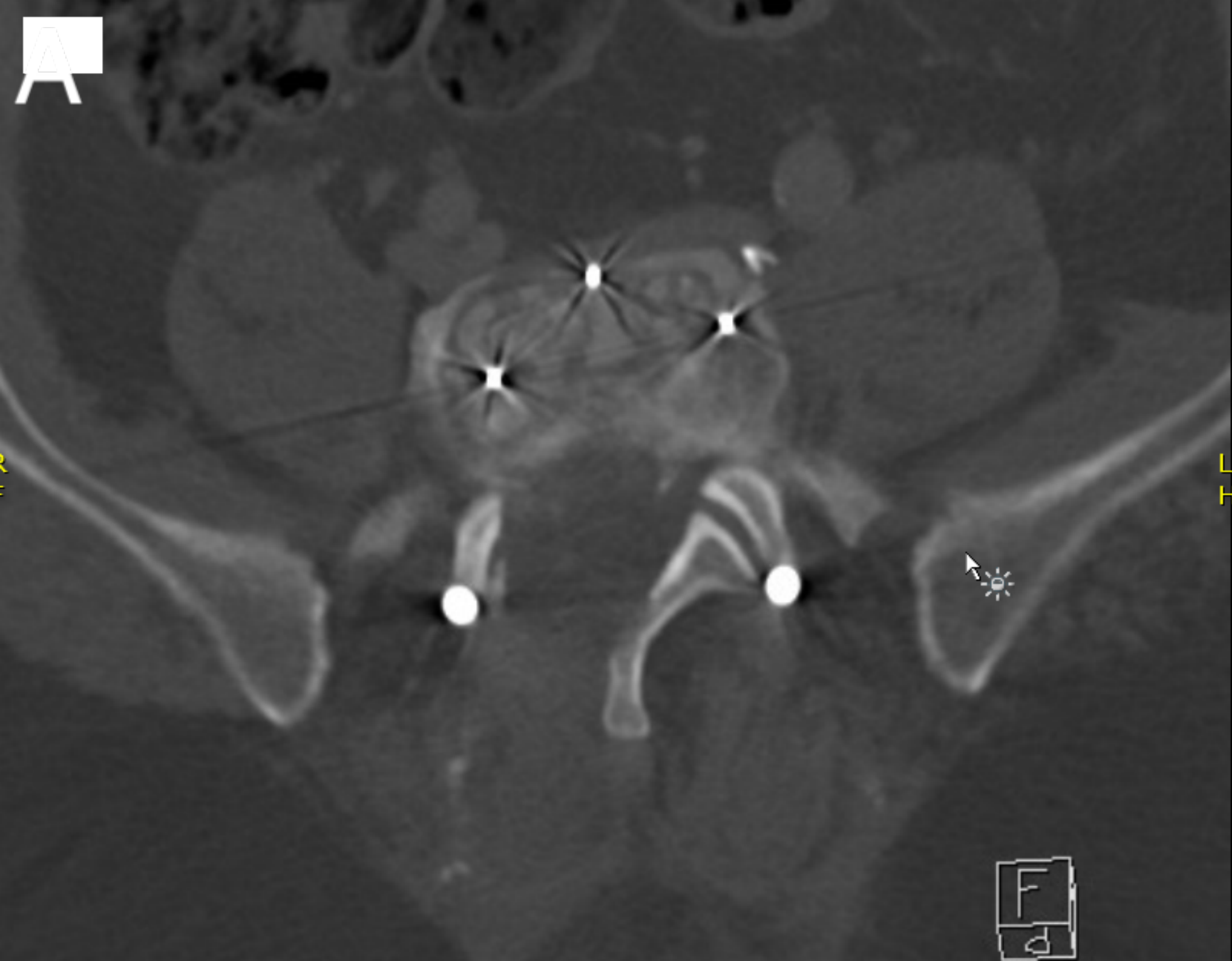
231 **References:**

232

- 233 1. Chastain CA, Eck JC, Hodges SD, Humphreys SC, Levi P. Transforaminal Lumbar
234 Interbody Fusion: A Retrospective Study of Long-Term Pain Relief and Fusion
235 Outcomes. *Orthopedics* 2007 30:389–392
- 236 2. Gill K, Blumenthal SL. Posterior Lumbar Interbody Fusion. A 2-Year Follow-Up of 238
237 Patients. *Acta Orthop Scand Suppl* 1993 251:108–110
- 238 3. Takahashi K, Kitahara H, Yamagata M et al. Long-Term Results of Anterior Interbody
239 Fusion for Treatment of Degenerative Spondylolisthesis. *Spine (Phila Pa 1976)* 1990
240 15:1211–1215
- 241 4. Chung NS, Jeon CH, Lee HD. Use of an Alternative Surgical Corridor in Oblique
242 Lateral Interbody Fusion At the L5-S1 Segment: A Technical Report. *Clin Spine Surg*
243 2017
- 244 5. Uribe JS, Arredondo N, Dakwar E, Vale FL. Defining the Safe Working Zones Using
245 the Minimally Invasive Lateral Retroperitoneal Transpsoas Approach: An Anatomical
246 Study. *J Neurosurg Spine* 2010 13:260–266
- 247 6. Silvestre C, Mac-Thiong JM, Hilmi R, Roussouly P. Complications and Morbidities of
248 Mini-Open Anterior Retroperitoneal Lumbar Interbody Fusion: Oblique Lumbar
249 Interbody Fusion in 179 Patients. *Asian Spine J* 2012 6:89–97
- 250 7. Davis TT, Hynes RA, Fung DA et al. Retroperitoneal Oblique Corridor to the L2-S1
251 Intervertebral Discs in the Lateral Position: An Anatomic Study. *J Neurosurg Spine*
252 2014 21:785–793
- 253 8. Zairi F, Sunna TP, Westwick HJ et al. Mini-Open Oblique Lumbar Interbody Fusion
254 (OLIF) Approach for Multi-Level Discectomy and Fusion Involving L5-S1: Preliminary
255 Experience. *Orthop Traumatol Surg Res* 2017 103:295–299
- 256 9. Lenke LG, Bridwell KH, Bullis D, Betz RR, Baldus C, Schoenecker PL. Results of in
257 Situ Fusion for Isthmic Spondylolisthesis. *J Spinal Disord* 1992 5:433–442
- 258 10. Davis M, Jenkins S, Bordes S et al. Iliolumbar Vein: Anatomy and Surgical Importance
259 During Lateral Transpsoas and Oblique Approaches to Lumbar Spine. *World Neurosurg*
260 2019
- 261 11. Orita S, Inage K, Eguchi Y et al. Lumbar Foraminal Stenosis, the Hidden Stenosis
262 Including At L5/S1. *Eur J Orthop Surg Traumatol* 2016 26:685–693
- 263 12. Chung NS, Jeon CH, Lee HD, Kweon HJ. Preoperative Evaluation of Left Common
264 Iliac Vein in Oblique Lateral Interbody Fusion At L5-S1. *Eur Spine J* 2017 26:2797–
265 2803
- 266 13. Kanno K, Ohtori S, Orita S et al. Miniopen Oblique Lateral L5-S1 Interbody Fusion: A
267 Report of 2 Cases. *Case Rep Orthop* 2014 603531
- 268 14. Kim KT, Jo DJ, Lee SH, Seo EM. Oblique Retroperitoneal Approach for Lumbar
269 Interbody Fusion From L1 to S1 in Adult Spinal Deformity. *Neurosurg Rev* 2017
- 270 15. Woods KR, Billys JB, Hynes RA. Technical Description of Oblique Lateral Interbody
271 Fusion At L1-L5 (OLIF25) and At L5-S1 (OLIF51) and Evaluation of Complication and
272 Fusion Rates. *Spine J* 2017 17:545–553

- 273 16. Phan K, Maharaj M, Assem Y, Mobbs RJ. Review of Early Clinical Results and
274 Complications Associated With Oblique Lumbar Interbody Fusion (OLIF). *J Clin*
275 *Neurosci* 2016 31:23–29
- 276 17. Chang J, Kim JS, Jo H. Ventral Dural Injury After Oblique Lumbar Interbody Fusion.
277 *World Neurosurg* 2017 98:881.e1–881.e4
- 278 18. Schroeder GD, Kepler CK, Millhouse PW et al. L5/S1 Fusion Rates in Degenerative
279 Spine Surgery: A Systematic Review Comparing ALIF, TLIF, and Axial Interbody
280 Arthrodesis. *Clin Spine Surg* 2016 29:150–155
281





Patient	sex	Age (Y)	Diagnostic	Operation	Blood loss (mL)	OLIF OR time (Min)	OR time per Level (Min)	ASA score	Acute Complications	Long term complications	Fusion achieved	Follow-up-period	LOS (D)	Orientation
1	F	74	Scoliosis	L1-L2 + L5-S1	100	105	52,5	3	Screw misplacement (posterior fixation)	No	Yes	19	24	R. Center
2	F	56	Flat back	L3-L4 to L5-S1	100	340	113,3	2	Compressive Hematoma that evolved to abscess	No	Yes	29	3	Home
3	M	75	Flat back	L2-L3 to L5-S1	200	230	57,5	2	No	Proximal Junction Kyphosis (PJK)	No	27	4	Home
4	M	55	Kyphoscoliosis	L2-L3 to L5-S1	300	210	52,5	2	No	No	Yes	8	15	Home
5	M	66	Flat back	L4-L5 to L5-S1	200	205	102,5	2	Pain	No	No	14	9	Home
6	F	45	Lytic Spondylolisthesis	L5-S1	200	300	300,0	1	No	No	Yes	59	2	Home
7	F	69	Lytic Spondylolisthesis	L5-S1	150	195	195,0	3	Cage displacement	No	Yes	58	16	R. Center
8	F	55	Scoliosis	L1-L2 to L5-S1	500	480	96,0	2	Anemia and Delirium	No	Yes	15	17	R. Center
9	F	63	Scoliosis	L2-L3 to L5-S1	200	345	86,3	3	No	No	Yes	31	14	Home
10	F	77	Scoliosis	L2-L3 to L5-S1	200	390	97,5	2	No	No	Yes	25	13	R. Center
11	M	66	Scoliosis	L2-L3 to L5-S1	200	300	75,0	3	No	No	Yes	30	7	Home
12	F	64	Scoliosis	L3-L4 to L5-S1	300	330	110,0	2	Psoas paresis	No	Yes	27	4	Home
13	M	66	Kyphoscoliosis	L1-L2 to L5-S1	650	375	75,0	3	Pulmonary atelectasis without infection	Non-union	No	58	19	R. Center
14	M	68	Flat back	L4-L5 to L5-S1	200	165	82,5	2	Ileus	No	Yes	6	6	Home
15	M	68	Lytic Spondylolisthesis	L3-L4 to L5-S1	300	260	86,7	2	No	No	Yes	23	5	Home
16	M	64	Kyphoscoliosis	L3-L4 to L5-S1	400	280	93,3	3	Psoas paresis	No	Yes	30	22	R. Center
17	F	65	Scoliosis	L1-L2 to L5-S1	100	310	62,0	2	Anemia, psoas paresis	No	Yes	23	9	Home
Average	8M /9F	64,5			252,9	283,5	102,2	2,3			88% fusion	28,3	11,1	

Patient	PI	SS pre-OP	SS post-OP	PT pre-OP	PT post-OP	LL pre-OP	LL post-OP	LL gain	L5-S1 L pre-OP	L5-S1 L post-OP	L5-S1 L gain	SVA pre-OP (mm)	SVA post-OP (mm)
1	61.00	25.00	32.00	36	29	33.00	44.00	11.00	4.00	8.00	4.00	101.00	66.00
2	43.00	17.00	17.00	26	26	19.00	27.00	8.00	0.00	7.00	7.00	60.00	15.00
3	49.00	10.00	22.00	39	27	-8.00	30.00	38.00	0.00	7.00	7.00	100.00	50.00
4	30.00	15.00	15.00	15	15	-5.00	15.00	20.00	8.20	12.00	3.80	80.00	61.00
5	62.00	38.00	28.00	24	34	36.00	37.00	1.00	4.00	6.00	2.00	86.00	0.00
6	77.00	40.00	40.00	37	37	53.00	58.00	5.00	4.00	13.00	9.00	20.00	19.00
7	61.00	32.00	33.00	29	28	48.00	52.00	4.00	0.00	9.00	9.00	72.00	68.00
8	55.00	20.00	36.00	35	19	-11.00	30.00	41.00	13.00	14.00	1.00	68.00	28.00
9	60.00	20.00	26.00	40	34	29.00	38.00	9.00	11.00	14.00	3.00	0.00	-25.00
10	48.00	28.00	28.00	20	20	33.00	45.00	12.00	6.00	9.00	3.00	63.00	50.00
11	65.00	33.00	41.00	32	24	12.00	61.00	49.00	2.00	12.00	10.00	170.00	67.00
12	60.00	45.00	17.00	15	43	47.00	47.00	0.00	9.00	15.00	6.00	12.00	12.00
13	50.00	20.00	14.00	30	36	-6.00	35.00	41.00	7.00	8.00	1.00	223.00	80.00
14	35.00	12.00	17.00	23	18	19.00	20.00	1.00	0.00	13.00	13.00	30.00	30.00
15	56.00	31.00	36.00	25	20	48.00	48.00	0.00	7.00	14.00	7.00	-16.00	29.00
16	44.00	33.00	41.00	11	3	24.00	43.00	19.00	6.00	15.00	9.00	124.00	75.00
17	43.00	16.00	19.00	27	24	40.00	41.00	1.00	2.00	10.00	8.00	-27.00	23.00
Average								15.29			6.05		