



HAL
open science

Twenty-four years of experience in management of complex mandibular fractures with low cost, custom-made mandibular external fixation: A 65-patient series

L. Marti-Flich, M. Schlund, G. Raoul, J.-M. Maes, J. Ferri, T. Wojcik, R. Nicot

► To cite this version:

L. Marti-Flich, M. Schlund, G. Raoul, J.-M. Maes, J. Ferri, et al.. Twenty-four years of experience in management of complex mandibular fractures with low cost, custom-made mandibular external fixation: A 65-patient series. *Journal of Stomatology, Oral and Maxillofacial Surgery*, 2020, 121, pp.242 - 247. 10.1016/j.jormas.2019.08.008 . hal-03490162

HAL Id: hal-03490162

<https://hal.science/hal-03490162v1>

Submitted on 22 Aug 2022

HAL is a multi-disciplinary open access archive for the deposit and dissemination of scientific research documents, whether they are published or not. The documents may come from teaching and research institutions in France or abroad, or from public or private research centers.

L'archive ouverte pluridisciplinaire **HAL**, est destinée au dépôt et à la diffusion de documents scientifiques de niveau recherche, publiés ou non, émanant des établissements d'enseignement et de recherche français ou étrangers, des laboratoires publics ou privés.



Distributed under a Creative Commons Attribution - NonCommercial 4.0 International License

Twenty-four years of experience in management of complex mandibular fractures with low cost, custom-made mandibular external fixation: A 65-patient series

L. Marti-Flich, M. Schlund, G. Raoul, J-M. Maes, J. Ferri, T. Wojcik, R. Nicot

Lucas Marti-Flich, Resident, Univ. Lille, CHU Lille, Department of Oral and Maxillofacial Surgery, F-59000 Lille, France

Matthias Schlund, MD, MSc, Chief Resident, Univ. Lille, CHU Lille, INSERM, Department of Oral and Maxillofacial Surgery, U1008 - Controlled Drug Delivery Systems and Biomaterials, F-59000 Lille, France

Gwénaél Raoul, MD, PhD, Professor, Univ. Lille, CHU Lille, INSERM, Department of Oral and Maxillofacial Surgery, U1008 - Controlled Drug Delivery Systems and Biomaterials, F-59000 Lille, France

Jean-Michel Maes, MD, Hospital Practitioner, Univ. Lille, CHU Lille, Department of Oral and Maxillofacial Surgery, F-59000 Lille, France

Joël Ferri, MD, PhD, Professor, Univ. Lille, CHU Lille, INSERM, Department of Oral and Maxillofacial Surgery, U1008 - Controlled Drug Delivery Systems and Biomaterials, F-59000 Lille, France

Thomas Wojcik, MD, MSc, Hospital Practitioner, Cervico-Facial Surgery Department, Centre Oscar Lambret, F-59000 Lille, France

Romain Nicot, MD, MSc, Senior Lecturer, Univ. Lille, CHU Lille, INSERM, Department of Oral and Maxillofacial Surgery, U1008 - Controlled Drug Delivery Systems and Biomaterials, F-59000 Lille, France

Corresponding author:

Dr. Matthias Schlund
Service de Chirurgie Maxillo Faciale et Stomatologie
Hôpital Roger Salengro – CHU de Lille
Rue Emile Laine – 59037 Lille Cedex - France
Tel: 33 3 20 44 63 60
Fax: 33 3 20 44 58 60
E-mail: schlund.matthias@wanadoo.fr

Abstract:

Introduction: Ginestet introduced the first external device used to fix the mandible in 1936. In 1949, Morris introduced a biphasic fixation device. This “Joe Hall Morris fixation” design led to use of a self-crafted external fixator based on pins connected by a breathing tube filled with dental resin. The objective of this study was to present our surgical results with this device through a 65-patient series.

Methods: This retrospective study included all the patients who benefited from the self-crafted mandibular external fixator at our Oral and Maxillofacial department from 1995 to 2019. Sixty-five patients were allocated into two groups. There were 39 patients in the temporary stabilisation (TS) group and 26 in the bone-healing (BH) group. Functional criteria were investigated, including mouth opening limitations and occlusal abnormalities. Aesthetic evaluation focused on skin healing, evaluated by both surgeon and patient.

Results: Twenty-three patients exhibited spontaneous bone healing during their immobilisation period and two patients developed a pseudoarthrosis in the BH group. Most TS group patients benefited from secondary management by bone graft, bone free flap, or distraction osteogenesis. Few complications were noted with our technique during the study period.

Conclusion: Our self-crafted external fixation with Joe Hall Morris fixation style is a valuable option for external stabilisation of the lower third of the face.

Keywords: Mandibular fracture; External fixation; ORIF; Gunshot injury; Pathological mandibular fracture; Osteoradionecrosis

Introduction:

Traumas of the lower third of the face represent up to 50% of facial traumas, and their epidemiology is fully described [1,2]. However, management of complex mandibular traumas remains challenging, and different approaches are possible depending on objectives and surgical teams' preferences. Historically, closed reduction and external fixation or open reduction and internal fixation (ORIF) have been discussed and applied with common outcomes: best functional and aesthetic rehabilitations with low morbidity [3].

Albin Lambotte, at the beginning of the twentieth century, initially developed the external fixator for trauma management of the limbs. Malgaigne and Rigaud had already reported its first use on long bones in 1870. Gustave Ginestet transposed the technique to the maxillofacial skeleton and successively developed three different devices between 1934 and 1948 [4]. Clouster and Walker modified a Roger Anderson orthopedic appliance to treat comminuted mandible fractures during World War II [3]. Of note, their last model consisted of pins inserted into bone fragments and connected to rods to build a frame; it is still commercially available nowadays, with slight improvement, but without any major modifications. Joe Hall Morris, during the Korean War, described an external fixator where pins were connected with self-curing resin instead of rods, simplifying and lightening the fixator compared with models with rods. Although external fixation remains a quick, simple, and non-traumatic technique according to available literature, its indications are currently rare [5].

In our experience, external fixation remains a good technique for management of complex traumas of the lower third of the face. Nevertheless, commercial devices are currently too expensive, and their high cost limits their use in routine practice. The “Joe Hall Morris fixation” design led to use of a self-crafted external fixator based on pins connected by a breathing tube filled with dental resin [6,7]. With this handmade surgical device, we only use materials available in our surgical department, which are available in any surgical department that manages trauma, thus significantly reducing the cost of this device and making it readily accessible at any trauma centre.

The purpose of this study was to present our surgical results with a self-crafted external fixator in complex mandibular fractures through a 65-patient retrospective study.

Materials and Methods:

Included patients

This retrospective study included all patients who benefited from our self-crafted mandibular external fixator at the Oral and Maxillofacial Department of Lille University Hospital from 1995 to 2019. Owing to heterogeneity of the indications, patients were split into two groups depending on the fixation objective: obtain complete bone healing (BH group) or allow temporary stabilisation (TS group).

Surgical technique

The surgical technique has been described previously [7]. Whenever possible, the procedure began with maxillomandibular fixation (MMF) using Dautrey's wires to set back patient's dental occlusion and drive the alveolar bone fragments to anatomical reduction [8,9]. When MMF was not possible, an assistant manually maintained the stabilisation during fixator placement. Punctiform skin incisions were made using a scalpel blade perpendicularly to pin insertion sites. Next, 1.8 or 2 mm Kirschner pins were inserted perpendicularly into the external cortical layer of the basilar bone by using a spindle motor. Depending on the aetiologies and the presence of a bone defect, bi-cortical or quad-cortical pinning was performed. Bi-cortical pinning was used in cases with small bone defects, two or three pins were inserted in each side of the fracture (Figure 1A). If there were multiples fragments, each one was stabilised with at least two pins to avoid fragment rotation. Quad-cortical pinning was useful to maintain posterior transversal dimension, and was used in cases with large bone defect of the anterior part of the mandible, which is often the case with ballistic trauma. In case of quad-cortical pin positioning, the tongue was pulled out to avoid iatrogenic ankyloglossia. Immobilisation of bone fragments and the pins' connection

was then realised using a breathing tube filled with an autopolymerising resin (OSTRON® 100, acrylic tray and baseplate resin). Acrylic resin or cement could also be used to fill the tube. The breathing tube was positioned about 0.5 to 1 cm from the soft tissues and maintained in position during the polymerisation of the resin to guarantee accuracy of the assembly and thus the position of basal bone fragments. Steps of the technique have been illustrated in Figure 1. Postoperative care only included daily local antiseptic application at the skin sites for about 1 month or until the absence of inflammatory phenomena. Removal of external fixator could be realised under local or general anaesthesia after performing orthopantomography or computed tomography (CT) scan (Figure 2). Necessary equipment is illustrated in Figure 3. The cost of such a device can be evaluated as <50 US dollars.

Data collection

Fracture locations, whether or not comminuted, the bone defect location and length, and the immobilisation duration were recorded for patients from both groups.

Functional and aesthetic results were studied in the BH group. Functional outcomes were investigated through mouth opening limitations. It was measured 2 months after the surgical procedure using a calliper with a threshold of 40mm. Aesthetic evaluation focused on skin healing, evaluated by both surgeon and patient.

Primary complications included lack of bone healing in patients with initially no bone defect, infections around the pins, ankyloglossia in cases of quad-cortical pinning, or injury to teeth roots, inferior alveolar nerve, parotid gland, or facial artery.

Results:

We included 65 patients in our study. Fifty-five of them were male. Patient age was 16-69 (mean 39) years in the BH group and 15-82 (mean 48.5) years in the TS group. There were 39 patients in the TS group and 26 patients in the BH group. Immobilisation lasted from 10 days to 19 months (mean 4.67 months) in the BH group, and 1-12 months (4.42 months) in the TS group. Ballistic traumas and osteoradionecrosis (ORN) were predominant in the TS group, whereas infections and complex traumatic cases were predominant in the BH group. Patients' data are summarised in Tables 1 and 2.

Among BH group patients, 23 presented spontaneous bone healing during their immobilisation period, and two patients developed pseudoarthrosis. In both cases, a second intervention consisting of ORIF was performed, which led to complete bone healing. Another patient had her external device removed 10 days after her traumatic event, and internal load bearing fixation was performed. In this group, the mean immobilisation by the external device was 4,67 months.

Among TS group patients, two with pathological fracture (one following ORN and one following tumour evolution) and one patient with a ballistic injury healed spontaneously, without any secondary procedure, after immobilisation of 3, 5, and 11 months, respectively. Remaining patients from the TS group benefited from secondary management by bone graft, bone free flap, or distraction osteogenesis.

We noted few complications with our technique during the study period. No damage to teeth roots, inferior alveolar nerve, parotid gland, or facial artery were reported. However, all patients presented local skin inflammation during the fixation period, as expected with transcutaneous fixation. We introduced local care and antibiotic therapy (amoxicillin-clavulanic acid) for 5 days, and none of these local skin inflammation episodes led to early device removal.

On functional assessment, seven patients experienced postoperative mouth opening limitations that resolved after physiotherapy. Regarding aesthetic results, none of the 26 evaluated patients complained or showed unacceptable scarring results due to transcutaneous pins after evaluation by the surgical team.

Discussion:

Owing to its low morbidity with acceptable aesthetic and functional sequelae and also its low cost, our self-crafted external fixator seems to be an effective therapeutic alternative for management of complex mandibular traumas [7].

Historically, the external fixator was the gold standard in management of complex mandibular fractures or bone defects [2,10,11]. Situations of important comminution associated with large periosteal, muscle, or mucosal damage, have an inherent high risk of nonunion and infections, leading surgeons to avoid performing ORIF. Most indications for external fixation have been developed based on the principle of soft tissue preservation. Indications of external fixation include heavy fractures with soft tissue damage, pathological mandibular fractures (infections, ORN, tumours, osteomyelitis, large cysts), and large bone defects awaiting secondary reconstruction [3]. Nowadays, ORIF is considered the gold standard for management of complex traumas of facial bones [12,13]. If appropriately executed, ORIF has proven to bring about great progress in management of comminuted fractures of the mandible, improving precision as well as aesthetics and functional outcomes [14]. However, if the surgical team is not well trained in ORIF, or the necessary equipment is not available, simple closed treatment should be preferred [15]. In our opinion, external fixation should not be completely discounted from the therapeutic solution, particularly for management of pathological fractures due to ORN or in cases of large bone defects before the reconstruction procedure [13].

The first element to discuss is the stabilisation objective: is it to obtain complete bone healing or to wait until secondary reconstruction? Considering the objective of

complete bone healing, the literature is extensive [5]. Our results were concordant with available literature [16,17]. In our study, the percentage of complete bone healing was 88.46% (23/26 patients). This is similar to the 92% (12/13 patients) who underwent bone healing reported by Zorman *et al.* [17]. We think that the development of pseudoarthrosis may be explained by an insufficient fixation period (2 months). In such situations, the stabilisation duration should not be less than 3 months to allow bone healing with calcification before removal of the fixator. These results, comparable to those reported with other external fixation devices, indicate the efficiency of this technique in complex maxillofacial traumas with a bone-healing objective.

In patients with large bone defects, the aim of our technique is to maintain the best patient anatomy before they can benefit from optimal secondary reconstructive surgical procedure and to reduce pain. In these cases, temporary stabilisation cannot be contested. According to Midis *et al.* [18], the Joe Hall Morris style appliance allows for reliable and rapid immediate fixation of the mandible with acceptable functional and aesthetic results, without any delay or interference with postoperative radiotherapy, in oral carcinoma with mandible resection. Performing ORIF or any other form of load-sharing fixation in cases of comminuted fractures or bone defects, would impart stabilisation by compression. This would be an incorrect choice of procedure because small fragments of large comminuted fractures cannot be compressed and are not capable of sharing loads [5]. ORIF has also its limitations with high rates of complications in case of mandibular continuity defects [19]. Closed reduction by external fixation remains a good indication when there is severe comminution, soft tissue disruption (mostly gunshot wounds), and inadequate teeth on either side of the comminuted fracture to control the spatial relationship of the

remaining mandibular fragments by MMF [5]. External devices are particularly indicated in face gunshot wounds and blast injuries that are associated with high morbidity and mortality. In fact, the surgery must be quick and efficient [20]. The temporary external device gives us more time to plan effective reconstruction while it effectively alleviates pain [21–23].

Another advantage of closed reduction and external fixation is its capacity to prevent bone fragments from devascularisation. Even if it does not offer the same rigidity as ORIF, external fixation presents the advantage of preserving bone periosteum, and, hence, vascularisation of the fragments. Indeed, the role of periosteal vascularisation in the bone healing process is essential, as demonstrated by Ilizarov [24]. Thus, in our opinion, this technique seems to be a good indication for periosteal bone vascularisation. Patients with low-velocity gunshot wounds to the lower face often present limited bone defect with several comminuted fragments and extensive soft tissue damage. In such cases, MMF associated with an external fixation device can be a viable option to preserve bony fragments from devascularization [25]. It could also help maintain the lower face anatomy or transversal dimension before a secondary reconstructive surgical procedure, thus avoiding cicatricial tissue retractions [26]. In our series, a patient with ORN who presented with a bone defect after removal of a bony sequestrum experienced spontaneous bone healing as well. We noticed the same in another patient with a gunshot wound. Our primary hypothesis to explain these cases was that the periosteum was preserved in both cases, ensuring its role in bone vascularization [17].

Technical evolution of ORIF led its results to be equivalent or superior to those of external stabilisation in several cases. It allows better stabilisation of the bone

fragments and thus improves the bone healing process [17]. Moreover, it leads to better posttraumatic restoration of facial proportions and earlier functional recovery [27]. However, ORIF requires performing large bone exposure, leading to devascularisation of comminuted fragments and further bone resorption. Finally, MMF as an alternative to avoid surgical injuries to the periosteum cannot provide stability of basilar bone fragments and should be completed by external or internal stabilisation.

Commercial external devices and the Joe Hall Morris style external fixator have the same indications and results [28]. In our self-crafted external fixator, the connection is ensured by a breathing tube filled with resin. In commercial external fixators, pins are connected by short bars or bow-shaped rods and nuts [29]. The self-crafted technique offers more stability than commercial ones, but its modification requires more complex manipulations such as sectioning between two pins to change the position and putting back some new resin, or removing the entire breathing tube and putting in a new one. However, we have never experienced such situations. In the commercial device, adjustment is easy to perform but nuts can unscrew and loosen reducing immobilisation stability; it is also time consuming to set. It is similar to an external orthopaedic fixator and provides several advantages because of its versatility and simplicity of use [30,31]. In our opinion, a major argument to employ our self-crafted fixator is that it does not require any specific ancillary. In fact, commercial devices need specific ancillaries and single-use material to be integrated into the therapeutic arsenal, whereas components of our custom-made fixator are present in all emergency departments. Moreover, if the basic principles are respected [7], components can be modified depending on surgeons' imagination, particularly

the material filling the breathing tube (self-curing resin or orthopedic cement) [32,33]. However, if the surgical team is not well trained for ORIF, closed reduction and fixation is a far better option [15]. In fact, it is the same for our handmade device with less bulky ancillaries and easy-to-use-and-find material.

Finally, the economic aspect is important in our medical practice, and our device is advantageous in this respect. The total cost is <50 US dollars/device for our device, compared with 3000-4000 US dollars/device for commercial devices (not counting the cost of the ancillary). Thus, use of our approach will be welcome in the context of budget restriction in hospitals. Medical techniques throughout the community must demonstrate their superiority or equivalence in comparison with the gold standard not only for patients but also for society [34].

However, to evaluate the cost of a technique, other parameters such as duration of intervention and length of the hospitalisation must be included owing to their high impact on global cost of patient care [35]. Unfortunately, due to the retrospective design of our study, we could not collect these data and include them into our analysis. However, we can report that in our experience, most of the time, the set-up procedure for this type of a device takes <30 min. Moreover, hospitalisation duration does not seem to be a relevant parameter because it is related more to the general condition of the patient than to the technique.

Other points to discuss are morbidity of the technique and its functional and aesthetic outcomes. Postoperative care was limited and local inflammation around the pins was easily managed without any major consequences [3]. Facial wounds were essentially linked to the trauma. Thus, the external fixator seems to have limited scarring effect, as compared with ORIF, which requires more important endobuccal or neck incisions [28]. However, although not studied in our retrospective study, the

external fixator has a negative impact on patients' daily lives and their social interactions. The size of the device makes it difficult to accept because of its stigmatizing nature. Hence, patients and/or their families, depending on the emergency conditions, are, whenever possible, informed about the technique and its objectives in order to obtain their adherence, which is essential for success of the treatment provided [36].

Conclusion:

Management of complex traumas of the lower third of the face remains challenging. Although ORIF is the gold standard for such patients, it is not the answer in all cases, and closed reduction with external fixation should be maintained in our therapeutic arsenal. However, considering the limited number of patients that would benefit from that technique, its cost must be reasonable and the necessary equipment must be present in all Maxillofacial Surgery Departments and Trauma centres. Hence, in our opinion, the self-crafted Joe Hall Morris fixation style external fixation device is a valuable option for external stabilisation of the lower third of the face.

Authors declare no conflict of interest.

References:

- [1] Allan BP, Daly CG. Fractures of the mandible. A 35-year retrospective study. *Int J Oral Maxillofac Surg* 1990;19:268–71.
- [2] Allareddy V, Allareddy V, Nalliah RP. Epidemiology of facial fracture injuries. *J Oral Maxillofac Surg* 2011;69:2613–8. doi:10.1016/j.joms.2011.02.057.
- [3] Braidy HF, Ziccardi VB. External fixation for mandible fractures. *Atlas Oral Maxillofac Surg Clin North Am* 2009;17:45–53. doi:10.1016/j.cxom.2008.10.001.
- [4] Ginestet null. [Osteosynthesis of mandible external fixator; French method, a U.S. equipment]. *Rev Odontostomatol (Paris)* 1949;5:197–9.
- [5] Chrcanovic BR. Open versus closed reduction: comminuted mandibular fractures. *Oral Maxillofac Surg* 2013;17:95–104. doi:10.1007/s10006-012-0349-2.
- [6] Morris JH. Biphasic connector, external skeletal splint for reduction and fixation of mandibular fractures. *Oral Surg Oral Med Oral Pathol* 1949;2:1382–98, illust.
- [7] Wojcik T, Nicot R, Ferri J, Raoul G. A Cheap Hand-Made Mandibular External Fixator? *J Craniofac Surg* 2016;27:1839–41. doi:10.1097/SCS.0000000000002963.
- [8] Al-Assaf DA, Maki MH. Multiple and comminuted mandibular fractures: treatment outlines in adverse medical conditions in Iraq. *J Craniofac Surg* 2007;18:606–12. doi:10.1097/01.scs.0000248661.91522.c5.
- [9] Li Z, Li Z-B. Clinical characteristics and treatment of multiple site comminuted mandible fractures. *J Craniomaxillofac Surg* 2011;39:296–9. doi:10.1016/j.jcms.2010.04.009.
- [10] Converse JM, Waknitz FW. External skeletal fixation in fractures of the mandibular angle. *J Bone Joint Surg* 1942;24:154.
- [11] Ginestet G, Merville L. [Indications and methods in the surgical treatment of fractures of the mandible]. *Rev Fr Odontostomatol* 1955;2:27–54.
- [12] Scolozzi P, Richter M. Treatment of severe mandibular fractures using AO reconstruction plates. *J Oral Maxillofac Surg* 2003;61:458–61. doi:10.1053/joms.2003.50087.
- [13] Rana M, Warraich R, Rashad A, von See C, Channar KA, Rana M, et al. Management of comminuted but continuous mandible defects after gunshot injuries. *Injury* 2014;45:206–11. doi:10.1016/j.injury.2012.09.021.
- [14] Perry M. Maxillofacial trauma--developments, innovations and controversies. *Injury* 2009;40:1252–9. doi:10.1016/j.injury.2008.12.015.
- [15] Alpert B, Tiwana PS, Kushner GM. Management of comminuted fractures of the mandible. *Oral Maxillofac Surg Clin N Am* 2009;21:185–92, v. doi:10.1016/j.coms.2008.12.002.
- [16] Kelly JF. Management of War Injuries to the Jaws and Related Structures. First Edition. Government Printing Office; 1977.
- [17] Zorman D, Godart PA, Kovacs B, Andrienne Y, Daelemans P, Burny F. Treatment of mandibular fractures by external fixation. *Oral Surg Oral Med Oral Pathol* 1990;69:15–9.
- [18] Midis GP, Feuer A, Bergman SA, Elias EG, Lefor AT, Didolkar MS. Immediate mandibular stabilization following resection of advanced oral cavity carcinoma using the Joe Hall Morris external fixation device. *J Surg Oncol* 1992;50:22–6.
- [19] Newlands SD, Samudrala S, Katzenmeyer WK. Surgical treatment of gunshot injuries to the mandible. *Otolaryngol--Head Neck Surg* 2003;129:239–44. doi:10.1016/S0194-5998(03)00481-9.

- [20] Shackford SR, Kahl JE, Calvo RY, Kozar RA, Haugen CE, Kaups KL, et al. Gunshot wounds and blast injuries to the face are associated with significant morbidity and mortality: results of an 11-year multi-institutional study of 720 patients. *J Trauma Acute Care Surg* 2014;76:347–52. doi:10.1097/TA.0b013e3182aaa5b8.
- [21] Ung F, Rocco JW, Deschler DG. Temporary intraoperative external fixation in mandibular reconstruction. *The Laryngoscope* 2002;112:1569–73. doi:10.1097/00005537-200209000-00006.
- [22] Ameerally PJ, Hollows P. Use of an external fixator to stabilise the proximal mandibular segments during reconstruction. *Br J Oral Maxillofac Surg* 2004;42:354–6. doi:10.1016/j.bjoms.2004.02.031.
- [23] Mohindra A, Blanco-Guzman MM. Temporary mandibular stabilisation during reconstruction: an alternative technique. *Br J Oral Maxillofac Surg* 2009;47:399–400. doi:10.1016/j.bjoms.2008.09.010.
- [24] Ilizarov GA. The tension-stress effect on the genesis and growth of tissues. Part I. The influence of stability of fixation and soft-tissue preservation. *Clin Orthop* 1989;249–81.
- [25] Wilkening MW, Patel PA, Gordon CB. External fixation in a low-velocity gunshot wound to the mandible. *J Craniofac Surg* 2012;23:e418–9. doi:10.1097/SCS.0b013e31825daecc.
- [26] Vural E, Yuen JC. Combining use of resin models with external fixation in mandibular reconstruction. *Arch Otolaryngol Head Neck Surg* 2007;133:603–7. doi:10.1001/archotol.133.6.603.
- [27] Smith BR, Teenier TJ. Treatment of comminuted mandibular fractures by open reduction and rigid internal fixation. *J Oral Maxillofac Surg* 1996;54:328–31.
- [28] Cornelius C-P, Augustin JB, Sailer L-K. External pin fixation for stabilization of the mandible--comeback of a method: historical review and first experiences with the "mandible external fixator." *Oral Maxillofac Surg* 2009;13:1–14. doi:10.1007/s10006-008-0142-4.
- [29] Louis PJ, Fernandes R. Temporary stabilization of the mandible with an external fixation device. *J Oral Maxillofac Surg* 2001;59:1374–5. doi:10.1053/joms.2001.27797.
- [30] Holmes S, Hardee P, Anand P. Use of an orthopaedic fixator for external fixation of the mandible. *Br J Oral Maxillofac Surg* 2002;40:238–40. doi:10.1054/bjom.2001.0770.
- [31] Alencar MGM de, Bortoli MMD, Silva TCG da, Silva ED de OE, Laureano Filho JR. Suitability of Wrist External Fixator for Treatment of Mandibular Fracture. *J Craniofac Surg* 2018;29:e371–2. doi:10.1097/SCS.0000000000004375.
- [32] Gibbons AJ, Mackenzie N, Breederveld RS. Use of a custom designed external fixator system to treat ballistic injuries to the mandible. *Int J Oral Maxillofac Surg* 2011;40:103–5. doi:10.1016/j.ijom.2010.08.001.
- [33] Koch FP, Götze E, Kumar VV, Schulz P, Wentaschek S, Wagner W. A bar-retained overdenture as an external fixator device in a three-dimensional CAD/CAM-based surgical reconstruction of the mandible. *J Craniomaxillofac Surg* 2015;43:1447–51. doi:10.1016/j.jcms.2015.06.019.
- [34] Wojcik T, Ferri J, Touzet S, Schouman T, Raoul G. Distraction osteogenesis versus fibula free flap for mandibular reconstruction after gunshot injury: socioeconomic and technical comparisons. *J Craniofac Surg* 2011;22:876–82. doi:10.1097/SCS.0b013e31820f7d9e.
- [35] Abramowicz S, Allareddy V, Rampa S, Lee MK, Nalliah RP, Allareddy V. Facial

Fractures in Patients With Firearm Injuries: Profile and Outcomes. *J Oral Maxillofac Surg* 2017;75:2170–6. doi:10.1016/j.joms.2017.05.035.

- [36] Omeje KU, Rana M, Adebola AR, Efunkoya AA, Olasoji HO, Purcz N, et al. Quality of life in treatment of mandibular fractures using closed reduction and maxillomandibular fixation in comparison with open reduction and internal fixation--a randomized prospective study. *J Craniomaxillofac Surg* 2014;42:1821–6. doi:10.1016/j.jcms.2014.06.021.

Figures:

Figure 1: Surgical procedure of external fixator manufacturing. Pins are first inserted, at least three in each bone fragment. Then, the breathing tube is modeled and connects the pins (A) before injection of self-curing resin (B), which will rigidify the device. The final aspect of the device at the end of the procedure: a small distance between soft tissues and the stabilisation tube should be noticed as it improves rigidity of the assembly.

Figure 2: Postoperative CT scan our self-crafted device to fix a mandibular fracture in an osteoradionecrosis patient

Figure 3: Necessary elements for self-crafted external fixator manufacturing, including spindle motor, Kirschner wires, breathing tube, and chemically cured resin (Ostron®)

Tables:

Table 1: Characteristics of patients with objective of bone healing

Table 2: Characteristics of patients with temporary stabilisation

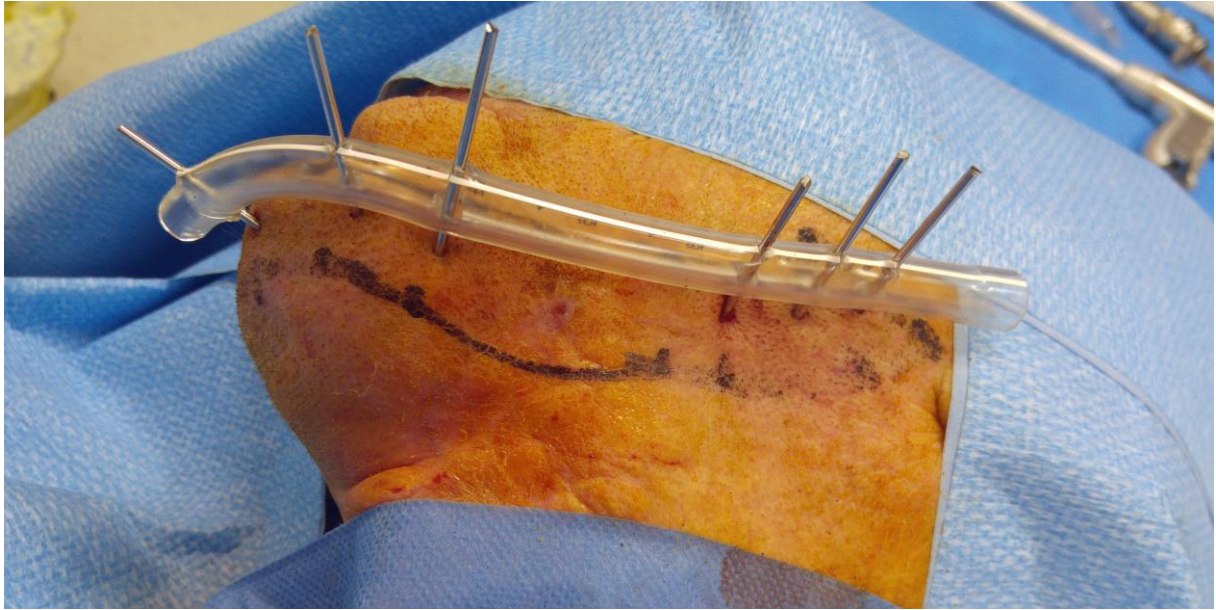

Figure1A

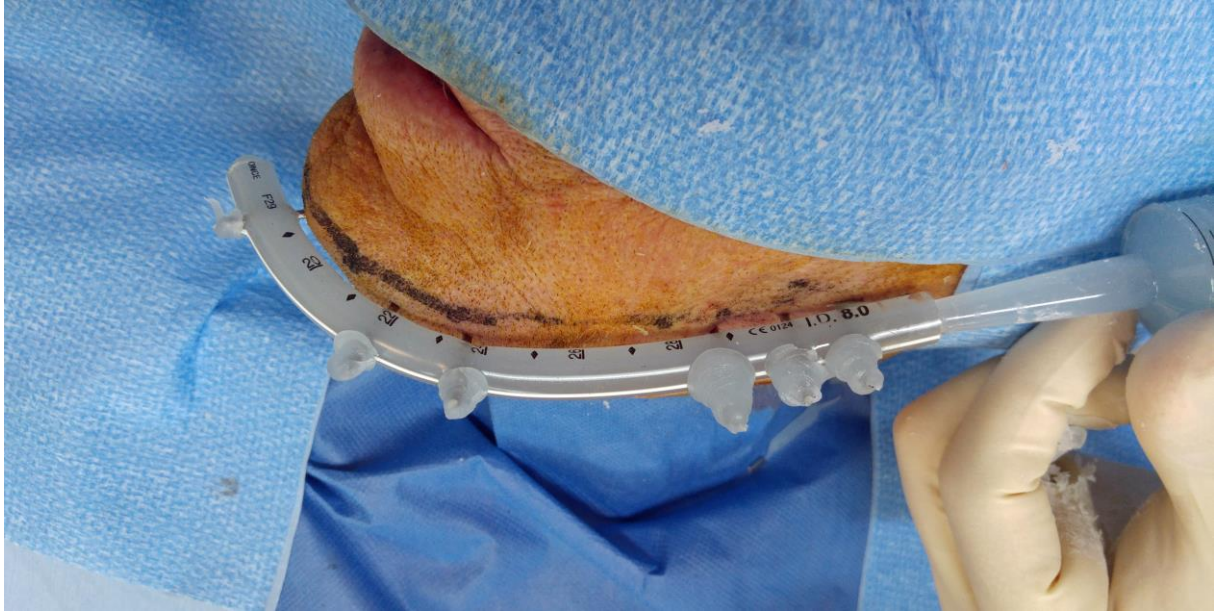

Figure1B

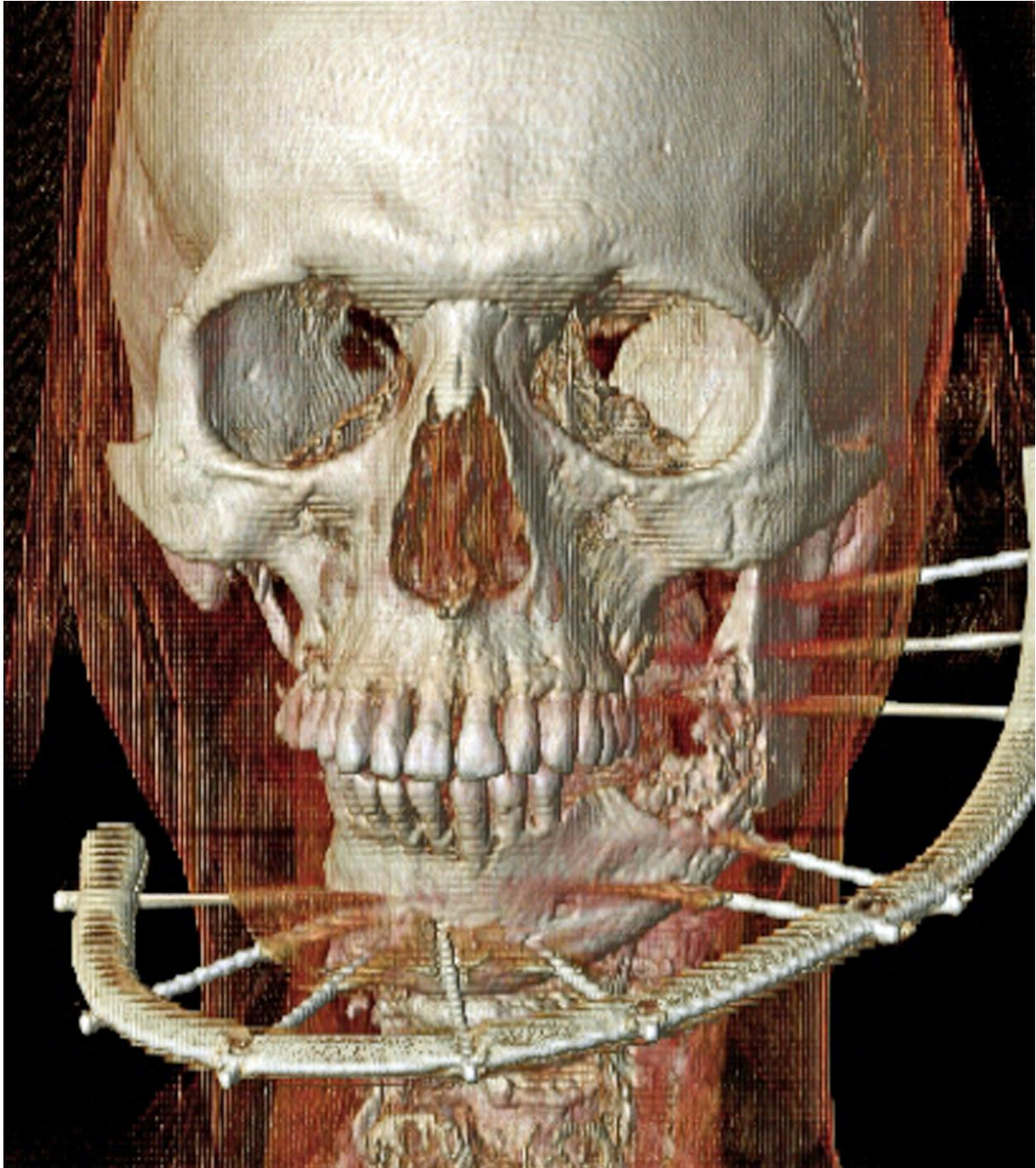


Figure2

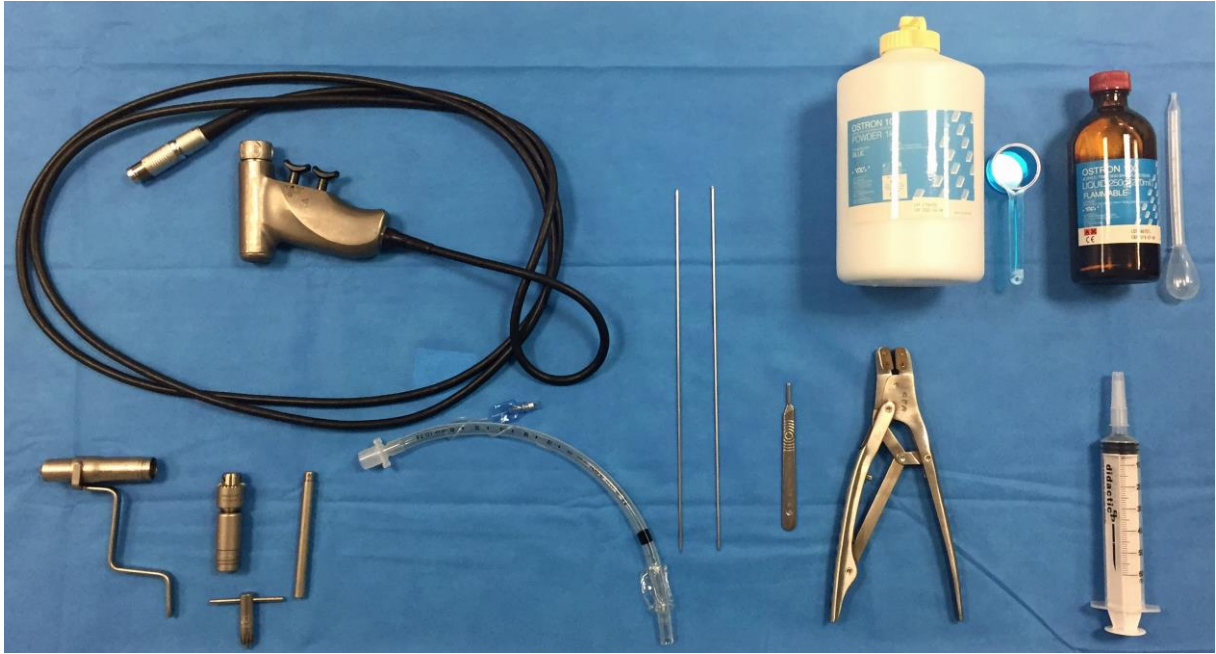

Figure3

Table 1: Characteristics of patients with objective of bone healing

Number	Aetiology	Age (years)	Sex	Fracture Location (Side)	Comminuted fracture	Immobilisation duration (months)	Complete bone healing	Complementary medical cares
1	Infectious	35	M	A (L)	No	11.5	Yes	No
2	Infectious	35	M	HB (R)	No	4.5	Yes	No
3	Infectious	45	M	HB (R)	Yes	3	Yes	No
4	Infectious	51	M	HB (R)	No	2	Yes	No
5	Infectious	35	F	A (L)	No	3	Yes	No
6	Traumatic	22	M	S+P (BL)+HB (BL)	Yes	3	Yes	No
7	Traumatic	34	M	S+SC (L)	Yes	3	Yes	No
8	Traumatic	33	M	HB (R) to Ramus (R)	Yes	2	Yes	No
9	Traumatic	16	F	S+HB (R)+SC (R)	Yes	3	Yes	No
10	Traumatic	27	M	HB (L)+C (BL)	Yes	3	Yes	No
11	Gunshot wound	32	M	P (R) to Ramus (R)	Yes	4	Yes	No
12	Gunshot wound	31	M	HB (L)+A (L)	Yes	2	No	ORIF
13	Gunshot wound	48	F	Angle (L)+ HB (L)	Yes	5.5	Yes	No

14	Gunshot wound	69	M	HB (L)+A (L)+C (L)	Yes	2	Yes	No
15	Gunshot wound	57	M	HB (L)+ P (L)	Yes	4	Yes	No
16	Cyst	59	M	HB (R)	No	3	Yes	No
17	Traumatic	30	F	HB (L)	yes	5	No	ORIF+IBG
18	Traumatic	54	M	HB (R) +P (R)	Yes	5	Yes	No
19	Osteoradionecrosis	64	F	HB (R)	No	4	Yes	No
20	Traumatic	27	M	A (L)	No	1	Yes	No
21	Traumatic	25	F	A (R)+P (BL)+SC (L)	Yes	10 days	No	ORIF
22	Traumatic	15	M	S+P (BL)	Yes	11	Yes	No
23	Traumatic	41	M	A (L)+P (R)	Yes	19	Yes	No
24	Traumatic	47	M	A (L)	No	5	Yes	No
25	AP	31	M	P (R)	No	8	Yes	No
26	AP	55	M	A (R)	No	5	Yes	No

M: Male
F: Female
ORIF: Open reduction and internal fixation
L: Left
R: Right
BL: Bilateral

SC: Sub Condylar
HB: Horizontal Branch
S: Symphysis
P: Parasymphysis
A: Angle
C: Condyles

IBG: Iliac Bone Graft
AP: Aseptic Pseudarthrosis

Table 2: Patients with temporary contention

Number	Aetiology	Age (years)	Sex	Bone defect Location (side)	Comminuted fracture	Immobilisation duration (months)	Complete bone healing	Complementary medical cares
1	Gunshot	33	M	P (L) to A (L)	No	1	No	Bone free flap
2	Gunshot	49	M	S to A (L)	yes	4	No	ORIF+bone graft
3	Gunshot	45	M	P (L) to A (R)	No	5	No	Bone free flap
4	Gunshot	56	M	S	No	2	No	Bone free flap
5	Gunshot	45	M	S+P (L)	No	1.5	No	DO
6	Gunshot	36	M	From P (R) to A (L)	yes	3	No	ORIF+bone graft
7	Gunshot	47	M	HB (L) + P (L)	No	2	No	Bone free flap
8	Gunshot	50	M	HB (R) to HB (L)	No	2	No	Bone free flap
9	Gunshot	37	M	HB (L)	No	1.5	No	DO
10	Gunshot	22	M	HB (R) to HB (L)	No	6.5	No	Bone free flap
11	Gunshot	43	M	HB (L)	No	3.5	No	Bone free flap
12	Gunshot	26	M	S to HB (R)	No	1.5	No	Bone free flap
13	Gunshot	34	F	C (R) to HB (R)	No	1	No	Bone free flap
14	Gunshot	38	M	A (R) to A (L)	No	2	No	Distraction
15	Post avulsion	58	M	HB (R)	No	7	No	ORIF+bone graft
16	Cancer	52	M	HB (L)	No	5	No	Bone free flap

17	ORN	65	M	HB (R)	No	4	No	Bone free flap
18	ORN	56	M	HB (R)	No	2	No	Bone free flap
19	ORN	75	M	HB (L)	No	3	Yes	No
20	ORN	57	M	S	No	7	No	Bone free flap
22	ORN	28	M	HB (BL)	No	5	No	No
23	Gunshot	50	M	A (R)+P (BL)	Yes	5	Yes	Pedicle flap
24	ORN	70	M	HB (L)	No	10	No	Bone free flap
25	ORN	67	F	HB (L)	No	10	No	Bone free flap
26	Gunshot	33	M	S+P (BL)	Yes	8	No	Bone free flap
27	ORN	82	M	HB (R)	No	5	No	No
28	ORN	67	M	HB (L)	No	2	No	Bone free flap
29	ORN	52	M	A (L)	No	5	No	Bone free flap
30	Gunshot	66	M	S+P (L)	Yes	1	No	ORIF
31	Gunshot	39	M	A (L) to S	Yes	5	No	Bone free flap
32	Tumoral	15	M	HB (BL)	No	11	Yes	No
33	SP	45	M	A (L)	No	2	No	No
34	ORN	52	M	A (R)	No	8	No	Bone free flap
35	ORN	48	F	HB (L)	No	6	No	Bone free flap

36	ORN	57	M	A (R)	No	1	No	Bone free flap
37	ORN	61	M	P (L)	No	12	No	No
38	ORN	60	M	HB (R)	No	3	No	No
39	Gunshot	32	M	HB (L)+P (L)	Yes	9	No	Bone free flap

M: Male
F: Female
ORIF: Open reduction and internal fixation
L: Left
R: Right
BL: Bilateral
Gunshot: Gunshot wound

IBG: Iliac Bone Graft
HB: Horizontal Branch
S: Symphysis
P: Parasymphysis
A: Angle
C: Condyles
Tumoral: tumoral pathology

ORN: Osteoradionecrosis
SP: Septic Pseudarthrosis
DO: Distraction osteogenesis