



Comparison of a standard locking screw versus a double-threaded cortical compression screw for fixation of die-punch fragments in distal radius fractures with volar plating

C. Muccioli, J.J. Hidalgo Diaz, C. Pizza, S. Gouzou, S. Facca, P. Liverneaux

► To cite this version:

C. Muccioli, J.J. Hidalgo Diaz, C. Pizza, S. Gouzou, S. Facca, et al.. Comparison of a standard locking screw versus a double-threaded cortical compression screw for fixation of die-punch fragments in distal radius fractures with volar plating. *Hand Surgery and Rehabilitation*, 2020, 39, pp.30 - 35. 10.1016/j.hansur.2019.10.195 . hal-03490103

HAL Id: hal-03490103

<https://hal.science/hal-03490103>

Submitted on 21 Jul 2022

HAL is a multi-disciplinary open access archive for the deposit and dissemination of scientific research documents, whether they are published or not. The documents may come from teaching and research institutions in France or abroad, or from public or private research centers.

L'archive ouverte pluridisciplinaire **HAL**, est destinée au dépôt et à la diffusion de documents scientifiques de niveau recherche, publiés ou non, émanant des établissements d'enseignement et de recherche français ou étrangers, des laboratoires publics ou privés.



Distributed under a Creative Commons Attribution - NonCommercial 4.0 International License

Comparison of a standard locking screw *versus* a double-threaded cortical compression screw for fixation of die-punch fragments in distal radius fractures with volar plating

Comparaison de vis verrouillée standard *versus* vis à compression à double pas pour l'ostéosynthèse de fragments die-punch dans les fractures de l'extrémité distale du radius

C. Muccioli, J.J. Hidalgo Diaz, C. Pizza, S. Gouzou, S. Facca, P. Liverneaux

Department of Hand Surgery, SOS main, CCOM, University Hospital of Strasbourg, FMTS, University of Strasbourg, Icube CNRS 7357, 0, avenue Baumann, 67400 Illkirch, France

Corresponding author:

Liverneaux Philippe

Hand Surgery Department, Strasbourg University Hospitals, 10, avenue Baumann, F-67403 Illkirch, France

Tel + 33 6 88 89 47 79

Fax + 33 3 88 55 23 63

Philippe.liverneaux@chru-strasbourg.fr

Other authors:

Christophe Muccioli

Juan José Hidalgo Diaz

Chiara Pizza

Stéphanie Gouzou

Sybille Facca

Conflicts of Interest:

P.L. has conflicts of interest with Newclip Technics, Argomedical, Biomodex, Zimmer Biomet.

None of the other authors have conflicts of interest

Acknowledgements:

Erik Sauleau , “Méthodes en Recherche Clinique, Service de Santé publique”, Strasbourg

University Hospitals, who performed the statistical analysis.

Comparison of a standard locking screw *versus* a double-threaded cortical compression screw for fixation of die-punch fragments in distal radius fractures with volar plating

Comparaison de vis verrouillée standard *versus* vis à compression à double pas pour l'ostéosynthèse de fragments die-punch dans les fractures de l'extrémité distale du radius

Abstract

The aim of this study was to use a compression screw in the epiphyseal medial orifice of a volar plate to reduce and stabilize the die-punch fragment in distal radius fractures (DRF) undergoing open reduction and internal fixation (ORIF). The main hypothesis was that the range of motion (ROM) in supination would be poorer when a standard screw was used. Our case series included 19 patients with an average age of 59 years (24–91) (SD –35.32) (10 male patients and 9 females) who underwent ORIF of DRFs with a volar plate. Group I included 10 patients in which the die-punch fragment was fixed with a standard locking screw and group II included the 9 patients in which the die-punch fragment was fixed with an angle stable compression screw through both cortices. At the 6-month follow-up visit, the average ROM in flexion was 83% in group I and 81% in group II (–2.327 [–13.657; 8.960]), the ROM in extension was 91% and 89% (–2.754 [–13.410; 7.602]), the ROM in pronation was 100% and 102% (+3.178 [–5.242; 11.457]), the ROM in supination 100% and 97% (–3.171 [–10.825; 4.537]), the pain level was 0.6/10 and 1/10 (+0.106 [–0.809 ; 0.977]), the QuickDASH score was 8.1/100 and 17.17/100 (+5.790 [–2.934; 15.012]), the PRWE was 6.2/100 and 22/100 (+13.109 [4.416; 22.779]) and the grip strength was 95% and 74% of the contralateral side (–12.478 [–24.832; 0.538]). No complications, nonunions or revision surgery were reported in the two groups. One case of secondary displacement of the die-punch fragment occurred in each group. The main hypothesis was not proven. In conclusion, despite what several biomechanical studies have suggested, the use of double-threaded compression screws for

die-punch fragment fixation in DRFs does not improve the clinical outcomes compared to standard locking screws.

Résumé

Le but de cette étude était de mettre en place une vis à compression dans l'orifice épiphysaire le plus médial pour réduire et stabiliser en rappel le fragment die-punch au cours de l'ostéosynthèses de fractures de l'extrémité distale du radius (EDR) par plaque antérieure. L'hypothèse principale était que la supination était inférieure avec une vis standard. Notre série comprenait 19 patients d'âge moyen 59 ans (24-91) (SD -35,32) dont 9 femmes, opérés par plaque antérieure verrouillée. Pour les 10 premiers (groupe I), le fragment die-punch a été synthésé par une vis verrouillée standard et les 9 patients suivants (groupe II) par une vis à compression à double pas. A 6 mois, la flexion moyenne était respectivement de 83% (groupe I) et 81% (groupe II) (-2,327 [-13,657 ; 8,960]), l'extension 91% et 89% (-2,754 [-13,410 ; 7,602]), la pronation 100% et 102% (+3,178 [-5,242 ; 11,457]), la supination 100% et 97% (-3,171 [-10,825 ; 4,537]), la douleur 0,6/10 et 1/10 (+0,106 [-0,809 ; 0,977]), le score QuickDASH 8,1/100 et 17,17/100 (+5,790 [-2,934 ; 15,012]), le PRWE 6,2/100 et 22/100 (+13,109 [4,416 ; 22,779]) et la force 95% et 74% par comparaison avec celle du côté opposé (-12,478 [-24,832 ; 0,538]). Aucune complication ni pseudarthrose ni reprise chirurgicale n'a été notée dans aucun des deux groupes. On notait 1 déplacement secondaire du fragment die-punch dans chacun des deux groupes. Aucune hypothèse n'était vérifiée. En conclusion, contrairement à ce qu'ont montré certaines études biomécaniques, l'utilisation de vis à compression à double pas pour l'ostéosynthèse de fragments die-punch dans les fractures de l'EDR ne donne pas de meilleur résultat fonctionnel que les vis verrouillées standards.

Key words: Distal radius fracture; Volar plate; Double-threaded compression screw;

Die-punch

Mots-clés : Fracture de l'extrémité distale du radius ; Plaque antérieure ; Vis à compression à double pas ; Die-punch

1. Introduction

The gold standard treatment for displaced intraarticular distal radius fractures (DRF) is open reduction and internal fixation (ORIF) with a volar plate [1,2]. The main benefit is the strength and stability of the bone fixation, which allows early mobilization [3-5]. However, this approach does not always provide satisfactory reduction and/or prevent secondary dorsal displacement of the intraarticular dorso-ulnar (die-punch) fragment [6], which would limit the range of motion (ROM) in pronation and supination [7]. The aim of this study was to reduce and stabilize the die-punch fragment by placing a compression screw in the most medial epiphyseal hole of the plate.

Because supination is the main movement impacted by die-punch fragments, the main hypothesis was that wrist ROM in supination after fixation of the die-punch fragment with a standard locking screw will be sub-optimal compared to the ROM obtained following fixation with a double-threaded cortical compression screw. The secondary hypothesis was that the pain, QuickDASH, PRWE, grip strength, and wrist ROM in flexion, extension and pronation will be dramatically improved when a double-threaded cortical compression screw was used.

2. Patients and methods

We reviewed records of all patients treated at our facility between October 2016 and March 2018 for intraarticular DRF (C type fracture according to the AO classification). Patients aged less than 18 years, pregnant female patients, patients with pathological fractures and/or bilateral and open fractures, non-displaced fractures or polytrauma were excluded from our study along with patients whose records were incomplete. Our case series included 19 patients with an average age of 59 years ranging from 24 to 91 years. The cohort included 9 female and 10 male patients (Tables 1 and 2).

All patients were operated under regional anesthesia on a delayed trauma emergency list on outpatient basis and underwent bone fixation with a volar locking plate (Initial R®, Newclip Technics™, Haute Goulaine, France) through a minimally invasive approach [8]. For the first 10 patients (group I), the die-punch fragment of the DRF was stabilized and fixed with

a standard locking screw (Fig. 1). For the next 9 patients (group II), the die-punch fragment of the distal radius was fixed with a double-threaded cortical compression screw (Hand motion®, Newclip Technics™, Haute Goulaine, France) (Fig. 2). Early mobilization was encouraged immediately after the surgery.

The assessment consisted of measuring the wrist ROM in flexion, extension, pronation and supination 6 months postoperatively (expressed as a percentage of the maximum ROM of the contralateral side), the pain level on a visual analog scale ranging from 0 (no pain at all) to 10 (maximum pain), the QuickDASH ranging from 0 (normal function of the upper limb) to 100 (totally impaired function of the upper limb), the PREW ranging from 0 to 100 [9], the grip strength recorded with a Jamar® dynamometer set on position 2 (Sammons Preston Ryolan™, Bolingbrook, IL, USA) and expressed as a percentage of the maximum strength of the contralateral side. The complications and secondary displacements observed on X-rays at the 6-month follow-up visit were documented.

Having established that the two groups were comparable, our statistical analysis focused on comparing the average values of the eight independent quantitative variables at the 6-month follow-up visit: wrist ROM in flexion, extension, pronation and supination; pain level, QuickDASH, PREW, grip strength. Given the small sample size and the paucity of our data, a classical “frequentist” statistical model based on the p-value was considered unsuitable for our data analysis and unlikely to deliver useful information. Therefore the analysis was conducted based on a Bayesian model, which studies the distribution of the T coefficient and calculates the likelihood of finding a difference or not. This model provides an estimate of how strong the likelihood is of finding a difference and is expressed as a figure between 0 and 1; this provides more accurate information compared to the binary information of the p-value ($p < 0.05$ or > 0.05). If the interval of the T coefficient did not contain 0 and the probability was higher than 95%, then the difference was considered significant. All data were analyzed through the software R (R2japgs).

3. Results

The results of our analysis are presented in Tables 3 and 4 (Figs. 3 & 4).

At 6 months postoperative, the ROM in flexion was on average 82.9% in group I and 81.3% in group II. The difference, estimated at -2.327 [-13.657 ; 8.960], was not significant as the interval of credibility of the difference contained 0, with a 65.6% likelihood of being negative. The ROM in extension was on average 91.4% in group I and 88.6% in group II. The difference, estimated at -2.754 [-13.410 ; 7.602], was not significant as the interval of credibility of the difference contained 0, with a 70.2% likelihood of being negative.

The ROM in pronation was on average 100% in group I and 102% in group II. The difference, estimated at $+3.178$ [-5.242 ; 11.457], was not significant as the interval of credibility of the difference contained 0, with a 77.0% probability of being positive. The ROM in supination was on average 100% in group I and 97% in group II. The difference was estimated at -3.171 [-10.825 ; 4.537], which was not significant as the interval of credibility of the difference contained 0, with a 79.6% likelihood of being negative.

The pain level was on average 0.6/10 in group I and 1/10 in group II. The difference, estimated at $+0.106$ [-0.809 ; 0.977], was not significant as the interval of credibility of the difference contained 0, with a 61% likelihood of it being positive.

The QuickDASH score was on average 8.1/100 in group I and 17.2/100 in group II. The difference estimated at $+5.790$ [-2.934 ; 15.012], was not significant as the interval of credibility of the difference contained 0, with a 90.9% likelihood of being positive. The PREW was on average 6.2/100 in group I and 22/100 in group II. The difference, estimated at $+13.109$ [4.416 ; 22.779], was significant as the interval of credibility of the difference did not contain 0, with a 99.7% likelihood of it being positive.

The grip strength was on average 94.6% in group I and 73.6% in group II. The difference, estimated at -12.478 [-24.832 ; 0.538], was not significant as the interval of credibility of the difference contained 0 with a 97.1% likelihood of it being negative.

All fractures healed. No complications, nonunions or revision surgeries were noted in the two groups. We observed one secondary displacement of the die-punch fragment in each group on X-rays.

4. Discussion

When it comes to the surgical management of intraarticular displaced DRFs, the die-punch fragment is crucial for the sagittal stability of the radio-carpal joint and for preventing dorsal collapse [10]. Fixation of this fragment is crucial for avoiding secondary displacement [6] that can lead to complications such as limited pronation and supination [7,11] and post-traumatic arthritis when the gap is wider than 2 mm [12]. Since it is difficult to reduce the die-punch fragment through a simple volar approach, some authors use dorsal plates for reduction and fixation of DRFs [13]. The main complication of using dorsal plates is the risk of damaging the extensor tendons [14,15]. Other authors have demonstrated that volar plates have delivered better results than dorsal plates when used with this specific indication [16]. Some of these authors have tried to obtain better results with volar plates by combining them with Frag-Loc® compression screws (Acumed™). Those screws improve the quality of the reduction [17] and reduce the risk of secondary displacement [18] of the die-punch fragment in intraarticular DRF. The die-punch fragment was compressed thanks to the additional force applied by the anterior segment of the Frag-Loc® screw, which was applied to the plate on the posterior segment of the screw on the dorsal cortex of the radius. This technique has the same disadvantages as dorsal plates [15]. Our study sought to avoid these complications firstly by avoiding the additional dorsal approach and secondly by eliminating the plate's projection on the dorsal cortex of the radius. Although it is very difficult to extrapolate the biomechanical findings of stability to the clinical reality of motion, we sought to use a double-threaded compression screw to secure the fixation of the die-punch fragment.

A study conducted on cadaver bone consisted in recreating a C.2 fracture on 16 distal radiuses with an oscillating saw [18]. All the fractures underwent reduction and fixation with a locking volar plate (Acumed®). In the first 8 cases (group I), the die-punch fragment was fixed using the same locking screws as those used to fix the plate. In the other 8 cases, the die-punch fragment was fixed with a Frag-Loc® compression screw (Acumed™) (group II). The mechanics of the radiuses in both groups were observed and compared. After a cycle of

compressions in the axis of the radius, the results were similar in terms of solidity and rigidity, but the secondary displacement rate of the die-punch fragment was significantly lower in group II. These findings differ from our results. In fact, we did not observe any difference between the two groups. Despite the numbers and variables being comparable between the two studies, the discrepancy between our study and the cadaver study can be explained by the fact that a cadaver study is less complex than a clinical study conducted on patients. The compression vectors in the axis of the radius are more easily reproducible in a cadaver study than in a clinical study. Many other factors contribute to the final outcome in clinical studies, such as the vectors acting on the soft tissues and the morphological variability of the fractures assessed in a clinical study.

A second study was conducted on a case series of 48 patients who had type C.1 and C.2 fractures [17]. All fractures were treated by reduction and fixation with a volar locking screw (Acumed®). In the first 26 patients (group I), the die-punch fragment was stabilized and fixed with the same locking screw used to fix the plate. In the next 22 cases, the die punch fragment was fixed with a Frag-Loc® compression screw (Acumed™) (group II). On a postoperative CT scan, a gap persisted between the palmar fragment and the die-punch fragment. This gap was significantly reduced in group II. These results differ from our findings. In fact, although the patient in our case series had a wide age range (24 to 91 years), we did not observe any difference between the two groups in our study. Because it is very difficult to get a large series of similar cases, this discrepancy can also be explained by the fact that also complex C.3 type fractures were included in our case series and that the degree of displacement of the die-punch fragment is not taken into account by the AO classification, which makes it difficult to compare results between studies. The discrepancy can also be explained by the paucity of data which affects the statistical power of our study and by the small number of cases which make it difficult to conclude that when clinical results do not differ, probable step/gaps or secondary dislocation do not differ.

Our main hypothesis was not proven as the ROM in supination after the reduction and fixation of the die-punch fragment of a DRF with a standard locking screw was not improved

compared to the ROM in supination obtained with a double-threaded compression screw. The secondary hypotheses were not proven either, as the patients' pain level, QuickDASH, grip strength, and wrist ROM in flexion, extension and pronation were not improved by using a double-threaded compression screw.

5. Conclusion

Despite what several biomechanical studies have suggested, the use of double-threaded compression screws for die-punch fragment fixation in DRFs does not improve the clinical outcomes compared to standard locking screws.

Conflicts of Interest:

P.L. has conflicts of interest with Newclip Technics, Argomedical, Biomodex, Zimmer Biomet.

None of the other authors have conflicts of interest

Acknowledgements:

Erik Sauleau , “Méthodes en Recherche Clinique, Service de Santé publique”, Strasbourg University Hospitals, who performed the statistical analysis.

References

1. Schnependahl J, Windolf J, Kaufmann RA. Distal radius fractures: current concepts. *J Hand Surg Am* 2012;37:1718-25.
2. Wilcke MK, Hammarberg H, Adolphson PY. Epidemiology and changed surgical treatment methods for fractures of the distal radius: a registry analysis of 42,583 patients in Stockholm County, Sweden, 2004–2010. *Acta Orthop* 2013;84:292-6.
3. Kamei S, Osada D, Tamai K, Kato N, Takai M, Kameda M, et al. Stability of volar locking plate systems for AO type C3 fractures of the distal radius: biomechanical study in a cadaveric model. *J Orthop Sci* 2010;15:357-64.
4. Leung F, Zhu L, Ho H, Lu WW, Chow SP. Palmar plate fixation of AO type C2 fracture of distal radius using a locking compression plate-a biomechanical study in a cadaveric model. *J Hand Surg Br* 2003;28:263-6.
5. Osada D, Fujita S, Tamai K, Iwamoto A, Tomizawa K, Saotome K. Biomechanics in uniaxial compression of three distal radius volar plates. *J Hand Surg Am* 2004;29:446-451.
6. Ikeda K, Osamura N, Tada K. Fixation of an ulnodorsal fragment when treating an intra-articular fracture in the distal radius. *J Hand Surg Am* 2014;19:139-44.
7. Geissler WB, Fernandez DL, Lamey DM. Distal radioulnar joint injuries associated with fractures of the distal radius. *Clin Orthop Relat Res* 1996;327:135-46.
8. Lebailly F, Zemirline A, Facca S, Gouzou S, Liverneaux P. Distal radius fixation through a mini-invasive approach of 15 mm. PART 1: a series of 144 cases. *Eur J Orthop Surg Traumatol* 2014;24:877-990.
9. MacDermid JC, Turgeon T, Richards RS, Beadle M, Roth JH. Patient rating of wrist pain and disability: a reliable and valid measurement tool. *J Orthop Trauma* 1998;12:577-86.
10. Dy CJ, Wolfe SW, Jupiter JB, Blazar PE, Ruch DS, Hanel DP. Distal radius fractures: strategic alternatives to volar plate fixation. *Instr Course Lect* 2014;63:27-37.
11. Thomas BP, Sreekanth R. Distal radioulnar joint injuries. *Indian J Orthop* 2012;46:493-504.

12. Knirk JL, Jupiter JB. Intra-articular fractures of the distal end of the radius in young adults. *J Bone Joint Surg Am* 1986; 68:647-59.
13. Hamada Y, Gotani H, Hibino N, Tanaka Y, Satoh R, Sasaki K, Kanchanathepsak T. Surgical strategy and techniques for low-profile dorsal plating in treating dorsally displaced unstable distal radius fractures. *J Wrist Surg* 2017;6:163-9.
14. Rozental TD, Beredjiklian PK, Bozentka DJ. Functional outcome and complications following two types of dorsal plating for unstable fractures of the distal part of the radius. *J Bone Joint Surg Am* 2003;85:1956-60.
15. Wichlas F, Haas Np, Disch A, Macho D, Tsitsilonis S. Complication rates and reduction potential of palmar versus dorsal locking plate osteosynthesis for the treatment of distal radius fractures. *J Orthop Traumatol* 2014;15:259-64.
16. Ruch DS, Papadonikolakis A. Volar versus dorsal plating in the management of intra-articular distal radius fractures. *J Hand Surg Am* 2006;31:9-16.
17. Lee JI, Cho JH, Lee SJ. The effects of the frag-loc® compression screw on distal radius fracture with a displaced dorsoulnar fragment. *Arch Orthop Trauma Surg* 2015;135:1315-21.
18. Kanazawa T, Tomita K, Kawasaki K, Yagi T, Tanabe Y, Inagaki K. Comparison of locking and frag-loc® screws for fixation of die-punch fragments. *J Wrist Surg* 2018;7:205-10.

Figure legends

Fig. 1. Group I. All the distal screws were standard locking screws (*black arrows*).

Fig. 2. Group II. The die-punch fragment of the distal radius was fixed using a double-threaded cortical compression screw (*grey arrow*). The three other screws were standard locking screws (*black arrows*).

Fig. 3. X-rays of an intraarticular distal radius fracture (Patient number 6, table 1) treated by ORIF with a volar locking plate in which the die-punch fragment was fixed with a standard locking screw. From left to right: preoperative X-ray, intraoperative fluoroscopy, 6-month postoperative X-ray. Above: posteroanterior view. Below: lateral view.

Fig. 4. X-rays of an intraarticular distal radius fracture (Patient number 4, table 2) treated by ORIF with a volar locking plate in which the die-punch fragment was fixed with a double-threaded locking compression screw. From left to right: preoperative X-ray, intraoperative fluoroscopy, 6-month postoperative X-ray. Above: posteroanterior view. Below: lateral view

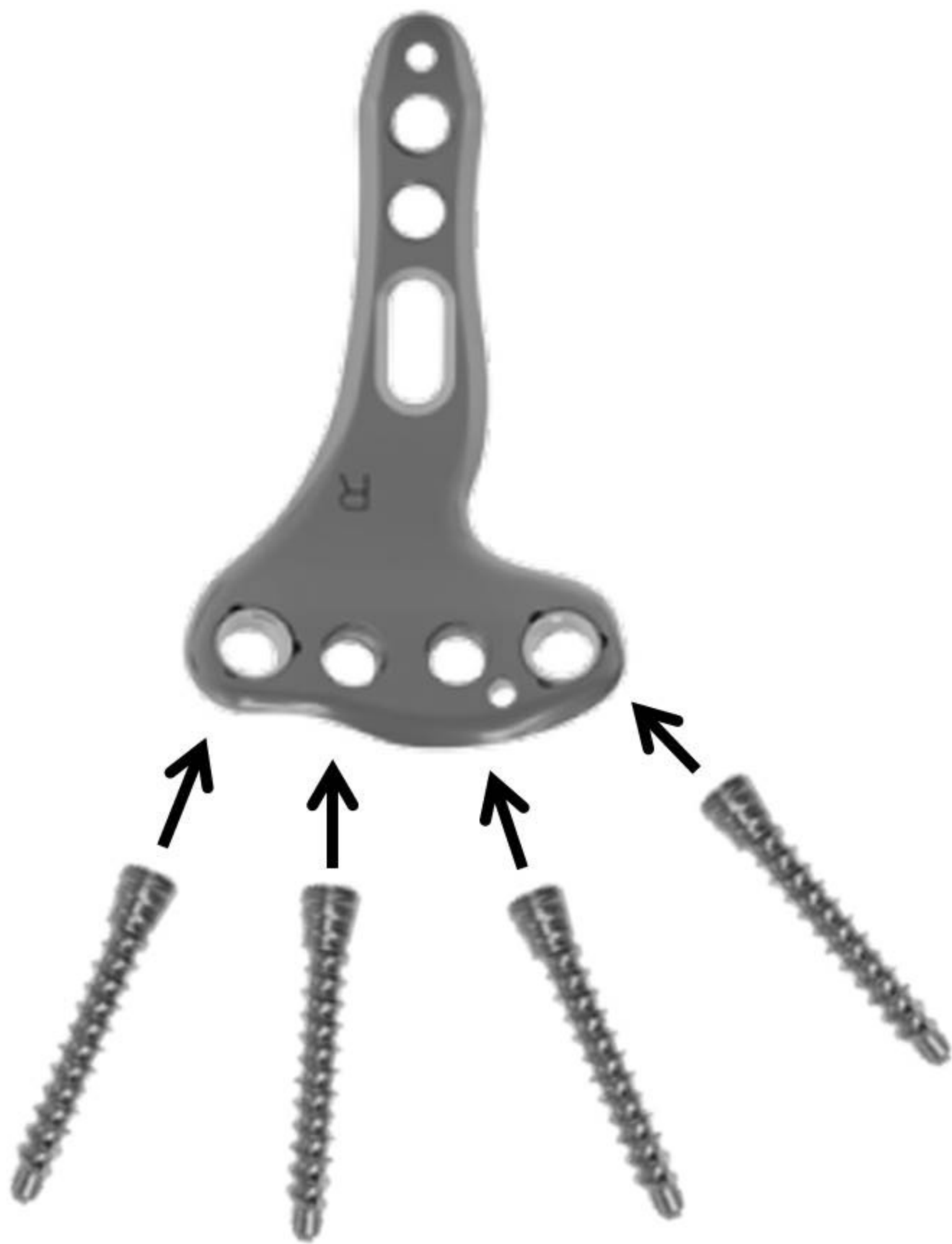
Table titles

Table 1. Case series of 10 distal radius fractures treated by open reduction internal fixation with volar plate and locking screw on the die-punch fragment (Group I)

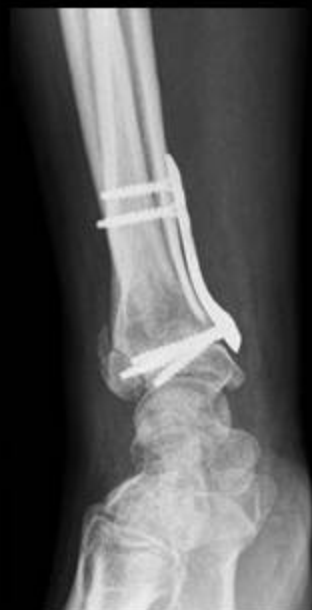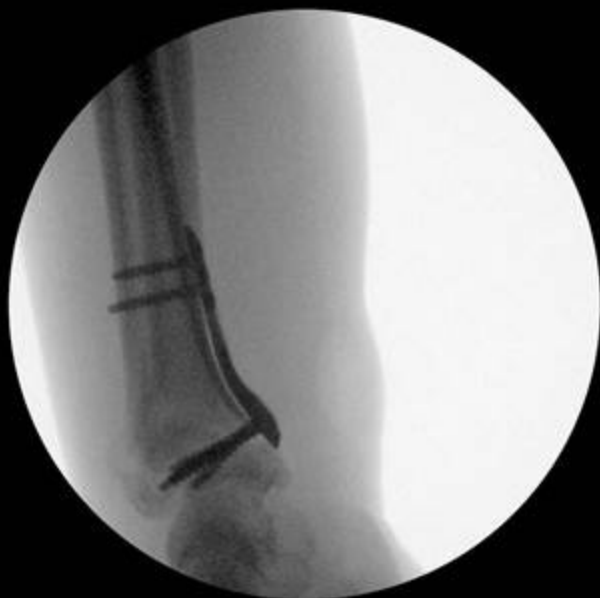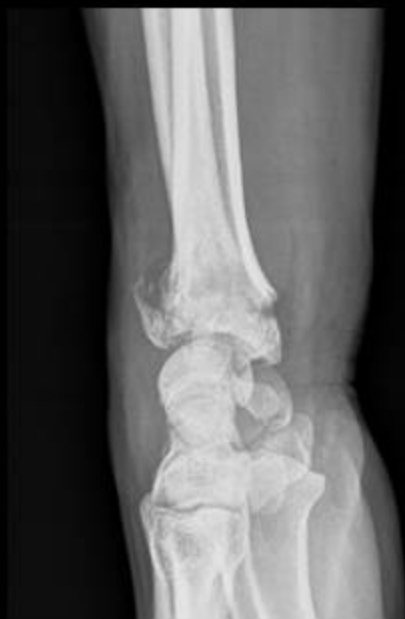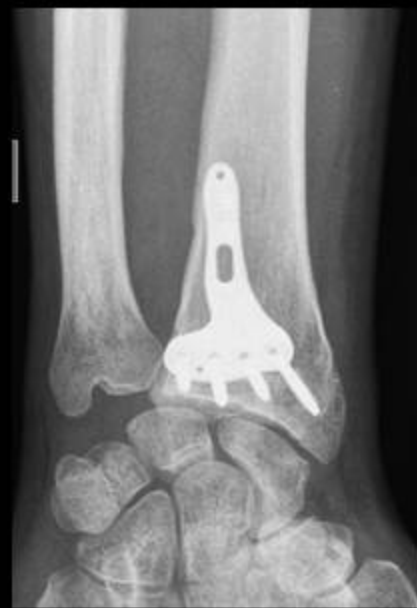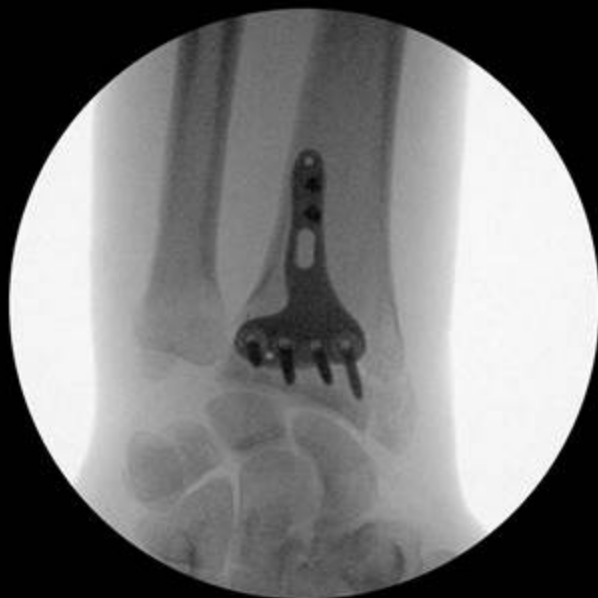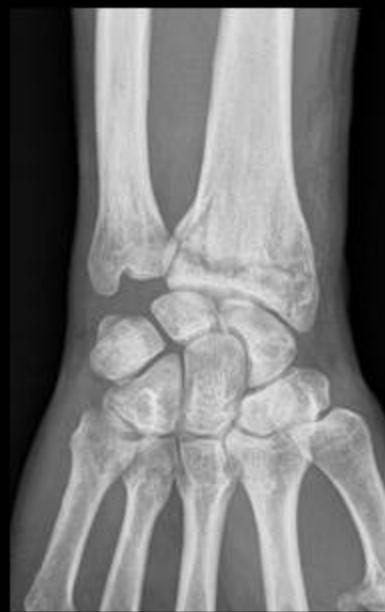Table 2. Case series of 9 distal radius fractures treated by open reduction internal fixation with volar plate and a double-threaded compression screw on the die-punch fragment (Group II)

Table 3. Results at 6 months' follow-up of 10 distal radius fractures treated by open reduction internal fixation with volar plate and locking screw on the die-punch fragment (Group I)

Table 4. Results at 6 months' follow-up of 9 distal radius fractures treated by open reduction internal fixation with volar plate and double-threaded compression screw on the die-punch fragment (Group II)



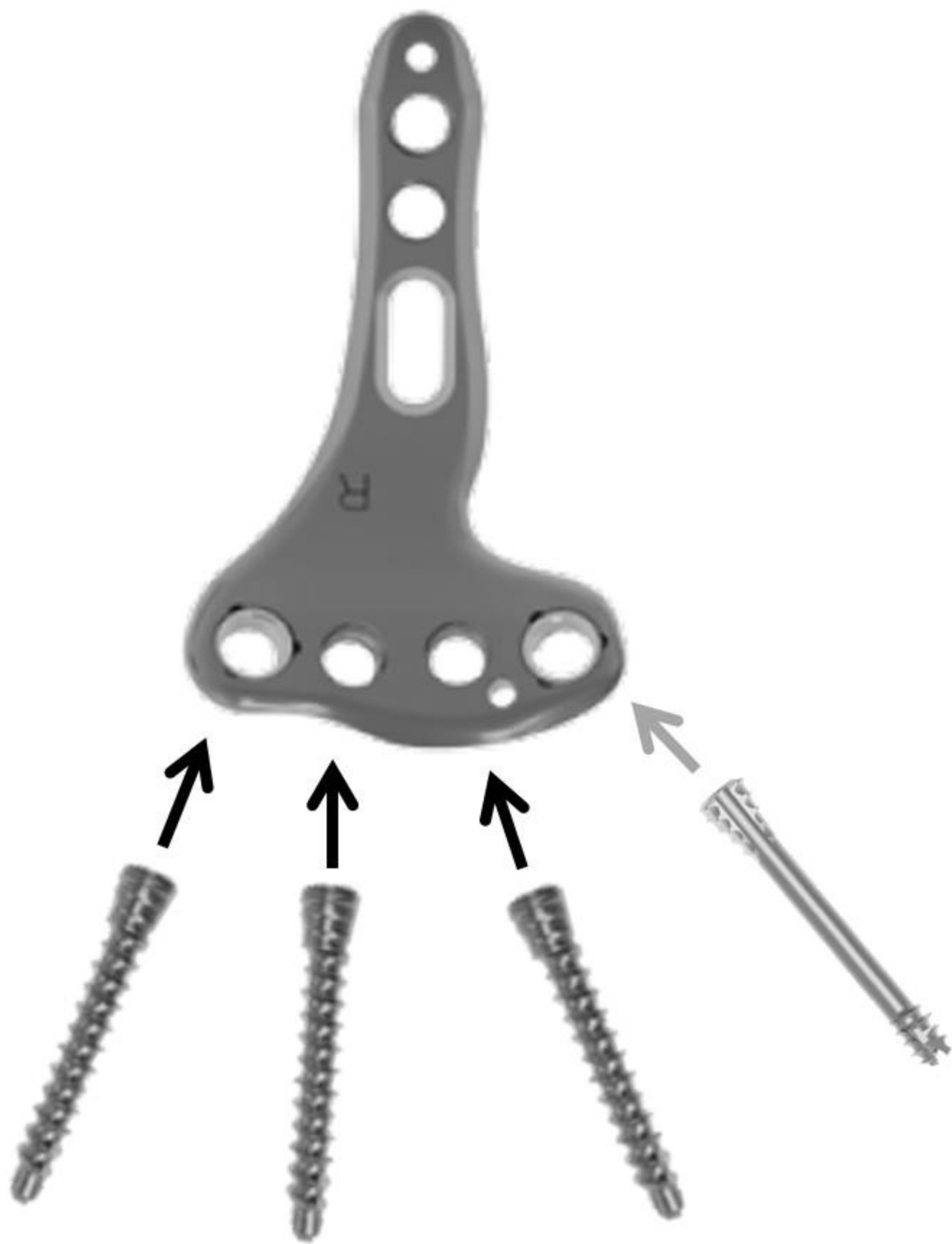



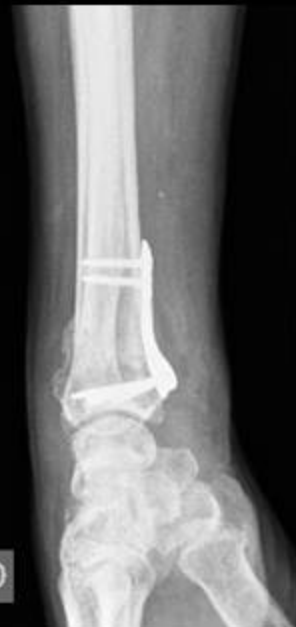
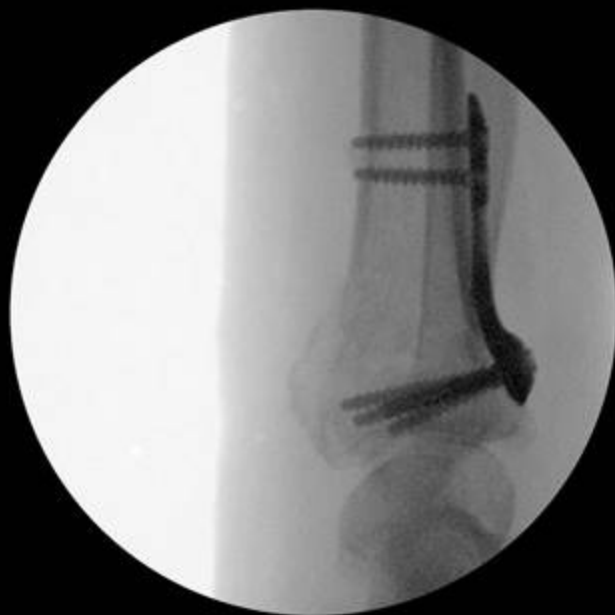
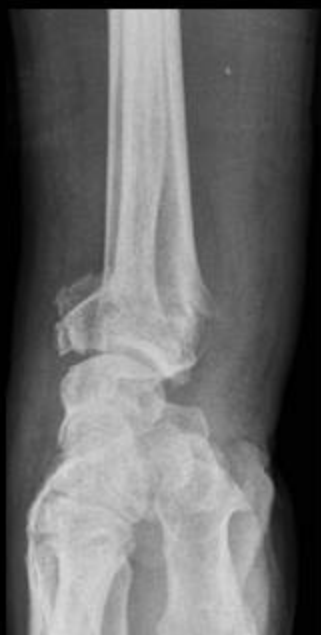
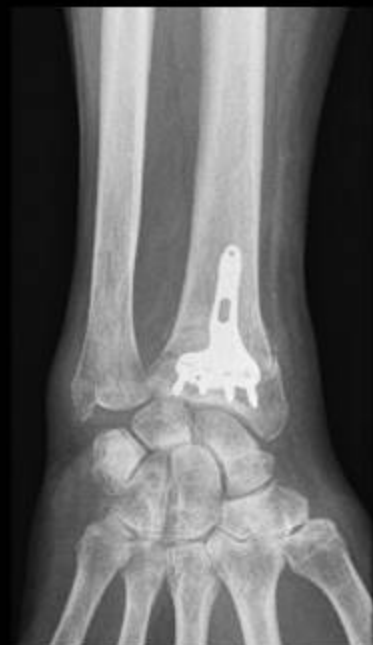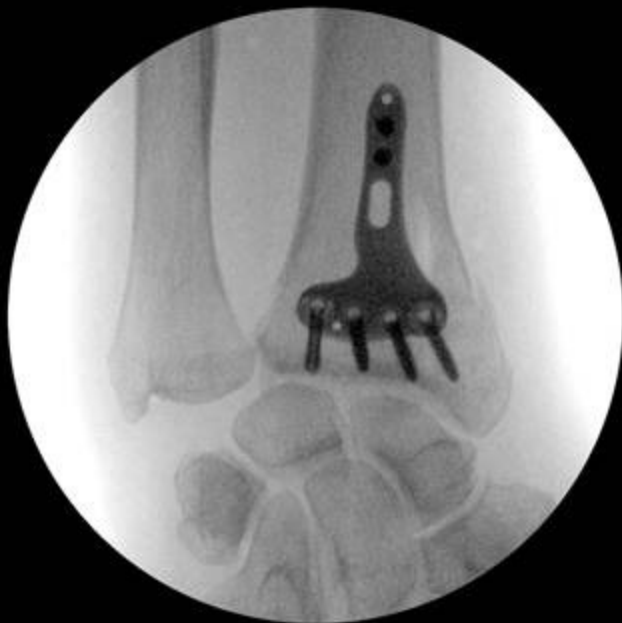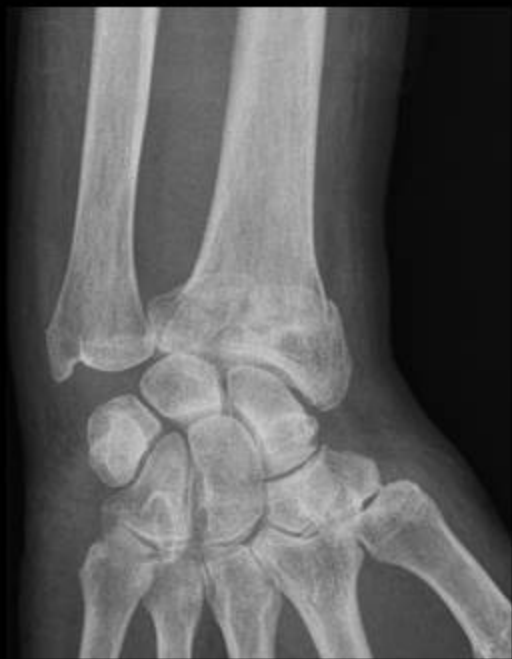Table 1. Case series of 10 distal radius fractures treated by open reduction internal fixation with volar plate and locking screw on the die-punch fragment (Group I)

Patient (n)	Age (years)	Gender (M/F)	Dominance (R/L)	Side injured (R/L)	A0 classification (C)
1	73	F	R	L	C1.2
2	28	F	L	R	C3.2
3	91	F	R	R	C1.1
4	73	M	R	R	C1.1
5	39	M	R	R	C2.2
6	47	M	R	R	C1.2
7	60	M	R	L	C1.1
8	68	F	R	R	C2.2
9	62	M	R	L	C1.2
10	77	F	R	L	C1.2

M: Male; *F*, female; *R*: right; *L*, left

Table 2. Case series of 9 distal radius fractures treated by open reduction internal fixation with volar plate and a double-threaded compression screw on the die-punch fragment (Group II)

Patient (n)	Age (years)	Gender (M/F)	Dominance (R/L)	Side injured (R/L)	AO classification (C)
1	41	F	R	L	C2.1
2	51	M	R	R	C1.1
3	24	M	R	R	C1.3
4	46	F	R	L	C1.2
5	80	M	R	L	C1.2
6	60	F	R	R	C1.2
7	52	M	R	L	C1.2
8	79	F	R	L	C2.2
9	67	M	R	R	C2.1

M: male; *F*: female; *R*: right; *L*: left

Table 3. Results at 6 months' follow-up of 10 distal radius fractures treated by open reduction internal fixation with volar plate and locking screw on the die-punch fragment (Group I)

Patient (n)	Follow-up (weeks)	Passive motion %				Pain (0–10)	QuickDASH (0–100)	PRWE (0–100)	Grip strength %	Secondary displacement (Y/N)
		F	E	P	S					
1	26	83	100	125	100	0	9.09	0	145	N
2	24	78	94	89	117	3	40.91	38	69	N
3	24	88	86	93	93	0	0	0	86	Y
4	22	100	100	100	100	0	2.27	5	83	N
5	24	79	92	81	106	0	0	0	114	N
6	24	79	100	107	107	0	13.64	5	68	N
7	25	59	79	100	100	2	2.27	10	89	N
8	23	75	100	100	100	1	11.36	4	100	N
9	27	94	100	100	88	0	0	0	92	N
10	22	94	63	100	92	0	2.27	0	100	N

%; compared to contralateral uninjured side; *F*: flexion; *E*: extension; *P*: pronation; *S*: supination; *Y*: yes; *N*: no

Table 4. Results at 6 months' follow-up of 9 distal radius fractures treated by open reduction internal fixation with volar plate and double-threaded compression screw on the die-punch fragment (Group II)

Patient (n)	Follow-up (weeks)	Passive motion %				Pain (0–10)	QuickDASH (0–100)	PRWE (0–100)	Grip strength %	Secondary displacement (Y/N)
		F	E	P	S					
1	24	93	79	107	106	0	6.82	12	82	N
2	29	72	94	106	100	0	18.18	16	84	N
3	26	50	63	94	94	3	45.45	52	55	N
4	24	100	100	100	75	0	25	22	67	N
5	31	77	75	93	93	1	11.36	16	79	N
6	24	59	93	107	107	0	15.91	23	73	N
7	24	100	93	100	100	0	0	12	86	N
8	32	81	100	100	100	3	6.82	23	69	Y
9	24	100	100	116	100	2	25	22	67	N

%; compared to contralateral uninjured side; *F*: flexion; *E*: extension; *P*: pronation; *S*: supination; *Y*: yes; *N*: no