



**HAL**  
open science

## Association of Mycoplasma Hominis and head and neck cancer with unknown primary

Sarah Atallah, Beatrice Berçot, Valérie Laurence, Caroline Hoffmann

### ► To cite this version:

Sarah Atallah, Beatrice Berçot, Valérie Laurence, Caroline Hoffmann. Association of Mycoplasma Hominis and head and neck cancer with unknown primary. European Annals of Otorhinolaryngology, Head and Neck Diseases, 2020, 137 (1), pp.69 - 71. 10.1016/j.anorl.2019.05.020 . hal-03490046

**HAL Id: hal-03490046**

**<https://hal.science/hal-03490046>**

Submitted on 21 Jul 2022

**HAL** is a multi-disciplinary open access archive for the deposit and dissemination of scientific research documents, whether they are published or not. The documents may come from teaching and research institutions in France or abroad, or from public or private research centers.

L'archive ouverte pluridisciplinaire **HAL**, est destinée au dépôt et à la diffusion de documents scientifiques de niveau recherche, publiés ou non, émanant des établissements d'enseignement et de recherche français ou étrangers, des laboratoires publics ou privés.



Distributed under a Creative Commons Attribution - NonCommercial 4.0 International License

## ASSOCIATION OF MYCOPLASMA HOMINIS AND HEAD AND NECK CANCER WITH UNKNOWN PRIMARY

Sarah Atallah (1), Beatrice Berçot (2), Valérie Laurence (3), Caroline Hoffmann (1)(4)\*

1. Département de chirurgie oncologique cervico-faciale, *Institut Curie, Université PSL, Paris 5e, FRANCE*

2. Département de microbiologie, Hôpital Saint Louis, Université Paris VII, Paris, France.

3. Département d'oncologie médicale, *Institut Curie, Université PSL, Paris 5e, FRANCE*

4. INSERM U932, Immunité et Cancer, *Institut Curie, Université PSL, Paris 5e, FRANCE*

### **\*Corresponding author:**

Email: [caroline.hoffmann@curie.fr](mailto:caroline.hoffmann@curie.fr) (Caroline HOFFMANN)

Adresse: Institut Curie  
Département de chirurgie oncologique cervico-faciale  
26, rue d'Ulm, 75248 PARIS Cedex 05  
FRANCE

*Institut Curie, Université PSL, Paris 5e, FRANCE*

## **Abstract**

### **Introduction**

Beside *HPV* infection, there is currently no evidence of association between head and neck squamous cell carcinomas and microbial infections. We report the case of a cervical squamous cell carcinoma by *Mycoplasma hominis*.

### **Case summary**

A 20-years-old woman, consulted for a swelling on the left cervical side. Clinical examination found a large fixed mass. Biological tests found no evidence of infection. Biopsies of the cervical lesion diagnosed an HPV negative squamous cell carcinoma. Microbiological tests of 16sRNA identification showed the presence of *Mycoplasma hominis* in the 3 specimens. The patient was treated by induction chemotherapy associated to antibiotherapy, followed by chemo-radiotherapy.

### **Discussion**

The present case suggests that oropharyngeal infection by *Mycoplasma hominis* might be more frequent than expected, that 16sRNA is an efficient technic to isolate this pathogen and finally that further studies are required to document its potential oncogenic role in head and neck squamous cell carcinomas.

### **Keywords:**

Mycoplasma, infection, squamous cell carcinoma, cervical lymphadenopathy, 16S RNA

## Introduction

Beside Human papilloma virus (HPV) infection implicated as an oncogenic factor in oropharyngeal head and neck squamous cell carcinomas (HNSCC) [1], there is currently no evidence of association between HNSCC and microbial infections. To our knowledge, we report the first case of a cervical SCC node with unknown primary, which was HPV negative, but colonized by *Mycoplasma hominis* (*Mh*).

## Case report

A 19-years-old woman, with no history of smoking or alcohol use, consulted for a swelling of the left side of her neck. Clinical examination found a large painless fixed mass and no fever. Biological tests found no evidence of infection. Computerized tomography scan (CT scan) revealed a 10cm mass, with a hypodense core and a peripheral enhancement, invading the cervical muscles and surrounding the primary carotid artery. Ultrasound-guided biopsies (3 samples) of the unresectable cervical lesion diagnosed an HPV negative (p16 and Polymerase Chain Reaction (PCR)) squamous cell carcinoma. Because of the young age of the patient, an infection was still suspected and microbial tests were performed on the same biopsies. The 16S ribosomal RNA (16s rRNA) microbiological testing showed the presence of *Mh* in all the specimens: PCR product's sequence showed 100% homology with the gene coding for *Mh* 16S rRNA (GenBank accession number AF443616.3, BLAST search). The serologies performed, HIV, B and C hepatitis were negative. PCR technique associated to mass spectrometry (ESI-MS) found no *Mh* in an oropharyngeal biopsy performed secondarily. Cultures from genital tract samples were negative for *Mh*.

An MRI, a TEP-CT and a left tonsillectomy were performed, but were unable to identify the primary carcinoma (Fig. 1).

The patient was treated by induction chemotherapy (Docetaxel-Cisplatin-5FU) associated to fifteen days of antibiotherapy (josamycin) and followed by chemo-radiotherapy. After 13 months of follow-up, there is no evidence of recurrence (Fig. 1). The diagnosis of Fanconi anemia was also excluded by clinical examination, blood test and skin biopsy.

## **Discussion**

Carcinoma of unknown primary involving cervical nodes in level II to IV are usually related to an oropharyngeal primary tumor [2]. When imaging is not able to identify the primary tumor, tonsillectomy is recommended in order to identify small tumors hidden inside the tonsil, together with HPV testing. In the present case involving a 19-year old patient, additionally to the histological analyses, microbial tests were also performed because the first hypothesis after clinical examination was an infection and not a cancer.

These microbial tests identified *Mh*, which is a common commensal bacterium of the genitourinary tract. Sackel et al. reported that *Mh*, *Ureaplasma urealyticum* and *Neisseria gonorrhoeae* were found in 14.3%, 14.8% and 4,9% of the pharyngeal samples obtained from 1044 men and women attending clinics in Boston, USA, respectively [3]. These results were obtained by cultures. Additionally, they showed that colonization alone was not necessarily associated with sore throat or other upper respiratory diseases [3]. Beyond colonization of the oropharyngeal tract by this genital pathogen, two reports described an association with infection. One study showed that the rate of mycoplasma isolation was significantly higher in children undergoing tonsillectomy for recurrent adenotonsillitis (34.5%) than in the cases of tonsillectomy for sleep apnea (20%) [4]. *Mh* infections, particularly extra-genital infections, are probably underdiagnosed for 3 main reasons: (i) the test is not performed, (ii) the culture technique is long and difficult, and (iii) 16sRNA is not systematically used.

The 16S rRNA technique is a recent, reliable and reproducible tool for bacteria identification [5], now routinely used for pathogen identification, particularly in cases of slow-growing, unusual, fastidious bacteria and for bacteria that are poorly differentiated by conventional methods. This technique consists of amplification and sequencing the *RRS* gene coding for 16S rRNA, a chromosomal gene of about 1500 base pairs, present in all bacterial species (universal gene). The 5' and 3' ends are preserved in all bacteria and are used to link the two complementary universal primers that initiate the PCR reaction. The gene's sequence is specific to each species and allows their precise identification by sequencing the amplification product. For each sequence obtained, homologous sequences are searched in databases via the BLASTN programs of the National Center for Biotechnology Information (NCBI) [6]. Contamination is one limit of this technique. In the present case, this bias has been excluded by using a standard hybridation technique for *Mh* identification, and by the repeated biopsies confirming the colonization.

The role of mycoplasma infections in carcinogenesis remains a matter of debate. Recent epidemiologic, genetic, and molecular studies suggest that mycoplasma infection and inflammation may initiate prostate cancer. Namiki and al. showed that Mycoplasma chronic infection (19 weeks of culture with benign human prostate cells) promoted malignant transformation resulting from a dysregulation of genes such as Ras, Myc or P53 [7]. Logunov and al., in a model of rat fibroblasts infected by *Mycoplasma arininis*, showed that the bacteria suppressed the transcriptional activity of p53 and activated the Nf-kB pathway, eventually inducing a Ras-dependent malignant transformation. This finding indicates that mycoplasma infection can act as an equivalent of p53-suppressing oncogene [8] (Fig. 2).

## **Conclusion**

This report describes an original case of association between *Mh* and cervical SCC in a young patient. It may suggest that, besides HPV infections, other genital pathogenic agent may be related to HNSCC. Further studies are required to document this association and the hypothesis of a potential oncogenic role.

## **Disclosure statement**

Dr Caroline Hoffmann: consultant and honorary, Nanobiotix. No disclosure related to this publication.

## References

- [1] Gillison ML, Koch WM, Capone RB, Spafford M, Westra WH, Wu L, Zahurak ML, Daniel RW, Viglione M, Symer DE, Shah KV, Sidransky D. Evidence for a causal association between human papillomavirus and a subset of head and neck cancers. ] J Natl Cancer Inst. 2000 May 3;92(9):709-20.
- [2] Chernock RD, Lewis JS. Approach to metastatic carcinoma of unknown primary in the head and neck: squamous cell carcinoma and beyond. Head Neck Pathol. 2015 Mar;9(1):6-15.
- [3] Sackel SG, Alpert S, Fiumara NJ, Donner A, Laughlin CA, McCormack WM. Orogenital contact and the isolation of *Neisseria gonorrhoeae*, *Mycoplasma hominis*, and *Ureaplasma urealyticum* from the pharynx. Sexually transmitted diseases. 1979;6:64-68.
- [4] Charnock DR, Chapman GD, Taylor RE, Wozniak A. Recurrent tonsillitis. The role of *Chlamydia* and *Mycoplasma*. Archives of otolaryngology-Head and neck surgery 1992;118:507-508.
- [5] Woo PC, Lau SK, Teng JL, Tse H, Yuen KY. Then and now: use of 16S rDNA gene sequencing for bacterial identification and discovery of novel bacteria in clinical microbiology laboratories. Clinical Microbiology and infection. 2008;14:908-934.
- [6] Patel J-B. 16S rRNA gene sequencing for bacterial pathogen identification in the clinical laboratory. Molecular diagnosis. 2001;6:313–321.
- [7] Namiki K, Goodison S, Porvasnik S, Allan RW, Iczkowski KA, Urbanek C, Reyes L, Sakamoto N, Rosser CJ. Persistent exposure to *Mycoplasma* induces malignant transformation of human prostate cells. PLoS One. 2009;10:1371.

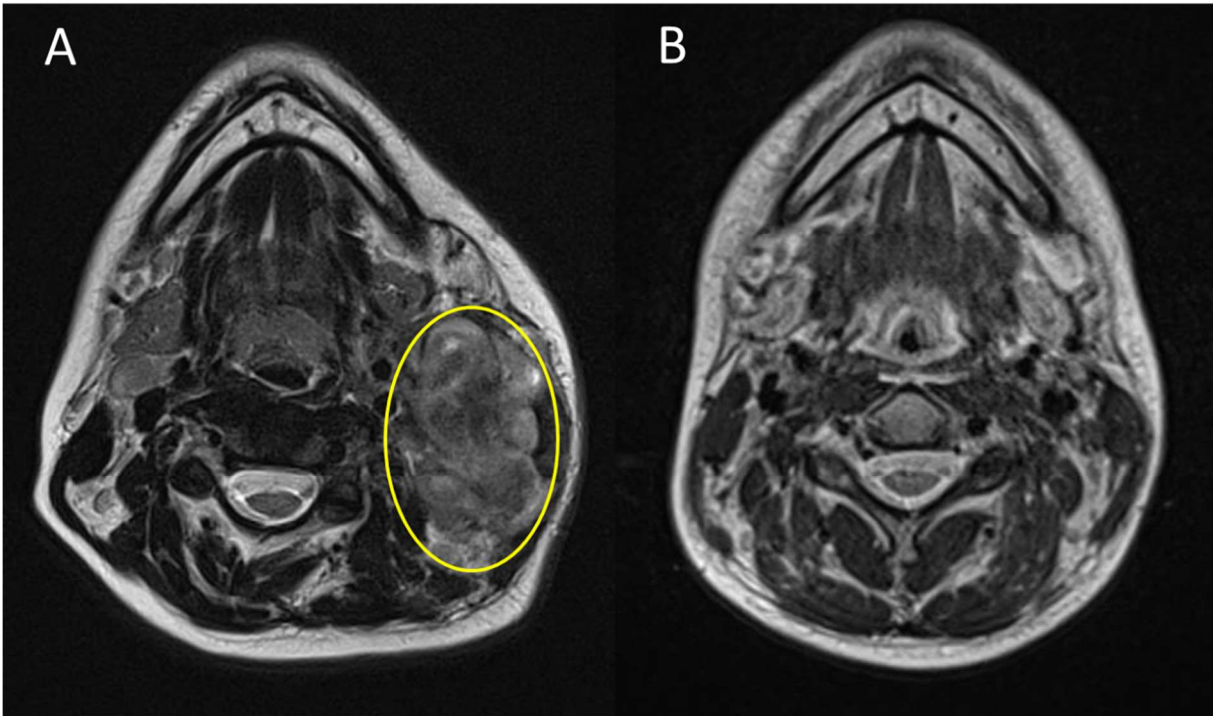


[8] Logunov DY, Scheblyakov DV, Zubkova OV, Shmarov MM, Rakovskaya IV, Gurova KV, Tararova ND, Burdelya LG, Naroditsky BS, Ginzburg AL, Gudkov AV. Mycoplasma infection suppresses p53, activates NF-kappaB and cooperates with oncogenic Ras in rodent fibroblast transformation. *Oncogene*. 2008 Jul 31;27(33):4521-31

Figure 1 – Cervical MRI before treatment (A) and after 13 months of follow-up (B)

Figure 2 – Schematic presentation of the three proposed mechanisms by which *Mycoplasma* sp. may promote tumor progression: epigenetic changes, inhibition of p53 pathway, and activation of NFkb pathway.

Figure 1 – Cervical MRI before treatment (A) and after 13 months of follow-up (B)



**Figure 2 – Schematic presentation of the three proposed mechanisms by which *Mycoplasma sp.* may promote tumor progression: epigenetic changes, inhibition of p53 pathway, and activation of NFkb pathway.**

