



HAL
open science

Forefoot malformations, deformities and other congenital defects in children

Virginie Rampal, Fabienne Giuliano

► **To cite this version:**

Virginie Rampal, Fabienne Giuliano. Forefoot malformations, deformities and other congenital defects in children. *Orthopaedics & Traumatology: Surgery & Research*, 2020, 106, pp.S115 - S123. 10.1016/j.otsr.2019.03.021 . hal-03490023

HAL Id: hal-03490023

<https://hal.science/hal-03490023>

Submitted on 21 Jul 2022

HAL is a multi-disciplinary open access archive for the deposit and dissemination of scientific research documents, whether they are published or not. The documents may come from teaching and research institutions in France or abroad, or from public or private research centers.

L'archive ouverte pluridisciplinaire **HAL**, est destinée au dépôt et à la diffusion de documents scientifiques de niveau recherche, publiés ou non, émanant des établissements d'enseignement et de recherche français ou étrangers, des laboratoires publics ou privés.



Distributed under a Creative Commons Attribution - NonCommercial 4.0 International License

Review article

Forefoot malformations, deformities and other congenital defects in children

Virginie **Rampal**, Fabienne **Giuliano**

Hôpitaux pédiatriques de Nice CHU-Lenval, 59 avenue de la Californie, 06000 Nice, France

Corresponding author:

Dr Virginie Rampal, MD PhD

Pediatric orthopedics

0492030541

rocher-rampal.v@pediatrie-chulenal-nice.fr

Dr Fabienne Giuliano, MD

Medical genetics

Abstract

Congenital pathologies of the forefoot encompass two broad entities with vastly different treatments and prognosis: malformations, which occur during the embryonic period and cause anatomical defects, and deformations, which occur during the fetal period on a foot that is configured normally. These deformities are more easily cured when they occur later during the fetal period. When the anomaly is bilateral, a genetic origin must be considered. There are two main entities under the term “deformity”: metatarsus adductus and skewfoot (aka “Z”-foot or serpentine foot). Within malformations are brachydactyly (transverse defects), longitudinal defects, syndactyly, polydactyly, clinodactyly and macrodactyly. Among other forefoot abnormalities are hallux valgus, which rarely presents in congenital form, and for which conservative treatment is sometimes sufficient. Also in this group are sequelae of amniotic band constriction, forefoot anomalies secondary to the treatment of congenital pathologies (talipes equinovarus and congenital vertical talus) and nail-related pathologies (ingrown toe nail and incorrect nail position).

Keywords

Child, congenital defect, forefoot, metatarsus varus, skewfoot, hallux valgus, toe anomaly, nail pathology, surgery

1. Introduction

Congenital pathologies of the forefoot encompass two broad entities with vastly different treatments and prognosis: malformations, which occur during the embryonic period and cause anatomical defects, and deformations, which occur during the fetal period on a foot that is configured normally. These deformities are more easily cured when they occur later during the fetal period.

Their classification is typically based on the distinction between defective formation (agenesis, brachymetatarsia, ectromelia) and excessive formation (poly- or macrodactyly), differentiation defects (syn-, clino-, camptodactyly), growth disturbances (metatarsus adductus, skewfoot, hallux valgus) and nail-related pathology.

Through this lecture, and for each disease class, we will aim to answer the following questions:

- Which treatment methods have been proven and which can be recommended?
- Which indications must be retained based on patient age and the severity of the deformity?

2. Deformities

This consists of two separate entities: metatarsus adductus and skewfoot. A meticulous clinical examination is needed at birth to differentiate between these two conditions.

2.1. Metatarsus adductus

Metatarsus adductus ^{1,2} (MA) is a common defect impacting 0.2% of births that is located solely in the foot's transverse plane. It consists of adduction of the metatarsals at the Lisfranc joint. Thus there is a relative deviation of the forefoot with respect to the hindfoot, which results in a more or less prominent concavity of the medial side and a convexity of the lateral side, without deformity in the frontal or sagittal planes. The base of the 5th metatarsal is prominent, the medial side of the foot concave and the lateral side convex. There is no dorsolateral bump visible on the clinical examination. To describe this purely transverse deformity, it is more appropriate to use the term "metatarsus adductus"² than "metatarsus varus" (name used by Kite³ because the forefoot supinates when unloaded).

The most highly used classification is the one by Bleck⁴, which combines the severity (classified as minimal, moderate or severe, based on a line bisecting the heel through the 3rd toe, 4th toe or beyond) and reducibility (reducible, partially reducible and rigid depending on the abduction above, on or below this bisecting line). But while this classification is very precise clinically, it has no prognostic value. Radiologically, the 1st metatarsal is deviated medially and the angle between the 1st and 2nd metatarsal is increased⁵.

It only self-corrects in moderate forms. If it does not spontaneously resolve in the first weeks of life, nonoperative treatment (such as cast⁵, curved hypercorrection pads, splint or strapping^{6,7}, with correction time a function of severity) must correct the deformity before the child starts walking. If nonoperative treatment fails, or the child is more than 4 years of age at the time of diagnosis, surgical correction should be proposed. Complete tarsometatarsal release proposed by Heyman is no longer recommended due to its potential for inducing arthritis⁸. The Cahuzac procedure combines opening of the cuneometatarsal joint capsule at the 1st ray with abduction osteotomy of metatarsals 2, 3 and 4.

Good outcomes with this percutaneous technique have been reported⁹, thus reducing the risk of poor wound healing and the length of hospital stay. Nevertheless, careful analysis of radiographs reveals the apex of the deformity is generally located at the medial cuneiform bone (more proximal than the base of the 1st metatarsal). Thus the preferred technique appears to be an opening-wedge osteotomy of the 1st cuneiform using a bone graft, in combination with closing-wedge osteotomy at the base of the 2nd to 5th metatarsals¹. However, we must be aware that osteotomies performed at the 1st cuneiform can impact the hindfoot (elevation of foot's medial arch, without lengthening of medial column due to excessively tight plantar fascia¹⁰), which may then require partial plantar fasciotomy.

2.2. Skewfoot

Two elements are specific to skewfoot¹¹: a clinically obvious dorsolateral bump on the midfoot (Figure 1), which corresponds to the intermediate (Cu2) and lateral (Cu3) cuneiform bones, and cuneometatarsal subluxation of the 1st ray (Cu1) visible on radiographs (Figure 2, 2A).

In children who have started walking, skewfoot is characterized by angular concavity of the medial side of the foot (Figure 2B). The lateral side is convex; there is no abnormality in the frontal plane and the hindfoot is not deformed^{12,13}. In some cases, a medial hollow is visible (which is the only sagittal defect) or the ankle is excessively mobile¹⁴.

Radiologically (Figure 2B), skewfoot consists in angular adduction of the medial column in the Lisfranc joint, with cuneometatarsal subluxation (or even dislocation) of the 1st ray. The medial cuneiform has a trapezoid shape with lateral base with a neo-articular facet between the base of the 1st metatarsal and the medial face of the medial cuneiform. This kinking of the medial column results in the typical Z-shaped alignment between the longitudinal axis of the 1st metatarsal, the three cuneiform bones and the cuboid. Laterally, the metatarsals follow the deformity of the 1st ray (adduction and proximal metaphysodiaphyseal curvature). The navicular is translated laterally relative to the head of the talus. There are no anomalies in the hindfoot¹¹ (alignment of lateral edges of calcaneus and cuboid).

Nonoperative treatment is used in newborns. It is based on physical therapy, with casting, pads and splints applied to the leg and foot¹³. In addition, corrective manipulations (including dorsal pressure on the bump) identical to the ones used for MA are used here.

In older children (after 18 months of age), or if nonoperative treatment fails, surgical treatment is proposed. Between 18 months and 6 years, it consists of soft tissue release in the medial column¹⁵. Correction of the Cu-M1 subluxation requires subtotal capsulotomy (medial, dorsal, plantar) between the base of M1 and the medial cuneiform. To realign the medial ray completely, a medial cuneonavicular capsulotomy can also be performed. The bump is corrected through direct pressure, once the capsule has been opened. The correction of the 1st ray (with joint gapping) and the bump is maintained by applying two K-wires in a cross configuration. The last step is casting. If the lateral metatarsals are also deformed, an osteotomy should be done.

Beyond 6 years of age, a medial-opening osteotomy of the medial cuneiform or the base of the 1st metatarsal is proposed (being careful of the growth plates), followed by osteotomy of the last four metatarsals¹⁶.

Another option is a lateral-closing osteotomy of the cuboid combined with medial and plantar opening of the three cuneiform bones with interposition of bone graft taken from the cuboid. The two osteotomy lines must be connected to help correct the lateralization of the mid-forefoot relative to the mid-

hindfoot inherent to closure of the cuboid osteotomy. To correct the commonly observed hollow, the plantar fascia is selectively transected through a short plantar incision. Lastly, lengthening with transection of the white/red portion of the abductor hallucis muscle corrects the hallux adduction related to medial column lengthening.⁶ In all cases, it is essential to correct the clinical bump and to maintain the correction with two K-wires before casting.

In summary, a meticulous clinical examination is needed to differentiate between MA and skewfoot. The diagnosis is confirmed by radiographs. Evidence of the two specific signs of skewfoot means that nonoperative treatment should be started right away. If this fails, surgical treatment consists of soft tissue release in children less than 6 years of age, and mid-foot osteotomy procedures in older children.

3. Malformations

Toe defects caused by a malformation are a common reason for consultation. The defect must be identified, while looking for any associated defects that may place the patient in the context of a syndrome. One should always suspect a genetic anomaly when the congenital defect is bilateral (even when very asymmetric) or when it is unilateral¹⁷ if it falls within a malformation syndrome.

3.1. Brachydactyly: transverse stoppage

This is a segmental agenesis, of which the most frequent form is brachymetatarsia. It affects, in decreasing order of frequency, the 4th, 3rd and 1st toe. It corresponds to a premature epiphysiodesis of the metatarsal, with the shortness appearing during growth. The clinical signs are generally visible starting at 4 years of age. Bilateral forms are common (45% to 70%) and the sex ratio is 15–25 girls to 1 boy¹⁸. We can differentiate between isolated and malformation syndrome-related brachydactyly.

3.1.1. Isolated

Type A, B and C brachydactyly affects the hands, with no associated malformations in the feet. Type D affects only the distal phalanx of the thumb or hallux, which is short and wide. Type E consists of shortening of the metacarpals and phalanges combined with shortening of the metatarsals and the distal phalanx of the thumb or hallux. The transmission is autosomal dominant, with no mutations identified for types D and E.

3.1.2. Syndrome-related

Type D brachydactyly can appear in the context of disease syndromes, especially Rubinstein Taybi syndrome (associated with distinctive facial dysmorphism – arched brows, long eyelashes, oblique palpebral fissures, aquiline nose, columellar protrusion, gothic palate, micrognathia, and language delay and/or intellectual disability).

The syndrome-related form of type E brachydactyly is mainly encountered in three genetic backgrounds:

- Turner syndrome (girls with delayed growth and primary amenorrhea, confirmation by the 46,XO karyotype)
- Albright's hereditary osteodystrophy, related to the *GNAS* gene (delayed intra-uterine growth, small post-natal height, roundish face, excess weight, subcutaneous ossifications, irregular

intellectual disability)

- The 2q37 microdeletion syndrome – fairly superimposable without bone lesions but with a consistent intellectual disability.

From a treatment perspective, improving the appearance is often requested, even if excessive loading on the head of the metatarsal can cause discomfort. Surgery is only recommended around 12 years of age, once the metatarsals have finished growing¹⁹. Two techniques can be used:

- extemporaneous lengthening²⁰ – however, the lengthening must be less than 15 mm (25% of length) because of the risk of nonunion¹⁸;
- progressive lengthening using an external fixator²¹. In this case, it is recommended to bridge the MTP with a K-wire or the external fixator to prevent MTP joint subluxation. The osteotomy must be performed with an osteotome¹⁹, with 1 mm lengthening per day. Union is slow (50 to 100 days).

Several complications have been documented (stiffness, angular deformity, infection) that impact the 1st metatarsal more than the 4th metatarsal.

A recent publication described encouraging results of lengthening done with an internal device implanted on the metatarsal's periosteum²². Another²³ combined several procedures: extemporaneous lengthening of the shortest metatarsals plus shortening of the longest metatarsals and toe phalanges to restore two well-matched arches (metatarsal heads and toe extremities); however these techniques have not been evaluated sufficiently to be recommended.

3.2. Longitudinal defects

These are more general pathologies, falling in the context of ectromelia. We can differentiate between tibial (agenesis or internal hypoplasia), fibular (external) and central (ectrodactyly or median clefts of the foot) ectromelia. In the first two cases, the absence of a toe is an epiphenomenon, which is usually treated with orthopedic shoes if necessary, depending on the overlying malformations.

Central isolated and unilateral ectromelia (longitudinal mesoaxial) are often sporadic. When bilateral (even if highly asymmetric) or also affecting the hands, they fall in the context of polymalformation disorders such as split hand/foot malformation (SHFM) or EEC syndrome (ectrodactyly, ectodermal dysplasia, and orofacial clefts (cleft lip/palate)). At least six genetic locations have been described with X-linked autosomal dominant or recessive inheritance (in particular for the *TP63* gene responsible for SHFM4 and EEC3 syndrome).

The classification proposed by Blauth and Borisch differentiates between the clinical forms based on the number of metatarsals visible on radiographs at birth.

Surgical treatment must be carried out early on to limit the psychological consequences and to allow sufficient time for remodeling of the foot after the procedure.

The classification by Abraham et al.²⁴ provides a system for treatment:

Type I – partial central cleft (Blauth & Borisch type 1 to 4): syndactylization of soft tissues + correction of the hallux valgus as needed.

Type II – complete tarsal cleft (type 5): syndactylization of soft tissues + osteotomy of 1st ray as needed.

Type III – rays 1 to 4 completely absent (type 6): no surgery on forefoot.

Tani et al.²⁵ proposed simple closure of the cleft for Blauth & Borsich types 1 to 3, and a silicone block graft to correct the bone defect in cases of type 4 to 6.

3.3. Syndactyly

These are common in the feet and are caused by a mesoderm differentiation disorder (6 to 8 gestational weeks). We must differentiate between simple syndactyly (soft tissues) from complex ones (bone fusion, which may also affect the metatarsals) and complete ones (to the pulp) from partial ones.

The 2nd web space is more frequently impacted. Isolated, it is transmitted by an autosomal dominant mode. Nevertheless, it is found in 95% of patients who have Smith-Lemli-Opitz syndrome (feet and/or hand polydactyly, intellectual disability, pre- and post-natal growth delay, microcephaly, abnormal sexual development of boys, and a variable spectrum of malformations: cleft lip/palate, cardiac malformation, brain malformation, etc.). This pathology is caused by defective cholesterol synthesis. The diagnosis is based on 7-dehydrocholesterol assay results. When it affects the 1st web space, the 1st toe must be released to allow free propulsion of the foot during walking²⁶.

Similarly, when the affected toes vary greatly in size, surgical treatment can be proposed to prevent impingement of the longest toe in shoes (flexion deformity due to adhesion with the shortest toe). The treatment is identical to the one used in the upper limb. The family must be warned of the greater wound healing risk and the risk of cheloid scars. For the other web spaces, there are no functional consequences, thus observation is an acceptable treatment.

3.4. Polydactyly

When isolated, it predominantly affects the 5th toe and hallux (Figure 3). It can also occur in the context of syndromes such as Greig's (polysyndactyly and macrocephaly) and Pallister Hall's (mesoaxial polydactyly, hypothalamic hamartoma and bifid epiglottis). The *GLI3* gene is responsible for this condition. Preaxial polydactyly can also occur in the context of orofaciogigital syndromes (variable involvement of the upper limbs and oral cavity (cleft lip/palate, split tongue, etc.)). Postaxial polydactyly can occur in the context of ciliopathy (pathologies related to defects of the cilia) such as Bardet-Biedl syndrome or Joubert syndrome, except for other specific characteristics (kidney disorders, retinopathy, cerebellum involvement).

3.4.1. Hallux

Preaxial polydactyly (hallux duplication) must lead to – when possible – amputation of the most lateral hallux to avoid having a scar on the medial side of the foot, which interferes with wearing shoes. It can be done in combination with realignment osteotomy of the metatarsal head, along with secondary lengthening surgery of the metatarsal.

We must also be aware of a rare condition²⁷ – combination of hallux duplication with congenital bowing of the tibia: this varus curvature in the middle of the tibia resembles congenital nonunion. The presence of 1st ray duplication, even in a minor form, brings us to suggest the tibial bowing is non-dystrophic and to order a CT scan to demonstrate an atypical tibia duplication with no risk of progressing to nonunion.

3.4.2. Other toes

“Floating” or “pendulum” toes must be excised under local anesthesia during the first few weeks of life. For the other forms, the alignment, syndactyly and nail problems must also be resolved in a single surgical procedure. It is important to resect the surplus bone elements in an extraperiosteal manner to

avoid the development of non-vascularized bone fragments. In general, surgical treatment must be done before the child starts walking, between 8 and 12 months of age²⁶.

Post-axial polydactyly is the most common. While there are no rules, the metatarsals must be evaluated to decide which toe should be resected, while trying as best possible to avoid leaving a scar on the side of the foot. It is theoretically important to reattach the muscles and reconstruct the ligament layers.

Central polydactyly is rare; the least functional toe is resected.

3.5. Clinodactyly

Clinodactyly can be simple (trapezoidal phalanx) or related to a delta phalanx.

3.5.1. Trapezoidal phalanx

In cases of trapezoidal phalanx (more often in the 4th toe or the hallux – hallux in valgus or lateral deviation), nonoperative treatment is not effective. Surgical treatment is proposed after 3 years of age when impingement while wearing shoes justifies an osteotomy.

3.5.2. Delta phalanx (longitudinal epiphyseal bracket – LEB)

The clinical presentation of 1st metatarsal involvement resembles metatarsus adductus (hallux varus deformity with no rearfoot deformity). Radiologically, the shortened and oval shape of the 1st metatarsal is suggestive of LEB²⁸ (Figure 4A, B). The growth delay in the 1st metatarsal is not significant enough to be detected clinically early on.

When a patient presents with delta phalanx, physiolsis should be performed as early as possible. This consists of resection of the epiphyseal bridge using small rongeurs and aligning the phalanx fragments with a K-wire; in some cases, an inert tissue graft (cement) can be added to stop the bridge from reforming.

3.5.3. Quintus varus

This is a common reason for consultation, early after birth. The pathology is bilateral in 20% to 30% of cases. This condition is due to an abnormal tendon insertion. Conservative treatment using bracing and daily massage²⁶ has proven effective in newborns.

The surgical indication is made only after the child has started walking (case of spontaneous resolution²⁹). The Butler procedure^{29,30} is the gold standard. The other treatment modalities are plagued by a high complication rate (recurrence, technical problems, morbidity)²⁹. Tenotomy of the extensor tendon and capsulotomy are done in this technique through a double-racket skin incision, which allows the dorsal skin defect to be covered by the lateral flap.

Recently, a percutaneous technique for capsulotomy of the metatarsophalangeal joint of the 5th toe and tenotomy of the extensor tendon has been described³⁰. The correction is achieved with the postoperative dressings, which can be followed by a custom brace. The advantage is that skin reconstruction is not necessary, which reduces the possibility of wound-healing complications. Lastly, surgical syndactylization techniques are debatable from a cosmetic point of view, although they lead to good functional outcomes. In cases of joint contracture, an osteotomy or arthrodesis procedure is preferred.

3.5.4. Other toes

Clinodactyly of the 2nd toe leads to secondary clinodactyly of the hallux and 3rd toe, which pass under the 2nd (infra-adductus) (Figure 5), leading to painful impingement in shoes. If this condition persists and interferes with function, opening of the plantar metatarsophalangeal joint capsule, tenotomy of the flexor²⁶ or an osteotomy can be proposed after 10 years of age.

Hallux varus corresponds to a medial deviation of the 1st toe from the metatarsophalangeal joint. Impingement while wearing shoes leads to an early indication of alignment correction. Soft tissue release is combined with resection of the internal fibrous band and wide arthrolysis with repositioning of the 1st phalanx on the metatarsal head. Reduction is maintained with a axial K-wire for 2 months. An osteotomy may be necessary later on²⁶.

Camptodactyly is rare in children and sometimes occurs in the 2nd toe. It causes hammer toe with flexion of the proximal interphalangeal (IP) joint and extension of the distal IP joint. Conservative treatment with bracing is often sufficient. In this fails or the result is not satisfactory, percutaneous tenotomy of the flexor hallucis longus is proposed followed by wearing a brace, resection arthroplasty or fusion.

3.6. Macroductyly

Macroductyly is characterized by enlargement of every segment of one or more toes. The corresponding metatarsal may be untouched or hypertrophic also (Figure 6, 6A and B). It is important to differentiate between static macroductyly, which are present at birth and progress regularly relative to the other toes, from syndrome-related macroductyly (Proteus syndrome, Neurofibromatosis type 1, Klippel-Trenaunay syndrome). The tendons and blood vessels are untouched, while the elements responding to neurogenic involvement are hypertrophic. The toe is hypertrophic overall, in length, width and thickness. Growth is accelerated with increasing bone age. Bone growth fades when the growth plates are closed.

Treatment has both functional and esthetic aims. Surgery must be proposed early on (Figure 6C). It is difficult to make a specific surgical plan, which generally combines skin flaps, debulking, and liposuction while preserving the vascular elements (30% to 50% of skin complications). Anecdotally, neurectomy has been proposed to slow down the growth spurts. Nevertheless, this technique cannot be recommended because of a lack of published efficacy.

From a bone perspective, percutaneous epiphysiodesis procedures are performed once the toe has reached its adult size. Since all the problems cannot be solved during a single operation, it is important to allow sufficient wound healing time between each one³¹. Amputation of the toe, and potentially the corresponding metatarsal, combined with subtraction osteotomy in the cuneiform or cuboid is the last resort when the other procedures have failed³¹.

In summary, when the defect affects a single toe, the treatment must be determined on a case-by-case basis, while avoiding making scars that will interfere with wearing shoes³². Families must be warned of the high risk of surgical revision, in order to improve an outcomes that gets worse with growth.

4. Other defects

4.1. What is new with hallux valgus? Does congenital hallux valgus exist?

Congenital hallux valgus is rare; instead, this is a juvenile developmental pathology that appears in early childhood. Nevertheless, there are rare case of late fetal deformity leading to true congenital hallux valgus. However, in this case, simple conservative treatment with physical therapy and padding is generally sufficient.

Juvenile hallux valgus is defined by the varus deviation of the 1st metatarsal and valgus deviation of the 1st phalanx of the hallux in an immature skeleton. The initial defect is progressive metatarsal varus during growth. Other anomalies then commonly develop (lateral deviation of the distal articular surface of the metatarsal, evidenced by an increase in the distal metatarsal articular angle (DMAA), angulation of the joint between the 1st metatarsal and the cuneiform, flat foot, or excess length of the 1st metatarsal³³) (Figure 7). Appropriate footwear or conservative treatment with bracing only delays the surgery³³. The indication is made when the condition interferes with walking or wearing shoes.

Osteotomy is recommended only on mature bone, once the growth plate of the 1st metatarsal has closed³⁴. Among the 130 described procedures, there is no true consensus and the optimal technique has not been determined. The incorrect orientation of the articular surface of the 1st metatarsal in juvenile hallux valgus leads us to recommend mainly techniques with osteotomy of the M1 base or cuneiform bone combined with osteotomy of the neck of the 1st metatarsal to reorient the articular surface³⁵. In the literature, a Scarf osteotomy combined as needed with an osteotomy of the 1st phalanx (Akin³⁴) and a Chevron-type osteotomy of the neck of the 1st metatarsal have been described extensively. Recurrence of the deformity does not seem to be related to the type of procedure done, but instead to the absence of metatarsus varus associated with the hallux valgus.

Minimally invasive techniques³⁶ (like those used in adults) are associated with a greater risk of the deformity recurring beyond 3 years (good patient satisfaction but non-optimal radiological correction). Recently, lateral hemi-epiphysiodesis of the base of the 1st metatarsal has been described³⁷ (Figure 8). The pain levels are significant lower, and the deformity stops getting worse, with no recurrence at 2 years' follow-up. The surgical indication must be made for functional disability at an average age of 10 years^{37,38}. In our experience, when evaluating the feet at the end of growth, we have found no cases of shortening of the 1st ray. The key to a successful procedure is the extent of the epiphysiodesis (optimal is 30% of width of the growth plate).

Overall, in cases of juvenile hallux valgus, before the growth plates close at the base of the 1st metatarsal, it is acceptable to propose lateral hemi-epiphysiodesis at the base of the 1st metatarsal. If the growth plate is closed, the optimal surgical technique has not been determined due to the abnormal orientation of the articular surface of the 1st metatarsal (increased MDAA).

4.2. Amniotic band constriction (ABC)

ABC is a syndrome combining multiple polymorphic and asymmetric malformations that do not follow any embryonic systematization³⁹. The most common manifestation are limb abnormalities. At the feet, the most prominent are skin grooves caused by constriction (circumferential with a perpendicular trajectory to the major axis of the limbs, or variable depth and resulting in distal lymphoedema), amputations (asymmetric) and pseudo-syndactyly. These are asymmetric and always follow the proximal portion of the interdigital space. Thus there is a characteristic fissure or opening at the old web space,

sufficient for a stylus to pass through (late formation of the syndactyly, after toe formation). The treatment of the various conditions is not specific.

4.3. Deformity sequelae of the forefoot in other congenital abnormalities

At the forefoot, true metatarsus adductus with adduction at the Lisfranc joint is a rare but potential complication of congenital talipes equinovarus (CTEV). We can also observe adduction of the toes and/or hallux adductus. In this case, a metatarsal osteotomy with or without medial cuneonavicular capsulotomy is needed⁴⁰.

In case of a dorsal bunion related to defective anteromedial support (consequence of residual supination in CTEV, or tendon transfer of the tibial anterior muscle through the talar neck in congenital vertical talus¹¹), we can propose lengthening of the tibialis anterior tendon with or without 1st metatarsal osteotomy to a child less than 10 years of age. Beyond this age, we need to use the same techniques as in adults, such as transfer of the flexor hallucis longus (FHL), Lapidus procedure (resection and cuneometatarsal fusion, and FHL transfer) or even anterior tarsectomy.

4.4. Nail pathologies

Congenital nail pathologies consist of ingrown nails and nail malalignment⁴¹.

Congenital ingrown nail impacts children 0 to 3 years of age. Two forms co-exist:

- Distal ingrowth (Figure 9) of an overly soft nail that may not have lengthened enough to reach the finger pulp. Conservative treatment is always indicated, even when the nail pierces the dorsal skin and a skin bridge has formed above it. If conservative treatments fail (local wound care, strapping, implantation of artificial nail), we can propose surgical treatment to a child older than 6 months, which consists in resecting a distal skin crescent (4–5 mm thick) dissected to the bone and then sutured with 5-0 monofilament (Figure 10).
- Early laterodistal ingrowth: local wound care is also recommended; surgery is indicated only in case of persistent hypertrophy after 1 year of age or inflammation / infection that is not responding to local wound care.

We must always consider the possibility of subungual exostosis mimicking an ingrowth, which will always require surgical excision.

In case of congenital malalignment of the great toenail, it is generally deviated towards the lateral side of the toe. The condition often improves spontaneously with growth. We should wait until 10 years of age to propose surgical treatment. The surgery consists of rotation the matrix and nail bed (Figure 11).

A more recently described condition is retronychia or proximal ingrowth of the nail (Figure 12 and 13). This is a reaction to nail trauma, often the hallux. Nail growth is temporarily interrupted, with detachment of the proximal portion. A new nail grows underneath it, but the damaged nail plate grows into the proximal part of the nail bed, leading to paronychia. The diagnosis is confirmed by ultrasonography showing reduced distance between the proximal part of the nail bed and the distal interphalangeal joint. The final stage is nail avulsion.

In conclusion, there are multiple and varied forefoot abnormalities in children. It is important for the orthopedic surgeon to ask the family about the child's history and to supplement the forefoot

examination with a general examination. The bilateral nature of malformations and/or association with other distinctive features must arouse suspicion. It is essential for the examination be well documented and for a radiological work-up to be requested. It may also be useful to take a few pictures before sending the child to a geneticist. Forefoot malformation should be considered as an orthopedic “doorway” to guide the etiological assessment for the overall care of the patient and his/her family.

Conflict of interest: No direct or indirect conflict of interest related to this lecture

Funding: none

Author contributions:

Virginie Rampal: writing of article, bibliography, layout

Fabienne Giuliano: contributed to writing genetics aspects of article

References

1. Feng L, Sussman M. Combined Medial Cuneiform Osteotomy and Multiple Metatarsal Osteotomies for Correction of Persistent Metatarsus Adductus in Children. *J Pediatr Orthop.* 2016; 36:730-5.
2. Dawoodi AI, Perera A. Radiological assessment of metatarsus adductus. *Foot Ankle Surg.* 2012; 18:1-8.
3. Kite JH. Congenital metatarsus varus; report of 300 cases. *J Bone Joint Surg.* 1950;32-A:500-6.
4. Bleck EE. Metatarsus adductus: classification and relationship to outcomes of treatment. *J Pediatr Orthop.* 1983;3:2-9.
5. Katz K, David R, Soudry M. Below-knee plaster cast for the treatment of metatarsus adductus. *J Pediatr Orthop.* 1999;19:49-50
6. Herzenberg JE, Burghardt RD. Resistant metatarsus adductus: prospective randomized trial of casting versus orthosis. *J Orthop Sci.* 2014 ;19:250-6.
7. Utrilla-Rodríguez E, Guerrero-Martínez-Cañavete MJAlbornoz-Cabello MMunuera-Martínez PV. Corrective Bandage for Conservative Treatment of Metatarsus Adductus: Retrospective Study. *Phys Ther.* 2016 ;96:46-52.
8. Stark JG, Johanson JE, Winter RB. The Heyman-Herndon tarsometatarsal capsulotomy for metatarsus adductus: results in 48 feet. *J Pediatr Orthop.* 1987;7:305-10.
9. Knörr J, Soldado F, Pham TT, Torres A, Cahuzac JP, de Gauzy JS. Percutaneous correction of persistent severe metatarsus adductus in children. *J Pediatr Orthop.* 2014;34:447-52.
10. Viehweger E, Jacquemier M, Launay F, Giusiano B, Bollini G. First cuneiform osteotomy alters hindfoot architecture. *Clin Orthop Relat Res.* 2005;441:356-65.
11. Wicart P, Loriaut P, Seringe R. Pied en Z. In : Seringe R, Besse J-I, Wicart P, editors. *Les déformations du pied de l'enfant et de l'adulte.* Cahiers d'Enseignement de la SOFCOT. Paris : Elsevier Masson ; 2010.p.137-140.
12. Mosca VS. Flexible flatfoot and skewfoot. *Instr Course Lect.* 1996;45:347-54.

13. Jawish R, Rigault P, Padovani JP, Klizowski PH, Finidori G, Touzet P et al. The Z-shaped or serpentine foot in children and adolescents]. *Chir Pediatr*. 1990;31:314-21. French.
14. Lloyd-Roberts GC, Clark RC. Ball and socket ankle joint in metatarsus adductus varus. (S-shaped or serpentine foot). *J Bone Joint Surg* . 1973 ;55-B:193-6.
15. Napiontek M, Kotwicki T, Tomaszewski M. Opening wedge osteotomy of the medial cuneiform before age 4 years in the treatment of forefoot adduction. *J Pediatr Orthop*. 2003;23:65-9.
16. Hofmann AA, Constine RM, McBride GG, Coleman SS. Osteotomy of the first cuneiform as treatment of residual adduction of the fore part of the foot in club foot. *J Bone Joint Surg*. 1984;66-A:985-90.
17. S. Manouvrier-Hanu, A. Mezel. Classification des malformations congénitales des membres. EMC - Appareil locomoteur 2010:1-6 [Article 15-200-C-10]
18. Jones MDRincker SA. Callus Distraction Versus Single-Stage Lengthening with Bone Graft for Treatment of Brachymetatarsia: A Systematic Review. *Foot Ankle Surg*. 2015 ;54:927-31.
19. Peña-Martínez VM, Palacios-Barajas D, Blanco-Rivera JC, Arnaud-Franco Á, Elizondo-Rodríguez JA, Acosta-Olivo C, Vílchez-Cavazos F, Morales-Avalos R. Results of External Fixation and Metatarsophalangeal Joint Fixation With K-Wire in Brachymetatarsia. *Foot Ankle Int*. 2018 Aug;39(8):942-948.
20. Baek GH, Chung MS. The treatment of congenital brachymetatarsia by one-stage lengthening. *J Bone Joint Surg*. 1998; 80-B:1040-4.
21. Kim HS, Lee YS, Jung JH, Shim JS. Complications of distraction osteogenesis in brachymetatarsia: Comparison between the first and fourth brachymetatarsia. *Foot Ankle Surg*. 2017 . pii: S1268-7731(17)31290-0. doi: 10.1016/j.fas.2017.09.004. [Epub ahead of print]
22. Kitabata R, Sakamoto Y, Nagasao T, Kishi K. Distraction Osteogenesis for Brachymetatarsia by Using Internal Device. *Plast Reconstr Surg Glob Open*. 2017; 25;5:e1381.
23. Kim HT, Hong SM, Kim IH. Treatment of Brachymetatarsia Involving the Great Toe. *JBJS Open Access*: June 2018 - Volume 3 - Issue 2 - p e0046 doi: 10.2106/JBJS.OA.17.00046
24. Abraham E, Waxman B, Shirali S, Durkin M. Congenital cleft-foot deformity treatment. *J Pediatr Orthop*. 1999;19:404-10.
25. Tani Y, Ikuta Y, Ishida O. Congenital cleft-foot deformity treatment. Surgical treatment of the cleft foot. *Plast Reconstr Surg*. 2000;105:1997-2002.
26. Jouve JL, Jacquemier M, Casanova D, Launay F, Bardot J, Magalon G, Bollini G. Anomalies congénitales des Orteils (Métatarsus adductus et hallux valgus exceptés) Monographie du Groupe D'Etude en Orthopédie Pédiatrique. *Sauramps Médical* 2001 : 187-201
27. Adamsbaum C, Kalifa G, Seringe R, Bonnet JC. Minor tibial duplication: a new cause of congenital bowing of the tibia. *Pediatr Radiol*. 1991;21:185-8.
28. Marcdargent Fassier A, Gueffier XJanelle C, Fassier F. [Longitudinal epiphyseal bracket of the first metatarsus (delta bone)]. *Rev Chir Orthop Reparatrice Appar Mot*. 2007;93:486-93. [Article in French]
29. Simões R, Alves C, Tavares L, Balacó I, Cardoso PS, Ling TP, Matos G. Treatment of the overriding fifth toe: Butler's arthroplasty is a good option. *J Child Orthop*. 2018 1;12:36-41.
30. Murgier J, Knörr J, Soldado F, Bayle-iniguez X, Sales de Gauzy J. Percutaneous correction of congenital overlapping fifth toe in paediatric patients. *Orthop Traumatol Surg Res*. 2013;99:737-

- 40.
31. Tatu RF, Anuşca DN, Dema ALC, Jiga LP, Hurmuz M, Tatu CS, Ionac M, Vaida MA. Surgical treatment in a case of giant macrodystrophia lipomatosa of the forefoot. *Rom J Morphol Embryol.* 2017;58:1115-1119.
 32. Salazard B, Philandrianos C, Gaudeuille A. [Congenital malformations of the forefoot]. *Ann Chir Plast Esthet.* 2016;61:519-527. French.
 33. Chell J, Dhar S. Pediatric hallux valgus. *Foot Ankle Clin.* 2014;19:235-43. Review.
 34. Agrawal Y, Bajaj SK, Flowers MJ. Scarf-Akin osteotomy for hallux valgus in juvenile and adolescent patients. *J Pediatr Orthop B.* 2015;24:535-40.
 35. Braito M, Dammerer D, Hofer-Picout P, Kaufmann G. Proximal Opening wedge osteotomy with distal chevron osteotomy of the 1st metatarsal for the treatment of moderate to severe hallux valgus. *Foot Ankle Int.* 2018; Oct 21:1071100718799079
 36. Gicquel T, Chapuis M, Violas P. Percutaneous hallux valgus surgery in children: short-term outcomes of 33 cases. *Orthop Traumatol Surg Res.* 2013;99:433-9.
 37. Sabah Y, Rosello O, Clement JL, Chau E, Solla F, Rampal V. Lateral hemiepiphysiodesis of the first metatarsal for juvenile hallux valgus. *Journal of Orthopedic Surgery (Hong Kong)* 2018;26:2309499018801135
 38. Greene JD, Nicholson AD, Sanders JO, Cooperman DR, Liu RW. Analysis of Serial Radiographs of the Foot to Determine Normative Values for the Growth of the First Metatarsal to Guide Hemiepiphysiodesis for Immature Hallux Valgus. *J Pediatr Orthop.* 2017;37:338-343.
 39. Sentilhes L, Verspyck E, Patrier S, Eurin D, Lechevallier J, Marpeau L. Maladie des brides amniotiques : étiopathogénie, diagnostic anténatal et prise en charge néonatale. *J Gynecol Obstet Biol Reprod.* 2003 ; 32 :693-704
 40. Wicart P, Tourne Y. « Pied bot varus équin congénital. In Seringe R, Besse JL, Wicart P, editors ». *Les déformations du pied de l'enfant et de l'adulte. Cahiers d'Enseignement de la SOFCOT.* Paris : Elsevier Masson ; 2010.p.93-126.
 41. Pediatric ingrown Toenails. Baran R. *Pediatric Nail Disorders.* CRC Press. 2017; 242-52

Figure legends

Figure 1: Skewfoot – dorsal bump in a 6-year-old child

Figure 2: Skewfoot – Alignment of 1st metatarsal, cuneiform bones and cuboid

A: radiograph at 4 years

B: radiograph at 10 years

Figure 3: Pre- and post-axial polydactyly

Figure 4: LEB

A: radiograph at 8 months

B: immediate postoperative radiograph at 9 months

Figure 5: Clinodactyly of 2th toe with infra-adductus of the 3th toe

Figure 6: Macroductyly

A: Clinical appearance in a 8-year-old child who has never been seen for this problem

B: Radiograph of the foot of an 8-year-old child who has never been seen for this problem

C: At 8 years of age, the child underwent surgical epiphysiodesis and debulking. Outcome at 5 years' follow-up

Figure 7: Juvenile hallux valgus – preoperative radiograph

Figure 8: Postoperative radiograph after hemiepiphysiodesis; procedure was successful since the lateral growth plate is closed

Figure 9: Ingrowth toe nail – distal ingrowth of a normally oriented nail

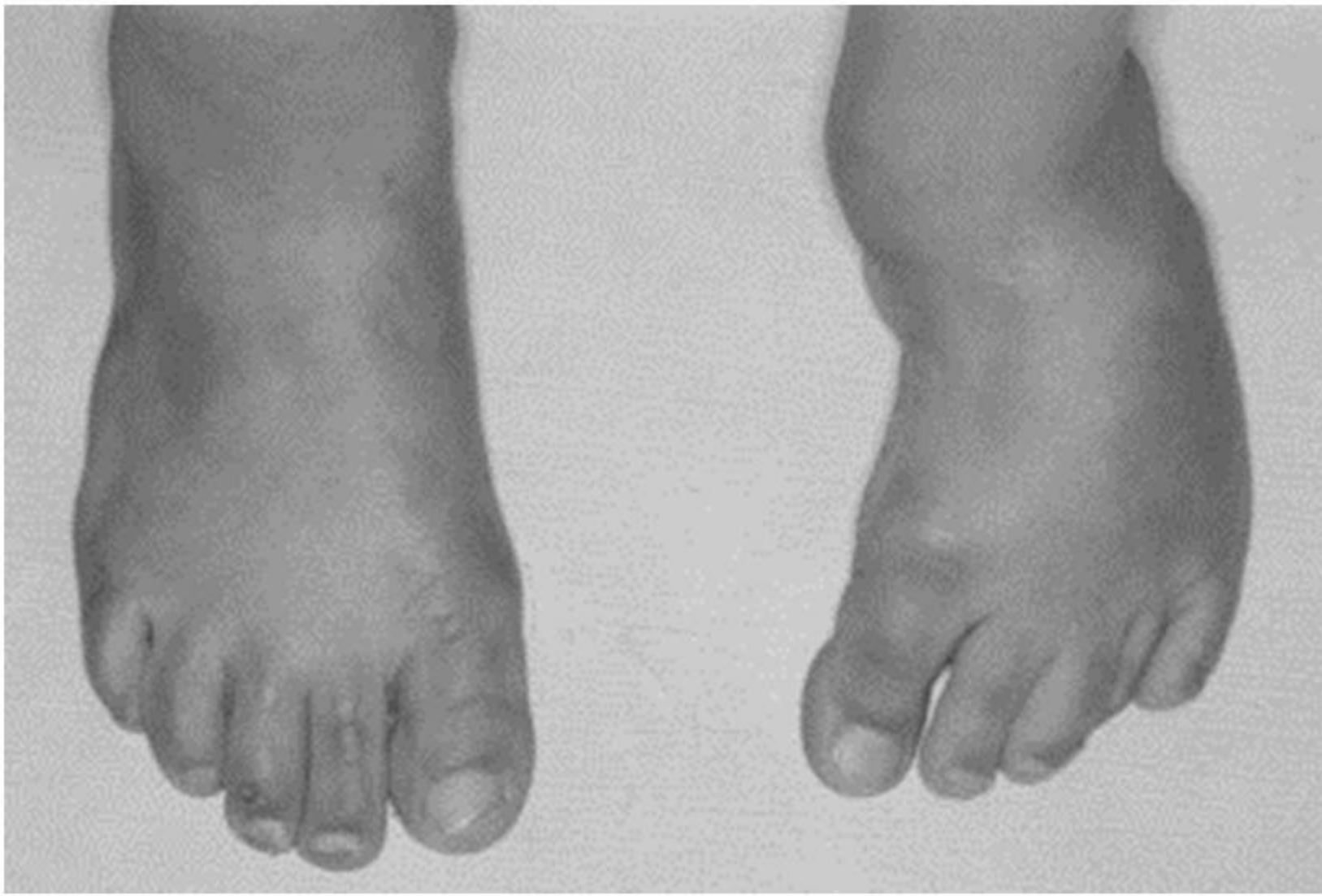Figure 10: Ingrown toe nail – surgical treatment of distal ingrowth

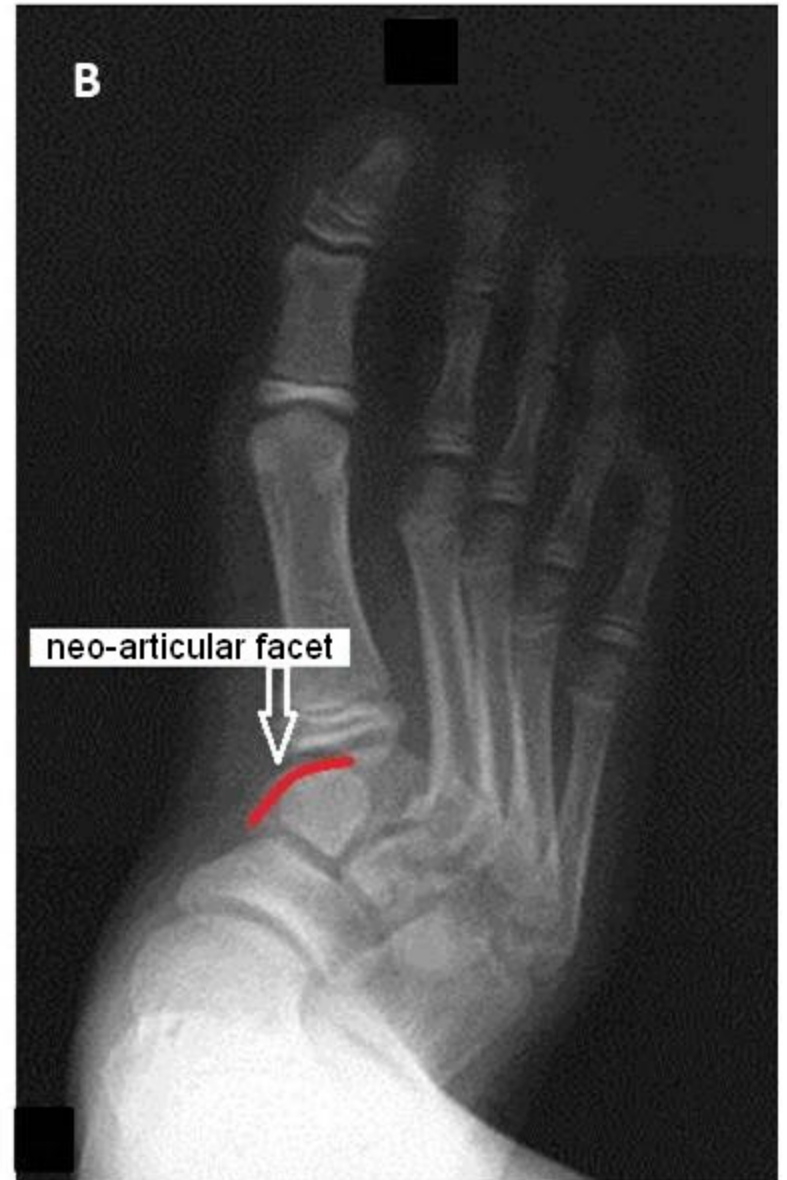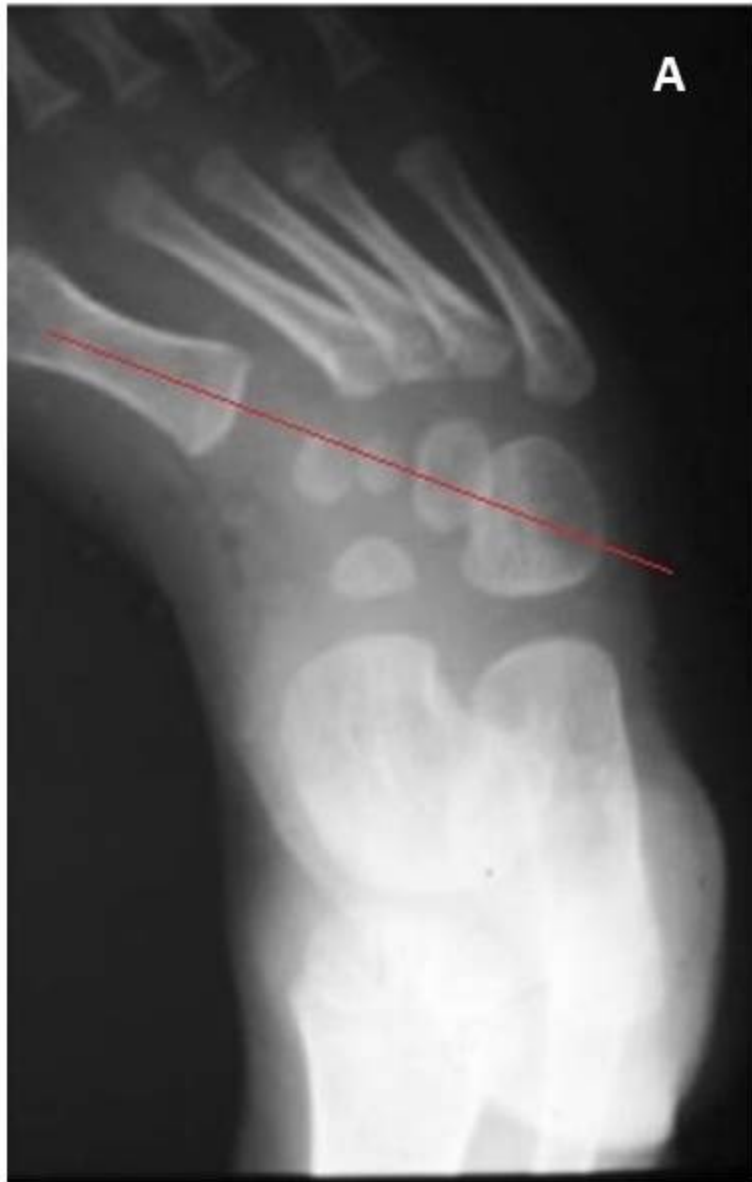Figure 11: Congenital malalignment of greater toe nail – surgical treatment

Figure 12: Clinical appearance of retronychia

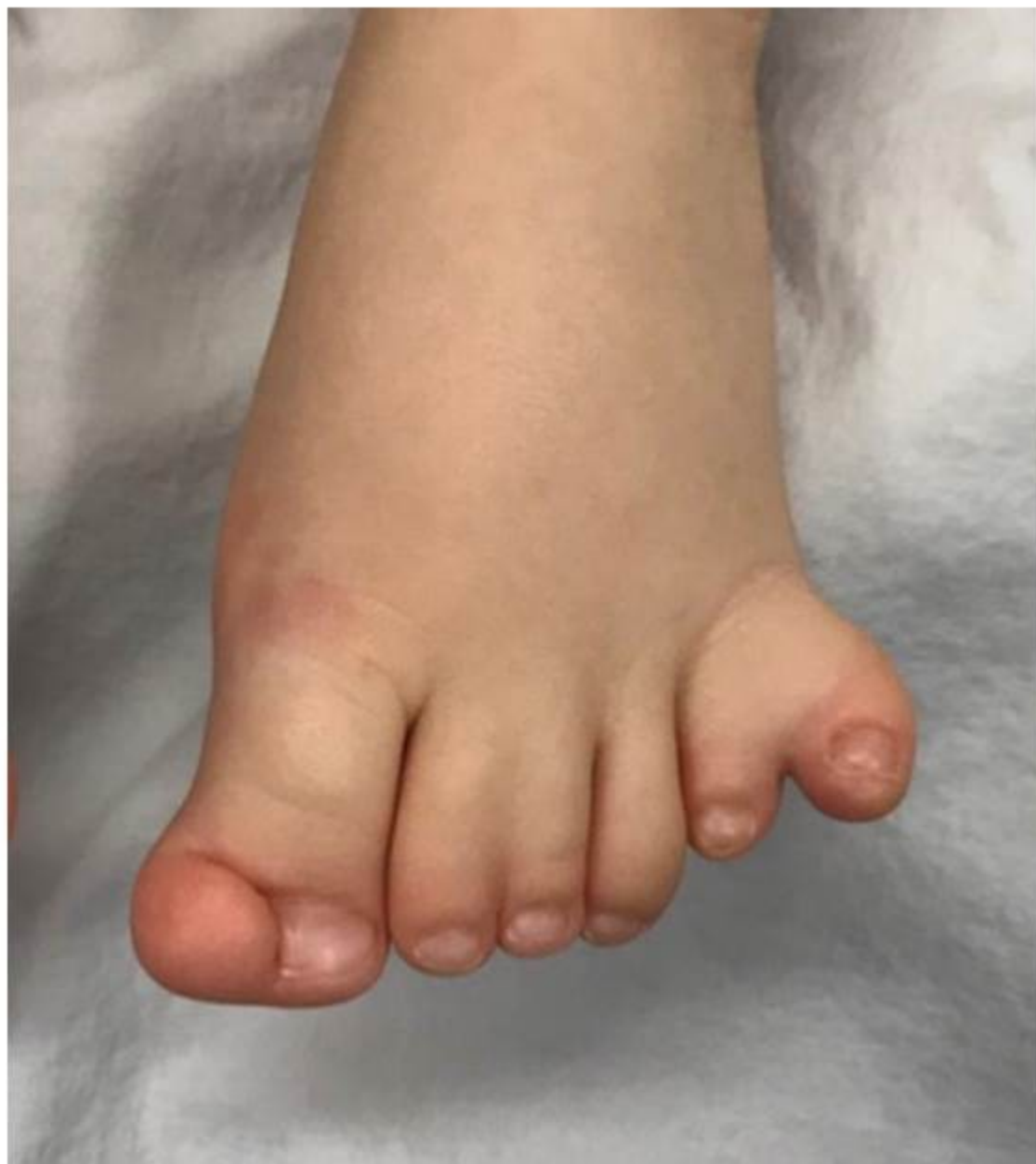Figure 13: Retronychia

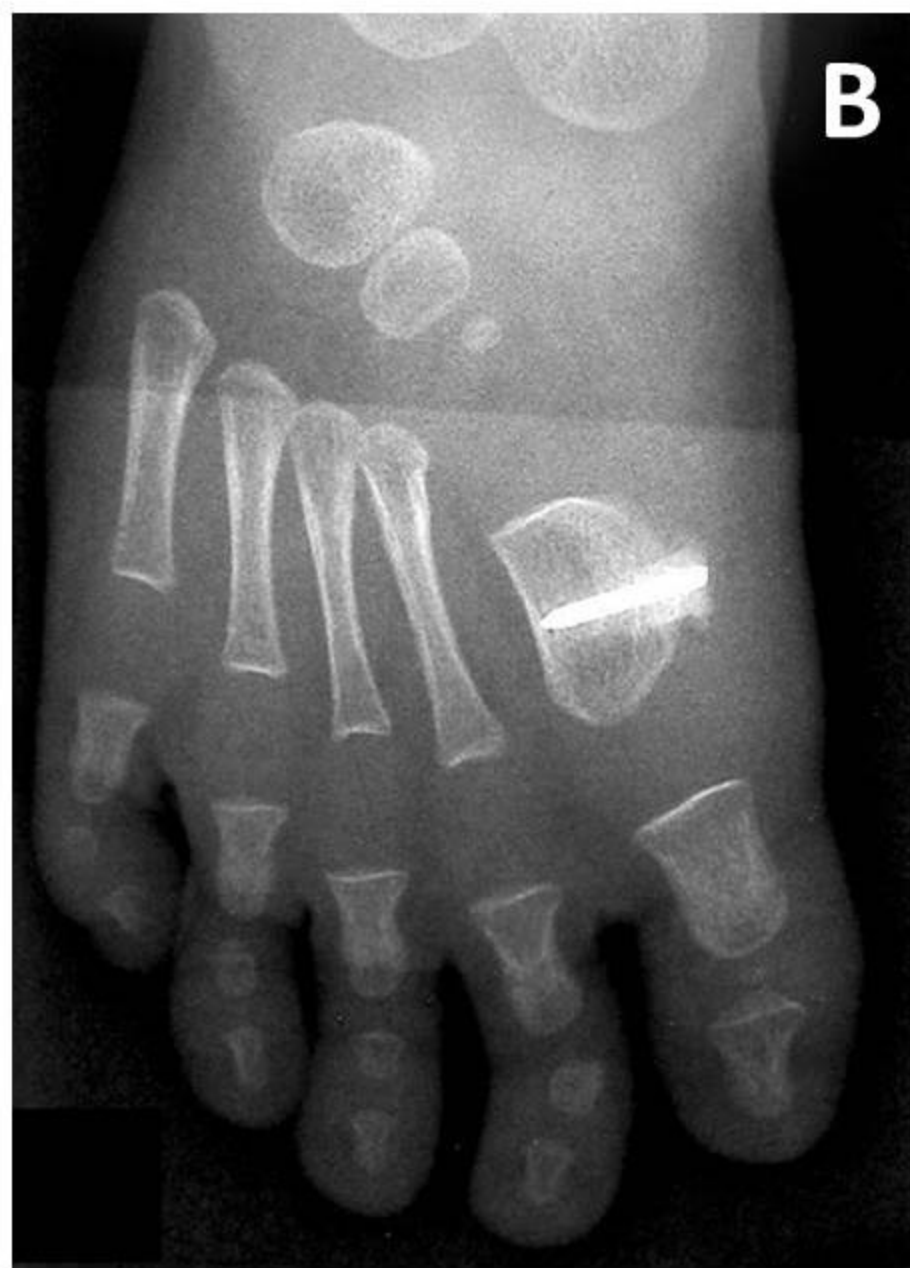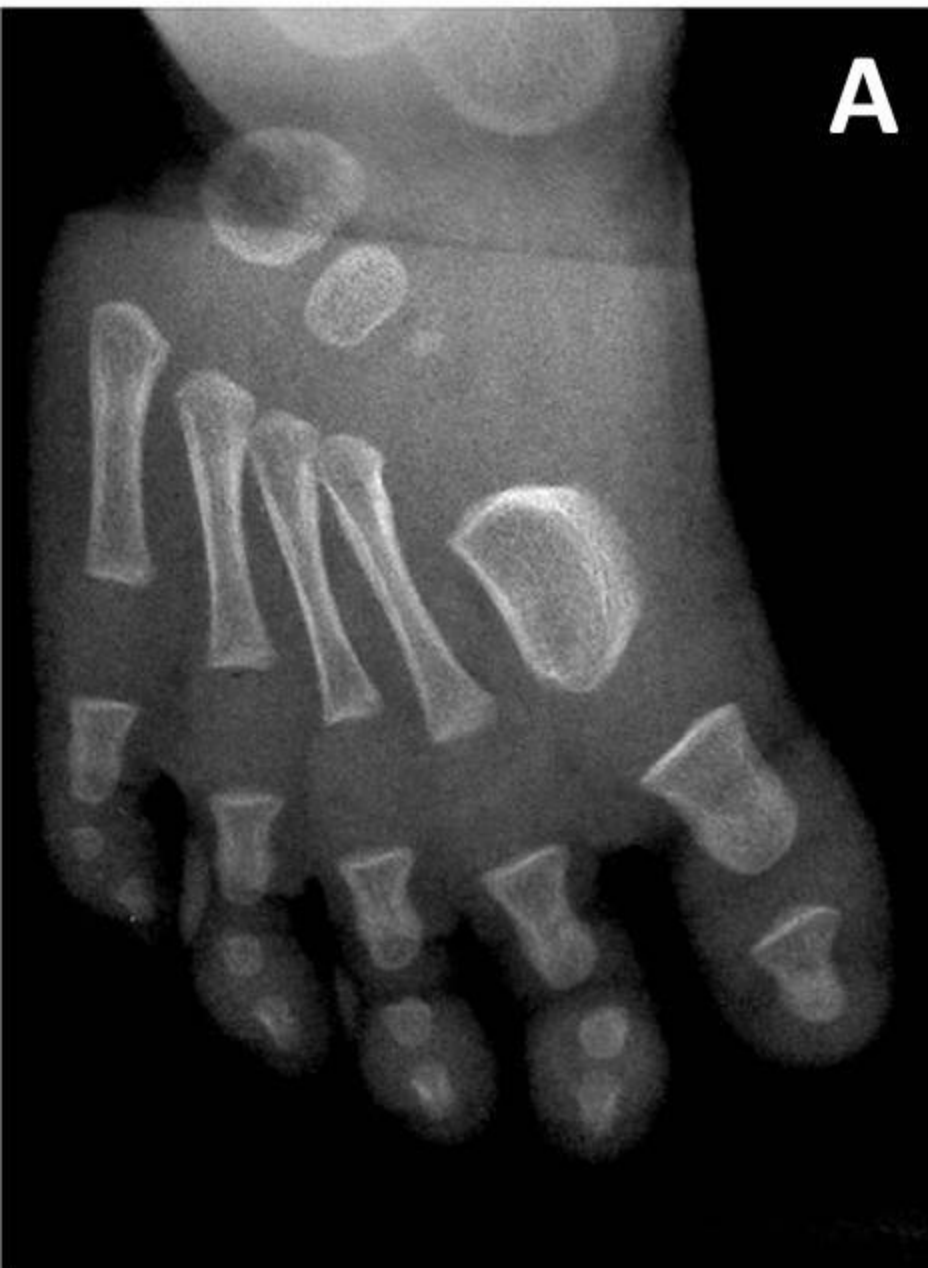Wicart P, Loriaut P, Seringe Cahiers d'Enseignement de la SOFCOT. Paris : Elsevier Masson ; 2010.p.137-140.



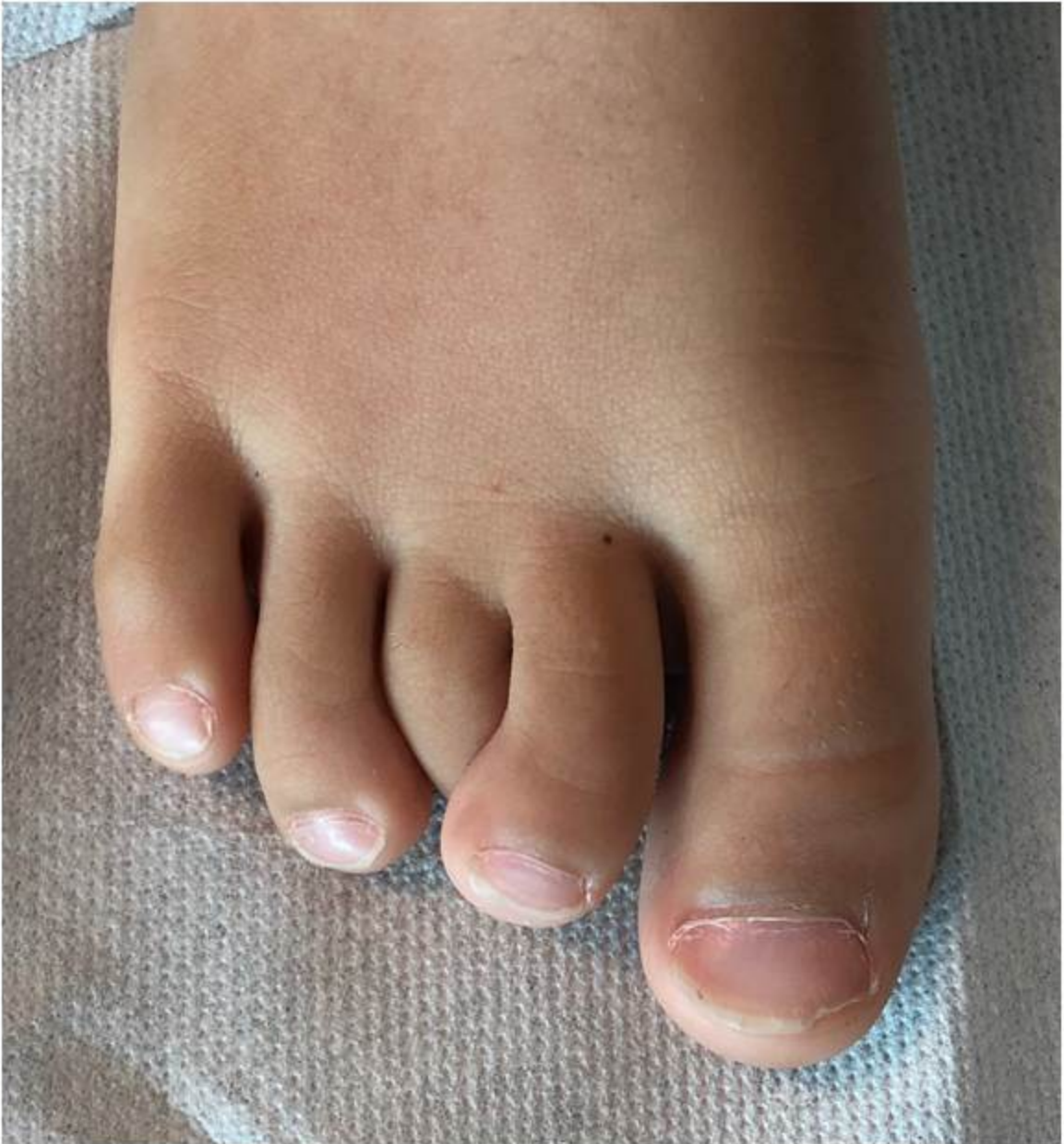

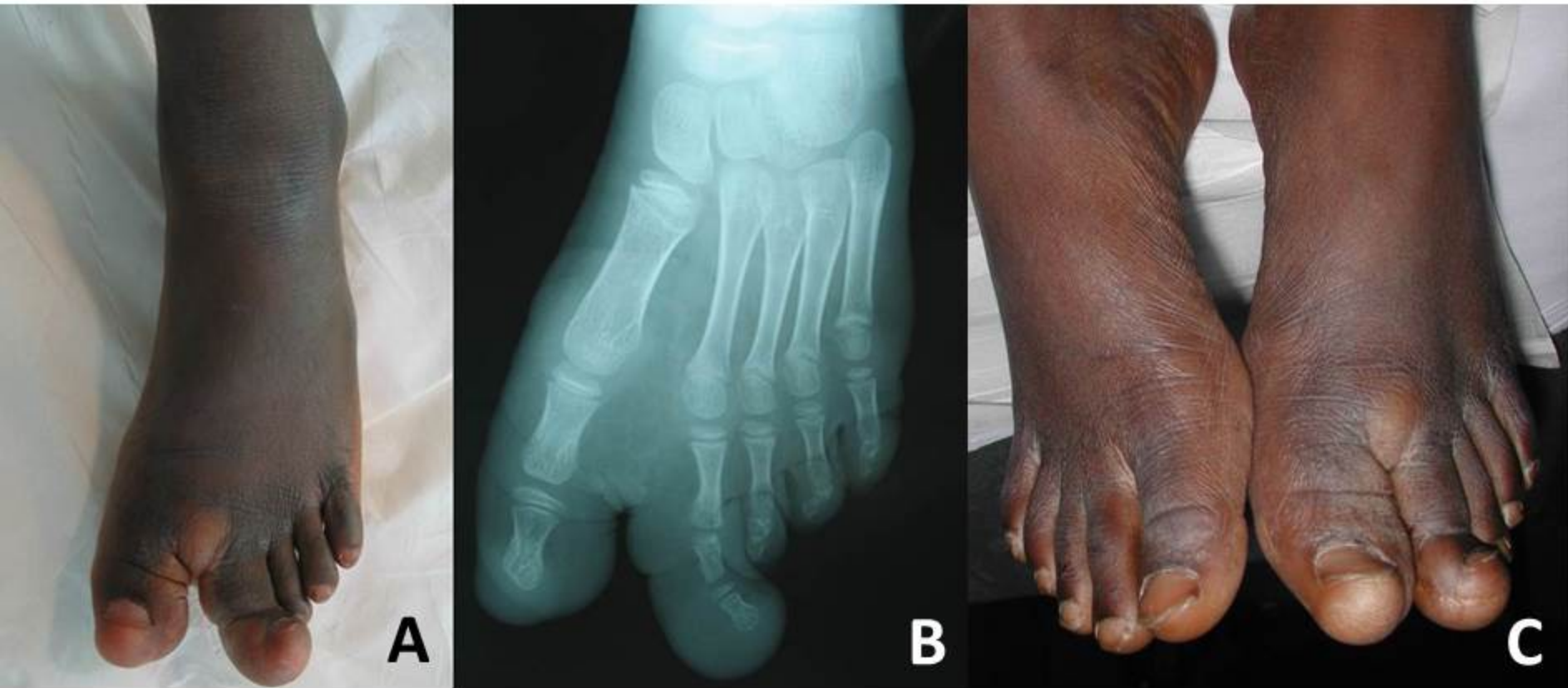
Collection personnelle





Collection personnelle

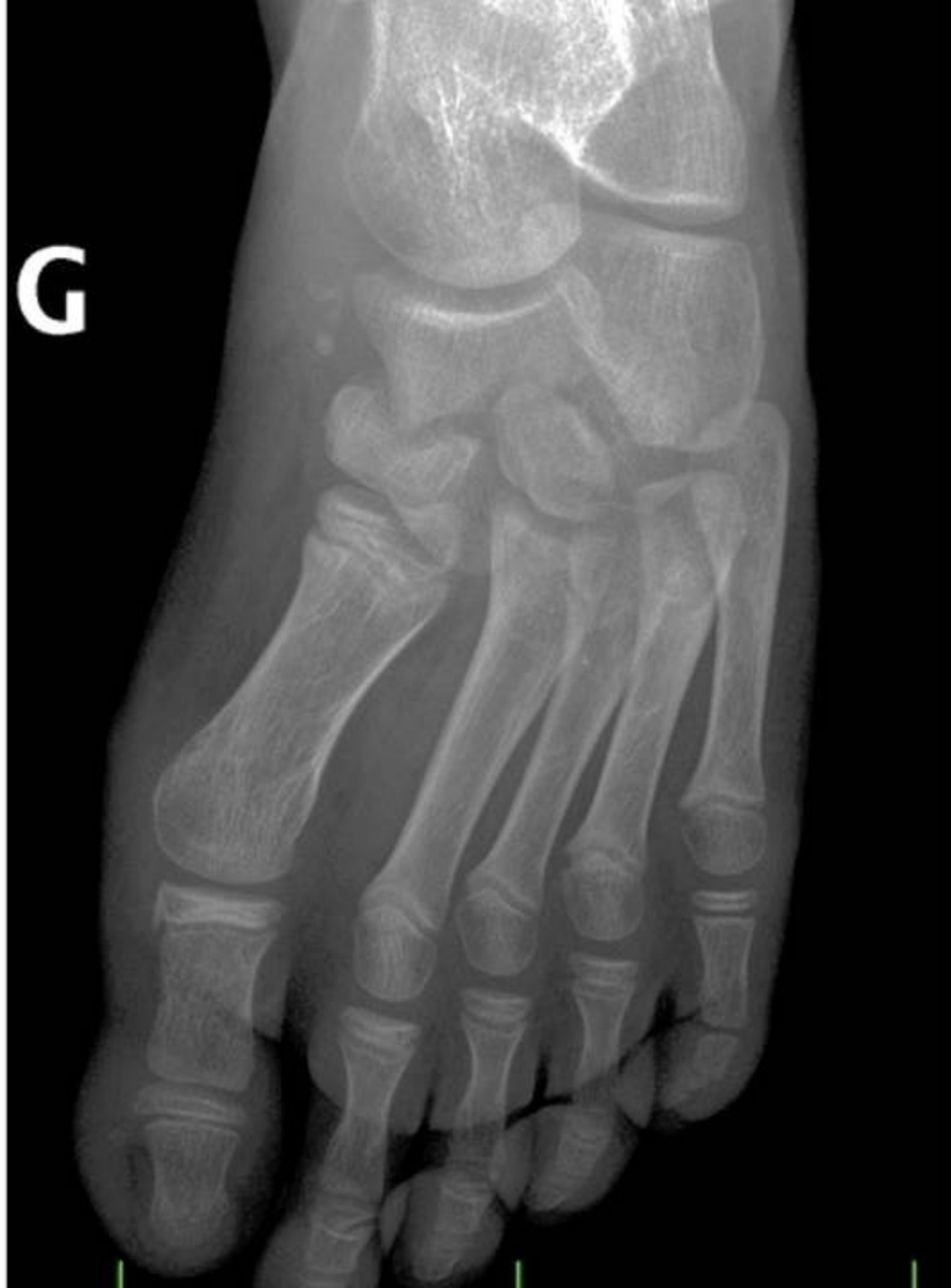



Collection personnelle

Collection personnelle

G



Collection personnelle





