



HAL
open science

Low Revision Rates at More Than 10 Years for Dual-Mobility Cups Cemented Into Cages in Complex Revision Total Hip Arthroplasty

Gary Sayac, Thomas Neri, Loïc Schneider, Rémi Philippot, Frédéric Farizon,
Bertrand Boyer

► **To cite this version:**

Gary Sayac, Thomas Neri, Loïc Schneider, Rémi Philippot, Frédéric Farizon, et al.. Low Revision Rates at More Than 10 Years for Dual-Mobility Cups Cemented Into Cages in Complex Revision Total Hip Arthroplasty. *The Journal of Arthroplasty*, 2020, 35 (2), pp.513 - 519. 10.1016/j.arth.2019.08.058 . hal-03489844

HAL Id: hal-03489844

<https://hal.science/hal-03489844v1>

Submitted on 21 Jul 2022

HAL is a multi-disciplinary open access archive for the deposit and dissemination of scientific research documents, whether they are published or not. The documents may come from teaching and research institutions in France or abroad, or from public or private research centers.

L'archive ouverte pluridisciplinaire **HAL**, est destinée au dépôt et à la diffusion de documents scientifiques de niveau recherche, publiés ou non, émanant des établissements d'enseignement et de recherche français ou étrangers, des laboratoires publics ou privés.



Distributed under a Creative Commons Attribution - NonCommercial 4.0 International License

Low revision rates at more than 10 years for Dual Mobility Cups cemented into cages in complex Revision Total Hip Arthroplasty

Gary Sayac¹
Thomas Neri^{1,2}
Loïc Schneider³
Rémi Philippot^{1,2}
Frédéric Farizon^{1,4}
Bertrand Boyer^{1,4}

¹Department of Orthopaedic Surgery, University Hospital Centre of Saint-Etienne, Saint-Etienne, France

² EA 7424 - Inter-university Laboratory of Human Movement Science, University Lyon - University Jean Monnet, Saint Etienne, France

³ Department of Orthopaedic Surgery, Clinique Mutualiste of Saint-Etienne, Saint Etienne, France

⁴ INSERM U1059 (SAINBIOSE), University Jean Monnet, Saint Etienne, France

*corresponding author: garysayac@gmail.com, Service de Chirurgie orthopédique, Centre Hospitalo Universitaire de Saint-Étienne, Hôpital Nord, 42055 Saint-Étienne, France

Conflict of interest

Bertrand Boyer and Thomas Neri are consultants for SERF (Décines, France)

Rémi Philippot and Frédéric Farizon receive royalties from SERF (Décines, France)

Compliance with ethical standards

Each author certifies that his or her institution approved the human protocol for this investigation, that all investigations were conducted in conformity with ethical principles of research and that consent for participation in a study was obtained.

1 **Low revision rates at more than 10 years for Dual Mobility Cups** 2 **cemented into cages in complex Revision Total Hip Arthroplasty**

3 4 5 **ABSTRACT**

6 7 Background

8 Instability and aseptic loosening are the two main complications after revision total hip
9 arthroplasty (rTHA). Dual mobility (DM) cups were shown to counteract implant instability
10 during rTHA. To our knowledge, no study evaluated the 10-year outcomes of rTHA using
11 DM cups, cemented into a metal reinforcement ring, in cases of severe acetabular bone loss.
12 We hypothesized that using a DM cup cemented into a metal ring is a reliable technique for
13 rTHA at 10 years, with few revisions for acetabular loosening and/or instability.

14 15 Methods

16 This was a retrospective study of 77 rTHA cases with severe acetabular bone loss (Paprosky \geq
17 2C) treated exclusively with a DM cup (NOVAE STICK[®], SERF, Décines, France) cemented
18 into a cage (Kerboull cross, Burch Schneider or ARM[®] rings). Clinical scores and radiological
19 assessments were performed preoperatively and at the last follow-up. The main endpoints
20 were revision surgery for aseptic loosening or recurring dislocation.

21 22 Results

23 With a mean follow-up of 10.7 years [2.1, 16.2], three patients were reoperated because of
24 aseptic acetabular loosening (3.9%) at 9.6 years [7, 12]. Seven patients (9.45%) dislocated
25 their hip implant, only one suffered from chronic instability (1.3%). Cup survivorship was
26 96.1% at 10 years. No sign of progressive radiolucent lines were found and bone graft
27 integration was satisfactory for 91% of the patients.

28 29 Conclusion

30 The use of a DM cup cemented into a metal ring during rTHA with complex acetabular bone
31 loss was associated with low revision rates for either acetabular loosening or chronic
32 instability at 10 years.

33 34 **Keywords**

35 Revision total hip arthroplasty, cemented dual mobility cup, acetabular loosening, instability
36
37

38 **INTRODUCTION**

39

40 Given the increasing number of total hip arthroplasty (THA) procedures performed annually
41 and our longer life expectancy, the number of revision THA (rTHA) procedures is expected to
42 increase in the coming years [1]. Revision THA is a complex procedure with a risk of
43 repeated revisions due to aseptic acetabular loosening and/or chronic instability [2]. The aim
44 is to achieve reliable, long-term results to limit the number of surgical revisions, which
45 involve major surgeries for the patient and complex struggles for the surgeon.

46 In cases of rTHA with severe acetabular defect (Paprosky score equal or higher than 2C) [3],
47 the use of a metal reinforcement device or cage helps ensuring a good fixation of the implants
48 on healthy bone while rebuilding acetabular bone stock with morselized allograft, and restore
49 the hip's center of rotation [4].

50 Dual mobility (DM) cups have been shown to prevent or treat chronic instability during rTHA
51 [5]. Because of the risk factors for dislocation, their use was proven relevant during these
52 complex acetabular revisions [6][7]. To the best of our knowledge, the 10-year outcomes of
53 rTHA using DM cups in cases of severe acetabular bone loss have not been evaluated,
54 whereas it is widely accepted that early acetabular failures occur between 7 to 10 years.

55 We hypothesized that using a DM cup cemented inside a cage is a reliable technique for
56 complex acetabular rTHA, with few surgical revisions for acetabular loosening and/or chronic
57 instability at a mean follow-up of 10 years. The purpose of this study was to determine
58 implant survival with cup revision either due to acetabular loosening or recurring dislocation
59 as primary endpoints.

60

61

62

63 MATERIAL AND METHODS

64

65 *Population*

66 This was a retrospective, single-center series of 77 rTHA cases (74 patients) exclusively with
67 cemented DM cups, performed between February 2002 and April 2010. Were included all
68 patients who underwent rTHA with a DM cup cemented in a metal ring during that period.
69 Exclusion criteria were surgery for tumor removal (primary or secondary) (n = 10), patients
70 over 85 years of age presenting a fracture (n = 5) and foreign patients operated in our surgical
71 unit (n = 12). These exclusions were justified either because of the limited life expectancy and
72 high mortality rate in patients who received rTHA for tumors or older patients with fractures,
73 and because of the challenges associated with a regular follow-up in the case of foreign
74 patients.

75 Overall, 74 patients (77 implants) were included (24 men, 50 women) with a mean follow-up
76 of 10.7 ± 3.1 years [2.1, 16.2] (**Fig.1**). Mean age at the time of revision surgery was 70 ± 11.3
77 years [34, 88]. The most common indications for rTHA were isolated acetabular loosening
78 (n = 32, 41.5%), bipolar loosening (n = 17, 22.1%), second-stage Prosthetic Joint Infection
79 (n = 10, 12.9%), or revision for recurrent dislocation due to implant wear (n = 7, 9.1%) (Table
80 1). The acetabular bone defects were considered severe, with mainly Paprosky stages 2C, 3A
81 or 3B (**Table 1**). The greater trochanter was damaged in four patients (n = 5, 2%) and
82 nonunion was present in two patients (n = 2, 6%). The mean number of prior operations on
83 the analyzed hip was 2.15 [1, 6].

84

85 *Acetabular implants*

86 All patients received a NOVAE STICK[®] Dual Mobility Cup (Serf, Décines, France) which is
87 a cup forged from 316L stainless steel. The convex side of the STICK[®], the cemented version
88 of the SERF Dual Mobility Cup (DMC), is grit-blasted by glass beads, in order to obtain the
89 optimal roughness (according to ISO1997 standard) to maximize cement fixation ($R_a <$
90 $1\mu\text{m}$). The cup was cemented in either one of three different acetabular reinforcement devices
91 (**Fig.2**). A Kerboull cross KE (Serf, Décines, France) was used in Paprosky 2A–3B cases
92 (**Fig.3A**). For Paprosky 3A-3B cases, either a Burch-Schneider anti-protrusion cage (Zimmer
93 Biomet, Warsaw, USA) (**Fig.3B**) or a custom tri-flange ARM[®] cage (SERF, Décines, France)
94 (**Fig.3C**) was used. The ARM[®] cage was only used in the most severe acetabular defect cases
95 and was specifically manufactured for the patient, based on computed tomography (CT) data.

96 The reinforcement devices were either made of 316L stainless steel (Kerboull cross and
97 ARM[®]) or Ti6Al4V titanium alloy (Burch-Schneider).

98 The following STICK[®] DM cup diameters were used: 45 mm (n = 15, 19.48%), 47 mm
99 (n = 19, 24.67%), 49 mm (n = 29, 37.66%), 51 mm (n = 6, 7.79%), 53 mm (n = 8, 10.35%).

100 For all the cages, the diameter of the DMC is always 7 mm shorter than the diameter of the
101 cage (*i.e.* a Kerboull cross KE[®] 56/49 is used with a 49 mm STICK[®], a Burch-Schneider of
102 56 mm is used with a 49 mm STICK[®]). This cement mantle thickness (> 3 mm) allows
103 preventing metal contact between the DMC and the cage.

104 A metal-polyethylene bearing was used in all cases. The UHMWPE Dual Mobility liners
105 were combined with a 22.2 mm-diameter metal head in 42 cases (54.5%) and a 28 mm head
106 in 35 cases (45.4%). Outer liner diameters depend on the corresponding DMC diameter; the
107 outer liner diameter is roughly 6 mm shorter than the outer diameter of the corresponding
108 DMC (*i.e.* the true outer diameter of a 49 liner is around 43 mm, clearance included).

109

110 *Surgical technique*

111 All revisions were performed through a posterolateral approach by three experienced
112 surgeons of our institution. The reinforcement device was selected based on the preoperative
113 CT scan and adapted, as needed, based on the surgeon's intraoperative observations.
114 Morselized acetabular bone allograft was impacted at the site in 98.7% of cases. The joint
115 capsule and pelvi-trochanteric muscles were not reinserted.

116

117 *Clinical and radiological assessments*

118 Clinical and radiological assessments were performed postoperatively at 45 days, 3 months, 6
119 months, 1 year, and then every 2 years until the final follow-up. The clinical assessment
120 consisted of functional scores (Merle d'Aubigné-Postel PMA Score [8], Harris Hip Score –
121 HHS [9]) determined preoperatively and during the follow-up period. Chronic instability was
122 defined by the occurrence of more than two episodes of dislocation and/or subluxation
123 perceived by the patient.

124 The radiological evaluation was carried out using OSIRIX[®] software (Pixmeo, Bernex,
125 Switzerland). The aim was looking for periprosthetic osteolysis based on the DeLee-Charnley
126 topography[10], signs of loosening, and determining whether the cup's position had shifted
127 [11]. The extent of the allograft's integration was evaluated using the Oswestry classification

128 [12]. Any heterotopic ossification was noted and classified according to Brooker [13].
129 Patients who suffered implant breakage underwent a CT scan to rule out loosening.

130

131 *Statistical analysis*

132 Statistical analysis was performed using SPSS Statistics (version 23, SPSS Inc., Chicago, IL,
133 USA). The significance level was set at $p < 0.05$. The results were expressed as mean \pm
134 standard deviation for quantitative variables and percentages for qualitative variables. After
135 confirming the data were distributed normally, Student's *t*-test was used to compare
136 quantitative variables (change in clinical outcome scores over time). The cup's survivorship
137 was determined using Kaplan Meier survival curves (with 95% confidence intervals), with
138 revision surgery for aseptic loosening and all-cause revision with implant removal as the main
139 endpoints.

140

141

142 **RESULTS**

143

144 *Clinical outcomes*

145 At the final follow-up, 34 patients (45.9%) had died after a mean of 8.8 ± 3.2 years [2.2,
146 13.7], with their implant in place (35 implants) and without revision. One patient was lost to
147 follow-up after 8 years. The mean PMA and HHS scores improved significantly between the
148 preoperative assessment and the final follow-up, going from 8.1 ± 2.5 [7, 9] to 15.3 ± 2.2 [15,
149 16] ($p < 0.001$), and from 39.5 ± 9.6 [37, 43] to 71.3 ± 14 [67, 75] ($p < 0.001$), respectively.

150

151 *Radiological outcomes*

152 A nonprogressive, periacetabular radiolucent line in zone II was found in four patients. The
153 cup inclination was 47.2 ± 6.24 [31.9, 64.2] immediately postoperative and 47.36 ± 6.5
154 [33.38, 64.32] at the last follow-up. No signs of abnormal liner wear or intraprosthetic
155 dislocation were found. There were 18 cases of Brooker I, 4 cases of Brooker II and 7 cases of
156 Brooker III heterotopic ossifications. According to the Oswestry classification, the allograft
157 integration was stage 0 in 1 case (1.3 %), stage I in 4 cases (5.2%), stage II in 2 cases (2.5%),
158 stage III in 14 cases (18.2%), stage IV in 23 cases (29.8%), and stage V in 33 cases (42.8%).

159

160 *Complications and survival*

161 All of the complications are listed in **Table 2**.

162 Three patients were reoperated because of aseptic loosening (3.89%) after a mean period of
163 9.6 ± 2.5 years [7, 12]. All of the loosening cases occurred in hips treated with the use of a
164 Kerboull cross. There were no cases of loosening with the Burch-Schneider ring or ARM[®]
165 device. Two of the loosening cases were in hips with Paprosky 2B defects and one in a hip
166 with a 3A defect.

167 Seven patients (**Fig.4**) suffered from a dislocation (9.45%), 5 of which occurring early at a
168 mean of 37 days [18, 54] and 2 occurring later [at 158 and 518 days]. Four of these
169 dislocations benefited from a closed reduction and the other three required open surgery. At
170 the last follow-up, only one patient (1.3%) reported chronic instability. This patient had a
171 fracture of the greater trochanter which resulted in a greater trochanter nonunion. These
172 dislocations occurred in patients with an acetabular defect classified Paprosky 3A (n = 1,
173 4.5%) and 3B (n = 6, 28.6%). The dislocation rate was 1.69% for the Kerboull cross, 20% for
174 the Burch Schneider ring and 38.5% for the ARM[®]. The six patients with greater trochanter

175 damage (n = 4) or nonunion (n = 2) all suffered a dislocation (**Fig.4**). The rTHA indications of
176 the hips that dislocated were post-infection reimplantation (30%), revision for recurrent
177 dislocation (14.3%) and aseptic bipolar loosening (5.9%).

178 One case of sciatic nerve impingement required surgical revision with change of the
179 reinforcement device.

180 Three infections occurred. One was an early infection treated by debridement, antibiotics and
181 implant retention (DAIR). This infection healed and did not recur as of the final follow-up.
182 The two other infections required surgical revision with implant change.

183 Six patients had complications requiring surgical revision without implant change: surgical
184 reduction of dislocation (n = 3), DAIR (n = 1), drainage of hematoma (n = 1), treatment of
185 greater trochanter nonunion (n = 1).

186 The following non-surgical complications occurred: closed reduction of dislocation (n = 4),
187 greater trochanter fracture (n = 1), breakage of screws holding the metal reinforcement device
188 without loosening (n = 2). Two patients were associated with broken screws of the cage (one
189 case of Kerboull cross, one case of ARM cage). The fractures were visible on early follow-up
190 x-rays (< 6 months) but this radiological finding did not evolve over time. Only one of four
191 Kerboull cross screws, or one of seven ARM screws were broken.

192 No radiolucent lines, osteolysis or loosening of components was found at last follow-up. The
193 Oswestry score for these two patients was stage V.

194 In 6 patients, the acetabular cup was changed: due to aseptic loosening in three patients
195 (3.89%), infection in two (2.59%) and sciatic nerve impingement in one (1.29%). At the final
196 follow-up, the dislocation rate was 9.45%, with a single patient having chronic instability.
197 The cup survivorship (**Fig. 5**) was 96.1% for aseptic loosening and 92.2% for all causes.

198

199

200 **DISCUSSION**

201

202 The results of our study confirmed our hypothesis. In complex cases of rTHA with severe
203 acetabular bone loss, cemented DM cups with metal reinforcement devices provided
204 satisfactory outcomes in terms of dislocation and revision rates for acetabular loosening at 10
205 year follow-up.

206 It was the first study to achieve 10 years of mean follow-up using DM cups in revision, and
207 one of the few studies in the literature focusing on severe acetabular bone defect.

208

209 The aseptic loosening rate in our study (3.89%) was lower than in studies of fixed bearing
210 cups cemented in reinforcement devices with comparable bone loss and follow-up. For
211 standard cups cemented in a Kerboull cross, the aseptic loosening rate ranged from 5.6% (at 8
212 years) [14] to 6.2% (at 11 years) [15]. In our study, there were no cases of aseptic loosening
213 when a DM cup was cemented in a Burch-Schneider ring, while series with fixed bearing
214 cups reported 6.3% at 9 years [16], 9.1% at 8 years [17] of aseptic loosening rate. There are
215 no published long-term studies evaluating the ARM[®]. While the custom triflanged acetabular
216 component (Zimmer[®]) has a similar design and indication (Paprosky 3) to the ARM[®], its
217 composition differs (porous or hydroxyapatite-coated flanged titanium). In studies with a
218 comparable follow-up reporting the use of fixed bearing cups cemented in a triflanged
219 component, the loosening rate ranged from 0% to 11.5% [18,19]; it was 5.3% for techniques
220 using trabecular metal [20] and between 1.5% and 9% for jumbo cups [18].

221 Compared with other rTHA studies in which a DM cup was used, the aseptic loosening rate
222 was similar: 0% at 1.3 years [21], 13.5% at 7 years [22], and 3.9% at 8.5 years [23]. Given the
223 differences in the type of bone defects between studies, it seems that aseptic loosening
224 appears between 7 and 10 years (mean of 9.6 years in our study). Thus a minimum follow-up
225 is needed to evaluate this outcome, justifying long term studies.

226 Two cases of broken screws were noted, early in the follow-up, but without any modification
227 at last follow-up.

228 One explanation for this phenomenon could be the association of a stainless steel cage (less
229 fatigue-resistant than a titanium alloy device) and a period of soft callus during the graft
230 integration. As soon as the graft is fully integrated in a remodelled bone callus, fewer

231 solicitations on the cage might explain the progression of the device failure pattern. However,
232 the patients presenting such signs of fixation failure should be closely monitored.

233 The dislocation rate in our study was 9.45%. Compared with other rTHA studies with DM
234 cups reporting dislocation rates between 0% and 10,4%[24] [25], our dislocation rate may
235 appear high. Nevertheless, our study specifically focused on the use of DM cups in patients
236 who had severe acetabular bone loss, with previously multiple surgeries, muscle weakness,
237 and who often had a damaged abductor mechanism. The other studies of rTHA with DM cups
238 were on a different patient population with less bone loss and fewer comorbidities (**Table 3**).
239 Our finding of a 1.3% chronic instability rate at 10.7 years is consistent with the 2% rate
240 reported by Viste et al. at 7 years with the same cup [22]. Compared with other studies of
241 fixed bearing THA, our chronic instability rate was lower: 1.54% to 8.1% [14] [26] with
242 Kerboull cross, 2.7% to 8% [17] [27] with Burch Schneider ring, 10.9% with triflanged
243 components, 2.5% with trabecular metal, and 7.1% for jumbo cups [18]. The chronic
244 instability rate was higher in cases of greater trochanter nonunion or damage, associated with
245 a 51% chronic instability with fixed bearing THA [28], while it was 16.7% with DM cups in
246 our study.

247 Our study has certain methodological limitations. The most important are its retrospective
248 design and the small number of cases in which a Burch-Schneider ring (n = 5) or ARM device
249 (n = 13) were used. The lack of a control group was a major limitation. Nevertheless, we had
250 a mean follow-up of 10 years for each of the three types of reinforcement devices, with more
251 than half the patients (54%) still alive at the review point. This will allow us to evaluate the
252 cup's fixation and stability over a longer period.

253

254 **CONCLUSION**

255

256 The use of a DM cup, cemented in a reinforcement device, for complex acetabular revisions
257 was a reliable technique with a low surgical revision rate for loosening and/or chronic
258 instability at a mean follow-up of 10 years. We recommend its use in this indication.

259

260 **REFERENCES**

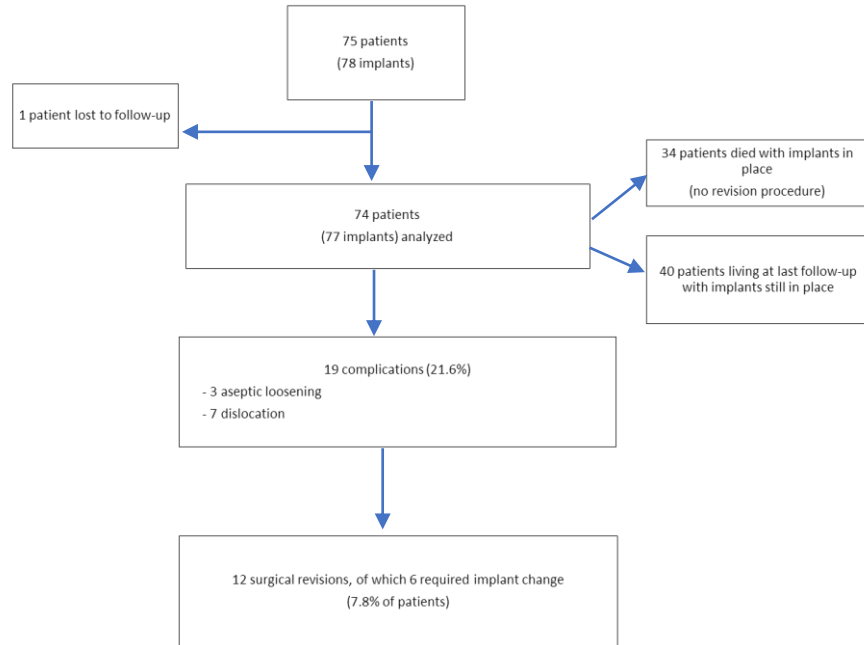
- 261
- 262 [1] Kurtz S, Ong K, Lau E, Mowat F, Halpern M. Projections of primary and revision hip
263 and knee arthroplasty in the United States from 2005 to 2030. *J Bone Joint Surg Am*
264 2007;89:780–5. doi:10.2106/JBJS.F.00222.
- 265
- 266 [2] Springer BD, Fehring TK, Griffin WL, Odum SM, Masonis JL. Why revision total hip
267 arthroplasty fails. *Clin Orthop Relat Res* 2009;467:166–73. doi:10.1007/s11999-008-
268 0566-z.
- 269
- 270 [3] Paprosky WG, Perona PG, Lawrence JM. Acetabular defect classification and surgical
271 reconstruction in revision arthroplasty: A 6-year follow-up evaluation. *The Journal of*
272 *Arthroplasty* 1994;9:33–44. doi:10.1016/0883-5403(94)90135-X.
- 273
- 274 [4] Sheth NP, Nelson CL, Springer BD, Fehring TK, Paprosky WG. Acetabular bone loss in
275 revision total hip arthroplasty: evaluation and management. *J Am Acad Orthop Surg*
276 2013;21:128–39. doi:10.5435/JAAOS-21-03-128.
- 277
- 278 [5] Philippot R, Adam P, Reckhaus M, Delangle F, Verdot F-X, Curvale G, et al. Prevention
279 of dislocation in total hip revision surgery using a dual mobility design. *Orthop*
280 *Traumatol Surg Res* 2009;95:407–13. doi:10.1016/j.otsr.2009.04.016.
- 281
- 282 [6] Darrith B, Courtney PM, Della Valle CJ. Outcomes of dual mobility components in total
283 hip arthroplasty: a systematic review of the literature. *Bone Joint J* 2018;100-B:11–9.
284 doi:10.1302/0301-620X.100B1.BJJ-2017-0462.R1.
- 285
- 286 [7] Abdel MP. Dual-Mobility Constructs in Revision Total Hip Arthroplasties. *J*
287 *Arthroplasty* 2018;33:1328–30. doi:10.1016/j.arth.2018.01.030.
- 288
- 289 [8] d’Aubigné RM, Postel M. The Classic: Functional Results of Hip Arthroplasty with
290 Acrylic Prosthesis. *Clin Orthop Relat Res* 2009;467:7–27. doi:10.1007/s11999-008-
291 0572-1.
- 292
- 293 [9] Harris WH. Traumatic Arthritis of the Hip after Dislocation and Acetabular Fractures:
294 Treatment by Mold Arthroplasty. *The Journal of Bone & Joint Surgery* 1969;51:737–55.
- 295
- 296 [10] DeLee JG, Charnley J. Radiological demarcation of cemented sockets in total hip
297 replacement. *Clin Orthop Relat Res* 1976:20–32.
- 298
- 299 [11] Massin P, Tanaka C, Hutten D, Duparc J. [Treatment of aseptic acetabular loosening by
300 reconstruction combining bone graft and Müller ring. Actuarial analysis over 11 years].
301 *Rev Chir Orthop Reparatrice Appar Mot* 1998;84:51–60.
- 302
- 303 [12] Aulakh TS, Jayasekera N, Kuiper J-H, Richardson JB. Long-term clinical outcomes
304 following the use of synthetic hydroxyapatite and bone graft in impaction in revision hip
305 arthroplasty. *Biomaterials* 2009;30:1732–8. doi:10.1016/j.biomaterials.2008.12.035.
- 306
- 307 [13] Brooker AF, Bowerman JW, Robinson RA, Riley LH. Ectopic ossification following
308 total hip replacement. Incidence and a method of classification. *J Bone Joint Surg Am*
309 1973;55:1629–32.

- 310 [14] Kerboull M, Hamadouche M, Kerboull L. The Kerboull acetabular reinforcement device
311 in major acetabular reconstructions. *Clin Orthop Relat Res* 2000;155–68.
312
- 313 [15] Makita H, Kerboull M, Inaba Y, Tezuka T, Saito T, Kerboull L. Revision Total Hip
314 Arthroplasty Using the Kerboull Acetabular Reinforcement Device and Structural
315 Allograft for Severe Defects of the Acetabulum. *J Arthroplasty* 2017;32:3502–9.
316 doi:10.1016/j.arth.2017.06.029.
317
- 318 [16] Carroll FA, Hoad-Reddick DA, Kerry RM, Stockley I. The survival of support rings in
319 complex acetabular revision surgery. *J Bone Joint Surg Br* 2008;90:574–8.
320 doi:10.1302/0301-620X.90B5.19789.
321
- 322 [17] Ilyas I, Alrumaih HA, Kashif S, Rabbani SA, Faqihi AH. Revision of type III and type
323 IVB acetabular defects with Burch-Schneider anti-Protrusio cages. *J Arthroplasty*
324 2015;30:259–64. doi:10.1016/j.arth.2014.08.014.
325
- 326 [18] Volpin A, Konan S, Biz C, Tansey RJ, Haddad FS. Reconstruction of failed acetabular
327 component in the presence of severe acetabular bone loss: a systematic review.
328 *Musculoskelet Surg* 2018. doi:10.1007/s12306-018-0539-7.
329
- 330 [19] Holt GE, Dennis DA. Use of custom triflanged acetabular components in revision total
331 hip arthroplasty. *Clin Orthop Relat Res* 2004:209–14.
332
- 333 [20] Whitehouse MR, Masri BA, Duncan CP, Garbuz DS. Continued good results with
334 modular trabecular metal augments for acetabular defects in hip arthroplasty at 7 to 11
335 years. *Clin Orthop Relat Res* 2015;473:521–7. doi:10.1007/s11999-014-3861-x.
336
- 337 [21] Pattyn C, Audenaert E. Early complications after revision total hip arthroplasty with
338 cemented dual-mobility socket and reinforcement ring. *Acta Orthop Belg* 2012;78:357–
339 61.
340
- 341 [22] Viste A, Desmarchelier R, Fessy M-H. Dual mobility cups in revision total hip
342 arthroplasty. *Int Orthop* 2017;41:535–42. doi:10.1007/s00264-016-3363-4.
343
- 344 [23] Hamadouche M, Ropars M, Rodaix C, Musset T, Gaucher F, Biau D, et al. Five to
345 thirteen year results of a cemented dual mobility socket to treat recurrent dislocation. *Int*
346 *Orthop* 2017;41:513–9. doi:10.1007/s00264-016-3343-8.
347
- 348 [24] Wegrzyn J, Pibarot V, Jacquiel A, Carret J-P, Béjui-Hugues J, Guyen O. Acetabular
349 reconstruction using a Kerboull cross-plate, structural allograft and cemented dual-
350 mobility cup in revision THA at a minimum 5-year follow-up. *J Arthroplasty*
351 2014;29:432–7. doi:10.1016/j.arth.2013.05.030.
352
- 353 [25] Schneider L, Philippot R, Boyer B, Farizon F. Revision total hip arthroplasty using a
354 reconstruction cage device and a cemented dual mobility cup. *Orthop Traumatol Surg*
355 *Res* 2011;97:807–13. doi:10.1016/j.otsr.2011.09.010.
356
- 357 [26] Gibon E, Kerboull L, Courpied J-P, Hamadouche M. Acetabular reinforcement rings
358 associated with allograft for severe acetabular defects. *Int Orthop* 2018.
359 doi:10.1007/s00264-018-4142-1.

- 360 [27] Udomkiat P, Dorr LD, Won YY, Longjohn D, Wan Z. Technical factors for success with
361 metal ring acetabular reconstruction. *J Arthroplasty* 2001;16:961–9.
362 doi:10.1054/arth.2001.27669.
363
- 364 [28] Taunton MJ, Fehring TK, Edwards P, Bernasek T, Holt GE, Christie MJ. Pelvic
365 discontinuity treated with custom triflange component: a reliable option. *Clin Orthop*
366 *Relat Res* 2012;470:428–34. doi:10.1007/s11999-011-2126-1.
367
- 368 [29] Langlais FL, Ropars M, Gaucher F, Musset T, Chaix O. Dual Mobility Cemented Cups
369 Have Low Dislocation Rates in THA Revisions. *Clin Orthop Relat Res*
370 2008;466(2):389-395. doi:10.1007/s11999-007-0047-9.
371
- 372 [30] Guyen O, Pibarot V, Vaz G, Chevillotte C, Béjui-Hugues J. Use of a dual mobility
373 socket to manage total hip arthroplasty instability. *Clin Orthop Relat Res*
374 2009;467(2):465-472. doi:10.1007/s11999-008-0476-0.
375
- 376 [31] Civinini R, Carulli C, Matassi F, Nistri L, Innocenti M. A dual-mobility cup reduces risk
377 of dislocation in isolated acetabular revisions. *Clin Orthop Relat Res* 2012;470(12):3542
378 3548. doi:10.1007/s11999-012-2428-y.
379
- 380 [32] Hailer NP, Weiss RJ, Stark A, Kärrholm J. Dual-mobility cups for revision due to
381 instability are associated with a low rate of re-revisions due to dislocation: 228 patients
382 from the Swedish Hip Arthroplasty Register. *Acta Orthop* 2012;83(6):566-571.
383 doi:10.3109/17453674.2012.742395.
384
- 385 [33] Pattyn C, Audenaert E. Early complications after revision total hip arthroplasty with
386 cemented dual-mobility socket and reinforcement ring. *Acta Orthop Belg*
387 2012;78(3):357-361.
388
- 389 [34] Simian E, Chatellard R, Druon J, Berhouet J, Rosset P. Dual mobility cup in revision
390 total hip arthroplasty: dislocation rate and survival after 5 years. *Orthop Traumatol Surg*
391 *Res* 2015;101(5):577-581. doi:10.1016/j.otsr.2015.05.002.
392
- 393 [35] Mohammed R, Hayward K, Mulay S, Bindi F, Wallace M. Outcomes of dual-mobility
394 acetabular cup for instability in primary and revision total hip arthroplasty. *J Orthop*
395 *Traumatol* 2015;16(1):9-13. doi:10.1007/s10195-014-0324-9.
396
- 397 [36] Lebeau N, Bayle M, Belhaouane R, et al. Total hip arthroplasty revision by dual-mobility
398 acetabular cup cemented in a metal reinforcement: A 62 case series at a minimum 5
399 years' follow-up. *Orthop Traumatol Surg Res* 2017; 103(5):679-684.
400
- 401 [37] Chalmers BP, Ledford CK, Taunton MJ, Sierra RJ, Lewallen DG, Trousdale RT.
402 Cementation of a Dual Mobility Construct in Recurrently Dislocating and High Risk
403 Patients Undergoing Revision Total Arthroplasty. *J Arthroplasty* 2018;33(5):1501-1506.
404 doi:10.1016/j.arth.2017.11.055.
405
406
407
408
409

410
411
412
413
414

FIGURES AND TABLES



415
416
417
418
419

Fig 1: Flow chart for the study

420
421
422
423

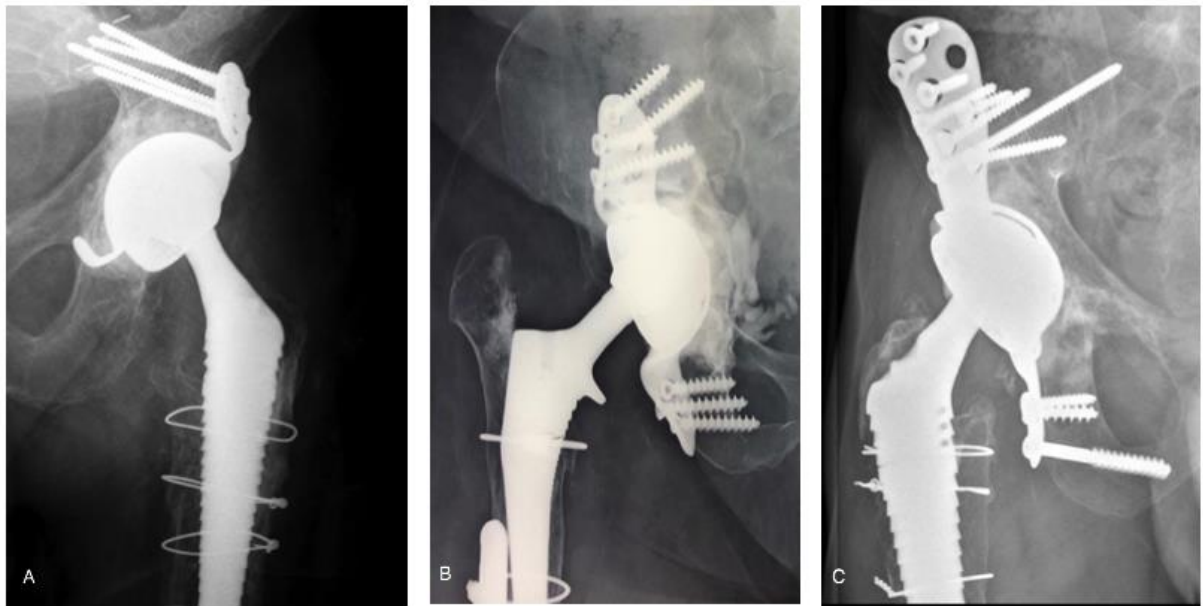


424
425
426
427
428

Fig. 2: NOVAE® STICK dual mobility cup (on top) with the Kerboull cross KE (Serf, Décines, France), the Burch-Schneider ring (Zimmer Biomet, Warsaw, USA) and the ARM device (Serf, Décines, France)

429

430
431
432



433
434
435
436
437
438
439
440
441
442

Fig. 3: X-rays of patients with a DM cup inside a Kerboul cross (A), a Burch Schneider ring (B) or an ARM device (C) at 14 years' follow-up.

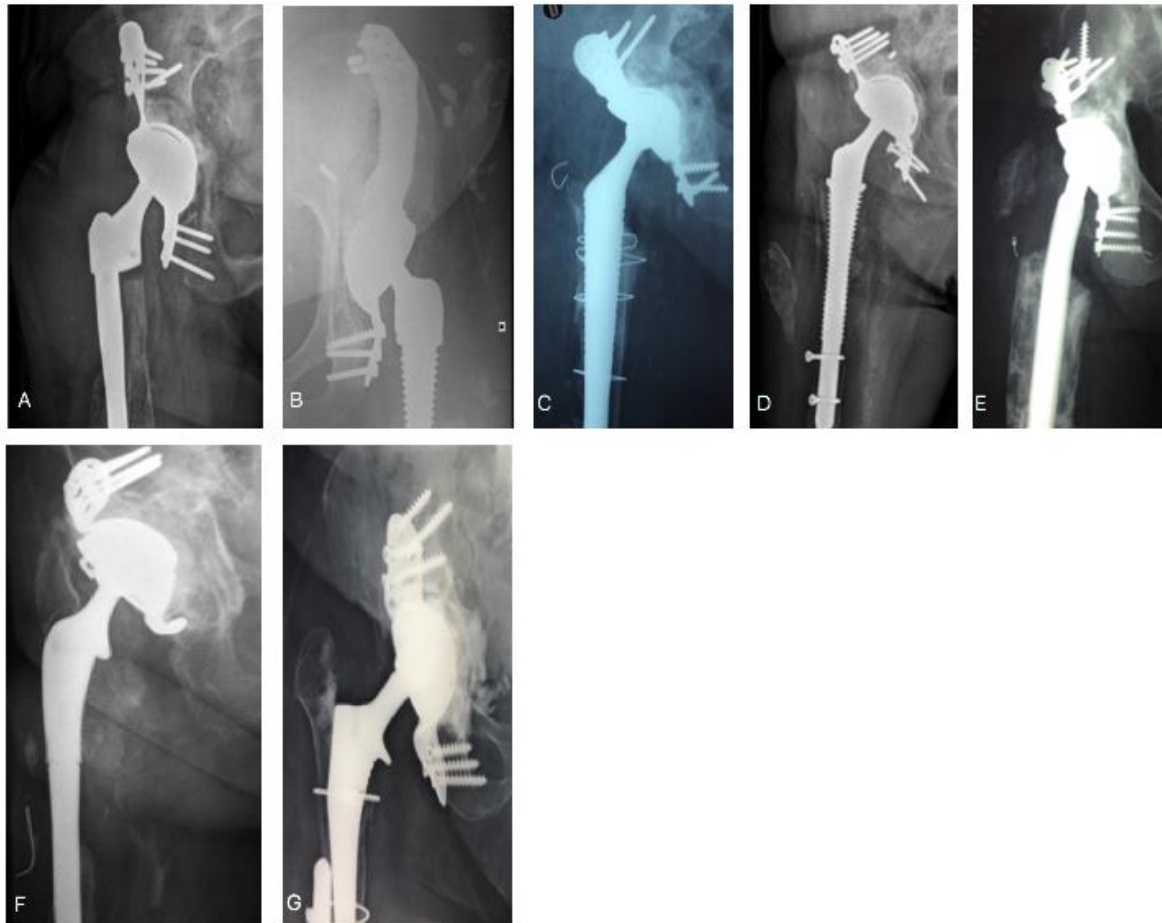

Fig 4: X-rays of the patients who suffered a dislocation. Patient A was plagued by chronic instability.

443
444
445
446
447
448
449
450

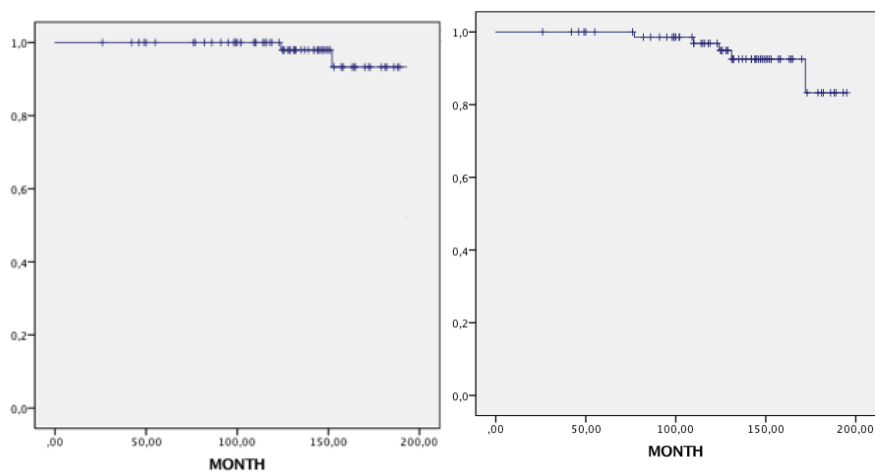


Fig 5: Cup survivorship, according to the Kaplan Meier method. Left chart: survival free of aseptic acetabular loosening. Right chart: all-cause survival for the cup.

451
452
453
454
455
456
457
458

Indications for acetabular revision	Study (n= 77)	Kerboull (n=59)	Burch Schneider (n=5)	ARM (n=13)
Bipolar loosening	17 (22.1%)	14		3
Acetabular loosening	32 (41.5%)	24	1	7
Femoral loosening (Hemiarthroplasties)	1 (1.3%)	1		
Postinfection reimplantation	10 (13%)	7	2	1
Recurrent dislocation / Wear	7 (9.1%)	7		
Intraprosthetic dislocation	1 (1.3%)	1		
Stiffness	2 (2.6%)	2		
Acetabular fracture < 85 years	2 (2.6%)			2
Femoral neck fracture < 85 years	1 (1.3%)	1		
Acetabular protrusion	4 (5.2%)	2	2	
Acetabular defects based on Paprosky classification	Study (n= 77)	Kerboull (n=59)	Burch Schneider (n=5)	ARM (n=13)
2A	4 (5.2%)	4		
2B	12 (15.6%)	12		
2C	18 (23.4%)	18		
3A	22 (28.6%)	18	1	3
3B	21 (27.3%)	7	4	10

459
460 Table 1: Indications for revision THA, and Paprosky grade for acetabular defects

461
462
463
464

Complications	N (%)
With surgical revision: n = 12 (15.6%)	
<u>with</u> change of acetabular implants	
Aseptic loosening	3 (3.89)
Infection-related loosening	2 (2.89)
Sciatic nerve impingement with metal ring	1 (1.29)
<u>without</u> change of implants	
Surgical reduction of dislocation	3 (3.89)
Drainage of compressive hematoma	1 (1.29)
Treatment of greater trochanter nonunion	1 (1.29)
Early infection (DAIR)	1 (1.29)
Without surgical revision: n = 7 (9.4%)	
Closed reduction of dislocation	4 (5.19)
Broken screw	2 (2.89)
Greater trochanter fracture	1 (1.29)
Total	19 (24.7)

465 DAIR: debridement, antibiotics and implant retention
466
467 Table 2: Complications in our study with or without surgical revision

Author	Year	Acetabular implants	N =	Acetabular Bone Loss	Mean FU (years)	Dislocation Rate (n) (%)	Re-operation rate for AL (n) (%)	Survival rate Any reason (%)
Langlais et al. [29]	2008	DMC Kerboull	88	AAOS: I: 21; III: 64; IV: 3	3	1 (1.2%)	2.3% (not reoperated)	94.6% at 5 years
Philippot et al. [5]	2009	DMC Kerboull / Burch-Schneider / ARM	163	AAOS: II:33%; III: 28%; IV:13%	5	6 (3.7%)	2 (1.2%)	96.1% at 7 years
Guyen et al. [30]	2009	DMC ± Cage	54	NA	2.2	1 (1.85%)	0	NA
Schneider et al. [25]	2011	DMC Kerboull / Burch-Schneider / ARM	96	SOFCOT: II: 8; III: 62; IV: 26	3.4	10 (10.4%)	1 (2%)	99.3% at 8 years
Civinini et al. [31]	2012	DMC Contour	33	PAPROSKY: 2A:21%; 2B:28%; 3A: 21%; 3B: 12%	3	0%	0%	97% at 5 years
Hailer et al. [32]	2012	DMC ± Cage (5%)	228	NA	2	4 (2%)	4 (2%)	93% at 2 years
Pattyn et al. [33]	2012	DMC + Ganz	37	NA	1.3	2 (5.4%)	0%	NA
Wegrzyn et al. [24]	2014	DMC Kerboull	61	AAOS: III: 54; IV: 7	7.4	0%	1 (2%)	98% at 7.5 years
Simian et al. [34]	2015	DMC Cementless ± Cage	74	NA	7.3	1 (1.4%)	1 (1.4%)	99% at 5 years
Mohammed et al. [35]	2015	DMC Cementless + DMC + Cage (n = 24)	44	NA	1.8	0%	0%	NA
Hamadouche et al. [23]	2016	DMC ± Kerboull	51	NA	8.5	1 (2%)	2 (3.9%)	75.2% at 10 years
Lebeau et al. [36]	2017	DMC + cage (Muller, Burch-Schneider, Link)	62	SOFCOT: II: 4; III: 45; IV: 9	6.4	1 (1.6%)	5 (6.4%)	91.9% at 8 years
Viste et al. [22]	2017	DMC Cementless + DMC Kerboull / Burch-Schneider / ARM	334 / 52 cage	AAOS	7	3.3% (Chronic instability 2.1%)	7 (13.5%)	NA
Chalmers et al. [37]	2018	DMC + Cage	18	NA	3	3 (17%)	0	NA
Our study	2019	DMC Kerboull / Burch-Schneider/ ARM	77	PAPROSKY: 2A:5.2%; 2B:15.6%; 2C: 23.4%; 3A: 28.6%; 3B: 27.3%	10.7	7 (9.45%) Chronic instability 1 (1.3%)	3 (3.89%)	92.2% at 10 years

Table 3: Main published studies of revision THA in which a dual mobility cup was used with an acetabular reinforcement device (AL: aseptic loosening, DMC: dual mobility cup)

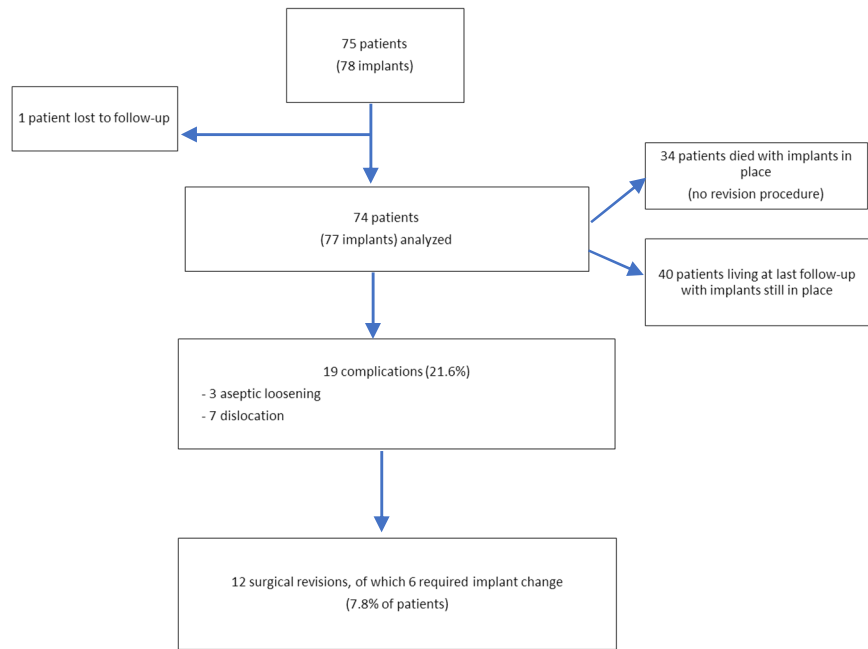


Fig 1: Flow chart for the study



Fig. 2: NOVAE® STICK dual mobility cup (on top) with the Kerboull cross KE (Serf, Décines, France), the Burch-Schneider ring (Zimmer Biomet, Warsaw, USA) and the ARM device (Serf, Décines, France)

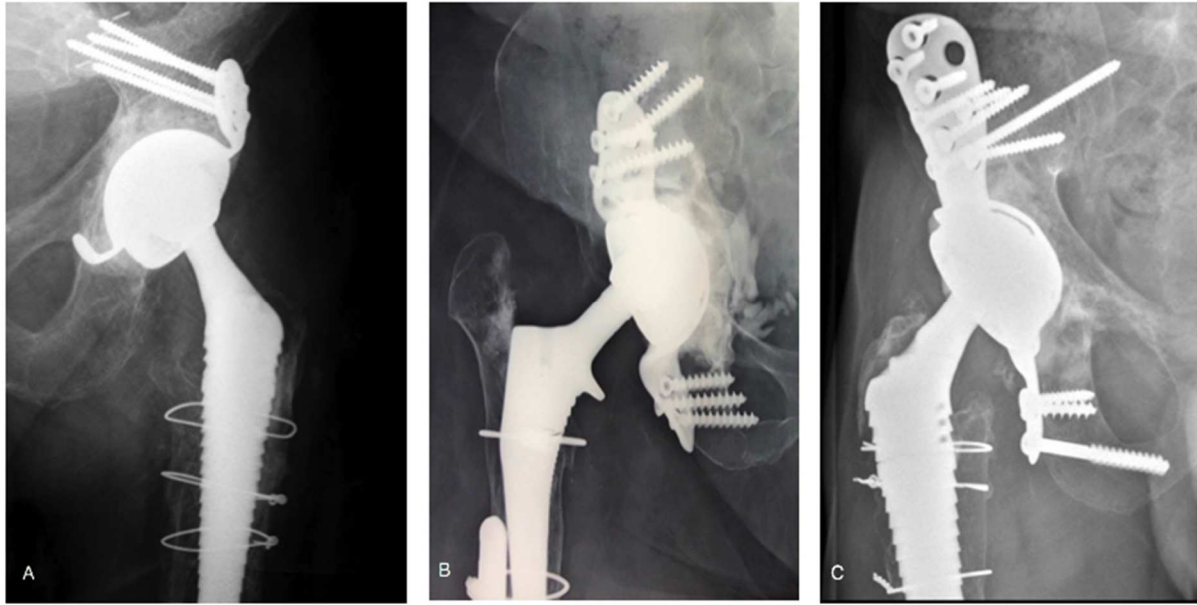
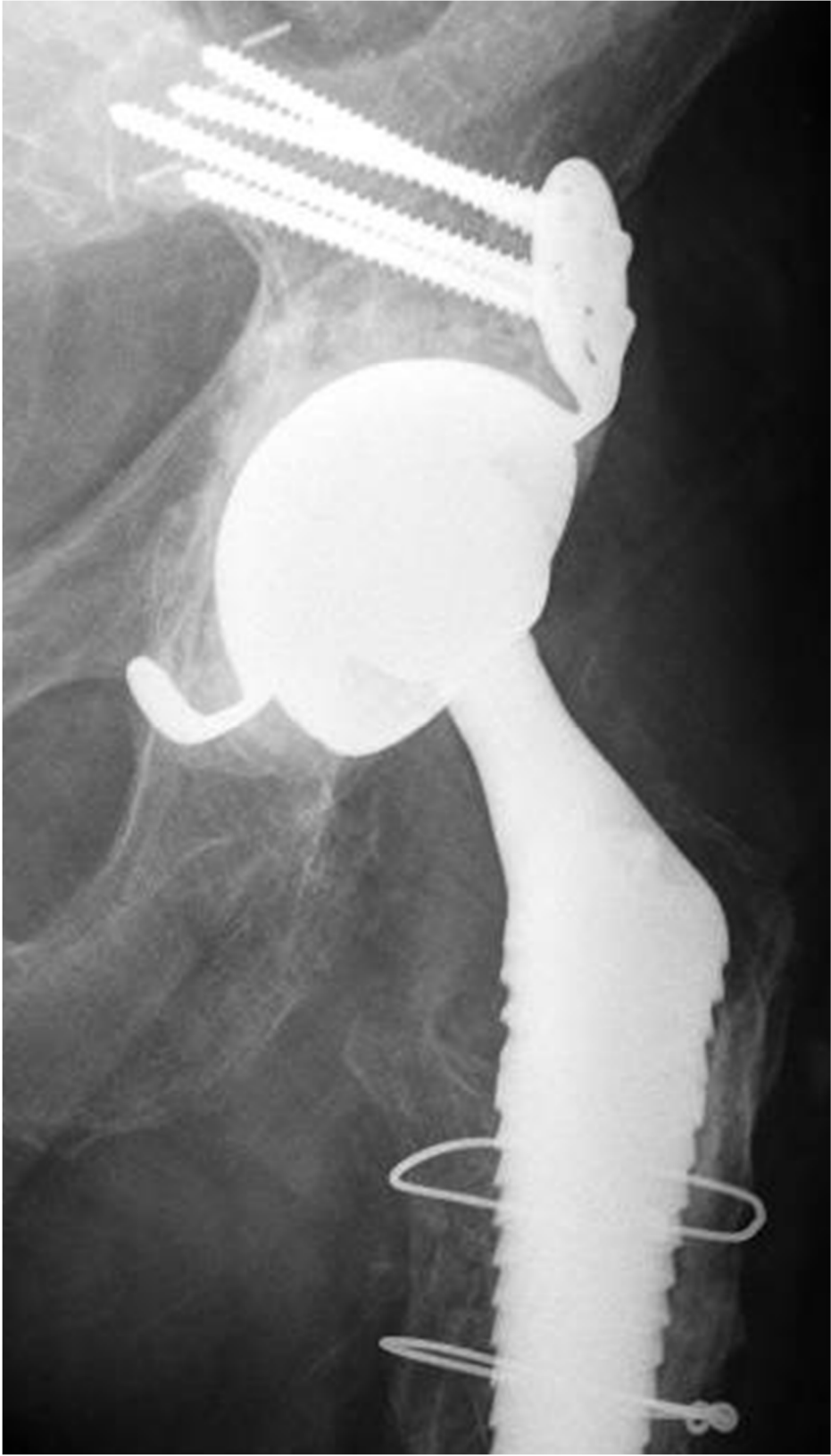

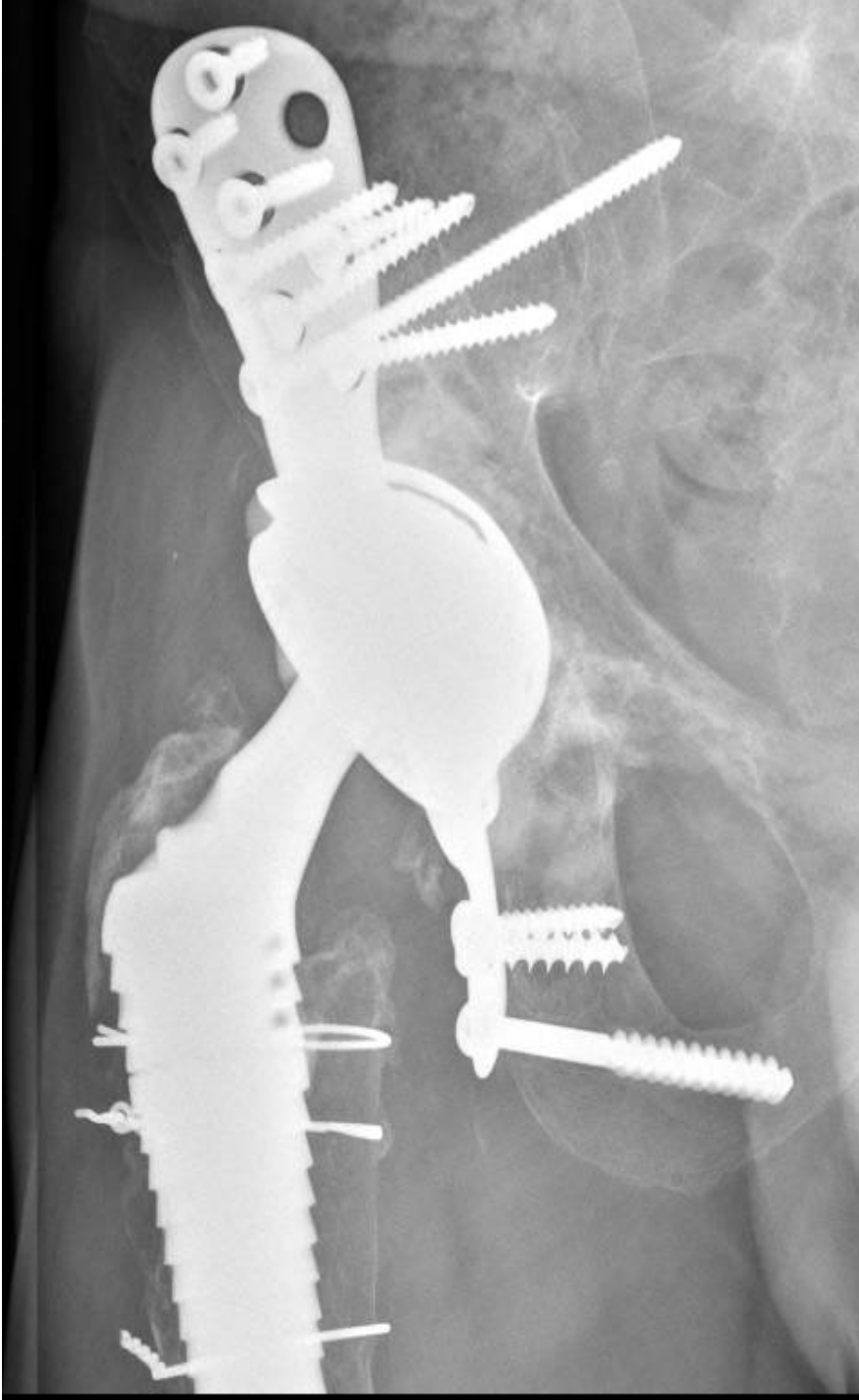Fig. 3: X-rays of patients with a DM cup inside a Kerboull cross (A), a Burch Schneider ring (B) or an ARM device (C) at 14 years' follow-up.



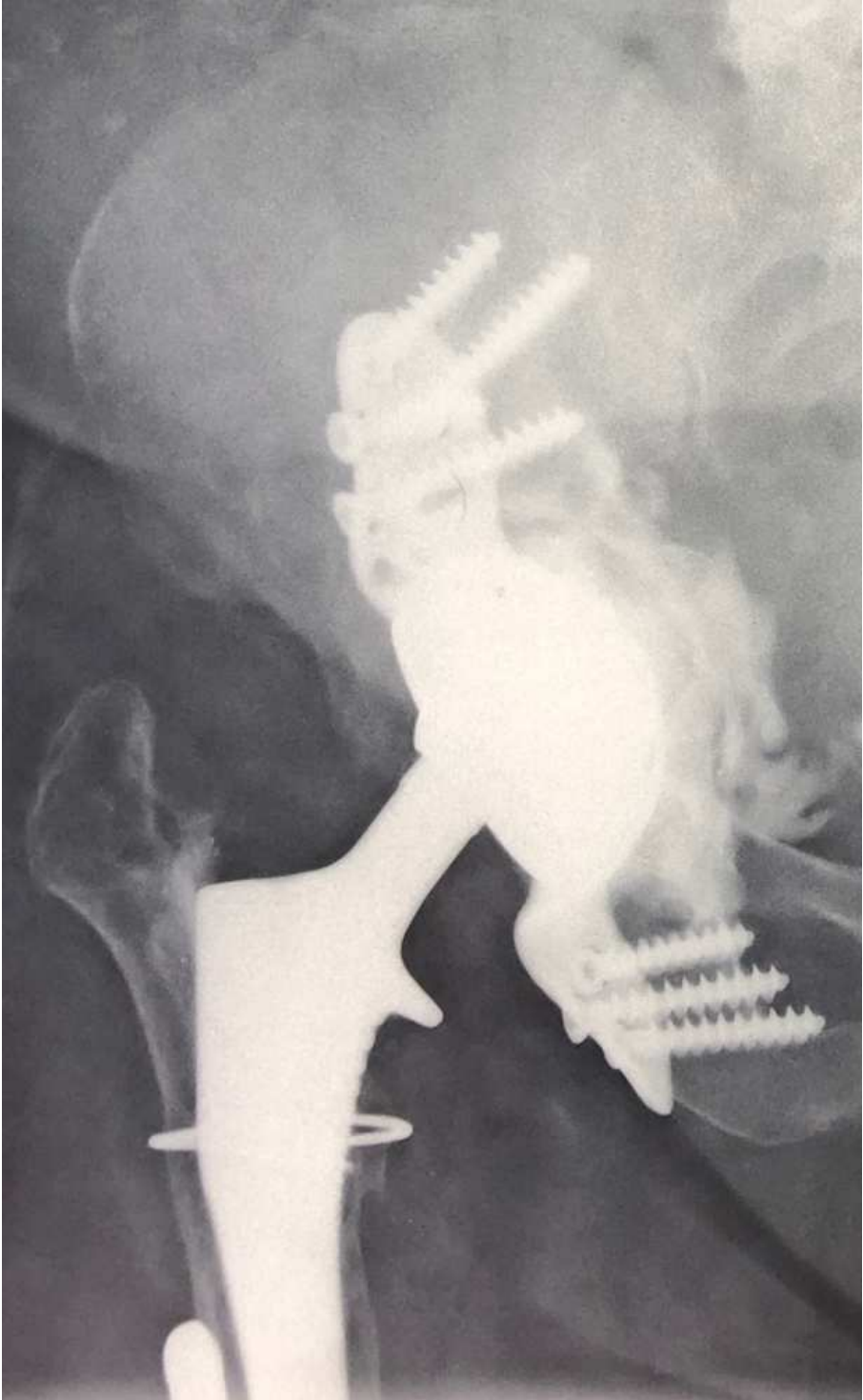
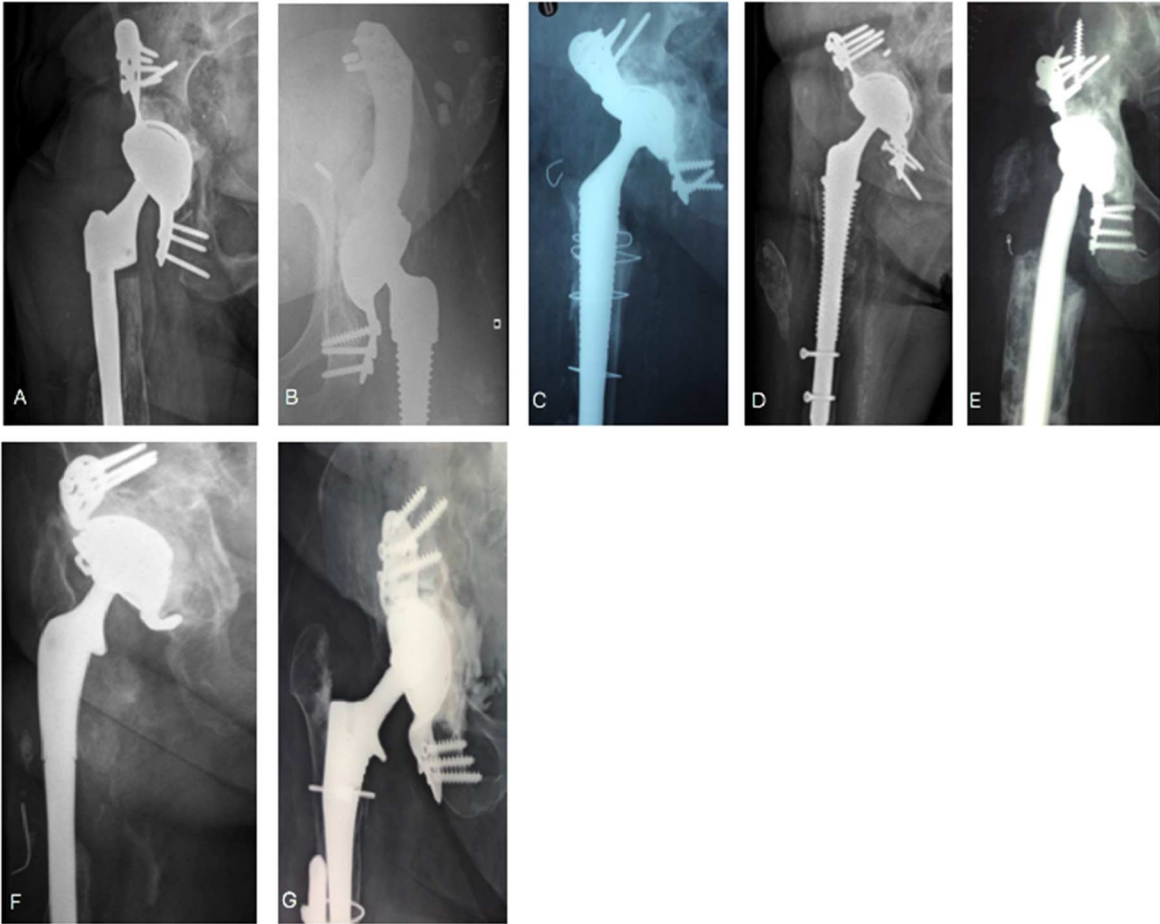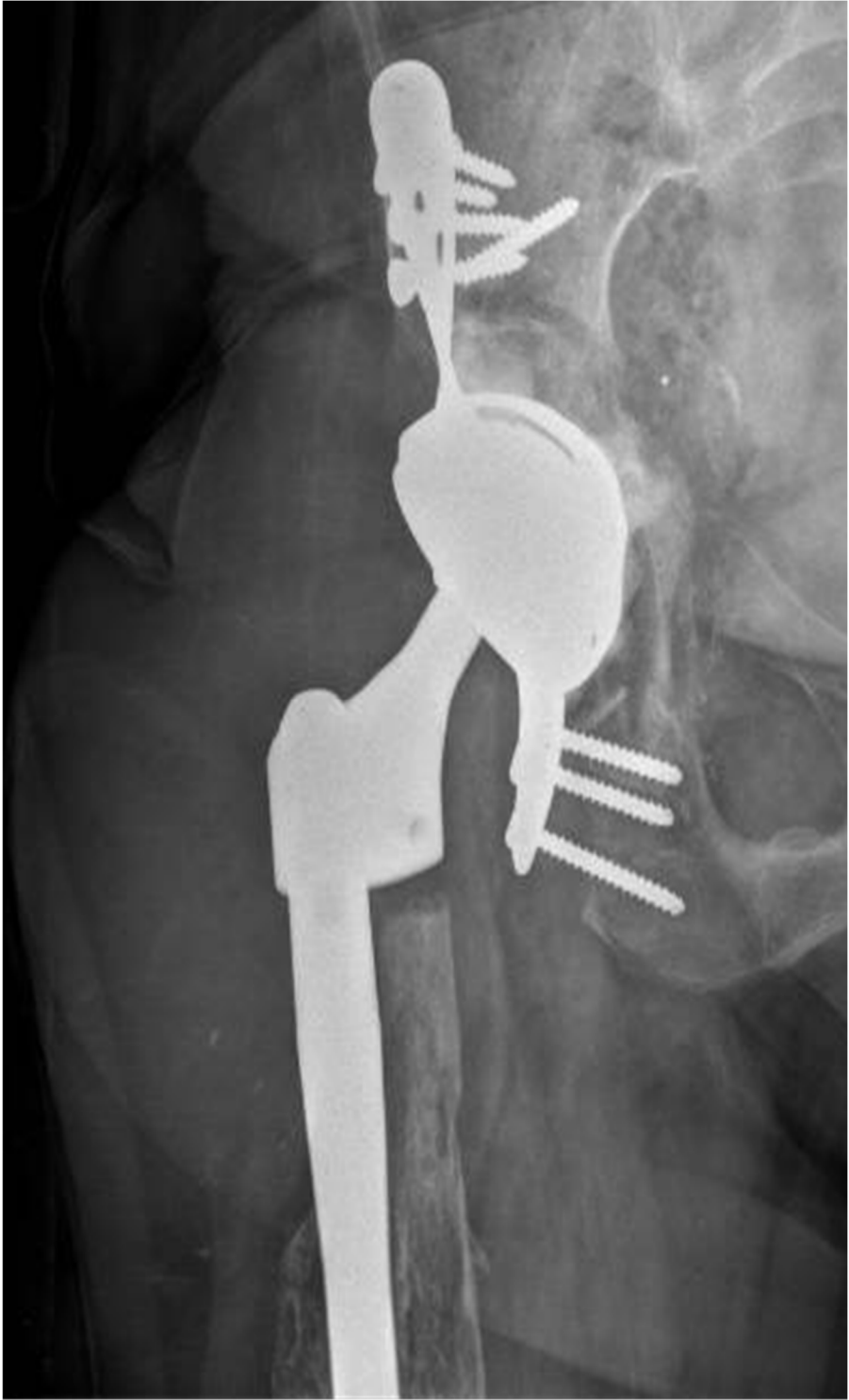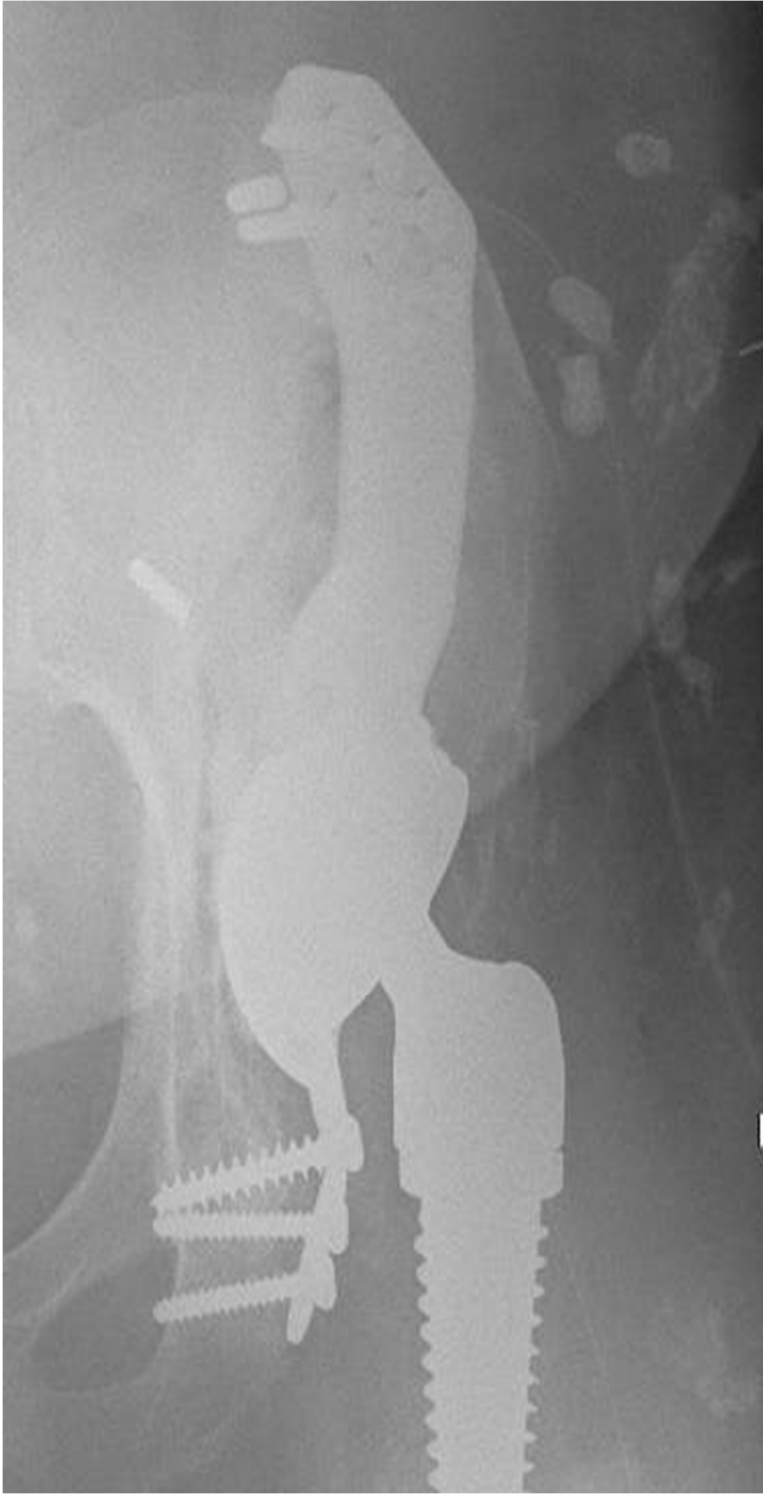


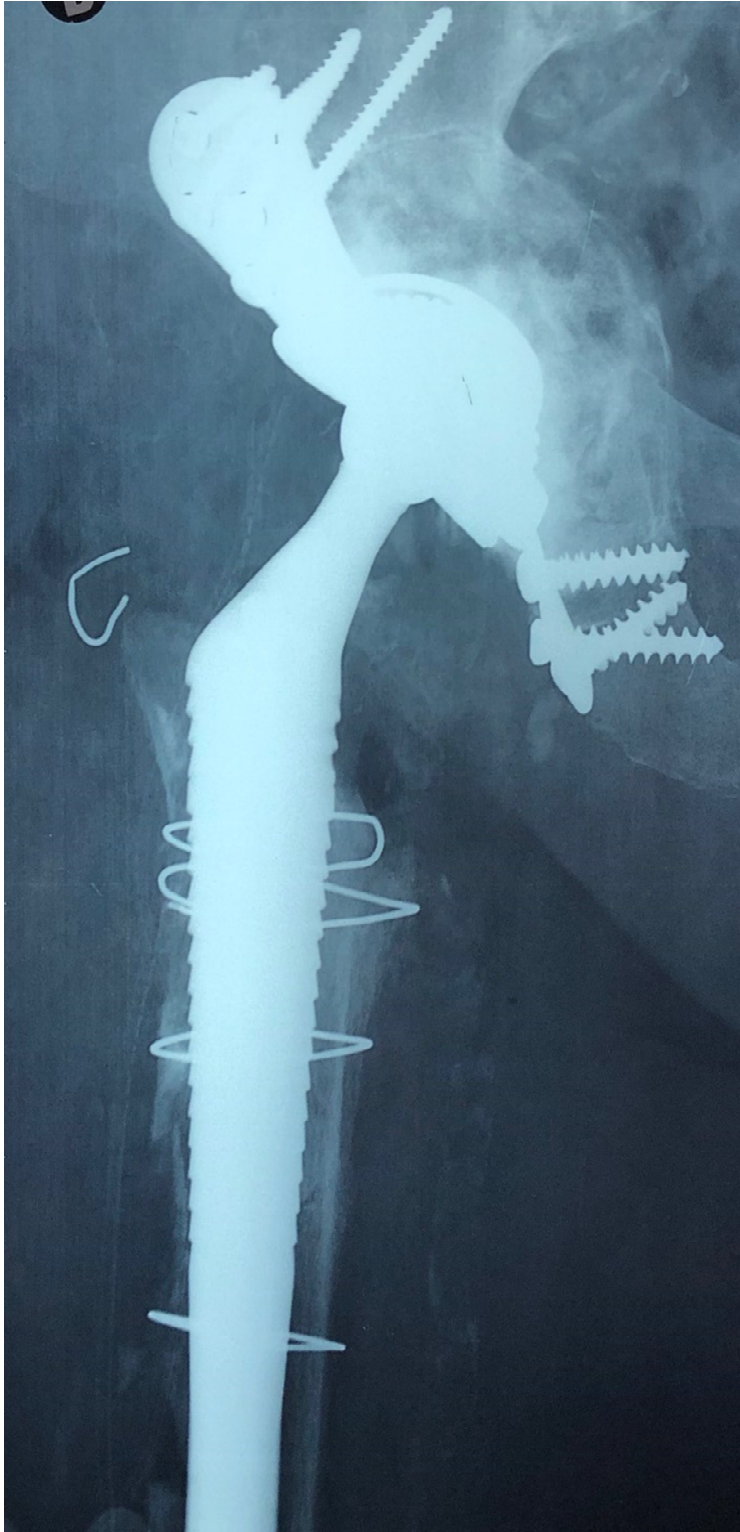



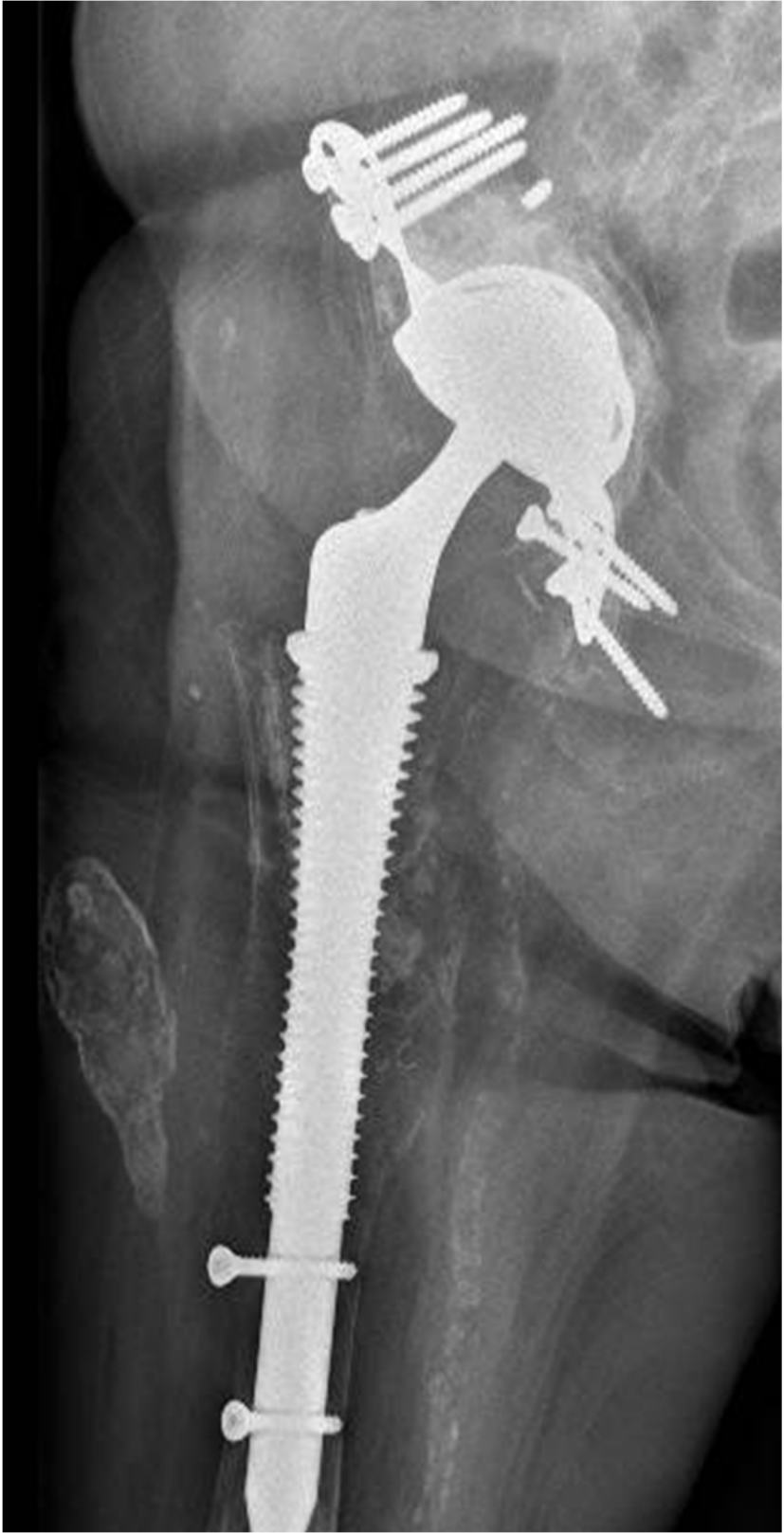
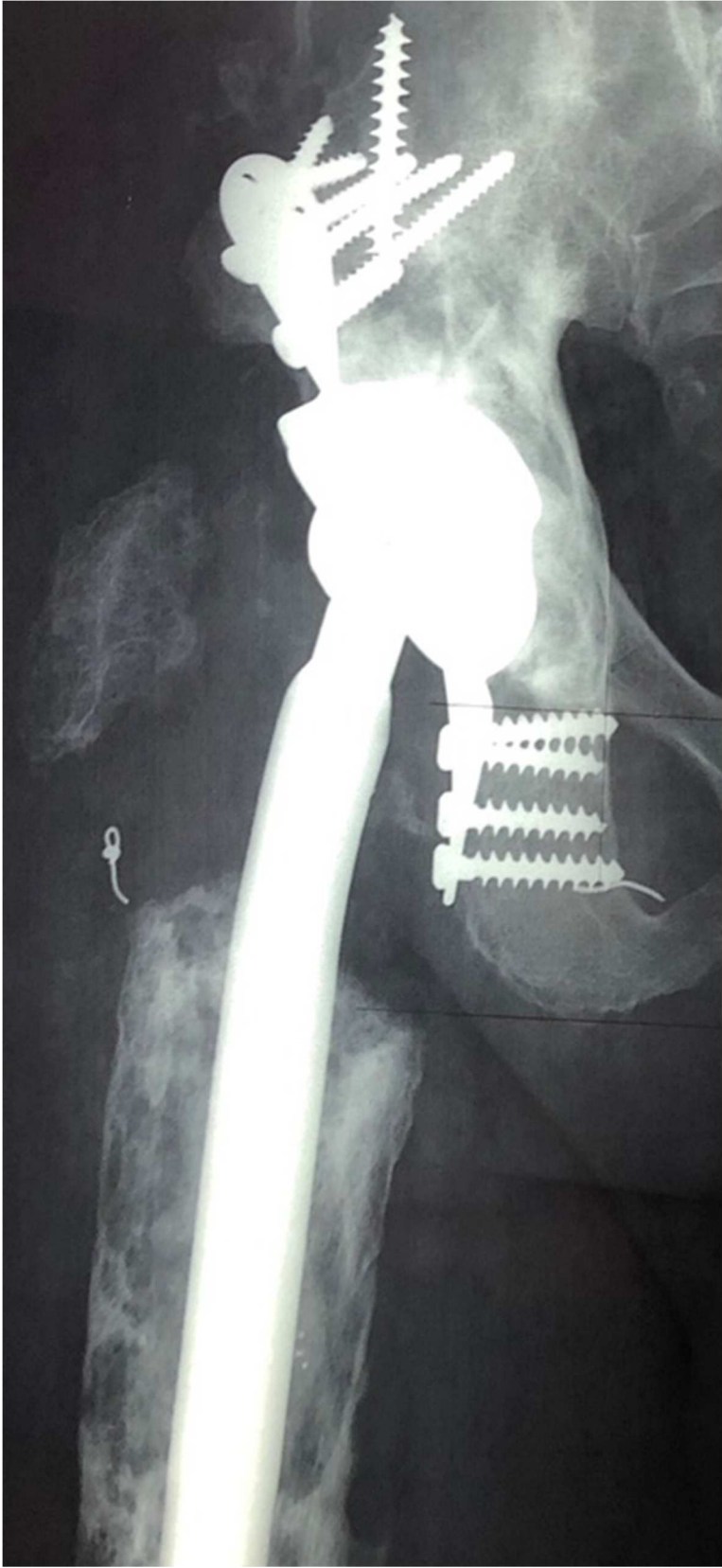
Fig 4: X-rays of the patients who suffered a dislocation. Patient A was plagued by chronic instability.

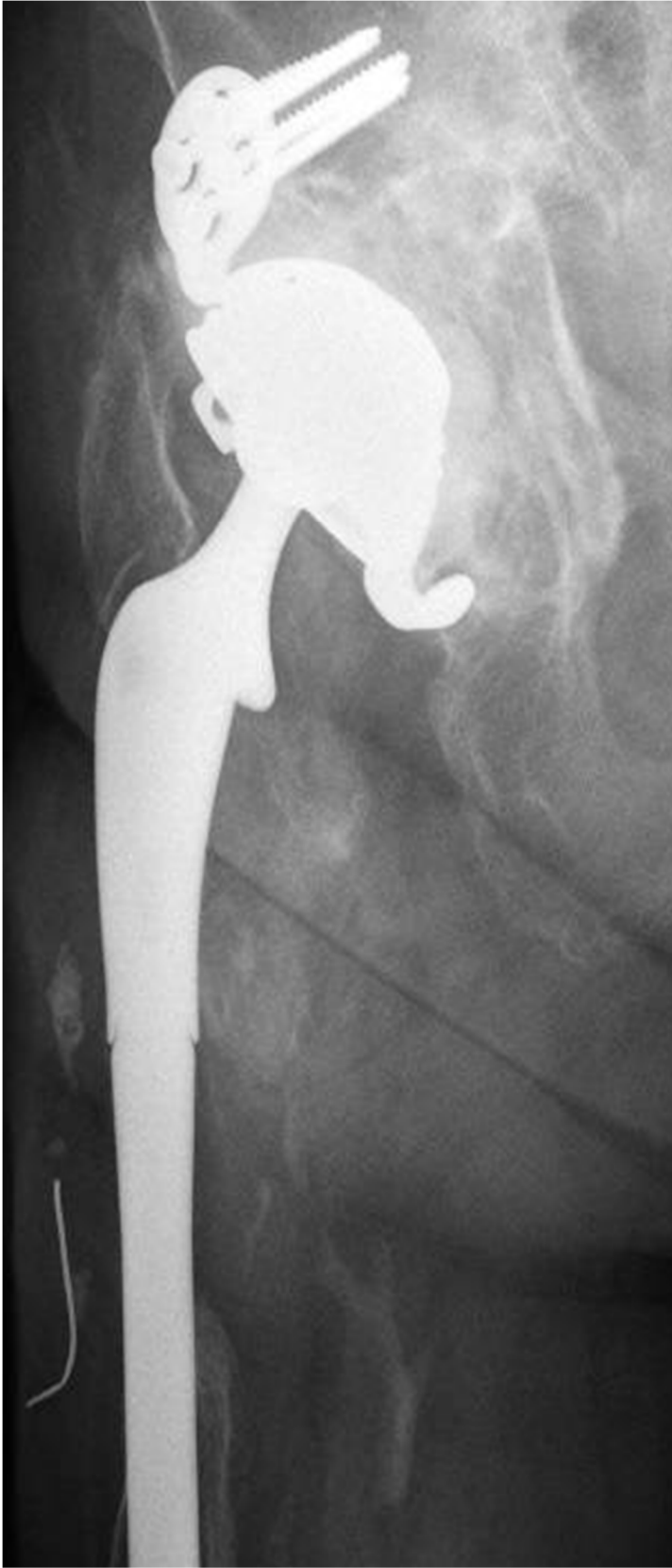

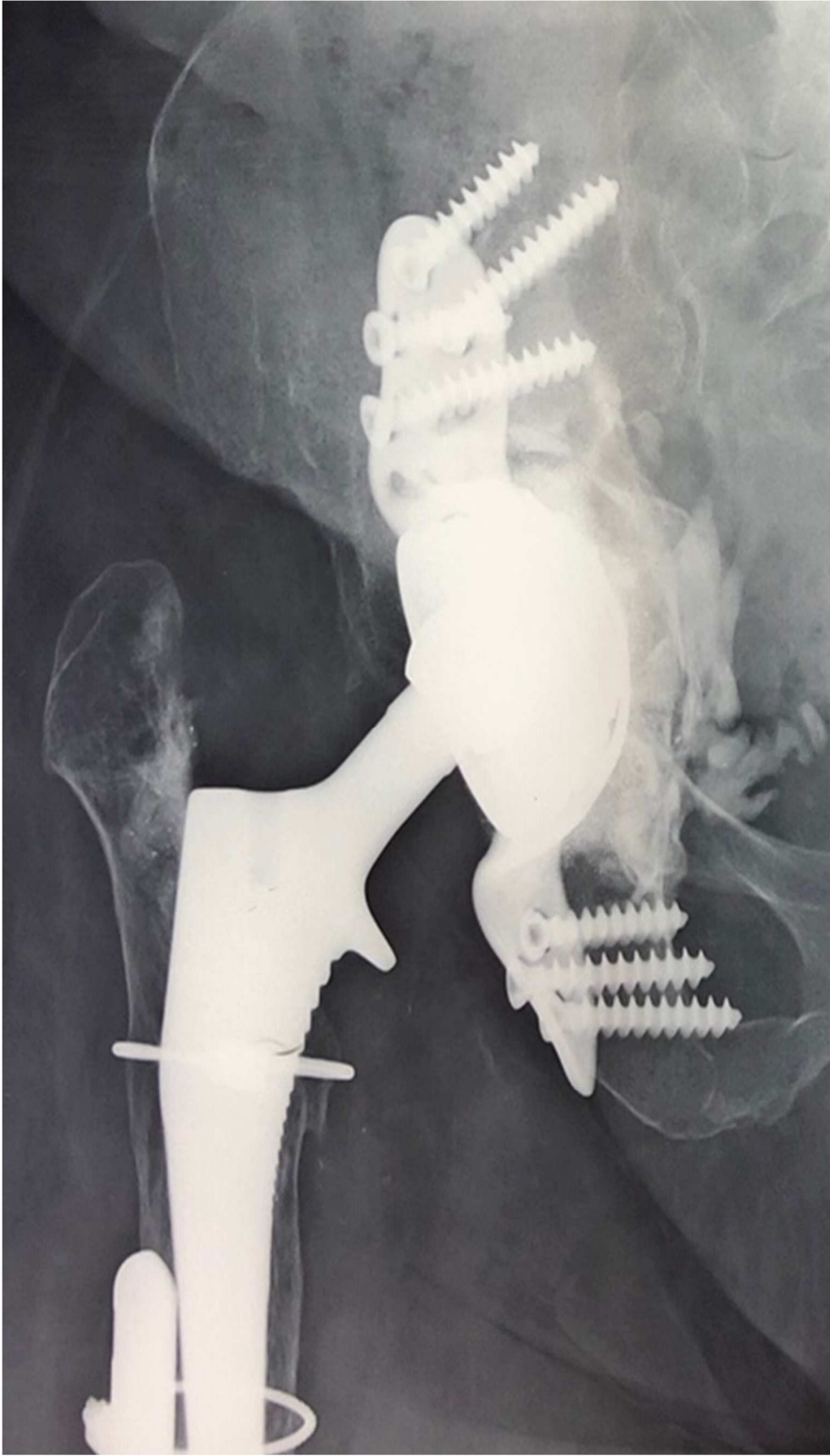












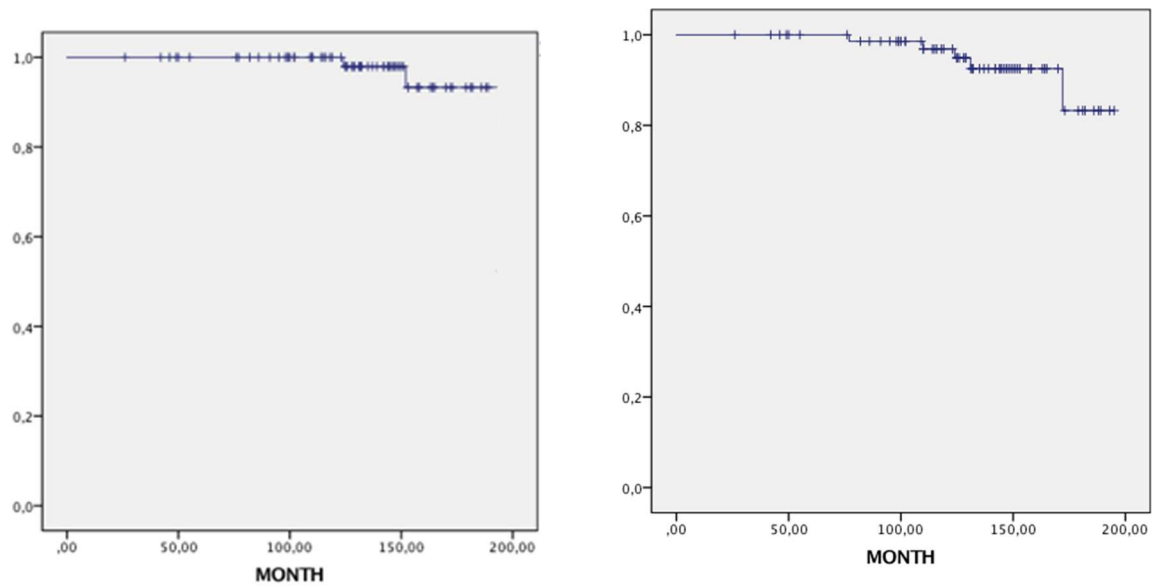


Fig 5: Cup survivorship, according to the Kaplan Meier method. Left chart: survival free of aseptic acetabular loosening. Right chart: all-cause survival for the cup.

Indications for acetabular revision	Study (n= 77)	Kerboull (n=59)	Burch Schneider (n=5)	ARM (n=13)
Bipolar loosening	17 (22.1%)	14		3
Acetabular loosening	32 (41.5%)	24	1	7
Femoral loosening (Hemiarthroplasties)	1 (1.3%)	1		
Postinfection reimplantation	10 (13%)	7	2	1
Recurrent dislocation / Wear	7 (9.1%)	7		
Intraprosthetic dislocation	1 (1.3%)	1		
Stiffness	2 (2.6%)	2		
Acetabular fracture < 85 years	2 (2.6%)			2
Femoral neck fracture < 85 years	1 (1.3%)	1		
Acetabular protrusion	4 (5.2%)	2	2	
Acetabular defects based on Paprosky classification	Study (n= 77)	Kerboull (n=59)	Burch Schneider (n=5)	ARM (n=13)
2A	4 (5.2%)	4		
2B	12 (15.6%)	12		
2C	18 (23.4%)	18		
3A	22 (28.6%)	18	1	3
3B	21 (27.3%)	7	4	10

Table 1: Indications for revision THA and Paprosky grade for acetabular defects

Complications		N (%)
With surgical revision: n = 12 (15.6%)		
<u>with</u> change of acetabular implants	Aseptic loosening	3 (3.89)
	Infection-related loosening	2 (2.89)
	Sciatic nerve impingement with metal ring	1 (1.29)
<u>without</u> change of implants	Surgical reduction of dislocation	3 (3.89)
	Drainage of compressive hematoma	1 (1.29)
	Treatment of greater trochanter nonunion	1 (1.29)
	Early infection (DAIR)	1 (1.29)
Without surgical revision: n = 7 (9.4%)		
	Closed reduction of dislocation	4 (5.19)
	Broken screw	2 (2.89)
	Greater trochanter fracture	1 (1.29)
	Total	19 (24.7)

DAIR: debridement, antibiotics and implant retention

Table 2: Complications in our study with or without surgical revision

Author	Year	Acetabular implants	N =	Acetabular Bone Loss	Mean FU (years)	Dislocation Rate (n) (%)	Re-operation rate for AL (n) (%)	Survival rate Any reason (%)
Langlais et al. [29]	2008	DMC Kerboull	88	AAOS: I: 21; III: 64; IV: 3	3	1 (1.2%)	2.3% (not reoperated)	94.6% at 5 years
Philippot et al. [5]	2009	DMC Kerboull / Burch-Schneider / ARM	163	AAOS: II:33%; III: 28%; IV:13%	5	6 (3.7%)	2 (1.2%)	96.1% at 7 years
Guyen et al. [30]	2009	DMC ± Cage	54	NA	2.2	1 (1.85%)	0	NA
Schneider et al. [25]	2011	DMC Kerboull / Burch-Schneider / ARM	96	SOFCOT: II: 8; III: 62; IV: 26	3.4	10 (10.4%)	1 (2%)	99.3% at 8 years
Civinini et al. [31]	2012	DMC Contour	33	PAPROSKY: 2A:21%; 2B:28%; 3A: 21%; 3B: 12%	3	0%	0%	97% at 5 years
Hailer et al. [32]	2012	DMC ± Cage (5%)	228	NA	2	4 (2%)	4 (2%)	93% at 2 years
Pattyn et al. [33]	2012	DMC + Ganz	37	NA	1.3	2 (5.4%)	0%	NA
Wegrzyn et al. [24]	2014	DMC Kerboull	61	AAOS: III: 54; IV: 7	7.4	0%	1 (2%)	98% at 7.5 years
Simian et al. [34]	2015	DMC Cementless ± Cage	74	NA	7.3	1 (1.4%)	1 (1.4%)	99% at 5 years
Mohammed et al. [35]	2015	DMC Cementless + DMC + Cage (n = 24)	44	NA	1.8	0%	0%	NA
Hamadouche et al. [23]	2016	DMC ± Kerboull	51	NA	8.5	1 (2%)	2 (3.9%)	75.2% at 10 years
Lebeau et al. [36]	2017	DMC + cage (Muller, Burch-Schneider, Link)	62	SOFCOT: II: 4; III: 45; IV: 9	6.4	1 (1.6%)	5 (6.4%)	91.9% at 8 years
Viste et al. [22]	2017	DMC Cementless + DMC Kerboull / Burch-Schneider / ARM	334 / 52 cage	AAOS	7	3.3% (Chronic instability 2.1%)	7 (13.5%)	NA
Chalmers et al. [37]	2018	DMC + Cage	18	NA	3	3 (17%)	0	NA
Our study	2019	DMC Kerboull / Burch-Schneider/ ARM	77	PAPROSKY: 2A:5.2%; 2B:15.6%; 2C: 23.4%; 3A: 28.6%; 3B: 27.3%	10.7	7 (9.45%) Chronic instability 1 (1.3%)	3 (3.89%)	92.2% at 10 years

Table 3: Main published studies of revision THA in which a dual mobility cup was used with an acetabular reinforcement device (AL: aseptic loosening, DMC: dual mobility cup)