



HAL
open science

Acute ischemic optic nerve disease: Pathophysiology, clinical features and management

E. Augstburger, E. Héron, A. Abanou, C. Habas, C. Baudouin, A. Labbé

► To cite this version:

E. Augstburger, E. Héron, A. Abanou, C. Habas, C. Baudouin, et al.. Acute ischemic optic nerve disease: Pathophysiology, clinical features and management. *Journal Français d'Ophthalmologie*, 2020, 43, pp.e41 - e54. <10.1016/j.jfo.2019.12.002>. <hal-03489583>

HAL Id: hal-03489583

<https://hal.science/hal-03489583v1>

Submitted on 22 Aug 2022

HAL is a multi-disciplinary open access archive for the deposit and dissemination of scientific research documents, whether they are published or not. The documents may come from teaching and research institutions in France or abroad, or from public or private research centers.

L'archive ouverte pluridisciplinaire **HAL**, est destinée au dépôt et à la diffusion de documents scientifiques de niveau recherche, publiés ou non, émanant des établissements d'enseignement et de recherche français ou étrangers, des laboratoires publics ou privés.



Distributed under a Creative Commons CC BY-NC 4.0 - Attribution - Non-commercial use - International License

Acute ischemic optic nerve disease: pathophysiology, clinical features and management.

Augstburger Edouard, MD,¹ Emmanuel Héron, MD,² Abdelouhab Abanou, MD,³ Christophe Habas, MD,^{3,5} Christophe Baudouin, MD, PhD,^{1,4,6} Antoine Labbé, MD, PhD.^{1,4,6}

- 1- Ophthalmology Service III, CHNO des Quinze-Vingts, IHU FOReSIGHT, Paris, France.
- 2- Internal medicine service, CHNO des Quinze-Vingts, Paris, France.
- 3- Neuroradiology center, CHNO des Quinze-Vingts, Paris, France.
- 4- CHNO des Quinze-Vingts, IHU FOReSIGHT, INSERM-DHOS CIC 1423, Paris, France.
- 5- Inserm, U968; UPMC Univ Paris 06, UMR_S968, Institut de la Vision; CNRS, UMR 7210; CHNO des Quinze-Vingts, INSERM-DHOS CIC 503, Paris, France.
- 6- Ophthalmology service, Hôpital Ambroise Paré, AP-HP, Université de Versailles Saint-Quentin-en-Yvelines, Versailles, France.

Disclosures: no conflicts of interest

Corresponding author: Prof. Antoine Labbé, MD, PhD, Service d'Ophtalmologie III, CHNO des Quinze-Vingts, 28 rue de Charenton, 75012 Paris, France.

E-mail: alabbe@15-20.fr

Tel: + 331 40021308

Fax: + 331 40021399

Abstract:

Ischemic optic neuropathies are among the leading causes of severe visual acuity loss in people over 50 years of age. They constitute a set of various entities that are clinically, etiologically and therapeutically different. Anatomically, it is necessary to distinguish anterior and posterior forms. From an etiological point of view, the diagnosis of the arteritic form due to giant cell arteritis requires emergent management to prevent blindness and even death in the absence of prompt corticosteroid treatment. When this diagnosis has been ruled out with certainty, non-arteritic ischemic optic neuropathies represent a vast etiological context that in the majority of cases involves a local predisposing factor (small optic nerves, disc drusen) with a precipitating factor (severe hypotension, general anesthesia or dialysis) in a context of vascular disease (sleep apnea syndrome, hypertension, diabetes, etc.). In the absence of specific available treatment, it is the responsibility of the clinician to identify the risk factors involved, in order to reduce the risk of contralateral recurrence that may occur even several years later. Due to their complexity, these pathologies are the subject of debates regarding both the pathophysiological and therapeutic perspectives; this review aims to provide a synthesis of validated knowledge while discussing controversial data.

Keywords: ischemic optic neuropathy, optical coherence tomography angiography

I) Introduction

Ischemic optic neuropathies represent one of the main causes of blindness and severe visual loss in subjects over 50 years of age, with an annual incidence estimated between 2.3-10.2/100,000 in the United States [1, 2]. Their clinical presentation, pathophysiology and management have been the object of numerous controversies and discussions over the past few decades [3–5]. They present most often with a clinical picture of acute, painless decreased visual acuity associated with a significant reduction in visual field. Anatomically, two clinical entities need to be distinguished: acute anterior ischemic optic neuropathy (AAION), involving the anterior part of the nerve or optic disc, and the more rare posterior ischemic optic neuropathy (PION) [6], which affects the retrolaminar portion of the optic nerve. AAION constitutes a frequent pathology in ophthalmologic emergency departments, for which the classic forms are easily diagnosed. It is, however, imperative to make a timely etiologic diagnosis and identify arteritic forms (of which the vast majority are associated with giant cell arteritis). In the case of bilateral involvement, the latter may lead to total blindness and must be treated immediately. With regard to the non-arteritic forms, while much more frequent, their pathophysiology remains a poorly understood source of debate, which explains why their ideal management has not yet been clearly described.

II) Optic nerve blood supply

Anatomically, one may consider the optic nerve as having two regions: anterior (the optic disc or optic nerve head, visible on fundus examination) and posterior (visible on MRI on certain cuts). The blood supply of the optic nerve depends on the ophthalmic artery, a branch of the internal carotid artery, which gives rise posteriorly to the central retinal artery (CRA) and then forms the posterior ciliary arteries (PCA).

II.1 Blood supply of the posterior portion of the optic nerve

The intracranial portion of the optic nerve (post-chiasmal) depends only upon the pial vascular plexus, supplied by a variable number of branches coming from the surrounding arteries: the superior hypophyseal artery, the anterior cerebral artery, the anterior communicating artery and the ophthalmic arteries.

The intracanalicular portion is supplied only by fine collaterals of the ophthalmic artery which travel through the inferior portion of the optic nerve.

The intra-orbital portion is supplied behind the point of entry of the ophthalmic artery by the centripetal peripheral vascular system formed by the pial vascular plexus and multiple collaterals coming directly from the ophthalmic artery and less often from other orbital arteries. The CRA enters the optic nerve 10 mm behind the globe. Between this point and the optic disc, the optic nerve is supplied by a double vascular system: a centripetal one formed by the pial vascular plexus and a centrifugal one (inconsistently) formed by the intraneural branches of the CRA.

II.2 Anatomy and blood supply of the optic disc

The optic disc corresponds to the intraocular portion of the optic nerve. It is classically divided into four sections from front to back: the retinal nerve fiber layer (RNFL), the prelaminar region, the lamina cribrosa, and the retrolaminar region. The blood supply of the optic disc depends essentially on the PCA's through the peripapillary choroid and the arterial circle of Zinn-Haller.

- The nerve fiber layer is situated on the surface of the optic disc and corresponds to retinal ganglion cell axons. It is essentially vascularized by capillaries dependent on

the retinal arteries. The radial peripapillary capillaries form a dense network parallel to the axons within the RNFL. Recently, the development of optical coherence tomography angiography (OCT-A) has allowed improved visualization of these structures and demonstration of their involvement in various optic neuropathies [7]. The cilioretinal artery, when present, supplies the sector adjacent to it and depends on the choroidal network, which is itself dependent on the PCA's.

- The prelaminar region consists of retinal nerve fibers, retinal vessels and glial cells. It is vascularized by branches coming from the peripapillary choroid. The blood supply in this region is sectioned according to the PCA's unique to each patient. There are many anatomic variations with regard to the number of PCA's: typically, there are two (one superior and one inferior, which probably explains the altitudinal nature of the visual field involvement), but this can vary from 1 to 5. These interindividual variations directly influence the pattern of perfusion of the choroid and optic nerve, explaining the distribution of ischemic regions in AAION according to the affected PCA(s). The CRA supplies no branches to this region.
- The lamina cribrosa (or laminar portion) is a structure continuous with the sclera, where fibrous septae cross the capillary plexus coming from the short PCA's. This plexus forms an anastomotic network: the circle of Zinn-Haller.
- The retrolaminar region marks the beginning of axonal myelination and depends on a double vascular network formed by branches of the central retinal artery as well as branches of the peripapillary choroid or short PCA's.

Venous drainage occurs through the central retinal vein, except for the prelaminar region, which is also drained by the peripapillary choroidal veins. The existence of this parallel

network explains the appearance of cilioretinal collaterals (optociliary shunt vessels) in central retinal vein occlusions posterior to the lamina cribrosa.

II.3 Factors influencing optic nerve perfusion

Blood perfusion of the optic nerve head depends both on local and regional blood perfusion as well as resistance to flow. Currently, there is no reliable method to measure this perfusion pressure in man [8]. Nonetheless, the perfusion pressure (P) within the optic disc may be estimated by the mean arterial pressure (MAP) minus the intraocular pressure (IOP), divided by the resistance to flow (R), i.e. $P=(MAP-IOP)/R$ [9]. This explains how variations in arterial pressure directly influence optic nerve head perfusion. Thus, it is strongly suspected that severe hypotension, by reducing optic disc perfusion, is the precipitating factor for ischemia in the majority of cases of non-arteritic AAION (NA-AAION).

To compensate for variations in systemic arterial pressure, there exists a general tissue mechanism whose objective is to maintain sufficient blood flow and constant capillary pressure despite changes in arterial pressure: autoregulation. This protective mechanism generally occurs in terminal arterioles through changes in their diameter and thus resistance to flow. The exact workings of autoregulation have not been completely elucidated, and various hypotheses have been advanced: metabolic (local concentration of metabolic products, decrease in pO₂ and increase in pCO₂), myogenic (increased intravascular pressure leading to vasoconstriction) or neurogenic [10, 11]. Given the absence of autonomic innervation of the retinal and optic disc vessels, it appears that the metabolic and myogenic mechanisms would be predominant. It has also been shown that capillary pericytes may play a role in autoregulation through the presence of the contractile proteins actin and myosin [12]. Nonetheless, there are significant limits to the mechanisms of constriction or dilation of capillaries and terminal arterioles; they do not react below a certain blood pressure threshold,

and they can be overwhelmed if perfusion exceeds the critical thresholds to too great an extent. Chronic HTN is a known vascular risk factor resulting in increased vascular resistance in terminal arterioles as well as loss of blood flow autoregulation with capillary damage.

Several studies in monkeys have attempted to establish the threshold for autoregulation within the optic nerve head: it appears that this mechanism ceases to function properly below 30 mmHg and above 50 mmHg [13]. However, it is difficult to extrapolate these results to man given the absence of a reliable means of measurement. The measurements found in the literature are most often performed on the optic disc surface by laser Doppler. Thus, they provide more of a measurement of central retinal artery flow than a true rate of capillary perfusion [14]. In addition to these mechanisms are interindividual variations and several systemic factors (age, blood pressure, diabetes, arteriosclerosis, or even dyslipidemia) whose influence is difficult to determine.

Ischemic optic nerve pathologies thus depend on a complex combination of local and systemic factors, explaining the debate and confusion which exists regarding their management.

III) Acute arteritic anterior ischemic optic neuropathy

III.1 Pathophysiology

Giant cell arteritis (GCA), or Horton's disease, is by far the main cause of arteritic AAION (A-AAION) [3]. A number of other causes have however been described and must be ruled out if the initial work-up comes back negative. These are essentially vasculitides such as periarteritis nodosa [15], systemic lupus erythematosus [16] or Churg-Strauss disease [17], but also types associated with chickenpox [18, 19] or amyloidosis [20].

Giant cell arteritis is a segmental, multifocal panarteritis (involvement of all three layers) preferentially affecting medium caliber arteries. Chronic inflammation results from tissue infiltration by T lymphocytes activated by antigen-presenting cells [21]. Histologically, lesions are seen which may or may not be associated with the presence of giant cells: infiltration of the intima and media with inflammatory cells (lymphocytes, monocytes and neutrophils), as well as destruction of the internal elastic lamina. This inflammation may cause thrombosis within the ophthalmic artery and one or more PCA's downstream [22]. The result is major, permanent ischemia of the optic disc and choroidal areas corresponding to the involved PCA's [23–25].

III.2 Clinical presentation

From all the retrospective studies, it is clear that A-AAION is rare prior to 50 years of age and that the mean age of onset is around 75 years, with 2.5 to 3 times higher risk in women [26, 27]. There is also a predominance in Caucasian subjects (particularly those of Scandinavian origin), which may suggest a genetic predisposition [22, 28]. It is an infrequent condition, with a frequency estimated at 0.36 per 100,000 people per year [1], although this is probably an underestimate. General symptoms of GCA include headaches, hyperesthesia of the scalp, and induration and absent pulse in the temporal arteries. Jaw claudication (pain or weakness worsening on chewing) is the most specific sign of the disease, but other symptoms, including a feeling of malaise, anorexia and weight loss, fever, inflammatory shoulder and pelvic pain (symptoms of polymyalgia rheumatica), must be inquired about on history [3]. Systemic involvement may include cerebrovascular accidents [29], myocardial infarction, and aortic aneurysms or dissection [30].

Visual symptoms inconsistently include transient or permanent decreased visual acuity, with eye pain and diplopia in the case of involvement of the cranial nerves to the extraocular muscles [28]. In 20% of cases of GCA, decreased visual acuity is the only symptom, with no other systemic signs [26].

III.2.1 Visual involvement

The change in visual function is often sudden and severe. A history of amaurosis fugax is found retrospectively in 1/3 of cases [31]. In giant cell arteritis, AAION is the most frequent cause of decreased visual acuity (80-90%), far ahead of CRAO (10%) and PION (5%) [26]. Without treatment, the risk of bilateral involvement is 50% within two months, but this generally occurs within the first 7 days. A large series of 170 cases of decreased visual acuity secondary to arteritic AAION published by Hayreh *et al.* [22] found a residual visual acuity \geq 5/10 in only 21% of cases, 1/10 to counting fingers in 24% of cases, and worse than hand motions in 38% of cases. Visual field involvement is classically more severe than in NA-AAION and depends on the number of PCA thromboses. On fundus examination, a non-specific clinical appearance of AAION is seen, with unilateral optic disc edema and peripapillary hemorrhages [22, 25, 31].

III.2.2 Imaging

Fluorescein angiography remains the standard ophthalmological examination for screening for arteritic cases and must be performed in subjects over 50 years of age if the clinical presentation is suggestive. In the early phase, choroidal ischemia can be seen, induced by PCA thrombosis [3, 24, 25]. This filling defect tends to reduce progressively due to collateral

circulation (Figure 1) [23]. A concomitant filling defect in the cilioretinal territory is possible, as this is also dependent on the PCA's.

III.2.3 Laboratory testing

If CGA is suspected clinically in a patient over 50 years of age, urgent bloodwork must be obtained to rule out inflammatory activity through an erythrocyte sedimentation rate (ESR), C-reactive protein (CRP) and complete blood count (CBC). The majority of GCA cases show a marked elevation in the ESR (70 mm/hr on average, often > 100 mm/hr), but in 16% of cases, it may be normal. The ESR increases physiologically with age or in anemia, thus levels above normal are common in patients over 70 years of age without arteritis. Measurement of C-reactive protein is more sensitive and less subject to physiologic variations. It routinely increases diagnostic precision and is currently recommended along with the ESR [32]. Thrombocytosis and normochromic normocytic anemia are the non-specific signs of inflammation which may also suggest GCA.

III.2.4 Temporal artery biopsy

If possible, the diagnosis of GCA should be confirmed by temporal artery biopsy (TAB), which is suggested any time strong clinical suspicion and suggestive laboratory results exist; however, it should not delay initiation of treatment. It does not need to be performed urgently, as the results take 2 weeks to become negative [32]. TAB is typically performed within the first week following initiation of steroid treatment. A negative biopsy does not rule out arteritis. The rate of false negative TAB's is on the order of 25% due to the discontinuous arterial involvement [33]. Thus, biopsy specimens must be at least 2 cm long so as to minimize the risk of an insufficient sample. If the initial biopsy comes back negative,

a contralateral biopsy may be considered, although it is rarely helpful [34]. Diagnostic imaging techniques: color Doppler ultrasonography of the temporal arteries [35–37], positron emission tomography [38] and magnetic resonance imaging [39] of the major arteries may be useful in diagnosing GCA, especially in cases where the TAB is non-contributory [40].

III.3 Prise en charge

When A-AAION is suspected, rapid initiation of treatment is essential. Intravenous methylprednisolone (500 to 1000 mg/day for the first 3 day) is recommended in the presence of decreased visual acuity, then switching to 1 mg/kg oral prednisone or equivalent. Oral treatment may be initiated from the start if IV administration would risk delaying treatment or posing a safety problem (especially patients on oral anticoagulants). High dose oral steroids must be maintained until the CRP and then the ESR normalize, typically within 2 weeks [3]. The dose can then be tapered over a period of 12 to 18 months before attempting discontinuation [41]. Steroids generally do not improve vision, but they prevent new ischemic events. Improvement in visual acuity (≥ 2 lignes) after the onset of A-AAION is atypical and varies between 4 and 29% of cases depending on the series [42–44]. Worsening is even possible in approximately 10% of cases within five days of starting treatment, which must not be interpreted as a misdiagnosis [42, 43]. The main risk is contralateral optic nerve involvement due to disease activity. Consequently, the steroid taper must be slow and cautious [3]. Reappearance of symptoms or re-elevation of the CRP calls for reassessment of disease activity and the steroid dose [44].

IV) Nonarteritic acute anterior ischemic optic neuropathy

IV.1 Pathophysiology

The pathophysiology of NA-AAION has been the subject of numerous controversies [45–47] and is still debated [4, 5]. It corresponds to acute ischemia of the optic nerve head secondary to low blood flow in the PCA's. For a number of decades, a thrombotic mechanism was the favored hypothesis, probably by analogy to A-AAION. While several cases have shown an embolic etiology on histology [48], Hayreh's many works have demonstrated that, in the vast majority of cases, the cause is transient hypoperfusion with patent PCA's rather than a true occlusion [3].

The hypothesis of a nonischemic origin in NA-AAION, in particular related to a posterior vitreous detachment (PVD) [4] has been criticized in the literature [5]. While acute vitreous traction can certainly induce local axonal edema and capillary hemorrhages, it is insufficient to induce optic disc edema severe enough to produce a clinical picture of NA-AAION. During vitreoretinal surgery, a PVD is also very often performed in an acute fashion without causing a secondary NA-AAION.

While there are statistical links between PVD and NA-AAION, it is probable that these are related to the fact that these two conditions occur in populations of similar age. Similarly, it is possible that the optic disc edema may itself induce a PVD through changes in the vitreopapillary interface which it induces (Figure 2).

This transient hypoperfusion is enough to induce optic disc edema, which corresponds to swollen axons of the peripapillary RNFL [49]. Since these fibers are very sensitive to ischemia, this creates a vicious cycle: the edema of the nerve fibers thus leads to compression of the peripapillary capillaries [50], which tends to worsen the ischemia and local venous stasis. Disc edema localized within the rigid, narrow scleral canal [51], also leads to compression and slowed flow within the retinal vessels [52].

The causes of transient hypo- or even non-perfusion of the optic disc are probably multiple and interrelated [53]. From the available evidence, there are on one hand local risk factors

which seem to predispose the optic nerve head to ischemic events, especially small discs known as “discs at risk” [54, 55] (cup/disc ratio < 0.2), even more so if optic nerve drusen are present [56]; and on the other hand, precipitating factors which induce an acute slowing of perfusion within the PCA’s, leading to the clinical presentation of NA-AAION. This appears to be essentially a nocturnal hypoperfusion [3, 5, 57], often associated with sleep apnea syndrome [58, 59]. Less frequently, an internal carotid or ophthalmic artery stenosis is found, or even associated ocular ischemic syndrome [60].

This blood pressure drop, if prolonged and severe, leads to decreased perfusion of the optic nerve head capillaries below the autoregulation threshold, leading to the clinical picture of NA-AAION. Other risk factors have been implicated, especially pharmacologic. Several cases have been described in the literature of NA-AAION occurring after taking phosphodiesterase 5 inhibitors (PDE5i) such as sildenafil citrate (Viagra), which can be explained by their vasodilatory, and thus hypotensive, action in men often of advanced age with other cardiovascular risk factors. One observational study reported a 2.15 times greater risk of NA-AAION in cases of PDE5i use within the 30 days preceding the decrease in visual acuity [61]. Taking amiodarone has also been associated with NA-AAION [62].

IV.2 Clinical presentation

NA-AAION is a pathology which typically affects younger subjects than A-AAION. A retrospective study of 655 patients (931) eyes found a mean age of 60 years, a male predominance (60%) and a higher proportion of Caucasian subjects compared to other ethnic groups [63]. The proportion of subjects less than 45 years of age varies between 11 and 23% depending on the series [64].

Aside from decreased visual acuity, a relative afferent pupillary defect is found on the affected side. On fundus examination, optic disc edema is systematic in the acute stage. It

may be sectoral or involve all quadrants without correlation between the edematous sector and the visual field involvement, except sometimes in the very early stages [65]. Most often, the edema is accompanied by peripapillary flame hemorrhages coming from capillary involvement. The presence of exudate is inconsistent. The disc edema persists for eight weeks on average [66] and gives way to pallor and cupping related to the disappearance of nerve fibers (Figure 3). Examination of the fellow eye may be a diagnostic aid: a small disc is often found, with a cup/disc ratio ≤ 0.2 [55]. Frequently in elderly subjects, upon the onset of NA-AAION, one finds contralateral disc pallor corresponding to a previous subclinical episode [3]. Simultaneous bilateral NA-AAION is extremely rare outside of cases of severe hypotension related to dialysis [67, 68] or a state of shock [69].

Incipient or pre-symptomatic AAION [70] is a special, rare form corresponding to optic disc edema in patients suspected of having NA-AAION, but without an identifiable decrease in visual acuity or scotoma. In a cohort of 60 eyes, Hayreh *et al.* [71] found progression to a classic AAION presentation in 45% of cases, with a 55% prevalence of AAION in the fellow eye. After ruling out other causes of disc edema, it must be treated as full-blown NA-AAION, working the patient up for the same risk factors (Figure 4).

IV.2.1 Visual involvement

In the vast majority of cases, the visual loss is painless and discovered upon awakening. Visual acuity is preserved in nearly one third of the cases, greater than 5/10 in half of the cases, and less than 1/10 in one out of five cases [72]. Visual field involvement, however, is systematic, and performance of a Goldmann visual field is indispensable and should be repeated over time. It is classically described that an inferior altitudinal scotoma is the most common defect. In reality, these scotomata may occur in various shapes and sizes. In a study of 312 consecutive cases of NA-AAION, a central scotoma to I-2 was found in 49% of cases,

and an inferior altitudinal relative scotoma in 35% of cases [73]. The combination of an inferonasal absolute scotoma and an inferior relative defect is actually the most common [3]. Visual field involvement may be related to peripapillary nerve fiber involvement, although the correlation is not systematic, especially in the edematous stage. The relationship between the altitudinal scotoma and the PCA territories in which the hypoperfusion occurs is an attractive hypothesis, given that there are, in the majority of subjects, two PCA's each supplying the inferior and superior portions of the optic nerve head. In practice, variability in the number of PCA's and their dependent vascular territories renders this hypothesis of anatomic-clinical correlation difficult to verify [74].

The fact that this hypoperfusion is only transient probably explains the reason that the visual involvement is frequently less severe in nonarteritic cases than in arteritic cases, which result from thrombosis. In two large cohorts, it has been shown that over 40% of patients with NA-AAION achieve spontaneous improvement [47, 63]. Conversely, this percentage was essentially nil in A-AAION [32]. Worsening on the order of 15% at 6 months has also been reported. It appears that after this time frame, no change occurs. Recurrences in the same eye are rare (6.4% at 3 years), probably because axonal atrophy and enlargement of the optic cup after NA-AAION decreases the predisposing state, which was narrowing within the optic nerve head [75]. Contralateral recurrence is more frequent, estimated at 15% over 5 years [76].

IV.2.2 Imaging

NA-AAION does not classically require imaging, since it mainly results from hypotension. Nonetheless, if an embolic origin is suspected, or if there are unilateral headaches and neck pain, it may be necessary to complete a work-up of the supra-aortic vessels in order to rule out a carotid dissection [77].

On fluorescein angiography, non-specific optic disc edema is seen [66]. In rare cases of NA-AAION of embolic origin, an angiographic appearance similar to that of A-AAION is seen, since both result from complete occlusion of the PCA's.

On OCT, one finds a very significant increase in RNFL thickness in all quadrants in the disc edema stage, which gives way to sectoral thinning which is well-correlated to the visual field in the atrophic stage [78, 79] (Figure 5).

Thinning of the macular ganglion cell layer, in contrast, is present from the edematous stage, then changes very little [80–82]. It is an important and consistent diagnostic element which explains, in part, the degeneration of the cell bodies after profound ischemic involvement of their axons. One may also observe a papillomacular serous retinal detachment in the early stage [83], or even macular edema, probably due to venous congestion secondary to the disc edema.

Recently, OCT-A has demonstrated its role in optic neuropathies [7, 84, 85], particularly in NA-AAION, notably through the detailed visualization of the retinal vascular plexus *in vivo* [50] (Figure 5). After resolution of the edematous phase, one sees a substantial reduction in peripapillary capillary density in the zones corresponding to the zones of RNFL thinning. Ultimately, these territories correspond to the scotoma observed on the visual field. Despite the structural changes (secondary to the disc edema) which generate some artifacts during OCT-A acquisition, it appears that peripapillary capillary involvement occurs progressively over the weeks that the edematous phase lasts. These observations tend to show that the capillary dropout seen in NA-AAION is an ischemic phenomenon related to compression of microvascular structures within the edematous RNFL, and not secondary to a sudden non-perfusion. This explains the therapeutic approaches designed to reduce the duration of the disc edema, although no positive results have been obtained to date. Within the macula, there is also a decrease in the density of the superficial and deep capillary plexuses in the zones

which appear to be contiguous with the peripapillary involvement. This involvement of the capillary plexuses, in particular that of the superficial capillary plexus, very certainly participates in the ganglion cell layer thinning seen on OCT. Due to their anatomic proximity and functional dependency, involvement of the superficial capillary plexus must necessarily induce ischemia of the ganglion cell bodies, which results in another wave of atrophy. Recent clinical studies have also found strong correlations between the decreased visual acuity and macular capillary dropout [50, 86]. The disappearance of macular capillaries demonstrates that NA-AAION is not a pathology limited strictly to the optic nerve, but also an effect of a vascular disorder upstream.

IV.3 Management

To date, there is no consensus concerning the treatment of NA-AAION, since no treatment has proven effective through studies with high levels of statistical significance (Tableau 1).

IV.3.1 Surgical decompression of the optic nerve

In 1989, Sergott *et al.*[87] led a multicenter trial aiming to surgically decompress the optic nerve sheath in progressive cases of NA-AAION. The reasoning for this was based on the hypothesis that, after the initial ischemic event, the edema within the inflexible optic nerve sheath was due to elevated cerebrospinal fluid pressure and that it caused a blockage of axoplasmic transport responsible for progressive visual loss. Although the hypothesis first appealed to a part of the scientific community at the time and had led to the performance of several trials, the results of this procedure were judged more harmful than withholding treatment, and the technique was quickly abandoned [47].

IV.3.2 Aspirin

The majority of studies carried out have not found a benefit to the administration of aspirin in the prevention of NA-AAION in the fellow eye, nor in improvement of visual symptoms after NA-AAION [76, 88]. These results can be explained by the fact that NA-AAION is not a primarily thromboembolic pathology. However, though no ocular benefit can be expected, the administration of low-dose daily aspirin may be considered for the general health of these elderly patients, who often have several cardiovascular risk factors, although this recommendation is increasingly debated [89, 90].

IV.3.3 Intravitreal anti-VEGF injection

A few case reports claim efficacy of anti-VEGF treatment in the acute stage. However, the only experimental study performed on a murine model found none of the expected neuroprotective effects [91], and the only prospective clinical study demonstrated no benefit of intravitreal bevacizumab injections for visual function [92].

IV.3.4 Intravitreal steroid treatment

Certain clinical trials and experimental data have observed a benefit of intravitreal triamcinolone administration [93–95]. The hypothesis rests on the idea of accelerating the regression of the optic disc edema with steroid treatment so as to decrease compression of the capillaries and thus improve circulation within the disc in order to save the surviving but non-functioning hypoxic axons. However, intravitreal steroid injections may also induce a transient intraocular pressure spike, leading conversely to a decrease in optic nerve perfusion. To date, there are insufficient clinical studies in agreement to justify performing this treatment.

IV.3.5 Systemic steroid treatment

There is not a consensus on systemic steroid treatment in NA-AAION. Few studies exist on the subject; however, a non-randomized controlled phase 3 study of 364 eyes treated with 80 mg per day of prednisone for 15 days followed by a taper was published in 2008 [96]. In the treated group, the results showed earlier resolution of the edema as well as a significant improvement in the six-month visual acuity (69.8% vs. 40.1%) and visual field (40% vs. 24.5%). Beyond this follow-up period, there was no change in these parameters. However, the absence of randomization and the open nature of the study, the higher proportion of elderly subjects and diabetics in the untreated group limited the applicability of the results. In addition, these results have never been confirmed by subsequent studies [97, 98].

IV.3.6 Neuroprotective agents

A number of additional potentially neuroprotective treatments, such as brimonidine [99], oxygen therapy [97], intravitreal [100] and systemic [101] erythropoietin, or even levo-dopa [102, 103], have been tried. These studies did not demonstrate convincing clinical effect, or, if a beneficial effect was observed, the level of proof turned out to be insufficient to justify a change in practice patterns. In the vast majority of these studies, the absence of a control group leads to doubt regarding the beneficial effect of these treatments, given the fact that visual function improves spontaneously in over 40% of patients once the optic disc edema regresses [72].

To date, there is thus no recommended treatment for NA-AAION. However, the search for and treatment of risk factors (Figure 4) must be performed jointly with other specialists in order to prevent a contralateral recurrence or another vascular event. In practice, it is essential to perform a sleep study, which will identify obstructive sleep apnea syndrome in a majority of cases, (nearly 90%). It is also important to perform a 24 hour blood pressure Holter monitor in treated hypertensive patients so as to identify episodes of nocturnal

hypotension. If positive, it is incumbent to adjust the dose of the hypotensive medications (eliminate any overdose) and to avoid, as much as possible, taking the medication just prior to bedtime [3].

V) Posterior ischemic optic neuropathy

This entity was first described by Hayreh in 1981 [104]. Since then, over 200 cases have been reported in the literature [6, 105, 106]. The true incidence is difficult to estimate, as it is often a diagnosis of exclusion after ruling out various retinal conditions, AAION, retrobulbar and compressive optic neuropathies, central nervous system involvement or masquerade syndromes. Nonetheless, the growing use of diffusion weighted MRI over the last decade has improved radiologic identification of this pathology, which is now able to be imaged and precisely defined (Figure 6) [107–110].

V.1 Pathophysiology

The cohorts of PION have identified three types: PION of arteritic origin (A-PION) associated with giant cell arteritis, non-arteritic PION (NA-PION), and PION secondary to a surgical procedure. Also found in the literature are a few reported cases related to inflammatory diseases [111, 112] or cancers [113]. The largest cohort of PION, published by Sadda *et al.* [105], found, out of 72 cases: 53% NA-PION, 39% PION secondary to surgery, and 8% A-PION.

A-PION is approximately ten times less frequent than the anterior form and is related to involvement of the orbital arteries by giant cell arteritis. With regard to NA-PION, a higher prevalence of cardiovascular risk factors (diabetes, HTN), ischemic heart disease, carotid disease and peripheral vascular disease has been identified in these patients. There are also cases secondary to PDE5i [114], which highly suggests a hypotensive origin just like NA-AAION.

Post-surgical PION classically manifests as a permanent, profound, unilateral or bilateral decrease in visual acuity appearing after surgery [115]. Its medical-legal implications are great. It actually differs from NA-PION only in that the hypotensive triggering factor is iatrogenic in this case. These cases have been reported during multiple surgical procedures, which may be ophthalmologic, vascular, orthopedic or neurologic. The main common factors appear to be severe, long-lasting hypotension (due to abundant bleeding or prolonged general anesthesia) [107], hemodilution induced by intravenous fluid replacement [116, 117], anemia [118], orbital and periorbital edema [119]. Rare cases secondary to torsion during cryo-indentation or strabismus surgery have been described [6, 105].

V.2 Clinical presentation

In the series published by Hayreh *et al.* [6], the visual acuity was less than or equal to 1/10 in 50% of cases of NA-PION and 69% of cases of A-PION. In the patients with post-surgical PION, visual acuity was most often limited to light perception. Visual field involvement was variable, but central involvement was most frequent and found in 84% of NA-PION and 69% of A-PION.

Clinically, there is no anterior segment involvement aside from a relative afferent pupillary defect in unilateral cases. Most often, there is no optic disc edema or angiographic abnormality, but generalized disc pallor may appear after 6 to 8 weeks.

Rapid, systematic performance of a diffusion-weighted brain MRI with cuts centered on the optic nerves is a large diagnostic aid: it can rule out a cerebrovascular accident and detect a characteristic hypersignal along the posterior portion of the optic nerve [107–109].

V.3 Management

Management depends essentially on the etiology. In cases of A-PION, it is similar to that of A-AAION, with institution of early steroid treatment to limit any risk of bilateral involvement or systemic involvement with GCA. In cases of NA-PION and post-surgical PION, there is no curative treatment, and it is valuable to best treat the risk factors while watching for possible recovery. The prognosis, however, is poor, especially in post-surgical cases, where the absence of improvement is particularly frequent [105].

VI) Conclusion

It is now established that ischemic optic neuropathy is not a single disease, but a category containing several quite distinct disease entities, each with its own etiologic, clinical and therapeutic characteristics. Currently, there are few recommendations regarding their management, especially because of the absence of appropriate treatments. This results from a still incomplete understanding of the pathophysiology of these diseases, primarily related to the difficulty in visualizing the affected nervous and microvascular structures. In the near future, the adoption of new imaging techniques will improve our anatomic and clinical understanding of these pathologies.

References

1. Johnson LN, Arnold AC (1994) Incidence of nonarteritic and arteritic anterior ischemic optic neuropathy. Population-based study in the state of Missouri and Los Angeles County, California. *J Neuroophthalmol* 14:38–44
2. Hattenhauer MG, Leavitt JA, Hodge DO, Grill R, Gray DT (1997) Incidence of nonarteritic anterior ischemic optic neuropathy. *Am J Ophthalmol* 123:103–107
3. Hayreh SS (2009) Ischemic optic neuropathy. *Prog Retin Eye Res* 28:34–62
4. Parsa CF, Hoyt WF (2015) Nonarteritic anterior ischemic optic neuropathy (NAION): a misnomer. Rearranging pieces of a puzzle to reveal a nonischemic papillopathy caused by vitreous separation. *Ophthalmology* 122:439–442
5. Hayreh SS (2015) Re: Parsa et al.: Nonarteritic anterior ischemic optic neuropathy (NAION): a misnomer. Rearranging pieces of a puzzle to reveal a nonischemic papillopathy caused by vitreous separation (*Ophthalmology* 2015;122:439-42). *Ophthalmology* 122:e75-76
6. Hayreh SS (2004) Posterior ischaemic optic neuropathy: clinical features, pathogenesis, and management. *Eye (Lond)* 18:1188–1206
7. Ghasemi Falavarjani K, Tian JJ, Akil H, Garcia GA, Sadda SR, Sadun AA (2016) SWEPT-SOURCE OPTICAL COHERENCE TOMOGRAPHY ANGIOGRAPHY OF THE OPTIC DISK IN OPTIC NEUROPATHY. *Retina (Philadelphia, Pa)* 36 Suppl 1:S168–S177
8. Hayreh SS (2001) The blood supply of the optic nerve head and the evaluation of it - myth and reality. *Prog Retin Eye Res* 20:563–593
9. Hayreh SS (2001) Blood flow in the optic nerve head and factors that may influence it. *Prog Retin Eye Res* 20:595–624
10. Cherecheanu AP, Garhofer G, Schmidl D, Werkmeister R, Schmetterer L (2013) Ocular perfusion pressure and ocular blood flow in glaucoma. *Curr Opin Pharmacol* 13:36–42
11. Schmidl D, Garhofer G, Schmetterer L (2011) The complex interaction between ocular perfusion pressure and ocular blood flow - relevance for glaucoma. *Exp Eye Res* 93:141–155
12. Anderson DR (1996) Glaucoma, capillaries and pericytes. 1. Blood flow regulation. *Ophthalmologica* 210:257–262
13. Hayreh SS, Bill A, Sperber GO (1994) Effects of high intraocular pressure on the glucose metabolism in the retina and optic nerve in old atherosclerotic monkeys. *Graefes Arch Clin Exp Ophthalmol* 232:745–752
14. Petrig BL, Riva CE, Hayreh SS (1999) Laser Doppler flowmetry and optic nerve head blood flow. *Am J Ophthalmol* 127:413–425
15. Hsu CT, Kerrison JB, Miller NR, Goldberg MF (2001) Choroidal infarction, anterior ischemic optic neuropathy, and central retinal artery occlusion from polyarteritis nodosa. *Retina (Philadelphia, Pa)* 21:348–351

16. Frigui M, Frikha F, Sellemi D, Chouayakh F, Feki J, Bahloul Z (2011) Optic neuropathy as a presenting feature of systemic lupus erythematosus: two case reports and literature review. *Lupus* 20:1214–1218
17. Lee JE, Lee SU, Kim SY, Jang TW, Lee SJ (2012) Anterior ischemic optic neuropathy in a patient with Churg-Strauss syndrome. *Korean J Ophthalmol* 26:469–472
18. Golas L, Bennett JL, White TM, Skarf B, Lesser R, Nagel MA, Gildea D (2015) Varicella Zoster Virus in Ischemic Optic Neuropathy. *Ophthalmology* 122:2142–2145
19. Buckingham EM, Foley MA, Grose C, Syed NA, Smith ME, Margolis TP, Thurtell MJ, Kardon R (2018) Identification of Herpes Zoster-Associated Temporal Arteritis Among Cases of Giant Cell Arteritis. *Am J Ophthalmol* 187:51–60
20. Reynolds MM, Veverka KK, Gertz MA, Dispenzieri A, Zeldenrust SR, Leung N, Pulido JS (2018) OCULAR MANIFESTATIONS OF SYSTEMIC AMYLOIDOSIS. *Retina (Philadelphia, Pa)* 38:1371–1376
21. Weyand CM, Goronzy JJ (2003) Medium- and large-vessel vasculitis. *N Engl J Med* 349:160–169
22. Hayreh SS, Podhajsky PA, Zimmerman B (1998) Ocular manifestations of giant cell arteritis. *Am J Ophthalmol* 125:509–520
23. Valmaggia C, Speiser P, Bischoff P, Niederberger H (1999) Indocyanine green versus fluorescein angiography in the differential diagnosis of arteritic and nonarteritic anterior ischemic optic neuropathy. *Retina (Philadelphia, Pa)* 19:131–134
24. Sadun F, Pece A, Brancato R (1998) Fluorescein and indocyanine green angiography in arteritic anterior ischaemic optic neuropathy. *Br J Ophthalmol* 82:1344–1345
25. Siatkowski RM, Gass JD, Glaser JS, Smith JL, Schatz NJ, Schiffman J (1993) Fluorescein angiography in the diagnosis of giant cell arteritis. *Am J Ophthalmol* 115:57–63
26. Chen JJ, Leavitt JA, Fang C, Crowson CS, Matteson EL, Warrington KJ (2016) Evaluating the Incidence of Arteritic Ischemic Optic Neuropathy and Other Causes of Vision Loss from Giant Cell Arteritis. *Ophthalmology* 123:1999–2003
27. Gonzalez-Gay MA, Miranda-Filloo JA, Lopez-Diaz MJ, Perez-Alvarez R, Gonzalez-Juanatey C, Sanchez-Andrade A, Martin J, Llorca J (2007) Giant cell arteritis in northwestern Spain: a 25-year epidemiologic study. *Medicine (Baltimore)* 86:61–68
28. Patil P, Karia N, Jain S, Dasgupta B (2013) Giant cell arteritis: a review. *Eye Brain* 5:23–33
29. Zenone T, Puget M (2013) Characteristics of cerebrovascular accidents at time of diagnosis in a series of 98 patients with giant cell arteritis. *Rheumatol Int* 33:3017–3023
30. Eberhardt RT, Dhady M (2007) Giant cell arteritis: diagnosis, management, and cardiovascular implications. *Cardiol Rev* 15:55–61
31. Hayreh SS, Podhajsky PA, Zimmerman B (1998) Occult giant cell arteritis: ocular manifestations. *Am J Ophthalmol* 125:521–526

32. Hayreh SS, Zimmerman B (2003) Management of giant cell arteritis. Our 27-year clinical study: new light on old controversies. *Ophthalmologica* 217:239–259
33. Hunder GG, Bloch DA, Michel BA, Stevens MB, Arend WP, Calabrese LH, Edworthy SM, Fauci AS, Leavitt RY, Lie JT (1990) The American College of Rheumatology 1990 criteria for the classification of giant cell arteritis. *Arthritis Rheum* 33:1122–1128
34. Grossman C, Barshack I, Bornstein G, Ben-Zvi I (2015) Is temporal artery biopsy essential in all cases of suspected giant cell arteritis? *Clin Exp Rheumatol* 33:S-84-89
35. Diamantopoulos AP, Haugeberg G, Hetland H, Soldal DM, Bie R, Myklebust G (2014) Diagnostic value of color Doppler ultrasonography of temporal arteries and large vessels in giant cell arteritis: a consecutive case series. *Arthritis Care Res (Hoboken)* 66:113–119
36. Aranda-Valera IC, García Carazo S, Monjo Henry I, De Miguel Mendieta E (2017) Diagnostic validity of Doppler ultrasound in giant cell arteritis. *Clin Exp Rheumatol* 35 Suppl 103:123–127
37. Estrada Alarcón P, Reina D, Navarro Ángeles V, Cerdà D, Roig-Vilaseca D, Corominas H (2018) Doppler ultrasonography of superficial temporal artery in a cohort of patients with strong clinical suspicion of giant cell arteritis. *Med Clin (Barc)*. doi: 10.1016/j.medcli.2018.04.016
38. Lariviere D, Benali K, Coustet B, et al (2016) Positron emission tomography and computed tomography angiography for the diagnosis of giant cell arteritis: A real-life prospective study. *Medicine (Baltimore)* 95:e4146
39. Klink T, Geiger J, Both M, Ness T, Heinzelmann S, Reinhard M, Holl-Ulrich K, Duwendag D, Vaith P, Bley TA (2014) Giant cell arteritis: diagnostic accuracy of MR imaging of superficial cranial arteries in initial diagnosis-results from a multicenter trial. *Radiology* 273:844–852
40. Bowling K, Rait J, Atkinson J, Srinivas G (2017) Temporal artery biopsy in the diagnosis of giant cell arteritis: Does the end justify the means? *Ann Med Surg (Lond)* 20:1–5
41. Arashvand K, Alexander WL, Dasgupta B (2007) Duration of treatment after eye involvement in giant cell arteritis. *J Rheumatol* 34:1945
42. Hayreh SS, Zimmerman B (2003) Visual deterioration in giant cell arteritis patients while on high doses of corticosteroid therapy. *Ophthalmology* 110:1204–1215
43. Danesh-Meyer H, Savino PJ, Gamble GG (2005) Poor prognosis of visual outcome after visual loss from giant cell arteritis. *Ophthalmology* 112:1098–1103
44. Chan CC, Paine M, O’Day J (2001) Steroid management in giant cell arteritis. *Br J Ophthalmol* 85:1061–1064
45. Smith DB (1995) Ischemic optic neuropathy decompression trial. *JAMA* 274:612
46. Sadun AA (1993) The efficacy of optic nerve sheath decompression for anterior ischemic optic neuropathy and other optic neuropathies. *Am J Ophthalmol* 115:384–389
47. (1995) Optic nerve decompression surgery for nonarteritic anterior ischemic optic neuropathy (NAION) is not effective and may be harmful. The Ischemic Optic Neuropathy Decompression Trial Research Group. *JAMA* 273:625–632

48. Lieberman MF, Shahi A, Green WR (1978) Embolic ischemic optic neuropathy. *Am J Ophthalmol* 86:206–210
49. Contreras I, Noval S, Rebolleda G, Muñoz-Negrete FJ (2007) Follow-up of nonarteritic anterior ischemic optic neuropathy with optical coherence tomography. *Ophthalmology* 114:2338–2344
50. Augstburger E, Zéboulon P, Keilani C, Baudouin C, Labbé A (2018) Retinal and Choroidal Microvasculature in Nonarteritic Anterior Ischemic Optic Neuropathy: An Optical Coherence Tomography Angiography Study. *Invest Ophthalmol Vis Sci* 59:870–877
51. Miller NR, Arnold AC (2015) Current concepts in the diagnosis, pathogenesis and management of nonarteritic anterior ischaemic optic neuropathy. *Eye (Lond)* 29:65–79
52. Zhu W, Cui M, Yao F, Liao R, Liu L (2014) Retrobulbar and common carotid artery haemodynamics and carotid wall thickness in patients with non-arteritic anterior ischaemic optic neuropathy. *Graefes Arch Clin Exp Ophthalmol* 252:1141–1146
53. Hayreh SS, Joos KM, Podhajsky PA, Long CR (1994) Systemic diseases associated with nonarteritic anterior ischemic optic neuropathy. *Am J Ophthalmol* 118:766–780
54. Doro S, Lessell S (1985) Cup-disc ratio and ischemic optic neuropathy. *Arch Ophthalmol* 103:1143–1144
55. Saito H, Tomidokoro A, Tomita G, Araie M, Wakakura M (2008) Optic disc and peripapillary morphology in unilateral nonarteritic anterior ischemic optic neuropathy and age- and refraction-matched normals. *Ophthalmology* 115:1585–1590
56. Ayhan Z, Yaman A, Söylev Bajin M, Saatci AO (2015) Unilateral Acute Anterior Ischemic Optic Neuropathy in a Patient with an Already Established Diagnosis of Bilateral Optic Disc Drusen. *Case Rep Ophthalmol Med* 2015:730606
57. Hayreh SS, Zimmerman MB, Podhajsky P, Alward WL (1994) Nocturnal arterial hypotension and its role in optic nerve head and ocular ischemic disorders. *Am J Ophthalmol* 117:603–624
58. Palombi K, Renard E, Levy P, Chiquet C, Deschaux C, Romanet JP, Pépin JL (2006) Non-arteritic anterior ischaemic optic neuropathy is nearly systematically associated with obstructive sleep apnoea. *Br J Ophthalmol* 90:879–882
59. Aptel F, Khayi H, Pépin J-L, Tamisier R, Levy P, Romanet J-P, Chiquet C (2015) Association of Nonarteritic Ischemic Optic Neuropathy With Obstructive Sleep Apnea Syndrome: Consequences for Obstructive Sleep Apnea Screening and Treatment. *JAMA Ophthalmol* 133:797–804
60. Luo R, Liu S, Li X, Zhuo Y, Tian Z (2010) Fifty-eight cases of ocular ischemic diseases caused by carotid artery stenosis. *Chin Med J* 123:2662–2665
61. Campbell UB, Walker AM, Gaffney M, et al (2015) Acute nonarteritic anterior ischemic optic neuropathy and exposure to phosphodiesterase type 5 inhibitors. *J Sex Med* 12:139–151
62. Macaluso DC, Shults WT, Fraunfelder FT (1999) Features of amiodarone-induced optic neuropathy. *Am J Ophthalmol* 127:610–612

63. Hayreh SS, Zimmerman MB (2008) Nonarteritic anterior ischemic optic neuropathy: clinical characteristics in diabetic patients versus nondiabetic patients. *Ophthalmology* 115:1818–1825
64. Preechawat P, Bruce BB, Newman NJ, Biousse V (2007) Anterior ischemic optic neuropathy in patients younger than 50 years. *Am J Ophthalmol* 144:953–960
65. Arnold AC, Hepler RS (1994) Natural history of nonarteritic anterior ischemic optic neuropathy. *J Neuroophthalmol* 14:66–69
66. Hayreh SS, Zimmerman MB (2007) Optic disc edema in non-arteritic anterior ischemic optic neuropathy. *Graefes Arch Clin Exp Ophthalmol* 245:1107–1121
67. Bansal S, Ansons A, Vishwanath M (2014) Hypotension-induced blindness in haemodialysis patients. *Clin Kidney J* 7:387–390
68. Al-Kaabi A, Haider AS, Shafeeq MO, El-Naggari MA, El-Nour I, Ganesh A (2016) Bilateral Anterior Ischaemic Optic Neuropathy in a Child on Continuous Peritoneal Dialysis: Case report and literature review. *Sultan Qaboos Univ Med J* 16:e504–e507
69. Onaran Z, Tan FU, Yilmazbaş P, Onaran Y (2012) Bilateral non-arteritic anterior ischemic optic neuropathy following second-trimester spontaneous abortion-related haemorrhage. *J Clin Neurosci* 19:1445–1447
70. Rebolleda G, Muñoz-Negrete FJ (2009) [Incipient or presymptomatic nonarteritic anterior ischemic optic neuropathy]. *Arch Soc Esp Oftalmol* 84:151–154
71. Hayreh SS, Zimmerman MB (2007) Incipient nonarteritic anterior ischemic optic neuropathy. *Ophthalmology* 114:1763–1772
72. Hayreh SS, Zimmerman MB (2008) Nonarteritic anterior ischemic optic neuropathy: natural history of visual outcome. *Ophthalmology* 115:298-305.e2
73. Hayreh SS, Zimmerman B (2005) Visual field abnormalities in nonarteritic anterior ischemic optic neuropathy: their pattern and prevalence at initial examination. *Arch Ophthalmol* 123:1554–1562
74. Tesser RA, Niendorf ER, Levin LA (2003) The morphology of an infarct in nonarteritic anterior ischemic optic neuropathy. *Ophthalmology* 110:2031–2035
75. Hayreh SS, Podhajsky PA, Zimmerman B (2001) Ipsilateral recurrence of nonarteritic anterior ischemic optic neuropathy. *Am J Ophthalmol* 132:734–742
76. Newman NJ, Scherer R, Langenberg P, Kelman S, Feldon S, Kaufman D, Dickersin K, Ischemic Optic Neuropathy Decompression Trial Research Group (2002) The fellow eye in NAION: report from the ischemic optic neuropathy decompression trial follow-up study. *Am J Ophthalmol* 134:317–328
77. Biousse V, Touboul PJ, D'Anglejan-Chatillon J, Lévy C, Schaison M, Bousser MG (1998) Ophthalmologic manifestations of internal carotid artery dissection. *Am J Ophthalmol* 126:565–577

78. Deleón-Ortega J, Carroll KE, Arthur SN, Girkin CA (2007) Correlations between retinal nerve fiber layer and visual field in eyes with nonarteritic anterior ischemic optic neuropathy. *Am J Ophthalmol* 143:288–294
79. Gümüş A, Öner V (2015) Follow up of retinal nerve fiber layer thickness with optic coherence tomography in patients receiving anti-tubercular treatment may reveal early optic neuropathy. *Cutan Ocul Toxicol* 34:212–216
80. Kupersmith MJ, Garvin MK, Wang J-K, Durbin M, Kardon R (2016) Retinal Ganglion Cell Layer Thinning Within One Month of Presentation for Non-Arteritic Anterior Ischemic Optic Neuropathy. *Invest Ophthalmol Vis Sci* 57:3588–3593
81. Larrea BA, Iztueta MG, Indart LM, Alday NM (2014) Early axonal damage detection by ganglion cell complex analysis with optical coherence tomography in nonarteritic anterior ischaemic optic neuropathy. *Graefes Arch Clin Exp Ophthalmol* 252:1839–1846
82. Park SW, Ji YS, Heo H (2016) Early macular ganglion cell-inner plexiform layer analysis in non-arteritic anterior ischemic optic neuropathy. *Graefes Arch Clin Exp Ophthalmol* 254:983–989
83. Hedges TR, Vuong LN, Gonzalez-Garcia AO, Mendoza-Santiesteban CE, Amaro-Quierza ML (2008) Subretinal fluid from anterior ischemic optic neuropathy demonstrated by optical coherence tomography. *Arch Ophthalmol* 126:812–815
84. Lévêque P-M, Zéboulon P, Brasnu E, Baudouin C, Labbé A (2016) Optic Disc Vascularization in Glaucoma: Value of Spectral-Domain Optical Coherence Tomography Angiography. *Journal of Ophthalmology* 2016:1–9
85. Zéboulon P, Lévêque P-M, Brasnu E, Aragno V, Hamard P, Baudouin C, Labbé A (2017) Effect of Surgical Intraocular Pressure Lowering on Peripapillary and Macular Vessel Density in Glaucoma Patients: An Optical Coherence Tomography Angiography Study. *J Glaucoma* 26:466–472
86. Fard MA, Ghahvechian H, Sahrayan A, Subramanian PS (2018) Early Macular Vessel Density Loss in Acute Ischemic Optic Neuropathy Compared to Papilledema: Implications for Pathogenesis. *Transl Vis Sci Technol* 7:10
87. Sergott RC, Cohen MS, Bosley TM, Savino PJ (1989) Optic nerve decompression may improve the progressive form of nonarteritic ischemic optic neuropathy. *Arch Ophthalmol* 107:1743–1754
88. Beck RW, Hayreh SS, Podhajsky PA, Tan ES, Moke PS (1997) Aspirin therapy in nonarteritic anterior ischemic optic neuropathy. *Am J Ophthalmol* 123:212–217
89. Matthys F, De Backer T, De Backer G, Stichele RV (2014) Review of guidelines on primary prevention of cardiovascular disease with aspirin: how much evidence is needed to turn a tanker? *Eur J Prev Cardiol* 21:354–365
90. Lamendola P, Villano A, Fusco A, Leggio M (2018) Low-dose aspirin for primary cardiovascular prevention in diabetic patients: the issue to believe it or not. *Ann Transl Med*. doi: 10.21037/atm.2018.04.01

91. Huang T-L, Chang C-H, Chang S-W, Lin K-H, Tsai R-K (2015) Efficacy of Intravitreal Injections of Antivasular Endothelial Growth Factor Agents in a Rat Model of Anterior Ischemic Optic Neuropathy. *Invest Ophthalmol Vis Sci* 56:2290–2296
92. Rootman DB, Gill HS, Margolin EA (2013) Intravitreal bevacizumab for the treatment of nonarteritic anterior ischemic optic neuropathy: a prospective trial. *Eye (Lond)* 27:538–544
93. Kaderli B, Avci R, Yucel A, Guler K, Gelisken O (2007) Intravitreal triamcinolone improves recovery of visual acuity in nonarteritic anterior ischemic optic neuropathy. *J Neuroophthalmol* 27:164–168
94. Radoi C, Garcia T, Brugniart C, Ducasse A, Arndt C (2014) Intravitreal triamcinolone injections in non-arteritic anterior ischemic optic neuropathy. *Graefes Arch Clin Exp Ophthalmol* 252:339–345
95. Huang T-L, Wen Y-T, Chang C-H, Chang S-W, Lin K-H, Tsai R-K (2016) Efficacy of Intravitreal Injections of Triamcinolone Acetonide in a Rodent Model of Nonarteritic Anterior Ischemic Optic Neuropathy. *Invest Ophthalmol Vis Sci* 57:1878–1884
96. Hayreh SS, Zimmerman MB (2008) Non-arteritic anterior ischemic optic neuropathy: role of systemic corticosteroid therapy. *Graefes Arch Clin Exp Ophthalmol* 246:1029–1046
97. Pakravan M, Sanjari N, Esfandiari H, Pakravan P, Yaseri M (2016) The effect of high-dose steroids, and normobaric oxygen therapy, on recent onset non-arteritic anterior ischemic optic neuropathy: a randomized clinical trial. *Graefes Arch Clin Exp Ophthalmol* 254:2043–2048
98. Rebolleda G, Pérez-López M, Casas-Llera P, Contreras I, Muñoz-Negrete FJ (2013) Visual and anatomical outcomes of non-arteritic anterior ischemic optic neuropathy with high-dose systemic corticosteroids. *Graefes Arch Clin Exp Ophthalmol* 251:255–260
99. Wilhelm B, Lüdtkke H, Wilhelm H, BRAION Study Group (2006) Efficacy and tolerability of 0.2% brimonidine tartrate for the treatment of acute non-arteritic anterior ischemic optic neuropathy (NAION): a 3-month, double-masked, randomised, placebo-controlled trial. *Graefes Arch Clin Exp Ophthalmol* 244:551–558
100. Modarres M, Falavarjani KG, Nazari H, Sanjari MS, Aghamohammadi F, Homaii M, Samiy N (2011) Intravitreal erythropoietin injection for the treatment of non-arteritic anterior ischaemic optic neuropathy. *Br J Ophthalmol* 95:992–995
101. Pakravan M, Esfandiari H, Hassanpour K, Razavi S, Pakravan P (2017) The Effect of Combined Systemic Erythropoietin and Steroid on Non-arteritic Anterior Ischemic Optic Neuropathy: A Prospective Study. *Curr Eye Res* 42:1079–1084
102. Johnson LN, Guy ME, Krohel GB, Madsen RW (2000) Levodopa may improve vision loss in recent-onset, nonarteritic anterior ischemic optic neuropathy. *Ophthalmology* 107:521–526
103. Lyttle DP, Johnson LN, Margolin EA, Madsen RW (2016) Levodopa as a possible treatment of visual loss in nonarteritic anterior ischemic optic neuropathy. *Graefes Arch Clin Exp Ophthalmol* 254:757–764
104. Hayreh SS (1981) Posterior ischemic optic neuropathy. *Ophthalmologica* 182:29–41

105. Sadda SR, Nee M, Miller NR, Biouesse V, Newman NJ, Kouzis A (2001) Clinical spectrum of posterior ischemic optic neuropathy. *Am J Ophthalmol* 132:743–750
106. Berg KT, Harrison AR, Lee MS (2010) Perioperative visual loss in ocular and nonocular surgery. *Clin Ophthalmol* 4:531–546
107. Khan AA, Hussain SA, Khan M, Corbett JJ (2012) MRI findings of bilateral posterior ischemic optic neuropathy in postcardiac transplant patient. *Neurologist* 18:313–315
108. Quddus A, Lawlor M, Siddiqui A, Holmes P, Plant GT (2015) Using Diffusion-Weighted Magnetic Resonance Imaging to Confirm a Diagnosis of Posterior Ischaemic Optic Neuropathy: Two Case Reports and Literature Review. *Neuroophthalmology* 39:161–165
109. Al-Zubidi N, Stevens S, Fung SH, Lee AG (2014) Diffusion-weighted imaging in posterior ischemic optic neuropathy. *Can J Ophthalmol* 49:e21-25
110. Wang Y, Brown DP, Duan Y, Kong W, Watson BD, Goldberg JL (2013) A novel rodent model of posterior ischemic optic neuropathy. *JAMA Ophthalmol* 131:194–204
111. Lim JW, Kang SH (2011) A case of Behçet's disease complicated by bilateral posterior ischemic optic neuropathy. *Int Ophthalmol* 31:157–160
112. Nagashima T, Matsumoto K, Murosaki T, Okada M, Iwamoto M, Makino S, Minota S (2013) Posterior ischemic optic neuropathy in a patient with granulomatosis with polyangiitis (Wegener's). *Rheumatol Int* 33:1915–1916
113. Becker EJ, Herwig MC, Holz FG, Kuchelmeister K, Thomas D, Charbel-Issa P, Löffler KU (2015) [Orbital metastasis of a previously unknown lung carcinoma mimicking posterior ischemic optic neuropathy]. *Ophthalmologe* 112:525–528
114. Coca MN, Morgan ML, Gupta P, Elkeeb A, Lee AG (2016) Bilateral posterior ischemic optic neuropathy associated with the use of Sildenafil for pulmonary hypertension. *Can J Ophthalmol* 51:e96-99
115. Rubin DS, Matsumoto MM, Moss HE, Joslin CE, Tung A, Roth S (2017) Ischemic Optic Neuropathy in Cardiac Surgery: Incidence and Risk Factors in the United States from the National Inpatient Sample 1998 to 2013. *Anesthesiology* 126:810–821
116. Ho VT-G, Newman NJ, Song S, Ksiazek S, Roth S (2005) Ischemic optic neuropathy following spine surgery. *J Neurosurg Anesthesiol* 17:38–44
117. Nickels TJ, Manlapaz MR, Farag E (2014) Perioperative visual loss after spine surgery. *World J Orthop* 5:100–106
118. Kawasaki A, Purvin V (2006) Recovery of postoperative visual loss following treatment of severe anaemia. *Clin Experiment Ophthalmol* 34:497–499
119. Roth S, Moss HE (2018) Update on Perioperative Ischemic Optic Neuropathy Associated With Non-ophthalmic Surgery. *Front Neurol* 9:557

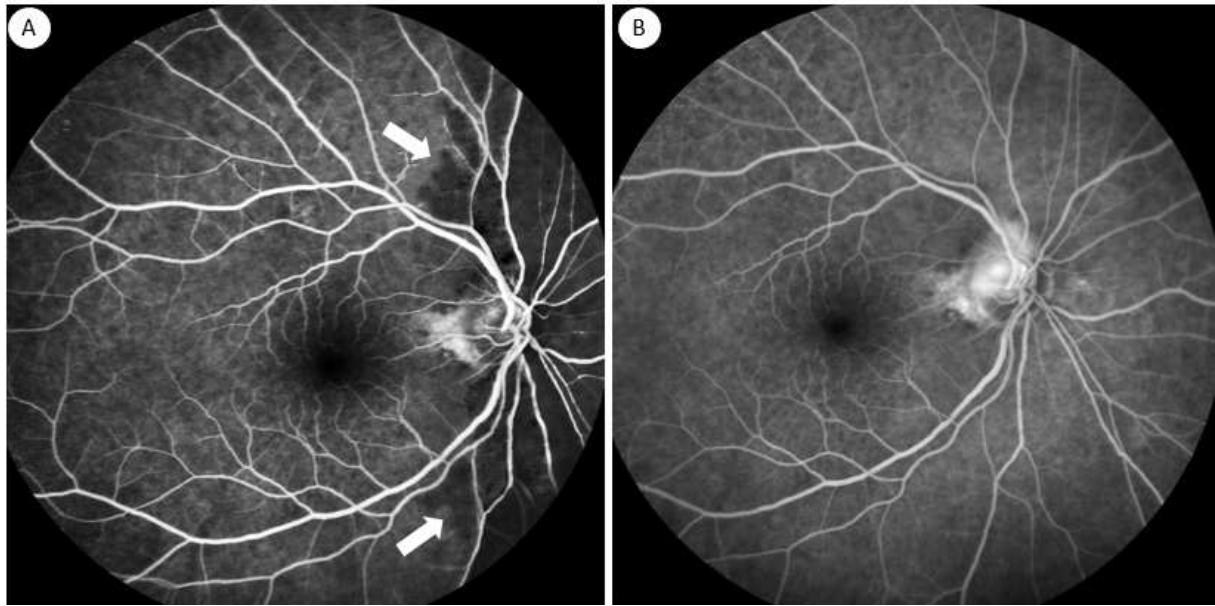


Figure 1. Fluorescein angiography of arteritic AAION, acute stage. (A) Arteriovenous phase. Delayed choroidal filling (arrows) suggestive of ischemia in the nasal choroidal territory. Due to numerous collaterals in this network, filling eventually occurs later (B). This indicates that the occlusion may have occurred in the medial short posterior ciliary artery. There is also early disc diffusion due to disc edema.

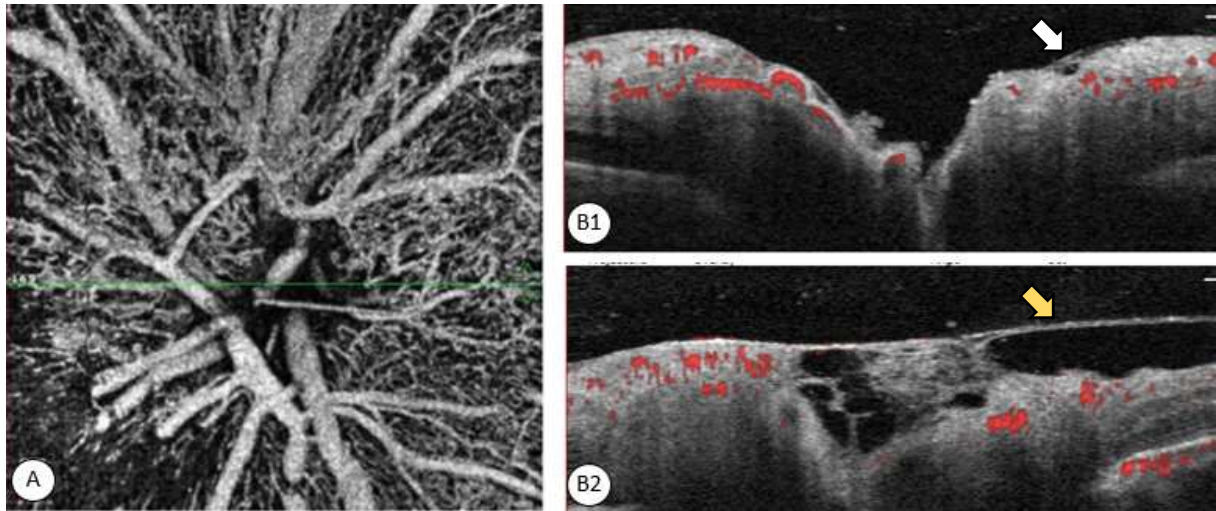


Figure 2. OCT-A of nonarteritic AAION, left eye. (A) En face OCT-A image of NA-AAION in the edematous stage. The green line shows the level of the transverse cuts. (B1) Transverse OCT-A cut through the optic disc. Posterior vitreous detachment is absent, as the posterior hyaloid (white arrow) is completely adherent to the RNFL. (B2) Same OCT-A cut 4 weeks later. Decreased disc edema, especially in the temporal portion of the disc: There is now a detachment between the posterior hyaloid (yellow arrow) and the atrophic RNFL. Nasally, the disc edema has not yet resolved, and the vitreous is still attached.

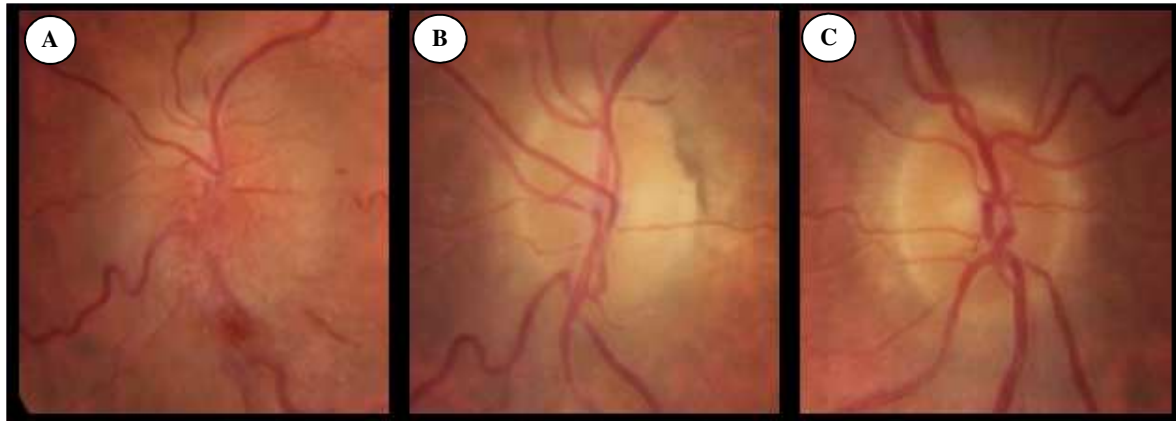


Figure 3. Nonarteritic AAION. (A) In the acute stage, optic disc edema is seen predominantly in the inferior and nasal quadrants, along with flame hemorrhages of the disc which result from capillary involvement. (B) Seven weeks later, the edema and hemorrhages have totally resolved, and nasal disc pallor is seen secondary to loss of optic nerve fibers. (C) In the fellow eye, the characteristic appearance of a small, full disc is seen, with a cup/disc ratio < 0.2 .

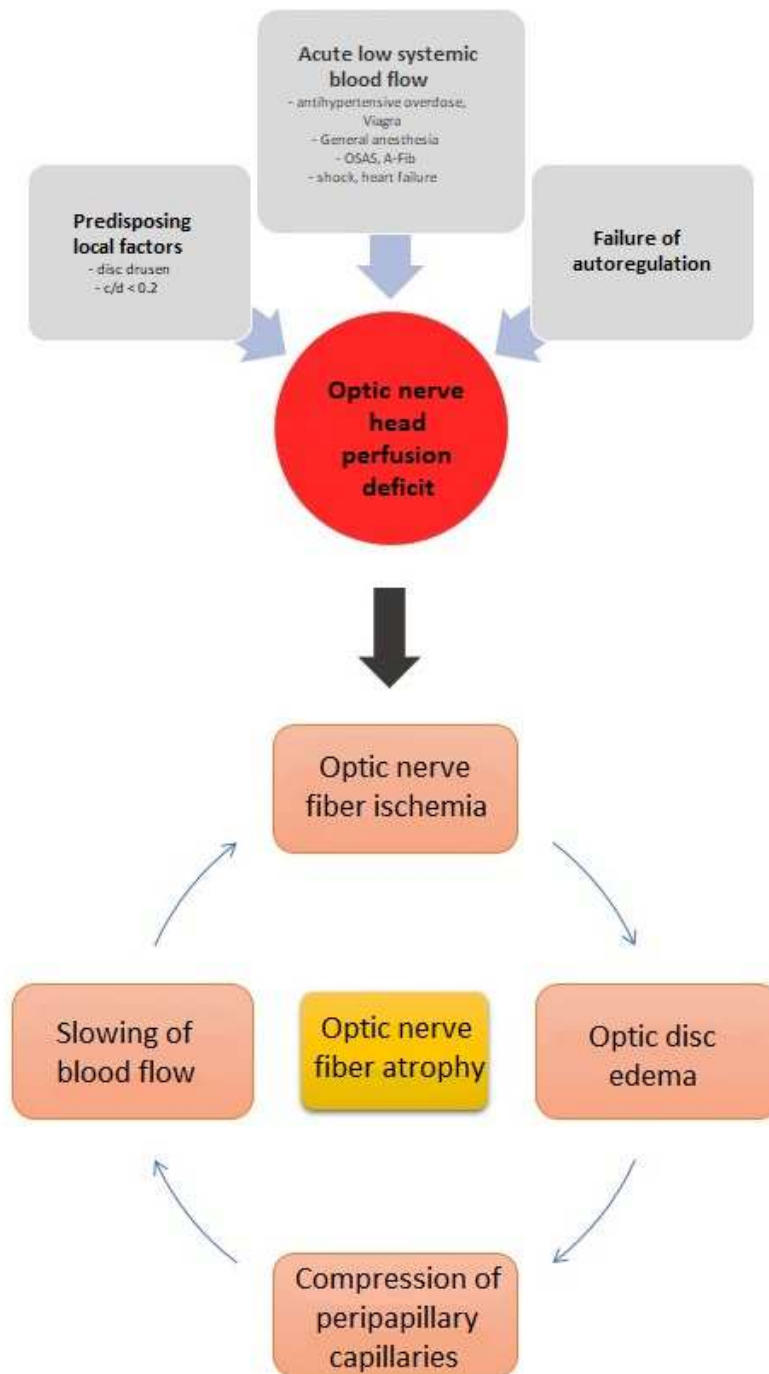


Figure 4. Simplified diagram of the pathophysiology of nonarteritic AAION.

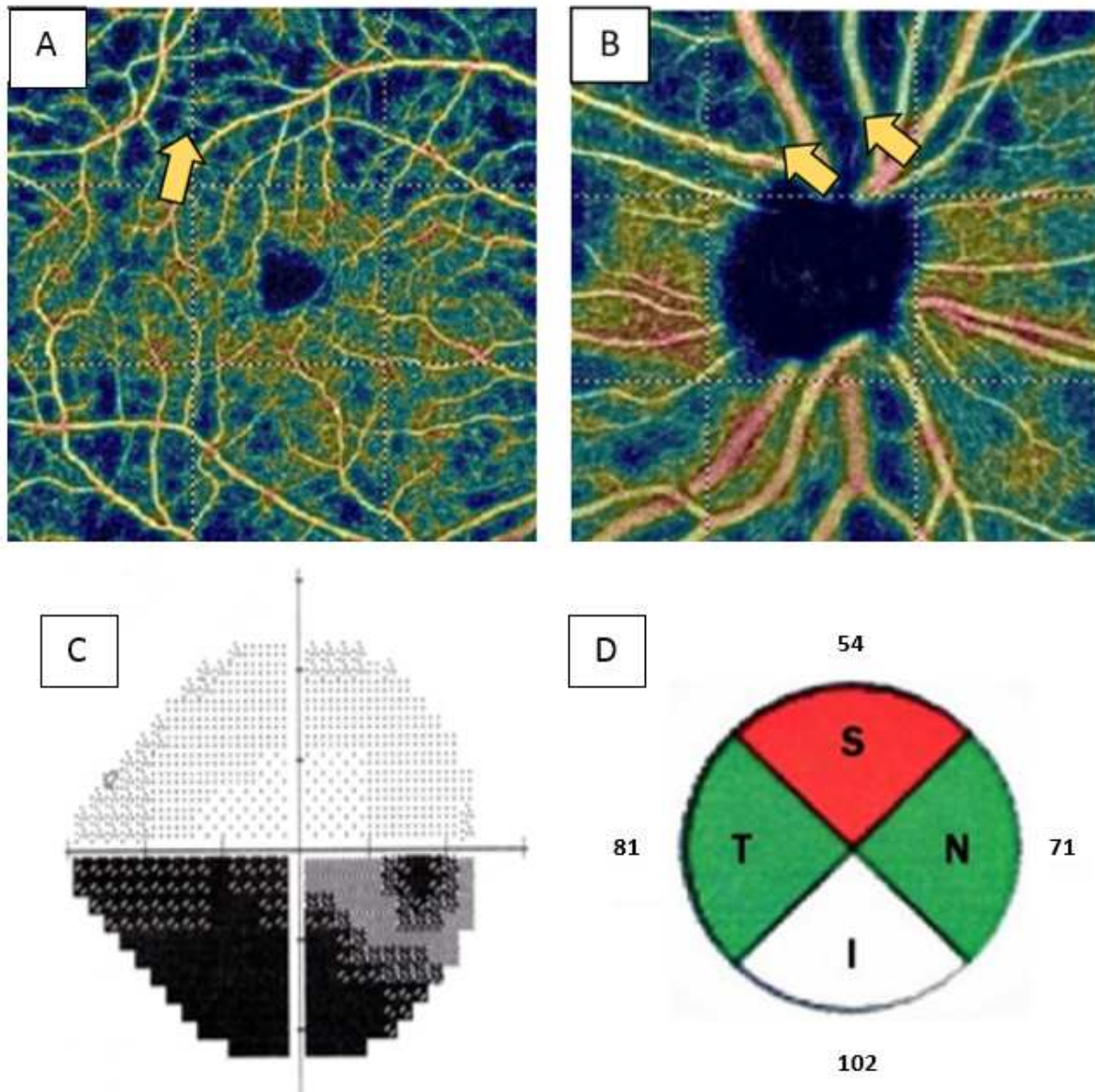


Figure 5. Correspondence between OCT-A, RNFL thickness and visual field results. (A) Macular vascular density map with segmentation within the superficial capillary plexus. There are zones of capillary dropout near the arcades (arrow) secondary to the ischemic episode. (B) Disc vascular density map with segmentation within the radial peripapillary capillaries. The ischemic zones (arrows) are predominant in the superior portion of the optic nerve and correspond to the inferior scotomatous areas (C) and superior RNFL thinning (D).

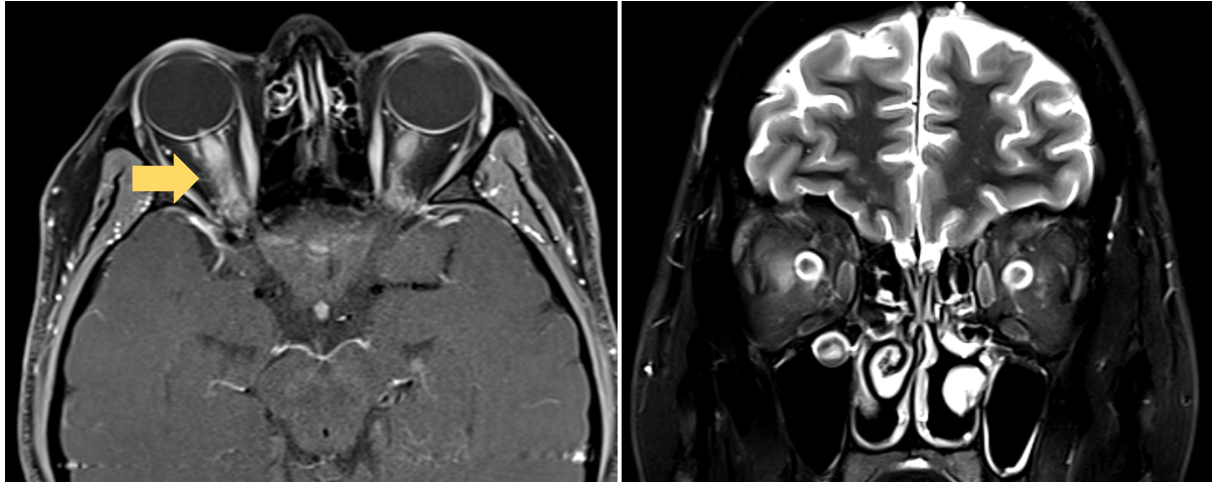


Figure 6. Posterior ischemic optic neuropathy. A characteristic hypersignal is seen within the posterior portion of the right optic nerve (arrow).

Table 1 Summary of the main studies on NA-AAION

Treatment	Presumed mechanism of action	Results	Study type
Topical			
Brimonidine	Neuroprotective	No efficacy on VA or VF	Prospective, masked, randomized vs. placebo [99]
Intravitreal			
Anti-VEGF	Accelerates resorption of disc edema	No efficacy on VA, VF or disc edema	Prospective, controlled, open [92]
Triamcinolone	Accelerates resorption of disc edema	Non-significant trend toward improvement of VA and quicker resolution of disc edema	Series of 6 cases [93]
Erythropoietin	Neuroprotective	Improvement in VA in 60% of cases at 1 month, no improvement in VF	Series of 31 cases [100]
Systemic			
Steroids	Accelerates resorption of disc edema	Controversial: earlier resolution of disc edema and improvement in VA and VF in a large series [96] but these results have never been confirmed [97, 98]	Prospective, controlled, non-randomized [96] Prospective, controlled, randomized, masked [101] Retrospective, controlled [97]
Erythropoietin	Neuroprotective	No efficacy of erythropoietin alone or in combination with intravenous steroid on VA, VF, RNFL thickness	Prospective, randomized, controlled [101]
Levodopa	Neuroprotective	Percentage of subjects with VA improvement greater in the treated group. No efficacy on VF, RNFL thickness	Retrospective, non-randomized, controlled [102, 103]
Oxygen therapy	Decreases capillary ischemia	No efficacy on VA, VF, RNFL thickness	Prospective, masked, randomized, controlled [97]
Aspirin	Improves perfusion	No efficacy on prevention of contralateral recurrences at 5 years	Retrospective, non-randomized, controlled [88]
Surgical			
Optic nerve sheath decompression	Relief of "compressive syndrome"	Increased risk of loss of 3 or more lines VA at 6 months	Prospective, open, randomized, controlled [47]

VA: best corrected visual acuity, VF: visual field