



HAL
open science

Cylindroma spine metastasis: Long-term follow-up is required

M. Riche, B. Mathon, K. Mokhtari, A. Carpentier, A. Amelot

► **To cite this version:**

M. Riche, B. Mathon, K. Mokhtari, A. Carpentier, A. Amelot. Cylindroma spine metastasis: Long-term follow-up is required. *Neurochirurgie*, 2020, 66, pp.45 - 49. <10.1016/j.neuchi.2019.09.024>. <hal-03489523>

HAL Id: hal-03489523

<https://hal.science/hal-03489523v1>

Submitted on 7 Mar 2022

HAL is a multi-disciplinary open access archive for the deposit and dissemination of scientific research documents, whether they are published or not. The documents may come from teaching and research institutions in France or abroad, or from public or private research centers.

L'archive ouverte pluridisciplinaire HAL, est destinée au dépôt et à la diffusion de documents scientifiques de niveau recherche, publiés ou non, émanant des établissements d'enseignement et de recherche français ou étrangers, des laboratoires publics ou privés.



Distributed under a Creative Commons CC BY-NC 4.0 - Attribution - Non-commercial use - International License

1 **Cylindroma spine metastasis: long-term follow-** 2 **up is required**

3
4 Maximilien Riche^a MD, Bertrand Mathon^{a,b} MD, Karima Mokhtari^{c,b}
5 MD, Alexandre Carpentier^{a,b} MD-PhD, Aymeric Amelot^{a,b} MD-PhD

6 a) Department of Neurosurgery, La Pitié-Salpêtrière, Paris, France. b) Sorbonne-University,
7 UPMC, University Paris 06, Paris, France. c) Department of Neuro-pathology, La Pitié-
8 Salpêtrière Hospital, Paris, France

9 10 **Corresponding author:**

11 Dr Aymeric Amelot, Department of Neurosurgery, Groupe Hospitalier Universitaire de la
12 Pitié-Salpêtrière, 47-83, Boulevard de l'Hôpital 75013 Paris, France. Email:
13 aymmed@hotmail.fr

14 **Running title:** ACC spine metastasis

15 **Disclosure:** The authors declare that they have neither personal conflicts of interest nor
16 institutional or financial prosperity in any drugs, materials, or devices described in this
17 manuscript. The authors have no financial disclosures to report. In addition, all patients gave
18 their informed consent for any medical and scientific investigations. This paper has not been
19 published previously, is not under consideration for publication elsewhere and we
20 acknowledge that, if accepted, this paper will not be published elsewhere in the same form, in
21 English or in any other language, without the written consent of the publisher.

1 **Abstract**

2

3 **Background:** Adenoid cystic carcinoma (ACC), or cylindroma, is a rare malignancy believed
4 to arise from epithelial cells of salivary glands. It is a slow-growing but aggressive tumor with
5 a propensity for perineural invasion. Metastases are common to the lung, but rare to the spine.
6 The natural history of ACC spine metastases is unknown and progression is unpredictable.

7 **Methods:** 1) A case report was described for a patient diagnosed with spine ACC metastasis
8 of the T6/T7 vertebrae. 2) A literature search was conducted on Medline via PubMed and the
9 Cochrane databases according to the PRISMA (Preferred Reporting Items for Systematic
10 Reviews and Meta-Analyses) guidelines to identify articles from 1973 to March 2019 using
11 following keywords: adenoid cystic carcinoma, cylindroma, metastasis, salivary glands.

12 **Results- Case report**

13 We report an unusual case of spine ACC metastasis of the T6/T7 vertebrae in a patient
14 suffering from progressive radiculopathy and thoracic pain. Based on these findings, the
15 patient underwent T6/T7 laminectomy. The diagnosis was confirmed by the pathology results.
16 The primary parotid tumor had been resected 35 years before spine metastasis. A review of
17 literature encompassing 40 years identified 16 patients treated for ACC spine metastases.
18 Mean time to spine metastases was 4.1 years after primary treatment of ACC. Spine
19 metastases were isolated, without local recurrence at the neck.

20 **Conclusion**

21 This case highlights the critical importance of long follow up of ACC patients, due to late
22 spine metastases. Diagnosis spinal metastasis of salivary carcinoma should be considered, to
23 guide management, especially in clinical follow-up.

24

25 **Keywords:** spine metastasis, cylindroma, survival, follow-up, interval

26

1 **INTRODUCTION**

2 The incidence of head and neck cancer is relatively low in developed countries and at
3 its highest in South East Asia. Adenoid cystic carcinoma (ACC), also known as cylindroma, is
4 a rare malignant tumor that accounts for around 1% of all head and neck cancers and for 10%
5 of all salivary gland neoplasms [1–3]. ACC may arise from the minor or major salivary glands
6 [2,4]. The parotid is the salivary gland most frequently affected by neoplasms, accounting for
7 approximately 75% of all cases [5].

8 Surgery is the most definitive treatment. Disease may also be managed by adjuvant
9 therapies such as chemotherapy, radiotherapy or chemoradiotherapy.

10 Natural history is characterized by an indolent but persistent growth, low likelihood of
11 regional lymph node metastasis but high rate of distant dissemination (lung, bone), and
12 eventual death [2,6,7].

13 There are scant data available in the literature to characterize and define incidence of
14 ACC spinal metastasis over time in order to adapt management. Because of the scarcity of
15 cases of vertebral metastases and the long timeline for ACC, we reported a clinical case to add
16 to the available evidence regarding the need for long follow-up.

17

18 **MATERIALS AND METHODS**

19 Here we report the case of a 71-year-old woman with a spine metastasis emanating from late
20 (35 years) relapse of the disease. A literature search was conducted on Medline via PubMed
21 and the Cochrane databases according to the PRISMA (Preferred Reporting Items for
22 Systematic Reviews and Meta-Analyses) guidelines to identify articles from 1973 to March
23 2019, using following keywords: adenoid cystic carcinoma, cylindroma, metastasis, salivary
24 glands. Twenty articles were retrieved. With inclusion criteria comprising adult patient, male
25 or female, histologic proof of ACC spine metastasis, and year of diagnosis >1973, 8 articles
26 were included, for a total of 16 patients (Figure 1, flowchart).

27

28

29

30 **CASE REPORT**

1 A 71-year-old woman was referred to our hospital in November 2017 for middle back
2 pain associated with left intercostal neuralgia. The patient reported medical history of right
3 sub-mandibular ACC tumor resection in 1981 (i.e., 37 years previously), followed by
4 radiation therapy.

5 Clinical examination suggested spinal tenderness at the level of T6-T7, with paraspinal
6 muscle spasms, but no obvious deformity of the spine. Detailed neurological examination
7 revealed thoracic back pain rapidly progressing over a few weeks, T6-T7 radiculopathy,
8 pyramidal syndrome in both lower limbs, and hypoesthesia of the right hallux. Spine MRI
9 revealed an invasive mass involving the T7 vertebral body and left pedicle and an epidural
10 location (Figure 2).

11 The patient underwent T7 decompressive laminectomy. There was immediate
12 improvement in symptoms, with significant pain relief: visual analog scale (VAS) rating of
13 back pain dropped to 1–2 points, from 8–9 points preoperatively.

14 Pathologic examination of the resection specimen confirmed spine metastasis of the
15 ACC removed in 1982 (Figure 3). Thoracoabdominal CT and PET scan showed a single
16 suspect sub-centimeter sternal lesion, with no local parotid recurrence (Figure 4). The
17 decision was made to perform complementary radiation therapy of T6-T7 and imaging control
18 of the sternal lesion. One year after surgery, at the time of writing, the patient was still alive
19 with no symptoms or signs of further relapse on clinical examination or imaging.

20
21
22

1 **DISCUSSION**

2 ACC is a tumor that usually occurs in the fifth and rarely before the second decade of
3 life [8–11].. Survival rates fluctuate between 45% and 91%, but long-term survival
4 dramatically decreases at 10 years. Natural history usually features slow growth and
5 perineural infiltration [2,12]. ACC remains a poorly understood disease because of its
6 unpredictable nature, whence the need for long-term follow-up. ACC is characterized by its
7 propensity for perineural invasion and its insidious diffuse local extension. Patients with ACC
8 can develop rare distant metastases and local recurrence [8,13].

9

10 ***Metastases***

11 The common sites of metastasis are lungs, bone, liver and brain [14], the lung being
12 the most frequent site (72.2%) [15–17]. Spine metastases are extremely rare, and often occur
13 locally (cervical), though perineural invasion in surgical resection with positive margins has
14 been reported [3,4,7,12]; perineural infiltration, hematogenous dissemination and frequent
15 positive local margins [12] makes surgical eradication difficult. For all these reasons, later
16 relapse is common [17–19]. It is unclear whether tumor metastases result from hematogenous
17 dissemination (via the venous drainage into Batson’s venous plexus and then into the arterial
18 arcade) or perineural invasion from the primary tumor. In the present case of late T7 vertebral
19 relapse, the metastatic mechanism could not be determined.

20

21 **Literature survey of ACC spine metastases**

22 Spinal metastasis from ACC of the salivary glands is exceedingly rare in the literature.
23 Only a few cases presenting spinal metastasis of the parotid gland have been documented. In a
24 series of 70 patients, which was the largest ACC series to date, Jang et al. identified 5 patients
25 with spinal metastases at diagnosis [7]. Overall survival (OS) at 5 years was < 40%. In
26 contrast, patients who developed visceral metastases (12/70, 17.1%) showed 5-year OS of
27 80%, and 10-year OS > 54%. [7]. Although the lungs are the most common site of ACC
28 metastasis, distant vertebral involvement seems to predict poorer median survival (20-20.6
29 months) [7,20].

30 As shown in Table 1, 16 cases of spine metastases of ACC were reported in the
31 literature, with mean time to metastasis of 4.1 years [range, 0.2-35 years][1,16,18–23].
32 Trilling et al. identified 3 cases of ACC spine metastases, with a mean interval of 9.4 years

1 from primary cancer to metastasis [24]. Patients with metastasis to the vertebrae were more
2 likely to have primary tumors located in the major (parotid) than minor salivary glands
3 ($p=0.038$) [7].

4 ***Other cancers***

5 There are many tumors that commonly spread to the spine, and the overall incidence
6 of spinal metastasis is approximately 5-20% [25]. However, metastasis arising from a primary
7 head and neck cancer to the spine is not widely reported [26]. Dissemination from other
8 malignancies to the spine is reported to be higher, especially from breast (20%), prostate,
9 lungs (12%), kidney and thyroid [27,28].

10 Our findings, supported by the literature, also demonstrate that distant metastasis of
11 ACC commonly occurs without local recurrence [7]. Given the slow progression of this
12 disease, patients with metastatic disease can remain asymptomatic for a long time. The
13 present case showed a relapse 36 years after diagnosis of ACC. Accordingly, it seems
14 necessary to follow patients with ACC for a long period of time. It is also important to inform
15 the patients of possible relapse years after treatment of the primary ACC.

16 This isolated T6-T7 metastasis raised the question of whether complete vertebral bloc-
17 resection might have been preferable for curative control. We opted for symptomatic surgical
18 management, firstly in light of the natural history and prognosis of spine metastatic ACC and
19 secondly because there were no radiological signs of spinal instability. At 1 year
20 postoperatively, at the time of writing, the patient had developed no secondary locations or
21 spine or neck recurrence. The sternal lesion had not progressed.

22

23 **CONCLUSION**

24 The present case illustrated ACC spine metastasis without neck recurrence, 35 years
25 after primary curative treatment. This case highlights the critical importance of following
26 ACC patients over a long period of time, due to slow indolent growth with a low propensity
27 for very late metastasis.

28 Spinal metastasis of salivary carcinoma should be considered as diagnosis, enabling
29 proper management strategy.

1 Without requiring regular long-term spine MRI, we believe that early clinical
2 suspicion has to be discussed in patients with history of ACC showing sudden-onset or
3 progressive low-back pain. MRI investigation should then be prompt.

4
5 **Funding**

6 No funding was received for this research

7
8 **Conflicts of Interest:**

9 All authors certify that they have no affiliations
10 with or involvement in any organization or entity with any financial interest (such as
11 honoraria; educational grants; participation in speakers' bureaus; membership, employment,
12 consultancies, stock ownership, or other equity interest; and expert testimony or patent-
13 licensing arrangements), or non-financial interest (such as personal or professional
14 relationships, affiliations, knowledge or beliefs) in the subject matter or materials discussed in
15 this manuscript.

16
17 **Ethical approval:**

18 All procedures performed in studies involving human participants were in accordance with
19 the ethical standards of the institutional and/or national research committee (name of
20 institute/committee) and with the 1964 Helsinki declaration and its later amendments or
21 comparable ethical standards.

22
23 **Informed consent:**

24 Informed consent was obtained from all individual participants included in the study.
25 This article does not contain any studies with human participants performed by any of the
26 authors.

1 **References**

- 2 [1] Chummun S, McLean NR, Kelly CG, Dawes PJ, Meikle D, Fellows S, et al. Adenoid
3 cystic carcinoma of the head and neck. *Br J Plast Surg* 2001;54:476–80.
4 doi:10.1054/bjps.2001.3636.
- 5 [2] DeAngelis AF, Tsui A, Wiesenfeld D, Chandu A. Outcomes of patients with adenoid
6 cystic carcinoma of the minor salivary glands. *Int J Oral Maxillofac Surg* 2011;40:710–4.
7 doi:10.1016/j.ijom.2011.02.010.
- 8 [3] Kim KH, Sung MW, Chung PS, Rhee CS, Park CI, Kim WH. Adenoid cystic carcinoma of
9 the head and neck. *Arch Otolaryngol Head Neck Surg* 1994;120:721–6.
- 10 [4] Khafif A, Anavi Y, Haviv J, Fienmesser R, Calderon S, Marshak G. Adenoid cystic
11 carcinoma of the salivary glands: a 20-year review with long-term follow-up. *Ear Nose Throat*
12 *J* 2005;84:662, 664–7.
- 13 [5] Mannelli G, Cecconi L, Fasolati M, Santoro R, Franchi A, Gallo O. Parotid adenoid
14 cystic carcinoma: Retrospective single institute analysis. *Am J Otolaryngol* 2017;38:394–400.
15 doi:10.1016/j.amjoto.2017.03.008.
- 16 [6] Bradley PJ. Adenoid cystic carcinoma of the head and neck: a review. *Curr Opin*
17 *Otolaryngol Head Neck Surg* 2004;12:127–32.
- 18 [7] Jang S, Patel PN, Kimple RJ, McCulloch TM. Clinical Outcomes and Prognostic Factors
19 of Adenoid Cystic Carcinoma of the Head and Neck. *Anticancer Res* 2017;37:3045–52.
20 doi:10.21873/anticancer.11659.
- 21 [8] Nascimento AG, Amaral AL, Prado LA, Kligerman J, Silveira TR. Adenoid cystic
22 carcinoma of salivary glands. A study of 61 cases with clinicopathologic correlation. *Cancer*
23 1986;57:312–9.
- 24 [9] Iseli TA, Karnell LH, Graham SM, Funk GF, Buatti JM, Gupta AK, et al. Role of
25 radiotherapy in adenoid cystic carcinoma of the head and neck. *J Laryngol Otol*
26 2009;123:1137–44. doi:10.1017/S0022215109990338.
- 27 [10] Lloyd S, Yu JB, Wilson LD, Decker RH. Determinants and patterns of survival in
28 adenoid cystic carcinoma of the head and neck, including an analysis of adjuvant radiation
29 therapy. *Am J Clin Oncol* 2011;34:76–81. doi:10.1097/COC.0b013e3181d26d45.
- 30 [11] Ellington CL, Goodman M, Kono SA, Grist W, Wadsworth T, Chen AY, et al. Adenoid
31 cystic carcinoma of the head and neck: Incidence and survival trends based on 1973-2007
32 Surveillance, Epidemiology, and End Results data. *Cancer* 2012;118:4444–51.
33 doi:10.1002/cncr.27408.
- 34 [12] Garden AS, Weber RS, Morrison WH, Ang KK, Peters LJ. The influence of positive
35 margins and nerve invasion in adenoid cystic carcinoma of the head and neck treated with
36 surgery and radiation. *Int J Radiat Oncol* 1995;32:619–26. doi:10.1016/0360-3016(95)00122-
37 F.

- 1 [13] Perzin KH, Gullane P, Clairmont AC. Adenoid cystic carcinomas arising in salivary
2 glands: a correlation of histologic features and clinical course. *Cancer* 1978;42:265–82.
- 3 [14] Font RL, Smith SL, Bryan RG. Malignant epithelial tumors of the lacrimal gland: a
4 clinicopathologic study of 21 cases. *Arch Ophthalmol Chic Ill* 1960 1998;116:613–6.
- 5 [15] Ko YH, Lee MA, Hong YS, Lee KS, Jung C-K, Kim YS, et al. Prognostic factors affecting
6 the clinical outcome of adenoid cystic carcinoma of the head and neck. *Jpn J Clin Oncol*
7 2007;37:805–11. doi:10.1093/jjco/hym119.
- 8 [16] Riela AR, Meyer D, McCool JA, Pikula L. Metastatic-adenoid cystic carcinoma of the
9 major salivary glands presenting as a spinal cord tumor. *Surg Neurol* 1983;19:365–8.
- 10 [17] Kumar V, Nair R, Upadhyaya S, Nayal B, Shetty A. Extradural Spinal Metastasis of
11 Adenoid Cystic Carcinoma (ACC): A Case Report. *J Clin Diagn Res JCDR* 2015;9:XD09-XD10.
12 doi:10.7860/JCDR/2015/10644.5498.
- 13 [18] Birkeland S. Spinal metastasis of submandibular gland adenoid cystic carcinoma: a
14 case report. *Surg Neurol* 2003;60:265–6.
- 15 [19] Feng H, Wang J, Guo P, Xu J, Feng J. C3 Vertebral Metastases From Tongue Adenoid
16 Cystic Carcinoma: A Rare Case Report. *Medicine (Baltimore)* 2015;94:e1135.
17 doi:10.1097/MD.0000000000001135.
- 18 [20] Sung M-W, Kim KH, Kim J-W, Min Y-G, Seong W-J, Roh J-L, et al. Clinicopathologic
19 predictors and impact of distant metastasis from adenoid cystic carcinoma of the head and
20 neck. *Arch Otolaryngol Head Neck Surg* 2003;129:1193–7.
21 doi:10.1001/archotol.129.11.1193.
- 22 [21] Liu S-Z, Zhou X, Song A, Huo Z, Zhang J, Wang Y-P, et al. Spinal Metastases from
23 Adenoid Cystic Carcinoma of the Parotid Gland. *Chin Med J (Engl)* 2018;131:2616–7.
24 doi:10.4103/0366-6999.244125.
- 25 [22] Ahmed A, Rajankulam Ganesan SK, Haleem S, Nicoll J. A rare case of late solitary
26 vertebral metastasis from an adenoid cystic carcinoma of the lacrimal gland. *BMJ Case Rep*
27 2017;2017. doi:10.1136/bcr-2016-218371.
- 28 [23] Preciado DA, Sebring LA, Adams GL. Treatment of patients with spinal metastases
29 from head and neck neoplasms. *Arch Otolaryngol Head Neck Surg* 2002;128:539–43.
- 30 [24] Trilling GM, Cho H, Ugas MA, Saeed S, Katunda A, Jerjes W, et al. Spinal metastasis in
31 head and neck cancer. *Head Neck Oncol* 2012;4:36. doi:10.1186/1758-3284-4-36.
- 32 [25] Asdourian P. Metastatic disease of the spine. *Textb. Spinal Surg.* JB Lippincott,
33 Philadelphia: Bridwell KH, DeWald RL; 1991, p. 1187–242.
- 34 [26] Thomas WH, Coppola ED. Distant Metastases from Mixed Tumors of the Salivary
35 Glands. *Am J Surg* 1965;109:724–30.
- 36 [27] Harrington KD. Metastatic disease of the spine. *J Bone Joint Surg Am* 1986;68:1110–
37 5.

1 [28] Choi D, Crockard A, Bungler C, Harms J, Kawahara N, Mazel C, et al. Review of
2 metastatic spine tumour classification and indications for surgery: the consensus statement
3 of the Global Spine Tumour Study Group. *Eur Spine* 2010;19:215–22. doi:10.1007/s00586-
4 009-1252-x.

5

6

7 **Figures**

8 **Figure 1:** Flowchart

9 **Figure 2:** (A) Preoperative sagittal T2-weighted and (B) T1-weighted MRI revealed
10 significant T6-T7 bone infiltration, hypointense on T1 and T2, and posterior epidural spinal
11 cord compression (arrow). (C) Preoperative axial T1-weighted MRI with gadolinium injection
12 demonstrated epidural compression and left lateral invasion (pedicle, lamina and costal
13 process)

14

15 **Figure 3:** Photomicrographs showing (A) the proliferation of carcinomatous cells in a
16 cribriform and adenoid pattern organized in glandular structures with luminal mucoid material
17 (H&E, X100); (B) Immunohistochemistry revealed neoplastic cells (CK7) x100; (C) PS100
18 focal expression x100, and (D): smooth muscle actin expression X100.

19 **Figure 4:** Coronal (A), and sagittal (B) postoperative bone scintigraphy indicated the skeletal
20 abnormality of T6/T7, with high suspicion of metastatic infiltration.

21

22

IDENTIFICATION

Records identified through MEDLINE
n= 17

Records identified through CENTRAL
n= 3

SCREENING

20 Records

4 excluded on title and abstract:
year of diagnosis < 1973, n=3
lack of diagnosis, n=1

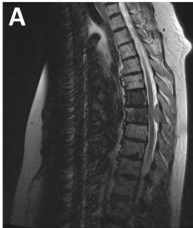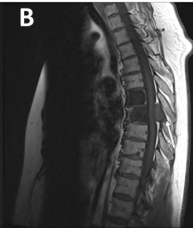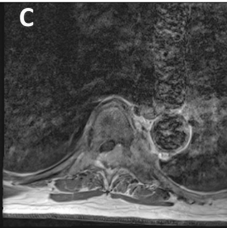
ELIGIBILITY

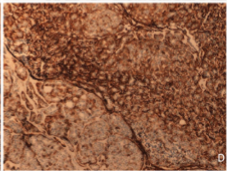
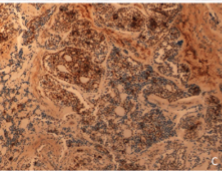
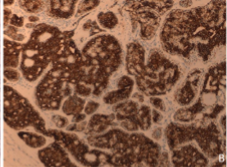
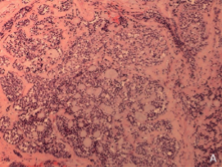
Records selected:
n=16

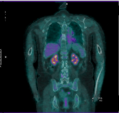
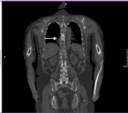
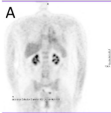
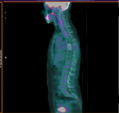
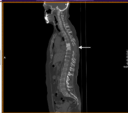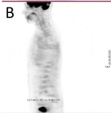8 were excluded:
metastasis other than in spine, n=8

INCLUDED

8 articles included

A**B****C**



A**B**

Study	Number of patients	ACC Primitive gland	Spine Level	Time to metastasis
Riela ²⁴ 1983	1	Parotid gland	L 2	17 y
Chummum ⁵ 2001	5	Sublingual/submandibular/Parotid	Not specified	< 12 mo
Preciado ²³ 2002	1	Tongue base	T10-L2	4.5 y
Birkeland ³ 2003	1	Parotid gland	L3-L4	7 y
Sung ²⁵ 2003	5	Sublingual/submandibular/Parotid	Not specified	10 mo-14 y
Feng ⁸ 2015	1	Tongue base	C3	5 y
Ahmed ¹ 2017	1	Lacrimal Gland	T 10	3.5 y
Liu ¹⁸ 2018	1	Parotid gland	L1, L3	3 y
Our study 2018	1	Parotid gland	T7	37 y

Table 1: review of the literature of patients with ACC who developed spine metastases (y; years, mo; months)