



HAL
open science

Giant Blisters

M. Delarue, A. Berceanu, M.-C. Laude, A. Louvrier

► **To cite this version:**

M. Delarue, A. Berceanu, M.-C. Laude, A. Louvrier. Giant Blisters. *Journal of Stomatology, Oral and Maxillofacial Surgery*, 2019, 120, pp.497 - 498. 10.1016/j.jormas.2019.01.007 . hal-03489311

HAL Id: hal-03489311

<https://hal.science/hal-03489311v1>

Submitted on 20 Jul 2022

HAL is a multi-disciplinary open access archive for the deposit and dissemination of scientific research documents, whether they are published or not. The documents may come from teaching and research institutions in France or abroad, or from public or private research centers.

L'archive ouverte pluridisciplinaire **HAL**, est destinée au dépôt et à la diffusion de documents scientifiques de niveau recherche, publiés ou non, émanant des établissements d'enseignement et de recherche français ou étrangers, des laboratoires publics ou privés.



Distributed under a Creative Commons Attribution - NonCommercial 4.0 International License

Giant Blisters

Maxime Delarue ^a, Ana Berceanu ^b, Marie-Charlotte Laude ^b, Aurélien Louvrier ^a

a Department of Maxillofacial and Facial Plastic Surgery, Jean Minjoz Hospital, 25000 Besançon, France

b Department of Haematology, Jean Minjoz Hospital, 25000 Besançon, France

corresponding author : Maxime Delarue maxime_delaruecardinaud@hotmail.com

Affiliation adress : Department of Maxillofacial and Facial Plastic Surgery, Jean Minjoz Hospital, 25000 Besançon, France

Disclosure of interests : none

Observation. A 61-year-old woman was hospitalised in the haematology department for a pheno-identical allograft transplantation of her peripheral stem cells (six days previously) in the context of acute lymphoblastic leukaemia pre-B Phi + diagnosed in 2016. An opinion was required for the discovery of oral lesions. The patient's medical history included hypertension, toxic sensory-motor axonal polyneuropathies, and latex allergy.

The current treatments were immunosuppressive agents (Neoral), penicillin V (Oracilline), beta blockers, angiotensin-converting enzyme inhibitors, fluconazole, valacyclovir, proton pump inhibitors, and ursodeoxycholic acid.

At examination, the patient had a recent swelling of her right cheek and tongue. It was her first episode, without pain, dysphagia, fever, and lymphadenopathy. No signs of skin lesions were found. Oral examination revealed two isolated giant fluctuating blisters.

The first, a ventral-side blister of the tongue with haemorrhagic content 1.5 cm in diameter on a large ulceration, appeared four days prior (Figure 1). The second blister was located in the entire mandibular right lower lateral vestibule. It had haemorrhagic content and measured approximately 5 cm in length and 2 cm in diameter (Figure 2).

Biological examinations confirmed aplastic anaemia: leukocytes 0.4 G/L, erythrocytes 2.66 T/L, haemoglobin 9.1 g/dL, neutrophils 0.28 G/L, and platelets 28 G/L.

What is your diagnosis?

Answer. Several conditions can induce acute oral blisters : traumatic (caustic) blisters, erythema multiforme, Stevens-Johnson syndrome, and angina bullosa haemorrhagica (1). Clinical and biological examinations confirmed the diagnosis of haemorrhagic blisters due to thrombocytopenia.

Discussion. Platelets achieve primary haemostasis, a key role in blood clot formation. The normal threshold of platelets is between 150 G/L and 400 G/L of blood. Thrombocytopenia is defined by a quantitative abnormality characterised by a decrease in the platelets below a threshold of 150 G/L of blood. It can be of central origin (leukaemia or cancer metastasis) or peripheral (excessive destruction, sequestration in the spleen, and medicated or toxic thrombocytopenia).

Whatever the aetiology, thrombocytopenia has an impact on haemostasis.

Between 20 G/L and 50 G/L, haemorrhagic signs are rare, except for superadded factors (antiplatelet drugs, thrombopathy, and coagulation-associated abnormalities). The presence of

buccal blisters is a clinical criterion for the severity of thrombocytopenia (2). The treatment consists of platelet transfusions (3) to increase the initial threshold of 28 G/L in the patient's blood. The presence of intact blisters, unbroken, with the aforementioned sizes, prompted us to be careful to avoid significant bleeding. To prevent the rupture of the blisters, antifibrinolytic mouthwash was administered. A few days later, the patient's platelets rose to 101 G/L. The blisters burst, leaving a voluminous ulcer. A local anaesthetic, sucralfate, and mouthwash with chlorhexidine were recommended for curative treatment (4). Perfect healing was achieved in four weeks.

Disclosure of interests

The authors declare that they have no competing interests.

REFERENCES

- [1] Vaillant L, Goga D, Ajacques JC, Ben Slama L, Boisnic S. *Dermatologie buccale*. Paris : Doin ; 1997
- [2] Société française d'Hématologie. *Référentiel des collèges d'Hématologie* (3^e ed.). Elsevier Masson ; 2018
- [3] Rivera C, Torres Í, González-Arriagada WA. Haemorrhagic bullae in the oral mucosa with gingival bleeding. *BMJ*. 2017 Oct 26;359:j4476. <https://doi:10.1136/bmj.j4476>.
- [4] Soylu Özler G, Okuyucu Ş, Akoğlu E. The Efficacy of Sucralfate and Chlorhexidine as an Oral Rinse in Patients with Recurrent Aphthous Stomatitis. *Adv Med*. 2014 ;2014 :1-3. <https://doi:10.1155/2014/986203>

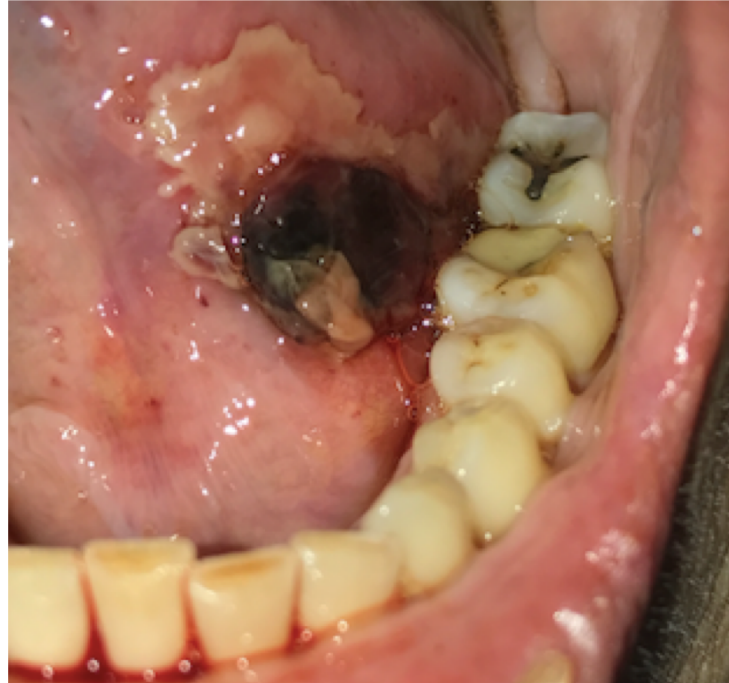

Figure 1

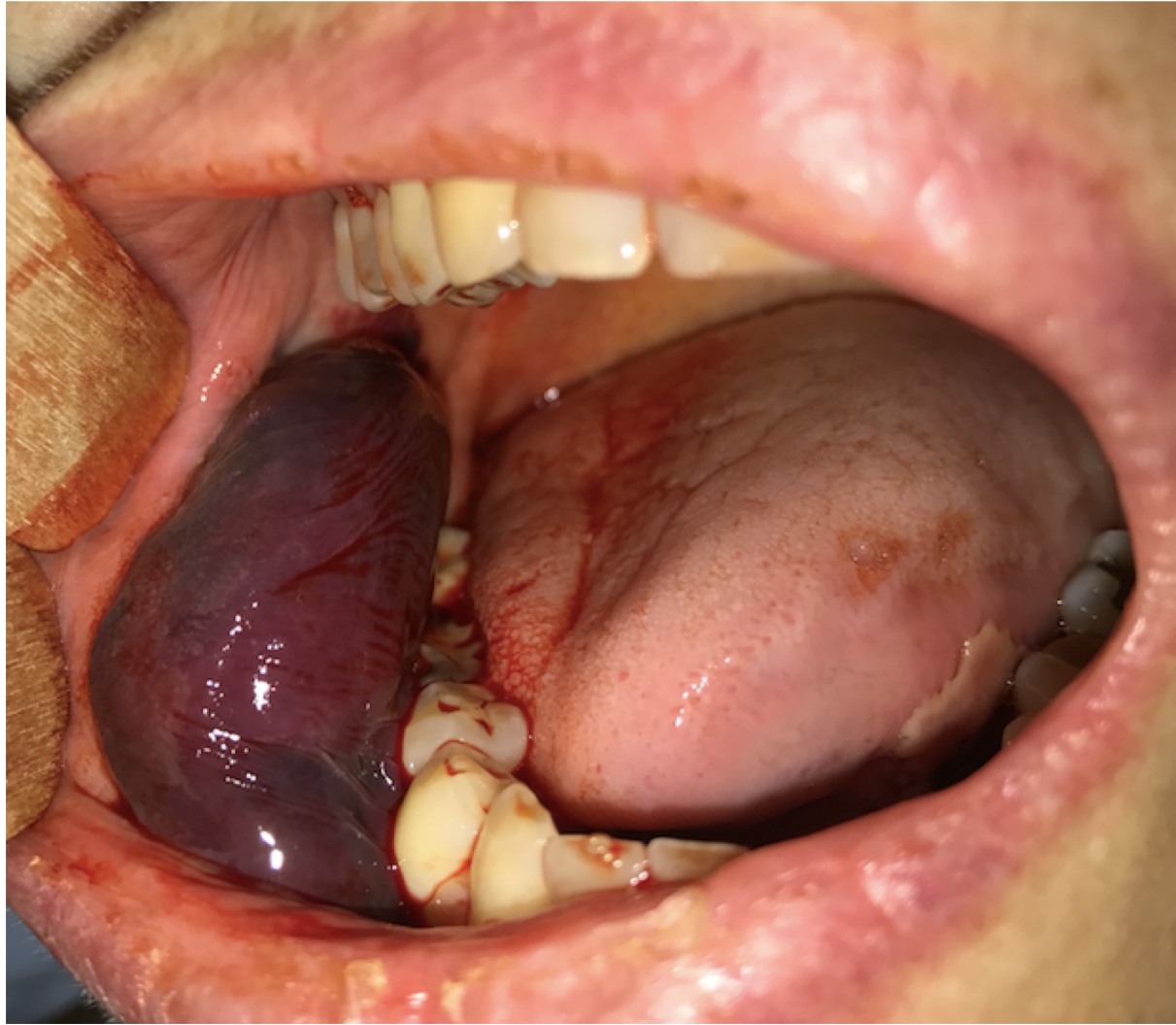


Figure 2