



**HAL**  
open science

## **Very painful acute frontal sinusitis revealing granulomatosis with polyangiitis**

M. Montero, T. Mom, P. Smets, L. Gilain

### **► To cite this version:**

M. Montero, T. Mom, P. Smets, L. Gilain. Very painful acute frontal sinusitis revealing granulomatosis with polyangiitis. *European Annals of Otorhinolaryngology, Head and Neck Diseases*, 2019, 136, pp.509 - 511. <10.1016/j.anorl.2019.05.008>. <hal-03489212>

**HAL Id: hal-03489212**

**<https://hal.science/hal-03489212v1>**

Submitted on 21 Jul 2022

HAL is a multi-disciplinary open access archive for the deposit and dissemination of scientific research documents, whether they are published or not. The documents may come from teaching and research institutions in France or abroad, or from public or private research centers.

L'archive ouverte pluridisciplinaire HAL, est destinée au dépôt et à la diffusion de documents scientifiques de niveau recherche, publiés ou non, émanant des établissements d'enseignement et de recherche français ou étrangers, des laboratoires publics ou privés.



Distributed under a Creative Commons CC BY-NC 4.0 - Attribution - Non-commercial use - International License

## **Very painful acute frontal sinusitis revealing granulomatosis with polyangiitis**

Maeva MONTERO (1)

Thierry MOM (1)

Perrine SMETS (2)

Laurent GILAIN (1)

(1) Service d'ORL et chirurgie cervico-faciale – CHU de Clermont-Ferrand, France

(2) Service de Médecine Interne – CHU de Clermont-Ferrand, France

\* Corresponding author.

e-mail: [mmontero@chu-clermontferrand.fr](mailto:mmontero@chu-clermontferrand.fr) (Maeva MONTERO)

0621583428

## **ABSTRACT**

*Introduction.* - Granulomatosis with polyangiitis (GPA) is a necrotizing vasculitis of small and medium-sized vessels comprising inflammation of the vessel wall and perivascular and extravascular granulomas, frequently presenting in the form of chronic sinusitis.

*Observation.* - We report the case of a 27-year-old man who presented with very painful acute frontal sinusitis that was managed medically and surgically. The symptoms rapidly recurred despite treatment and CT scan demonstrated diffuse thickening of the sinus mucosa. Anti-proteinase 3 ANCA were positive. Biopsy of a pulmonary nodule confirmed the diagnosis of GPA. The patient was treated with corticosteroids in combination with rituximab, resulting in improvement of the clinical, laboratory and CT signs.

*Discussion.* - In the presence of persistent, acute, localized sinusitis despite appropriate treatment, associated systemic signs and/or the presence of other signs suggestive of GPA, the ENT surgeon must request a targeted work-up. In the absence of treatment, GPA can be fatal within a few months. However, with currently available treatment, remission is obtained in 80% of cases with a 75% 10-year survival rate.

### ***Keywords***

*Granulomatosis with polyangiitis*

*Frontal sinusitis*

*Anti-Neutrophil Cytoplasmic Antibody-Associated Vasculitis*

*Anti-Neutrophil Cytoplasmic Antibodies*

*Histology*

## Introduction

Granulomatosis with polyangiitis (GPA), formerly called Wegener's granulomatosis, is a necrotizing vasculitis of small and medium-sized vessels comprising inflammation of the anti-neutrophil cytoplasmic antibody (ANCA)-associated vasculitis [1].

Head and neck involvement is present in 80% of cases of GPA, consisting of chronic sinusitis that may be isolated in the early stages of the disease [2].

Isolated acute sinusitis is an exceptional presentation of GPA, as illustrated by this unusual case report.

## Case report

A 27-year-old man, with no history of sinusitis, presented with acute left frontal sinusitis associated with supraorbital and frontal headache, which was intense and persistent despite several lines of antibiotics: amoxicillin/clavulanic acid, pristinamycin then amoxicillin/clavulanic acid and levofloxacin. The laboratory work-up revealed elevated C-reactive protein at 22 mg/L, an elevated neutrophil count at  $12.8 \times 10^9/L$  and a normal eosinophil count. CT scan of the sinuses demonstrated complete opacity of the left frontal sinus with mucosal thickening of several sinuses (Fig. 1).

Left ethmoido-maxillary meatotomy with drainage of the left frontal sinus by a Lemoyne nail allowed immediate improvement of the patient's symptoms. Culture of bacteriological samples was negative and histological examination was in favour of an inflammatory polyp.

Following early recurrence of the symptoms despite antibiotic therapy with pristinamycin, amoxicillin/clavulanic acid and then amoxicillin/clavulanic acid and levofloxacin, the left ethmoidectomy was reopened with endoscopic opening of the left frontal sinus according to a DRAF I technique. Bacteriological cultures remained negative.

Despite satisfactory opening of the left frontal sinus one month postoperatively, the patient continued to experience severe pain. Follow-up CT scan showed diffuse mucosal thickening of the paranasal sinuses with the presence of a contralateral right frontal sinus opacity.

At this stage, in the presence of persistent facial pain and resistance to treatment, the hypothesis of GPA was proposed. The laboratory work-up showed elevated c-ANCA (cytoplasmic fluorescence) at 20 IU/L with significantly elevated anti-proteinase 3 (anti-PR3) antibodies at 2.1 IU/L. MRI of the sinuses revealed marked diffuse mucosal thickening of the paranasal sinuses, predominantly on the left (Fig. 2).

The patient subsequently developed systemic signs with asthenia, anorexia, weight loss of 12 kg over 4 months, night sweats, cough, inflammatory arthralgia, left orbital swelling, right earache, and nasal chondritis. Urine culture revealed microscopic haematuria and leukocyturia without proteinuria, while renal function remained normal. A 6.8 cm mass and a pulmonary nodule were detected on chest CT angiography (Fig. 3).

Histological examination of the very large nodule was suggestive of a granulomatous lesion with alteration of certain vessel walls by an inflammatory infiltrate, confirming the diagnosis of GPA. Histological examination of surgical biopsies of sinus mucosa was negative.

Treatment with a combination of corticosteroids at a dose of 1 mg/kg/day and rituximab at a dose of 375 mg/m<sup>2</sup> in the form of 4 weekly cycles was initiated, together with cotrimoxazole antibiotic prophylaxis. This treatment allowed rapid resolution of the symptoms with the absence of any active sinus or pulmonary lesions on the 18-month follow-up CT scan.

## **Discussion**

GPA is a rare systemic disease predominantly involving the head and neck, the lungs and the kidneys. Systemic “diffuse” forms, predominantly consisting of vasculitis, are distinguished from localized forms, predominantly consisting of granulomatous inflammation [3].

Sinusitis is a common clinical presentation of GPA, but the clinical features are usually bilateral with a chronic course over several years. Isolated, unilateral acute sinusitis is an exceptional clinical presentation of GPA. To our knowledge, only one other case of acute frontal sinusitis revealing GPA has been reported in the literature [4], highlighting the unusual nature of this case report.

GPA can occur at any age, but the mean age at diagnosis is situated in the fifth decade, in contrast with the case reported here. GPA affects both sexes equally and almost exclusively concerns Caucasians (93%-98%) with a higher frequency in northern Europe [5].

The precise aetiology of GPA remains unknown, but genetic and environmental factors are thought to be involved. Various immunological abnormalities have been identified over recent years, involving c-ANCA (cytoplasmic fluorescence), circulating mononuclear cells, various lymphocyte populations, cytokines, and activation molecules [6].

Systemic signs such as fever, weight loss, anorexia, and asthenia are present in 70 to 100% of cases. Detailed clinical interview and complete physical examination can demonstrate systemic signs, such as inflammatory arthralgia, skin lesions, chondritis, and orbital swelling, that can contribute to the diagnosis.

CT scan and magnetic resonance imaging of the paranasal sinuses often reveal thickening of the sinus mucosa, bone changes or septal lysis [7]. Opacities are usually bilateral and predominantly involve the maxillary sinus. Chest CT scan must be performed looking for excavated or non-excavated pulmonary nodules, and frosted glass opacities.

Proteinuria and abnormalities of the urinary sediment must be systematically investigated. ANCA and particularly anti-proteinase 3 c-ANCA are present at the initial phase of the disease in 96% of severe forms and 83% of limited forms [8].

Histopathological examination of biopsies of affected organs confirms the diagnosis by demonstrating granulomas and necrotic vasculitis of small vessels [9].

The treatment of GPA comprises induction therapy with a combination of corticosteroids and an immunosuppressive (such as cyclophosphamide or rituximab) designed to induce remission, followed by maintenance therapy. Concomitant cotrimoxazole therapy appears to reduce the risk of relapse [9].

In the absence of treatment, GPA can be fatal within several months. Treatment ensures remission in 80% of cases. Despite a recurrence rate of 50%, the 10-year survival rate is now 75% [10].

## **4. Conclusion**

This case report highlights the central role played by otorhinolaryngologists in the diagnosis of paranasal sinus forms of GPA. The diagnosis of GPA must be considered in a young patient with no notable history, in the presence of very painful, persistent and recurrent

unilateral acute sinusitis despite appropriate treatment and the patient must be examined for the presence of associated systemic signs. These sudden-onset forms of GPA in young subjects are characterized by their severity and their rapidly deteriorating course. Early diagnosis and urgent treatment are essential determinants of the prognosis.

#### **Conflicts of interest statement**

The authors have no conflicts of interest to declare.

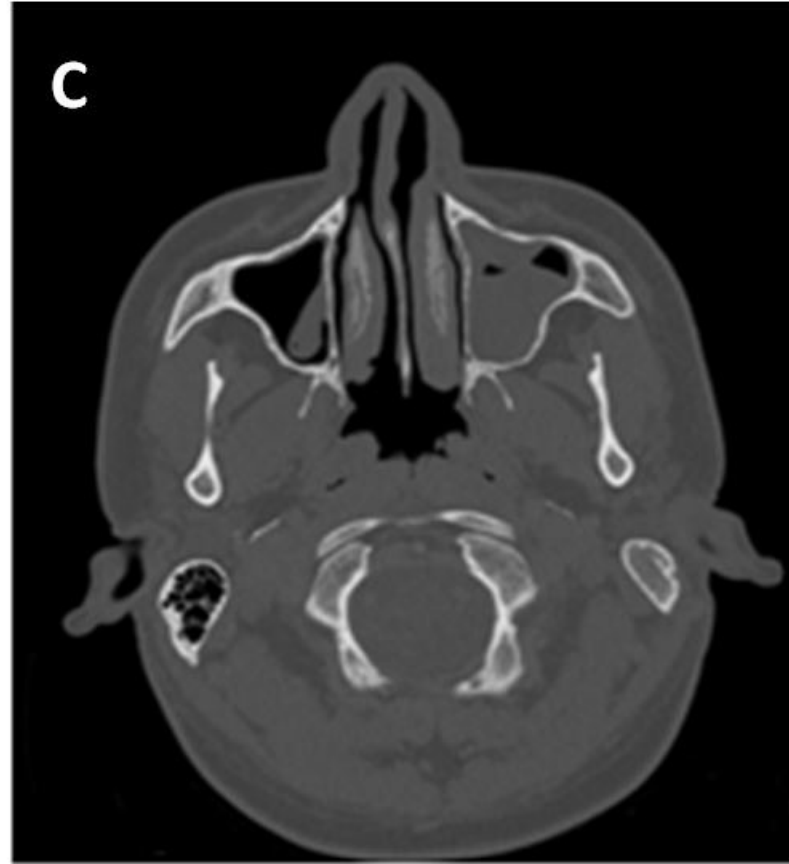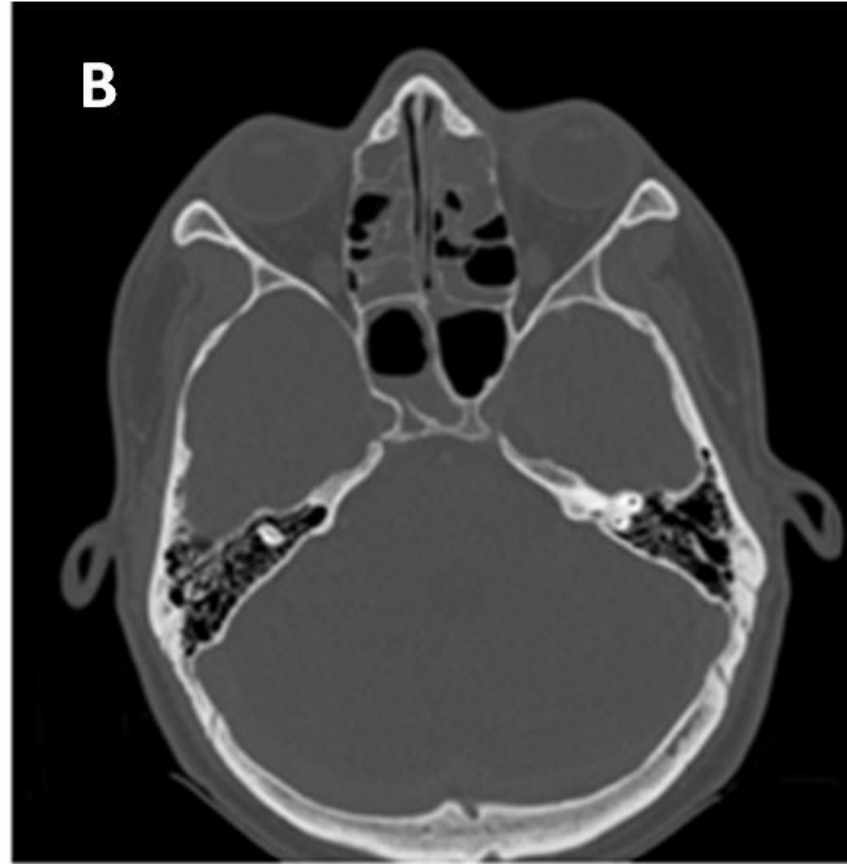
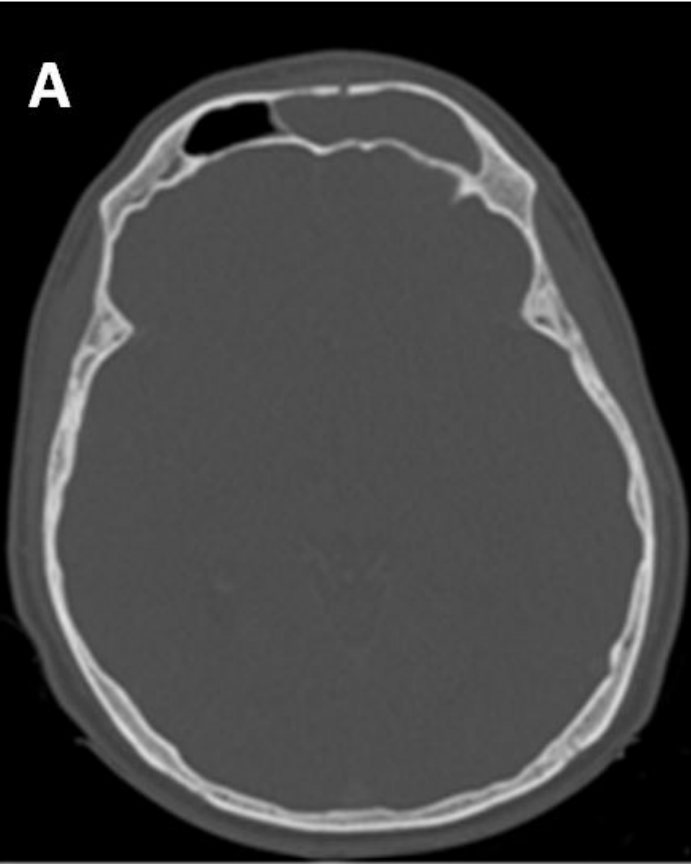
## References

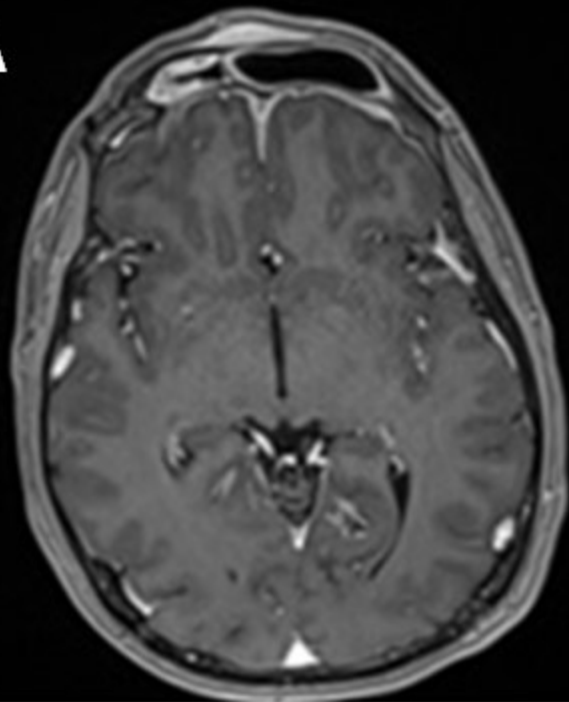
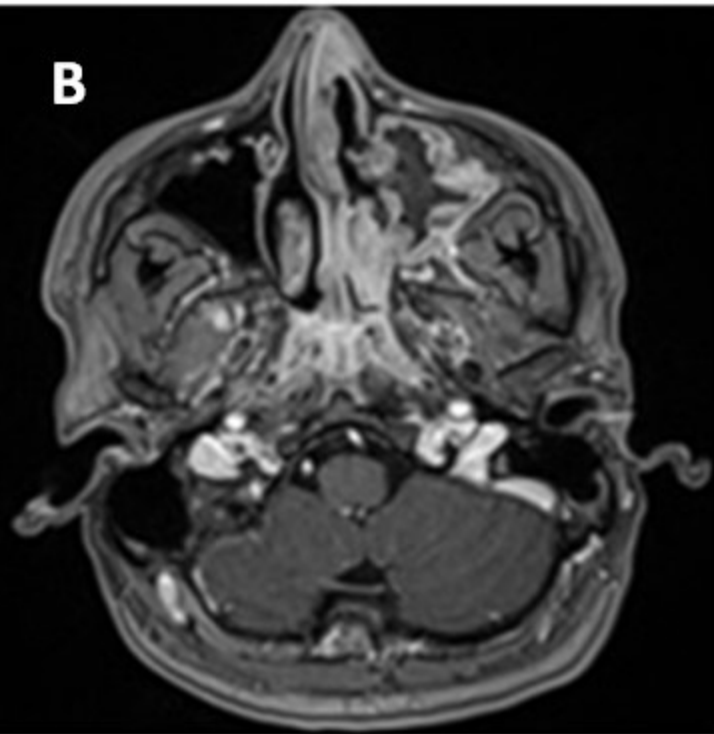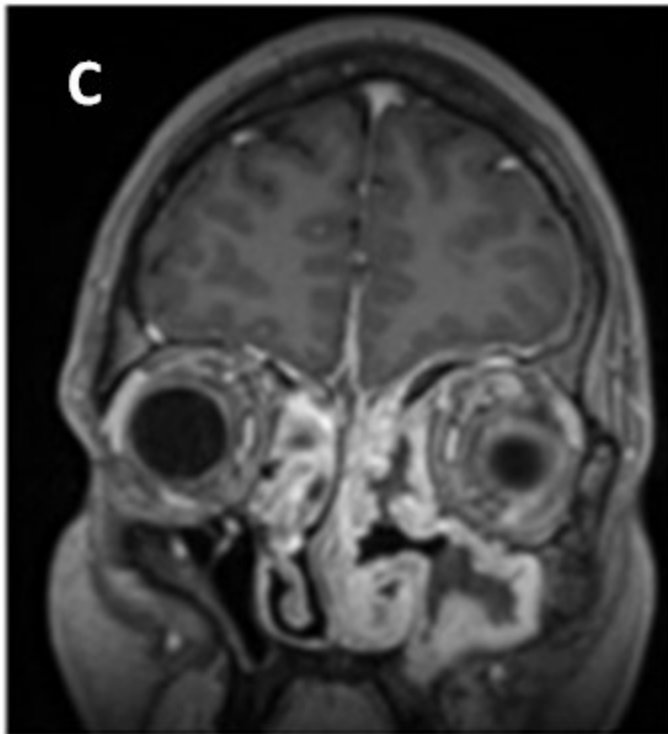
- [1] Jennette JC, Falk RJ, Bacon PA, Basu N, Cid MC et al: 2012 revised International Chapel Hill Consensus Conference Nomenclature of Vasculitides. *Arthritis and rheumatism* 2013, 65(1):1-11.
- [2] Llompart X, Aumaitre O, Kemeny JL, Mom T, Gilain L: [Early otorhinolaryngological manifestations of Wegener's granulomatosis. Analysis of 21 patients]. *Annales d'oto-laryngologie et de chirurgie cervico faciale: bulletin de la Societe d'oto-laryngologie des hopitaux de Paris* 2002, 119(6):330-336.
- [3] Hoffman GS, Kerr GS, Leavitt RY, Hallahan CW, Lebovics RS et al: Wegener granulomatosis: an analysis of 158 patients. *Annals of internal medicine* 1992, 116(6):488-498.
- [4] Abraham-Inpijn L: Wegener's granulomatosis, serous otitis media and sinusitis. *The Journal of laryngology and otology* 1980, 94(7):785-788.
- [5] Watts RA, Gonzalez-Gay MA, Lane SE, Garcia-Porrúa C, Bentham G et al: Geoepidemiology of systemic vasculitis: comparison of the incidence in two regions of Europe. *Annals of the rheumatic diseases* 2001, 60(2):170-172.
- [6] Flint J, Morgan MD, Savage CO: Pathogenesis of ANCA-associated vasculitis. *Rheumatic diseases clinics of North America* 2010, 36(3):463-477.
- [7] D'Anza B, Langford CA, Sindwani R: Sinonasal imaging findings in granulomatosis with polyangiitis (Wegener granulomatosis): A systematic review. *American journal of rhinology & allergy* 2017, 31(1):16-21.
- [8] Finkelstein JD, Lee AS, Hummel AM, Viss MA, Jacob GL et al: ANCA are detectable in nearly all patients with active severe Wegener's granulomatosis. *The American journal of medicine* 2007, 120(7):643.e9-14.
- [9] Yates M, Watts RA, Bajema IM, Cid MC, Crestani B et al: EULAR/ERA-EDTA recommendations for the management of ANCA-associated vasculitis. *Annals of the rheumatic diseases* 2016, 75(9):1583-1594.
- [10] Puechal X, Pagnoux C, Perrodeau E, Hamidou M, Boffa JJ et al: Long-Term Outcomes Among Participants in the WEGENT Trial of Remission-Maintenance Therapy for Granulomatosis With Polyangiitis (Wegener's) or Microscopic Polyangiitis. *Arthritis & Rheumatology* 2016, 68(3):690-701.

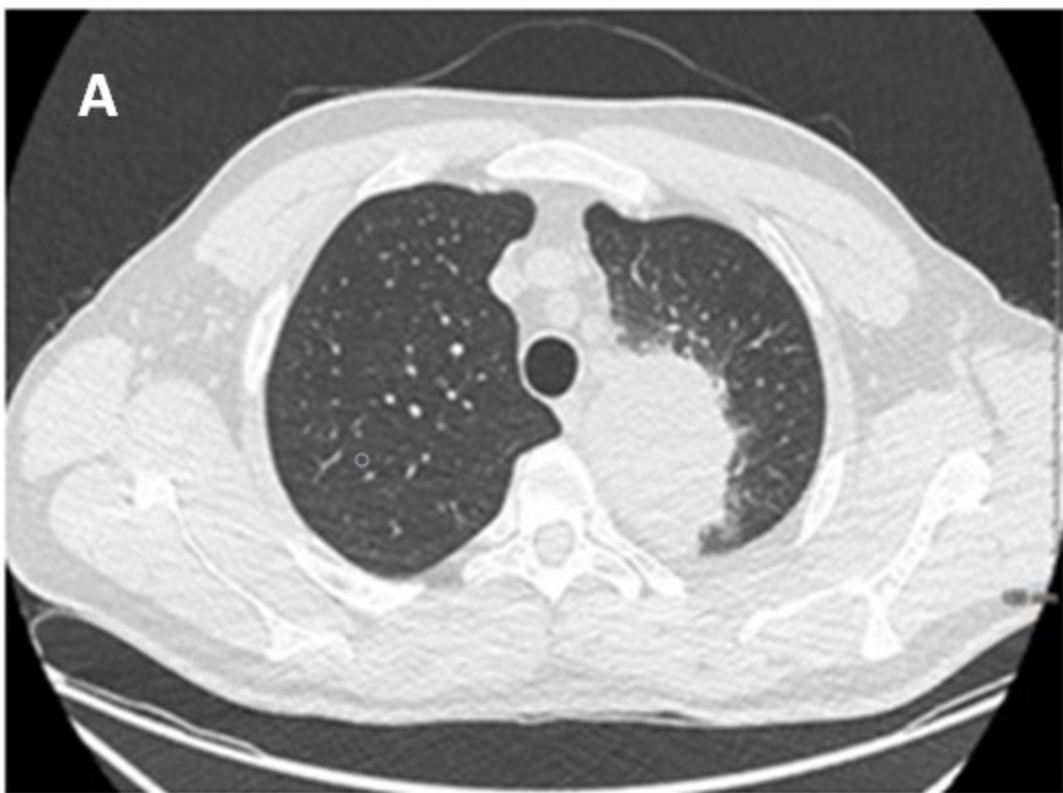
**Fig. 1.** Axial CT scan of the sinuses. A. Opacity of the left frontal sinus. B. Opacity of the left anterior ethmoidal cells. C. Moderate mucosal thickening of the maxillary sinus.

**Fig. 2.** Postoperative MRI of the sinuses, axial (A, B) and coronal (C) scans, gadolinium-enhanced T1-weighted sequence. A. Mucosal thickening of the right frontal sinus and good aeration of the left frontal sinus. B, C. Opacity and diffuse mucosal thickening, predominantly on the left. C. Left orbital mass.

**Fig. 3.** Chest CT scan. A. Left upper lobe solid mass surrounded by haemorrhage. B. Right pulmonary nodule measuring 9 mm in diameter.



**A****B****C**

**A****B**